HANDBOUND
AT THE
UNIVERSITY OF
TORONTO PRESS

9445 I

THE Ophthalmoscope

A Monthly Review of Current Ophthalmology.

Editor:
SYDNEY STEPHENSON
(London).

Sub-Editor:
ERNEST THOMSON
(Glasgow).

Editorial Secretary:
T. HARRISON BUTLER
(Leamington).

Correspondents:
Dr. JAMES BARRETT and Dr. T. K. HAMILTON (Australasia); Dr. P. COOTE and Dr. HANFORD McKEE (Canada); Lieut.-Col. H. HERBERT and Lieut.-Col. R. H. ELLIOT (East Indies); Dr. C. MANCHÉ (Malta); Dr. A. DARIER (France); Dr. G. F. ROCHAT (Holland); Professor A. BIRCH-HIRSCHFELD (Germany); Dr. RICKARD VIDÉKY (Austria-Hungary); Dr. A. ANTONELLI (Italy); Dr. H. COPPEZ (Belgium); Professor HAAB (Switzerland); Dr. FORSMARK (Scandinavia); Dr. EMILIO ALVARADO and Dr. ADOLFO ALVAREZ (Spain); Dr. M. URIBE-TRONCOSO (Mexico); ARTHUR F. MacCALLAN (Egypt); and A. W. STIRLING (Georgia, U.S.A.)

VOL. XI.
(1913)

London:
GEORGE PULMAN AND SONS, LTD.

1913.

RE
1
078
v.11
no.7-12

LIBRARY
DEC 8 1964
UNIVERSITY OF TORONTO

946574

INDEX

Original Communications and Clinical, Pathological and Bacteriological Memoranda.

PAGE

BALLANTYNE, ARTHUR J.—Pulsation of the retinal arteries 271, 338, 460

BENNETT, H. PERCY.—Case of recurrent hæmorrhages into vitreous in a young patient (with retinitis proliferans) cured by administration of thyroid extract... ... 20

BRAILEY, W. H.—A method of operating on after-cataract, etc. 600

BRIDE, T. MILNES.—Epileptic fits induced by the use of eserin sulphate 21

BURCH, GEORGE J.—On negative after-images with pure spectral colours 143

BURDON-COOPER, JOHN.—Direct ophthalmoscopic examination with indirect vision and illumination 729

BUTLER, T. HARRISON.—Case of optic neuritis with retinitis and consecutive atrophy associated with pregnancy 597

CRAGGS, Lieut. H. C. and TAYLOR, Assistant-Surgeon, C. G.—A research into the relation between systematic blood tension and raised intra-ocular tension ... 350

CRIDLAND, BERNARD.—Gonorrhœal infection in eye diseases 64

——————— The visual fields in coal miners' nystagmus 727

COATS, GEORGE.—Infarction of the posterior ciliary arteries 708

COLLINS, E. TREACHER.—A pathological report upon a case of Doyne's choroiditis. ("Honeycomb" or "family" choroiditis) 537

CROSS, F. R.—Discussion on the present position of ophthalmology in Great Britain 518

DEUTSCHMANN, FRANZ.—The pathogenesis of sympathetic ophthalmitis 654

DOYNE, ROBERT W.—On the present position of ophthalmology 508

DRAKE-BROCKMAN, E. F.—A note on extraction of cataract by rupturing the capsule antecedent to the section through the cornea 351

ELLIOT, LIEUT.-COL. R. H.—A case of soamin poisoning resulting in optic atrophy 15

——————On the use and management of self-lit ophthalmoscopes ... 145

——————Some additional notes on sclero-corneal trephining 324

——————Trephining in glaucoma, acute and chronic: miscellanea 523, 580

GIRI, D. V.—Contact infection of carcinoma of the eye 202

——————— On concretions in the optic nerve 390

GRÓSZ, EMILE v.—The methods of cataract extraction practised in the Royal Hungarian University Eye Hospital No. 1, Budapest 576

——————The No. 1 Royal Hungarian University Eye Hospital in Budapest 206

——————The present position of ophthalmology in Hungary 517

HARMAN, N. BISHOP.—A phantom for use in the practice of squint operations 285

——————A scheme for the exact record of fundus changes in myopia 335

——————Lengthening a rectus tendon in squint operations 17

——————Partial tenotomy of a lateral rectus to secure vertical deviation ... 74

HAWTHORNE, C. O.—The relation of ophthalmology to general medicine 513

HAY, PERCIVAL J.—Synchysis scintillans 663

HERBERT, H.—Some complications recently met with in glaucoma operations 398

IGERSHEIMER, J.—Recent investigations dealing with inherited syphilis of the eye 718

JOHNSON, G. LINDSAY.—Notes on the new operative treatment of glaucoma 539

JULER, F. A.—Acute purulent keratitis in exophthalmic goitre, treated by repeated tarsorrhaphy, resection of the cervical sympathetic, and X-rays: retention of vision in one eye 456

KILLICK, CHARLES.—A year's record of cataract extraction 11

LAMB, ROBERT SCOTT.—Perithelioma of the eyelids 401

MACCALLAN, A. F.—An operation for ectropion of the lower lids 538

PAGE

McKEE, HANFORD.—Foreign body in the orbit: removal after two years 159
——————Meningococcus conjunctivitis 75
——————Retinitis pigmentosa: a pathological report 408
MADDOX, ERNEST E.—*See* Stirling, A. W. 660
MARPLE, WILBUR B.—On the electric ophthalmoscope with presentation of a new model ... 663
MOULD, GEORGE T.—Clinical notes on a case of glaucoma covering a period of twenty years... 76
OBARRIO, P. DE—Rational surgery of retro-bulbar neoplasms with report of a case of cylindroma of the orbit, with extirpation of the same and preservation of the eye 148
OLIVER, GEORGE H.—Hyaline bodies at the optic disc in a case of retinitis pigmentosa ... 716
——————Thirteen cases of hereditary transmissions of retinitis pigmentosa in two generations 407
PAUL, GEORGE A.—Congenital coloboma of both upper lids 473
PEEL, THOS. A.—Notes on the vaccine treatment of infections which involve the cornea ... 471
PERCIVAL, ARCHIBALD STANLEY.—Trephining the sclerotic 219
POSEY, WILLIAM CAMPBELL.—Two unusal orbital conditions 466
REEVE, R. A.—The present position of ophthalmology in Canada 513
RIDLEY, N. C.—Some commonplaces with regard to plastic operations 650
SOBHY, M.—Case of congenital coloboma of the lens 156
STEPHENSON, SYDNEY.—Case of septic endophthalmitis associated with the diplococcus lanceolatus 411
——————On the present position of ophthalmology in Great Britain 520
——————On some causes of failure after Elliot's sclero-corneal trephining ... 640
STEVENSON, EDGAR.—Case of acute glaucoma excited by homatropin 73
——————Foreign body, three inches long, removed from orbit of a small boy: wound of optic nerve 23
STIRLING, A. W.—Latent convergence or divergence? with addendum by Ernest E. Maddox 660
THOMSON, ERNEST.—British and Continental eye clinques; some comparisons and contracts... 136
——————Hyaline nodules in the optic disc in a case of retinitis pigmentosa ... 19
TIRUMURTI, T. S.—Case of traumatic multilocular implantation corneal cyst 268
VERHOEFF, F H.—A further note on the sclerectome 220
——————Brawny scleritis 2
WALLIS, G. F. C.—Elliot's trephining for glaucoma and its technique 588
——————Interstitial keratitis (congenital syphilitic) treated with salvarsan 342
——————The restoration of the anterior chamber after Elliot's operation 594
WHITHAM, LLOYD B.—Experiments on the excretion of salicylic acid in the ocular humours... 71
WHITNALL, S. E.—The ligamentum palpebrarum mediale 216
WOOD, C. G. RUSS.—On pseudoneuritis 530
——————and ANDERSON, FREDERICK A.—Guaiacol diaphoresis in ophthalmology 347
ZORAB, ARTHUR.—Aqueoplasty 211
——————A note upon essential oils in the treatment of irido-cyclitis 406

Translations.

ATTIAS, GUSTAVO.—Senile changes found in the human eye 222
GREEFF, R., STOCK, and WINTERSTEINER.—Guide to the microscopic examination of the eye. (Translated by Hugh Walker) 92, 170, 229, 288
RÖNNE, HENNING.—Studies on the fields of vision with reference to the relationship between peripheral visual acuity and colour sense and especially regarding their influence upon the prognosis of atrophy of the optic nerve 25
STARGARDT and OLOFF.—On the significance and the method of examining the colour sense 79

Novelties.

PAGE

Director-forceps for use in partial tenotomy. (N. Bishop Harman) 24
Hand perimeter 540
Modified glaucoma trephine. (F. A. Anderson) 668
Near vision phorometer. (Ernest E. Maddox) 287
New cutting cystitome. (F. R. Cross) 413
New eyelid retractor. (C. G. Russ Wood) 221
New sclerectome. (Percy C. Bardsley ... ... [illegible]
"Signal" vision test type. (N. Bishop Harman) ... ... [illegible]
Tarsal cyst forceps. (Arthur Greene) 733
Trephine worked by electric motor. (H. H. Taylor) 669

Book Notices.

PAGE

Abstract-Bulletin of the Physical Laboratory of the National Electric Lamp Association, Cleveland, Ohio, Vol. I, No. 1. E. P. Hyde, Director 700
Accidents from defective sight. (Nettleship.) London, 1913. 567
Adrenaline mydriasis and its diagnostic significance. (*Die Adrenalin Mydriasis und ihre diagnostiche Bedeutung.*) (Cords.) Wiesbaden, 1911 185
American encyclopedia and dictionary of ophthalmology. Edited by Casey A. Wood. Vol. I. A to Azio. Chicago, 1913. 698
Anatomy and histology of the human eyeball in the normal state, its development and senescence. (Salzmann.) (Authorized translation by Dr. E. V. L. Brown.) Chicago, 1912 ... [illegible]
Anatomy of the human eye, as illustrated by stereoscopic photographs. (Thomson.) Oxford, 1912 125
Angiomatosis of the retina. (von Hippel's disease.) *Die Angiomatose der Retina.* (*von Hippelsche Krankeit*). (Vossius.) *Sammlung zwangloser Abhandlungen aus dem Gebiete der Augenheilkunde*, Band IX, Heft i. 1913. Halle 260
Anomalies of scleral tension. (*Die Anomalien der Skleralspannung.*) Stransky, Bd. I. Leipzig und Wien. 1912 187
Bericht über die Neununddreissigste Versammlung der Ophthalmologischen Gesellschaft, Heidelberg, 1913. Wiesbaden. 698
Bulletin de la Société Belge d'Ophtalmologie. No. 34. Gand: 21-23. 1913. 187
Bulletins et Mémoires de la Société Française d'Ophtalmologie. Twenty-ninth year, 1912. Paris 54
Compendium of the pharmacopœias and formularies (official and unofficial), with practical aids to prescribing and dispensing. (Thompson.) Fourth Edition. London, 1913 ... 701
Diseases and injuries of the eye. (Edinburgh Med. Series.) (Sym.) London, 1913 568
Diseases of the eye. (de Schweinitz.) Seventh Edition. London and Philadelphia, 1913 ... 698
Diseases of the eyes. (Marshall.) London, 1912 123
Elliot's corneo-scleral trephining: a technical study, anatomical and experimental researches. (*La trépanation cornéo-sclérale d'Elliot: étude technique, recherches anatomiques et experimentales.*) (Ducamp.) Paris, 1913 636
Eye-strain in everyday practice. (Stephenson.) London, 1913 186
La rétinite albuminurique. (Albuminuric retinitis.) (Rochon-Duvigneaud.) Paris, 1912 54
Le nystagmus (*tremblement oculaire*). (Coppez.) Paris, 1913 446
Geometrical optics. (Percival.) London, 1913 314
Guide to the microscopic examination of the eye. (Greeff, Stock, and Wintersteiner.) Translated from the third German edition by Hugh Walker. London, 1913 699
Julius Hirschberg's Ausgewählte Abhandlungen. (1868-1912.) Fehr and Muhsam. Leipzig. 1913 634

PAGE

Merck, E.—Annual report on recent advances in pharmaceutical chemistry and therapeutics. Vol. XXV. 1912. London 56
Vol. XXVI. 1913 701

Miners' nystagmus: its causes and prevention. (Llewellyn.) London, 1912 263

——— (*Das Augenzitten der Bergleute.*) (Ohm.) Leipzig, 1912 127

Monograph on albinism in man. (Pearson, Nettleship, and Usher.) (Drapers' Company research memoirs, biometric Series IX.) Text part IV., and atlas part IV. London, 1912 ... 764

Non-traumatic dislocation of the lens. (*Ueber traumatische Linsenluxation.*) Davids. Halle, 1912 635

Ophthalmic semiology and diagnosis. (Pyle's System of Ophthalmic Practice.) (Beard.) Philadelphia 447

Ophthalmic surgery. (Meller.) (Edited by W. M. Sweet). Second edition. London, 1912 315

Ophthalmic year book. Vol. IX. Edited by E. Jackson. Denver, 1913 567

Opuscula selecta Neerlandicorum de arte medica. Fasciculus II. (Camperi). Amsterdam, 1913 500

Origin of myopia. (*Die Entstehung der Kurzsichtigkeit.*) (Levinsohn.) Berlin, 1912 ... 54

Origin of spherical refractions of the human eye. (*Die Entstehung der sphärischen Refraktieren des menschlichen Auges*). (Steiger.) Berlin, 1913 765

Outlines of applied optics. (Nutting.) Philadelphia, 1912 315

Over de Accommodatie en Refractie van het oog. Een Kort Overzicht van het Wekk van Donders en ven de Vorderingen die in de laatste 50 Jaar ziju Gemaakt. (Clarke.) Amsterdam, 1913 500

Précis d'ophtalmologie. (Morax.) Deuxième Edit. refondue. Paris, 1913 700

Researches in colour vision and the trichromatic theory. (Abney.) London 449

Royal London Ophthalmic Hospital Reports. Edited by J. H. Parsons. Vol. XIX., pt. 1, July, 1913 566

Sclero-corneal trephining in the operative treatment of glaucoma. (Elliot.) London, 1913 ... 264

Significance of the teachings of heredity in ophthalmology. (*Die Bedeutung der Vererbungslehre für die Augenheilkunde.*) (Peters.) Halle, 1911 377

Studies in clinical medicine. (Hawthorne.) London, 1912 122

Surgery of the eye. (Török and Grout). London, 1913 501

Text-book of diseases of the eye. (*Lehrbuch der Augenheilkunde.*) (Professors Axenfeld, Bach, Bielschowsky, Elschnig, Greeff, Heine, Hertel, v. Hippel, Krückmann, Oeller, Peters, and Stock.) Edited by Professor Axenfeld. Third edition. 1912 261

Text-book of ophthalmology in the form of clinical lectures. (Roemer.) Translated by M. L. Foster. Vols. I, II, III. London 185, 378

Trachoma and its complications in Egypt. (MacCallan.) London. 1913 764

Transactions of the American Ophthalmological Society. Vol. XIII, Part i. 1912 125

Transactions of the American Ophthalmological Society, Forty-ninth Annual Meeting. Washington, D.C., 1913. Vol. XIII. Part ii. Philadelphia. 1913 698

Transactions of the Ophthalmological Society of the United Kingdom. Vol. XXXII, Fasc. 3 1912 53
Vol. XXXIII, 1913 ... 638

Transactions of the Seventeenth Annual Meeting of the American Academy of Ophthalmology and Oto-Laryngology, held at Niagara Falls, Ontario, on August 20, 21, and 22, 1912 447

Treatment after operation. (Turner and Carling.) London, 1912 190

Vicious circles in disease. (Hurry.) London. Second edition. 1913 260

NAMES.

PAGE

Abadie, C. ... 255, 541
Abney, Sir W. de W. ... 449
Adams, M. A. ... 382
Addario, C. ... 492
Agricola, B. ... 435, 692
Albanese ... 682
Alexander, E. W. ... 357
Alger, E. M. ... 498
Alt, Adolf ... 34, 112, 614, 742
Anderson, F. A. ... 255, 347, 668
Antonelli, A. ... 178, 255, 617
Arboleda... ... 679
Armaignac, H. ... 297, 676
Attias, G. ... 222, 547
Angstein... ... 425
Aurand, L. ... 487

Bach, L.... ... 674
Bahn, C. A. ... 632
Baildon, F. J ... 108
Ballantyne, A. J. ... 271, 338, 460, 503
Barck, C. ... 632
Bardsley, P. C. ... 160
Barnes, S. ... 606
Barr, J. S. ... 632
Bartels, M. ... 28
Batten, F. E. ... 553
Baudry, S. ... 561
Bayer, H. ... 614
Beard, C. H. ... 447
Beauvieux ... 182, 561
Beduarski ... 176
Behr, C.... ... 734
Belenky-Raskin... ... 674
Bennett, H. Percy ... 20
Berche 103
Bettremieux, P.... ... 357, 429
Bey, S. 747
Bietti, A.... ... 354, 756
Birch-Hirschfield, A. ... 255, 429, 482
Bishop, J. T. ... 372
Bistis, J. ... 182
Blaauw, E. E. ... 296
Bogatsch, G. ... 357
Botteri, A. ... 492
Bourdier ... 354
Bourland ... 605
Brailey, W. H. ... 600
Brandenburg, F. ... 542
Brandès, F. ... 180
Bray, A. 684
Brewerton, Elmore ... 552
Bribak, E. J. ... 297
Bride, T. Milnes ... 21
Bronner, A. ... 372, 678
Brown, S. H. ... 364
Brown, W McEnery ... 296
Browne, F. J. ... 175
Browning, S. H. ... 234, 692
Brückner, A. ... 753
Brunetière, C. ... 483
Bruno, D. ... 498
Brunszlow ... 414
Burch, George J. ... 143
Burdon-Cooper, J. ... 729

PAGE

Butler, T. H. ... 384, 435, 597, 630
Byers, W. Gordon M. ... 235

Calderaro ... 182, 371, 413
Calendoli, S. ... 747
Calhoun 415
Calhoun, F. P.... ... 498
Calhoun, J. G 622
Camille ... 679, 753
Campbell, E. K. ... 631
Camperi, P. ... 500
Canilla, G. ... 372
Caralt ... 561
Cassimatis ... 297
Chaillous, F. ... 369
Chaillous, J. ... 485, 692
Chatterton, E. ... 692
Chauffard ... 47
Chevalier, G. ... 53, 556
Churchill, S. ... 296
Claiborne, J. H. ... 498
Clapp, C. A. ... 753
Clarke, E. ... 416, 500
Clausen, W. ... 758
Clausen 679
Clausnizer, Th. ... 52
Coats, George ... 496, 670, 708
Cohen, M. ... 541, 679
Collier, J. ... 553
Collins, E. T. ... 537, 550, 551, 743
Colombo, G. L. ... 415
Connor, F. P. ... 747
Coppez, H. ... 247, 446, 604, 605
Coppez, V. M. Jean ... 109
Cords, R. ... 545
Coronat 364
Coulomb, R. ... 692
Craggs, H. C. ... 350
Cramer, E. ... 606
Cridland, B. ... 64, 727
Critchett, Sir Anderson ... 503
Critchley, H. G. ... 697
Cross, F. R. ... 413, 518
Cunningham, H. H. B. ... 34

Dalmer 422
Danis, M. ... 357. 541, 624
Danis, R. ... 624
Darling, C. G. ... 605
Darier, A. ... 296, 498, 692
Darrieux... ... 48
Davids, H. ... 635
Davis, A. E. ... 619
Dawnay, A. H. P. ... 384
Del Monte, A. ... 353
Delord 34, 662
de Saint Martin, R. ... 605
de Schweinitz, G. E. ... 114, 176, 625, 698, 743
Desvaux, E. ... 561
Deutschmann, F. ... 108, 654
Deutschmann, R. ... 103
Devaux, E. ... 442
Digby, K. H. ... 560
Dodd, O. ... 753
Domann, P. ... 684

PAGE

Domec, Th. 93
[illegible], L. 251, 365, 443, 485, 562, 626
[illegible], H. 679
Durell, E. A. 736
Dowling, J. I. 632
Doyne, R. W. 508, 553
Drake-Brockman, E. F. 351
[illegible] 604
[illegible], A. 474
[illegible] 636
[illegible] 614
[illegible], R. 741
Dupont 34
Dupuy Dutemps 434, 484, 605, 627
Duran, C. 117
Durand 612
Dutoit, A. 182, 313, 498, 606, 693
Duverger 759
Dwyer, J. G. 758

Eales, H. 196
Eason, H. L. 552
Edridge-Green, F. W. 58, 425, 560
Elliot, R. H. 15, 59, 145, 259, 264, 296, 324, 378, 523, 580
Elschnig, A. 684, 747
Eppenstein, A. 617
Ettles, Wm. 372
Ewing, A. E. 32, 112

Fau 303
Ferentinos, Sp. 747
Fergus, A. F. 297
Fehr 634
Fleischer, B. 105, 354
Foster, J. 296
Foster, M. L. 378
Fox, L. W. 247, 443
Franco 178
Frank 498
Frankal, H. 605
Franke 684
Frankenstein, J. 498
Franz, V. 601
Frenkel, H. 421, 555
Frescoin, L. D. 252
Fromaget, H. 313, 679, 753
Fricker, E. 242
Friedenwald, P. 435
Fritzberg, W. 474
Fujita, H. 474

Gabriélidès 605, 628, 632
Galezowski, J. 753
Gallenga... 357
Galloway, A. R. 234
Gamble, W. E. 673
Gebb 434, 440
Geerts, J. 357
Gilbert, W. 242, 365
Ginsberg, S. 758
Giri, D. V. 202, 390
Gonin 618, 620
Gonzalez 178
Gonzalez, José de Jesus 255
Gradle, H. S. 244
Grandclément 693
Granert 370
Greeff 92, 170, 229, 288, 699, 737
Green, John, Jr. 742
Greene, A. 733
Greeves, R. A. 431, 549
Grignols, F. 480

PAGE

Grimsdale, H. 161
Groes-Petersen 33
Grönholm, W. 244
Gross, J. H. 105
Gross, J. 679
Grosz, Emil v. 206, 517, 576
Grout, G. H. 501
Gruening, E. 180, 247
Grunert 604
Grüter, von 613
Guibert 684
Guillery 684
Gunnufsen, Ths. 244
Guzmann, E. 435

Hamburger, ... 758
Hanke, V. 474
Harman, N. Bishop 17, 24, 74, 285, 335, 422, 432, 552. 667
Harris, C. M. 182
Harry, P. A. 371
Handmann, M. 756
Hawthorne, C. O. 122, 513
Hay, P. J. 663, 697
Heerfordt, C. F. 367
Hegner, C. A. 743
Heller, S. 176
Henderson, F. L. 443
Hepburn, M. L. 118
Herbert, H. 398
Herff, Otto v. 371
Hertel, E. 734
Hess, C. 614
Hessberg, R. 442
Hesse, R. 737
Higgens, C. 48
Hilbert, R. 425, 676
Hill, Emory 553
Hime, Major H. G. R. 247
Hinshelwood, J. 546, 605
Hirschberg, J. 198, 253, 431
Hoeve, J. Van der 105
Hoffmann, R. 357
Hoffmann, T. 605
Holden, W. A. 443
Holloway, T. B. 560, 625
Holmes, Gordon 552, 741
Holth, S. 429
Hoor, Karl v. 622
Hoppe, J. 50
Horniker, E. 676
Hosford, J. Stroud 49
Howitz, I. 313
Hudson, A. C. 234, 551, 556
Hurry, J. B. 260
Hutchinson, Sir Jonathan 503
Hyde, G. P. 700

Ichikawa, K. 743
Igersheimer, Jos. 365, 435, 443, 718
Isabolinsky 492
Ischreyt, G. 475
Ishihara, S. 679, 743

Jackson, E. 567, 747
Jacqueau 48
Jakobs, M. W. 234
James, G. B. 247
Janson, E. 692
Jaspers, I. 756
Jeillais 357
Jensen, E. 33
Jocqs, R. 296, 313, 485, 677

PAGE

Johnson, G. L. ... 539
Jones, E. L. ... 372
Juler, F. A. ... 384, 456
Junins ... 50, 492

Kalt ... 627
Kambe, Toshiro ... 614
Kapuscinski, W. ... 30
Kaufmann, M. ... 758
Killick, Charles... 11
Klinedinst, J. F. ... 605
Knapps, G. H. ... 605
Köllner ... 425
Komoto, J. ... 109
Koster, Gzn. W. ... 632
Krailsheimer, R. ... 743
Krusins ... 679
Kuffler, O. ... 479
Kümmell, R. ... 108, 178

Lacompte, F. ... 753
Lagrange, F. ... 247, 555, 561, 572
Lamb, R. S. ... 401
Lang, B. T. ... 416
Lang, Wm. ... 416
Langenbeck, R. ... 105
Lawford, J. B. ... 416, 552, 632
Laws, W. G. ... 432
Lawson, A. ... 562
Lazareff ... 234
Lee, C. G. ... 382, 450
Lehle, A. ... 371
Leishmann, Lieut.-Col. W. B. ... 442
Lemoine, P. ... 297, 545
Lenz ... 426
Le Roux, H. ... 625
Le Roy, B. ... 372
Levinsohn ... 54
Lindahl, C. ... 34
Llewellyn, T. L. ... 263
Lloyd, J. H. ... 114
Lloyd-Owen, D. C. ... 321
Löhlein, W. ... 234, 368
Lohmann, W. ... 632
Löwenstein, A. ... 353
Luedde, W. H.... 118, 244, 753
Lutembacher ... 605

MacCallan, A. F. ... 538, 764
McHardy, M. M. ... 195, 321
Mackay, G. ... 176, 297, 322, 561
McKee, H. ... 75, 159, 408
Mackenzie, J. Ross ... 175
MacNab, A. ... 372
McReynolds, J. O. ... 684
Maddox, E. E ... 287, 747
Maklakoff, Prof. ... 247
Maklakow, A. ... 247
Maklakow, W. ... 484
Magitot, A. ... 309, 601
Manolesco, D. N. ... 692
Marlow, F. W.... 606
Marmoiton ... 357
Marple, W. B. ... 382, 663
Marshall, C. D. ... 123, 259
Mattice, A. F. ... 682
Mawas, J ... 47, 491, 601, 614
Max, W.... 357
May, C. H. ... 182
Mayou, S. ... 258, 317
Meding, C. B. ... 747
Meller, J. ... 315
Menacho ... 756

PAGE

Metafune ... 682
Meyerhof ... 308
Morax, V. ... 303, 485, 700
Moreau ... 747
Moret, E. T. ... 382
Mould, G. T. ... 76
Mouradian ... 541
Moxon, F. ... 759
Muhsam ... 634
Muncaster, S. B. ... 440
Münch, K. ... 253
Mylius, W. ... 753

Nesfield, V. B. ... 556
Nettleship, E. ... 567, 764, 767
Neves da Rocha ... 440
Noceti ... 605
Norman, A. B. ... 692
Nuel ... 47
Nutting, P. G. ... 315

Oatman ... 357
Ochsner, A. J. ... 440
Ogawa, K. ... 235
Ohm ... 127
Oliver, G, H. ... 407, 716, 737
Oloff, Fleet-Surgeon ... 79
Oloff, H. ... 357
Onfray ... 371
Opin ... 435
Ormond, A. W. ... 496, 605, 606, 679
Ostwalt, F. ... 296

Paparcone, Ernesto ... 32
Parisotti ... 303
Parker, F. J. ... 105
Parson, H. ... 552
Parsons, J. H. ... 556, 566
Paton, L. ... 247, 562
Pearson, Karl ... 764
Pechdo ... 684
Péchin ... 255, 606
Peel, T. A. ... 471
Percival, A. S. ... 219, 314
Peretz ... 632
Peter, L. C. ... 435
Peters, A. ... 377, 684
Pfalz, G.... 678
Phelps, E. ... 737
Pickler, A. ... 234, 756
Pokrowski ... 297
Posey, W. C. ... 466
Poynton, F. J. ... 552
Precerutti ... 498
Purtscher, V. ... 621
Puscarin, Elena ... 488

Rados, A. ... 435, 614
Reeve, R. A. ... 484, 513
Reid, J. ... 296
Reis, W. ... 51, 108
Revel ... 34, 622
Ridley, N. C. ... 650
Risley, S. D. ... 415, 552
Ritchie, L. C. Peel ... 561
Rochon-Duvigneaud ... 39, 54, 371, 614
Roemer, P. ... 378
Rohmer ... 562
Rollet, E. ... 482, 487, 612
Rönne, H. ... 25, 605
Rosenhauch ... 120
Rowan, J. ... 632
Rübel, E. ... 105

PAGE
Rubert, J. 619
Rueben 367
Rutherford, L. T. 432
Rutson, J. R. 553

Sachs, E. 240
Salus, R. 235, 549
Salzmann 358
Santer, A. C. 677
Santos-Fernandez, J. 182, 255
Sattler, C. H. 105, 253, 371, 556, 747
Sava-Goin 678
Savage, G. C. 440
Schieck 613
Schnaudigel, O. 247, 365, 371
Schneider, R. 372
Schrimer, O. 105
Semple, N. M. 358
Shaw, Cecil 383
Shoemaker, J. F. 415, 490
Shumway, E. A. 743
Sidler-Huguenin 252
Siegrist 370
Smith, D. P. 247
Smith, E. T. 570
Smith, F. F. S. 747
Smith, Henry 556, 747
Smith, Homer 747
Smith, Priestley 297
Snyder, W. H. 491
Sobhy, M. 156
Spassky 492
Spellissy, J. M. 114
Spencer, F. R. 443
Stähli, J. 734
Stargardt, K. 79, 614, 756
Starr, M. Allen... 31
Steiger, A. 765
Steiger, O. 490
Steiner, L. 35
Steinhaus, J. 235
Stephenson, Sydney 113, 411, 422, 520, 640, 758
Stevenson, Edgar 23, 73, 562
Stewart, T. G. 552, 553
Stilling, J. 474
Stirling, A. W.... 660
Stock, Professor 92, 170, 229, 288, 291, 365, 443, 699
Stoewer, P. 605, 684
Stoll, K. L. 443
Strebel, J. 490
Stuelp, O. 415
Sumner, F. W.... 747
Swanzy, Sir H. R. 320, 383, 451
Sweet, W. M. 315
Sym, W. G. 568
Szily, Aurel v. 480

Taft, W. H. 176
Takayasu, M. 235
Taylor, C. G. 350
Taylor, H. H. 669
Taylor, J. 670, 741
Taylor, Seymour 696
Terrien, F. 47
Terson, A. 46, 440
Teulières 429
Thies, O. 435
Thompson, C. J. S. 701
Thompson, Theodore 552
Thomson, A. 125
Thomson, Ernest 19, 136, 372, 424

PAGE
Tirumurti, T. S. 268
Toczyski, F. 244
Tooke, F. 234, 251, 297
Torok, E. 501
Trantas 753
Truc 435
Tschirkowsky, W. 371
Turner, J. 108
Turney, H. G. 552

Uhlenhuth, E. 474
Uhthoff, W. 357
Urao Arisawa 479
Usher, C. H. 764

Vail, D. T. 432, 624
Valois, G. 297, 545
Van der Hoeve, J. 105
Van Lint, A. 235
Vassilopulos, V. 354
Vaughan, H. 619
Velter, E. 97, 114
Verhoeff, F. H.... ... ... 2, 220, 548
Verry-Westphal, A. 759
Villard 34, 38, 415, 605
Villardo, A. de L. 34
Velhagen, C. 614
Vinsonneau 545
Vital-Bérard 555
Vogt, A. 734
von Hippel, E. 415, 716
von Mende, R. 247
Vossius, A. 260

Walker, H. 699
Wallis, G. F. C. 342, 588, 594
Warlomont 550
Watzold 605
Webster-Fox, L. 502
Weekers... 109
Weil 303
Weill, G. 556
Weiner, A. 34
Werncke, Th. 440
Werner, L. 37, 670
Wessely, K. 367, 371
Westhoff, C. H. A. 382
Weve, H. 474
White, W. Hale 606
Whitham, L. B. 53, 71
Whitnall, S. E. 216, 601
Wicherkiewicz, B. 48, 247, 498, 753
Widal 303
Wilcox, W. H. 553
Williams, E. Cecil 553
Wilson, J. A. 756
Wilson, S. A. K. 552
Wintersteiner, Professor 92, 170, 229, 288, 699
Wirtz, R. 740
Wölffin, E. 562
Wood, Casey A. 698
Wood, C. G. Russ 221, 347, 530
Woodruff, T. 176
Würdemann, H. V. 442
Wydler, V. 734

Yeld, R. A. 630

Zeeman, W. P. C. 103
Zentmayer, W.... 103
Zirm 108
Zorab, A. 211, 317, 406

SUBJECTS.

Entries printed in thick type indicate grouped or special abstracts.

PAGE

Absorption of Cataract... 32
Accessory sinuses of the nose, enlargement of the blind spot in diseases of the ... 105
Accidents which have occurred through colour-blindness 560
Accommodation, apparatus of, in reptiles ... 474
——— influence of cocaine and homatropine upon ... 313
——— persistent paralysis of, after diphtheria 357
Acne rosacea 560
———and keratitis 561
———ocular manifestations associated with 560
Acromegaly, case of 553
———bitemporal hemianopsia with ... 552
———case of, with signs of regression 552
———disease of the pituitary body, without 37
———early, pituitary tumour with ... 552
Adenoma of the Meibomian glands 632
Admiralty test for colour blindness 560
Adrenaline, mydriasis due to 255
Ætiology of Diseases of the Eye ... 673
———**of Iritis** 630
After-Cataract, method of operating upon ... 600
Airol, insufflation of, bismuth excretion upon the cornea, after 498
Albuminuric retinitis, ... 39, 303
——— ætiology of ... 323
——— and retention of nitrogenous substances in the blood 303
——— lipoids and white plaques in ... 614
Alimentary toxæmia, its sources, consequences, and treatment 416
Amaurotic idiocy, or Tay-Sachs' disease ... 108
Amblyopia, hysterical, diagnostic value of the form and colour fields in 105
Amblyopia, hysterical, of dental origin ... 626
Amphibians and reptiles, rudimentary visual organs of 474
Amphibian eye, transplanted, influence of the host on the... 474
Amyloid degeneration of the conjunctiva ... 743
Amæmic fundus 358
Anæmia, post-hæmorrhagic, blindness which follows 357
——— severe, spontaneous conjunctivo-palpebral ecchymosis in 606
Anæsthesia, general 482
——— local 624
——— regional, eye operations practised under 624
——— surgical, in the lacrymal gland 482
Anaphylaxis in eye work. 480
Anatomical study on infantile glaucoma ... 305
Anatomy and Physiology 601
Aneurism of the aorta and tabes 605
——— of the central retinal artery in the course of pregnancy 357
Angiopathia in retinæ traumatica 621
Angiosarcoma of the iris and ciliary bodies... 353
Anophthalmic, an eyebath for the 692

PAGE

Anophthalmus with palpebral cysts 234
Anterior chamber, restoration of, after Elliot's operation 594
——— segment of the eye, nerves of the, senile changes in the 228
Anti-diphtheric serum, influence of on infective diseases of the eye 692
Anti-glaucomatous sclerectomy ... 627
Antiseptic measures in ophthalmic surgery ... 372
Aortic aneurism, ocular complications in ... 605
Appointments 59, 130, 197, 384, 451, 570, 702
"Aqueoplasty" 211
Aqueous humour, acute intoxications due to methyl alcohol 480
——— intra-ocular coagulation of the 424
Arc light, unilateral optic atrophy after exposure to 678
Arcus juvenilis and arcus senilis 547
——— senilis and arcus juvenilis 547
Argyrosis 112
——— of the conjunctiva 112
Arsenic and thyroid, and its associated internal secretions in diseases of the eye 440
Arsenobenzol, cranial polyneuritis after treatment by 255
——— eye complications following the use of 182
——— paraplegia follows injection of 255
Arteries, posterior ciliary, infarction of the... 708
Arterio-sclerosis of the retinal vessels ... 357
Ascarides, conjunctivitis due to 678
Aseptic, antiseptic and prophylactic measures in ophthalmic surgery 372
Asthenopia and conjunctivitis, ætiology of ... 415
"Atrophic myotonia" cataract in and with... 605
Atropine, action of, in diffuse parenchymatous inflammation of the cornea ... 498
——— and duboisine in the treatment of eye diseases in children 182
——— tablets for the determination of refraction in children 759
Atrophy of the iris and epibulbar carcinoma associated with xeroderma pigmentosum 357
——— of the optic nerve 25
Autocytotoxic theory of senile cataract ... 234
Auto-intoxication, gastro-intestinal, a cause of eye trouble 415
Autoserotherapy and subconjunctival injections 498
——— in ophthalmology ... 562
Bacteria of the eye 291
Bacteriology 682
———of conjunctivitis, value of the "direct smear" in the 234
Belgium Ophthalmological Society 386
Bilateral papillœdema with central scotoma, from sinusitis 105
Bio-chemical reaction of the lens 51
Biology of light 734
Bismuth excretion upon the cornea after insufflation of airol 498
Bjerrum method of investigating the field of vision in glaucoma 105
Blennorrhœa, congenital, of the lacrymal sac 296

PAGE

Blennorrhœa inclusion, clinical, experimental and microscopic studies of ... 492
——— of the lacrymal sac 296
Blepharo-conjunctivitis and perléche, relationship between 679
Blind, industrial education of the 176
——— spot, enlargement of the, in disease of the posterior accessory sinuses of the nose 105
——— spot, size of, in the emmetropic eye... 105
Blindness 176
——— among Egyptian children in Cairo, causes and frequency of 632
——— caused by the eclipse 545
——— causes and prevention of ... 176
——— eclipse 482
——— in children, causes of 176
——— prevention of 176
——— which follows acute post-hæmorrhagic anemia 357
——— word 546
Blood examinations in glaucoma patients ... 368
Board of Trade, sight tests of the 319
Booth, "General," the case of 48
Bowman lecture, 1914 571
Bradycardia after grave ocular trauma ... 357
Brawny scleritis 2
British Medical Association, Brighton meeting 322
Budapest Eye Hospital, method of cataract extraction practised there ... 576
——— No. 1 Royal Hungarian University, Eye Hospital in 206
Bulbar conjunctiva, cavernous lymphangioma of the ... 34
——— epithelioma of the ... 34
Buphthalmos 364
———pathology and treatment of 242
———with full vision and without cupping of the optic disc 550
———**with good sight** ... 550
———unilateral case in which a positive Wassermann reaction was obtained 364

Calcareous conjunctivitis, chronic 679
——— degeneration of the cornea and lens capsule 234
Canada, present position of ophthalmology in 513
Canthus, inner, gummatous inflammation of the 753
Capillary angiomatosis of the retina 421
Capsulotomy, preliminary, especially in immature cataracts 747
Carcinoma, epibulbar 743
——— of the eye, contact infection of... 202
Cardiovascular disease, ocular affections associated with 415
Caruncle, tumours of the 35
Caruncula lacrymalis, pathological anatomy of the 614
Catarrh, vernal, pathology of 614
Cataract 555
——— **absorption of** 32
——— after, method of operating upon... 600
——— and heterochromia, relation which exists between 601
——— causation of 601
——— dacryocystitis and epithelioma of the cheek on the same side in a woman 555
——— diabetic 555
——— double, the case of General Booth 48
——— extraction 503, 569

PAGE

Cataract extraction, a year's record of ... 11
——— expulsive hæmorrhage after 614
——— followed by sympathetic disease treated with tuberculin 108
——— management of the capsule in, and afterwards 747
——— of, by rupturing the capsule 351
——— ——— of in its capsule ... 556
——— operation 555
——— relative value of recent improvements ... 556
——— sympathetic irido-cyclitis following 684
——— with peripheral iridectomy 556
——— dangerous, safety device for 747
——— in and with "atrophic myotonia" 605
——— in the capsule, new operation for... 49
——— intra-capsular extraction of, details of vision in 132 cases ... 556, 747
——— intra-capsular operation for ... 747
——— lamellar, and tetany 737
——— method of extraction practised at the University Eye Hospital, Budapest 576
——— operating for, methods of avoiding prolapse of the vitreous in ... 747
——— operations 747
——— operations, control of the eye in ... 747
——— senile, autocytotoxic theory of ... 234
——— microscopic findings in a fatal case of... 235
——— operation for with the keratome 556
——— simple flap extraction of ... 747
——— treatment of early stages of 371
——— spontaneous absorption of... ... 32
——— unilateral, treatment of 556
——— with its capsule, extraction of ... 747
Cataractous lens, intracapsular extraction of 747
Cataracts due to electric discharge 677
——— immature, preliminary capsulotomy in 747
——— nuclear, use of euphthalmine in ... 440
——— senile, determination of ripeness of, by bio-chemical reaction of the lens 51
——— slow-growing, operative treatment of 556
Catheterism of the lacrymal passages ... 297
Cauterisation, superficial, of granulations ... 371
Cavernous degeneration of the optic nerve ... 235
Cell bodies in trachoma 492
Central London Ophthalmic Hospital ... 572
Cerebellar ataxia, with symptoms of hypophyseal lesion 553
Cerebral decompression 114
———in which cerebral hernia resulted with marked improvement in optic neuritis 114
———relation of, to the relief of the ocular manifestations of intracranial tension 114

PAGE

Cerebral localisation of some visual phenomena 741
Chancre, conjunctival 753
Chlamydozoa of Prowazek and Halberstädter, diagnostic value of, in trachoma ... 492
Choked disc, diagnostic value of in intracranial diseases 357
Choroid, flat sarcoma of the 614
——— inflammatory and vascular diseases of the 118
——— microscopic examination of the ... 171
——— rupture of, and high myopia ... 736
——— sarcoma of the 742
Choroidal tubercle, glaucomatous form of ... 434
——— tumour, microscopical examination of the eye in 742
Choroiditis 719
——— (Doyne's) pathological report on on a case of 537
——— "Honeycomb" or "Family"... 537
Chromatopsias, the true 676
Ciliary body and iris, angiosarcoma of the ... 353
——— senile changes in the 225
——— portion of the retina, structure of the 601
Circulatory Phenomena of the eye ... 118
Cocaine and homatropine, influence of upon accommodation 313
——— as a local anæsthesia 313
Coloboma, congenital, of both upper lids ... 473
——— of the lens 156
Colorado, University of, course in ophthalmology 60, 443, 703
Colour-blindness 560
——— accidents which have occurred through ... 560
——— the Admiralty test for... 560
——— discrimination of 425
——— fields in hysterical amblyopia ... 105
——— sensations, complete system of ... 425
——— sense 425
——— and peripheral visual acuity, relationship between ... 25
——— centre 426
——— method of examining the ... 258
——— on the significance of the method of examining the ... 79
——— testing the 676
Colour Vision 676
———tests... 571
———and colour - blindness, Hunterian lectures on ... 425
———and Daltonism 676
———normal, and colour weakness, demarcation between 425
Coloured wool for the investigation of Daltonism 676
Comparative Anatomy and Physiology of the Eye ... 474
———morphology of the eye in the duck family... ... 475
Cornea and lens capsule, calcareous degeneration of the 234
——— bismuth excretion upon the, after insufflation of airol 498
——— diffuse parenchymatous inflammation of the, action of atropine in ... 498
——— dystrophia epithelialis (Fuchs) ... 50
——— epithelioma of the 34
——— formation of "Drusen" at the surface of the 353
——— inflammation of the 97
——— in the rabbit, pneumococcal infections of the, treated by alkaloids 758

PAGE

Cornea, layers of the 92
——— lipoid granules in the fixed cells of the 614
——— nodular opacities of the 488
——— oval, and the blue sclerotic in hereditary syphilis 617
——— papilloma of the, cured by mesothorium 692
——— pathology of rodent ulcer of the ... 743
——— primary fatty degeneration of the ... 235
——— senile changes in the 222
——— tumours of the 34
——— vaccine treatment of infections of the 471
——— vertically-oval form of 617
Corneal cells and lacunæ 94
——— corpuscles, fixed 94
——— cyst, traumatic multilocular implantation 268
——— epithelium 93
——— ——— of a glaucomatous eye ... 614
——— fibrillæ 94
——— nerves 96
——— ulcer, iodine in 372
Correspondence ... 57, 191, 258, 317, 381, 502, 569, 695
Concretions in the optic nerve 390
——— of the lacrymal canaliculi ... 354
Congenital anterior staphyloma 551
——— coloboma of both upper lids ... 473
——— elephantiasis and infantile glaucoma 364
——— syphilitic diseases of the eye ... 753
Conical cornea 370
Conjunctiva and sclera, tuberculosis of the ... 435
——— amyloid degeneration of the ... 743
——— argyrosis of the 112
——— bulbar, cavernous lymphangioma of the 34
——— epithelioma of the ... 34
——— tuberculosis of the ... 435
——— tuberculosis of the, cured by the serum of Marmoreck 313
——— **inflammations of the** ... 678
——— lipoma of the 34
——— papilloma of the, cured by mesothorium 692
——— pemphigus of the 679
——— pneumococci on the, after extirpation of the lacrymal sac ... 682
——— staphylococcal infection of the, a rare form of 679
——— traumatic cysts of the 34
——— tumours of the 34
——— vernal 679
Conjunctival xerosis, hemeralopia and ... 746
———affections associated with so-called trachoma bodies ... 679
———chancre 750
Conjunctivitis 718
——— and asthenopia, ætiology of ... 415
——— bacteriology of, the value of the "direct smear" in the 234
——— chronic calcareous 679
——— croupous 622
——— diphtheritic 622
——— diplobacillary, vaccine and serum therapy in 371
——— diplobacillary, notes on an epidemic of 678
——— due to ascarides 679
——— gonococcal, epidemic in Egypt and its relation with trachoma 308

PAGE

Conjunctivitis, gonorrhœal, of the new born, involvement of the middle ear in 422
——— membranous 662
——— meningococcus 75
——— Parinaud's 120, 548
——— etiology of ... 679
——— polycystular 619
——— pseudo-membranous, cured by serum 53
——— subacute, diplobacillus of, action of sulphate of zinc on 759
——— traumatic 678
Conjunctivo-palpebral ecchymosis, spontaneous, in severe anæmia 606
Conservation of vision... 704
Convergence, latent, or divergence ? ... 660
Cranial polyneuritis, especially oculo-motor, after treatment by arsenobenzol ... 255
Croupous conjunctivitis 622
Crystalline lens, fluorescence of the... ... 544
Cyclic affections of the third nerve 549
Cycloplegics with hyoscine, use of, in refraction 182
Cyst formation of the retina 614
Cystotome, a new cutting 413
Cysts and holes in the fovea centralis ... 103
——— traumatic, of the conjunctiva 34
Dacryocystitis, purulent, bilateral congenital 297
——— double congenital 297
Daltonism, colour vision and 676
Dazzling, after images due to, and other relationship to dazzling erythropsia ... 734
Deafness in sympathetic ophthalmia... ... 109
Decompression craniectomy in the papilloedema of the syndrome of intracranial hypertension 114
Dermo-Epithelioma, Parinaud's 369
Dermoid of the eye 743
Detachment of the Retina 431
Development, precocious, in a boy aged eight 552
Diabetes insipidus in neuritis and iridocyclitis 605
——— retinal lipæmia in 605
Diabetic cataract 555
Diathermy influence of, on the intraocular pressure 52
——— ocular, researches on 371
Dietetic poisoning, visual trouble caused by 357
Diplobacillary conjunctivitis, action of salts of zinc in... ... 759
——— notes on an epidemic of ... 678
——— vaccine and serum therapy in 371
——— infection of the eye, therapy of 440
Diplococcus lanceolatus, septic endophthalmitis associated with the 411
Diploma in ophthalmology of the University of Liverpool 132
Diphtheria, persistent paralysis of accommodation follows 357
Diphtheritic conjunctivitis 622
Director-forceps for use in partial tenotomy 24
Disc, glaucomatous excavation of the, and optic neuritis 354
"Drusen", formation of, at the surface of the cornea 353
Duboisine and atropine in the treatment of eye diseases in children 182
Duck family, comparative morphology of the eye in the 475

PAGE

Dystrophia marginalis corneæ ... 50
Ecchymosis, spontaneous conjunctivo-palpebral, in severe anæmia 606
Eclipse blindness 482, 545
Ectopia lentis, keratoconus and 490
Ectropion of the lower lids, an operation for 538
Egyptian children in Cairo, causes and frequency of blindness among 632
——— ophthalmia 308
Electric colloidal mercury in ocular therapeutics 498
———discharge, cataracts due to 677
——— injuries of the eye 677
———motor, a trephine worked by ... 669
———ophthalmoscope 663
Electricity in ophthalmic practice 692
Elephantiasis, congenital, and infantile glaucoma 364
Elliot's sclero-corneal trephining, some causes of the failure after 640
Embolic metastases in the eye, pathologicaal anatomy of 743
Emmetropic eye, size of the blind spot in the 105
Endophthalmitis, septic, associated with the diplococcus lanceolatus 411
Enophthalmos, traumatic, autopsy upon a case of 234
Enucleation in cases of panophthalmitis 48
——— of the eye for post-traumatic phlegmon, intense meningitis after 48
——— of the eye under local anæthesia 624
Epibulbar carcinoma 743
——— epithelioma, cure of, by the use of X-rays and radium 693
——— tuberculosis 435
Epileptic fits induced by the use of eserin sulphate 21
Epithelioma of the bulbar conjunctiva ... 34
——— of the cornea 34
Erythæmia, ophthalmoscopic signs of ... 605
Erythropsia, dazzling 734
Eserine solutions, prevention of red colouration in 562
——— sulphate, epileptic fits induced by the use of 21
Essen-Rhin, eye clinic at the Municipal Hospital at 442
Etherisation in eye surgery, new apparatus for 248
Euphthalmine, use of, in nuclear cataracts ... 440
Exophthalmic goitre, acute purulent keratitis in, treated by tarsorrhaphy... 456
———treatment of ... 440
Exophthalmos, unilateral, diagnostic value of in intracranial diseases ... 357
———in optic atrophy 612
———leontiasis faciei and, ... 604
———of Graves' disease and the nose 357
Eye, affections of the, Wassermann's reaction in 541
——cliniques, British and Continental ; Some comparisons and contrasts 136
——disease, septic infection in the causation of 416
——disease, toxæmia (alimentary and oral) as a cause of 415
——diseases, gonorrhœal affections in ... 64
——diseases of the, indicanuria in 415
———procrastination in ... 443

PAGE

Eye, human, case which demonstrates the hardihood of the 443
——human, senile changes found in, the ... 222
——lesions in insular sclerosis 97
——**light and the** 734
——microscopic examination of the 92, 170, 229, 288
——movements of labyrinthine origin ... 28
——work, anaphylaxis in 480
Eye bath for the anophthalmic 692
Eye-glasses, oldest preserved 737
Eyelid retractor, a new 221
——— tuberculosis of the 435
Eyelids, xanthelasma of the 235
Eyes, diseases of the, bodily temperature in 443
Fæces and urine, importance of examining the, in eye diseases 692
Fermentations on the eye and their relation to sympathetic ophthalmia 684
Fever, African recurrent, ocular complication of 604
Field of vision 105
Fishes, the light sense of 474
Fistula of the lacrymal sac 296
Fluoresence of the crystalline lens 544
Forceps, tarsal cyst 733
Foreign bodies, intra-ocular, sympathetic ophthalmia and 684
——— body in the orbit 159
———————removed from orbit of boy, wound of optic nerve ... 23
Fovea centralis, holes and cysts in the ... 103
Fracture of the skull and lesions following of the optic canal... 625
French Ophthalmological Society 452
Fundus, anæmic 358
———changes in myopia, scheme for the exact record of 335
———lymphorrhagia of the 621
———tuberculosis of the 434
Gastro-enteritis in infants, irido-choroiditis following 415
Gastro-intestinal auto-intoxication a cause of eye trouble 415
Glaucoma, acute, excited by homatropin ... 73
——— Bjerrum method of investigating the field of vision in ... 105
——— chronic, modification of Herbert's flap operation for 247
——— chronic, of 13 years' standing treated without operation ... 562
——— chronic, operation of combined iridectomy and sclerectomy for 247
——— clinical and pathological aspects of 251
——— Elliot's trephining for and its technique 588
——— field of vision in 105
——— infantile, anatomical study on ... 305
——— infantile, congenital elephantiasis and 364
——— internal medication with iodine in... 182
——— Mayou-Zorab method for operation 258
——— Mayou-Zorab operation for ... 317
——— miscellaneous communications on 251
——— new operative treatment of ... 539
——— notes on a case covering twenty years 75
——— operations, complications recently met in 398
——— **operations for** ... 58, 247, 259, 365
——— pathogenesis of 242
——— patients, blood examination in ... 368
——— results of Elliot's trephining for ... 365

PAGE

Glaucoma, secondary injury to the vitreous body as a cause of 234
——— so-called inflammatory valvular action of vorticose sinus scleral plate, as a cause of 367
——— **sundry communications on** 367
——— trephine, a modified 668
——— trephining in 523
——————— acute and chronic ... 580
——— unilateral, due to congenital malformations 251
Glaucomatous and normal eyes, investigation of, by Schiötz's tonometer ... 244
——————————— tension of, influence of accommodation and convergence upon the ... 244
——————— excavation of the disc and optic neuritis 354
——————————— Schnabel's vacuoles and their significance in the development of 354
——————— eye, corneal epithelium of a ... 614
——————— form of choroidal tubercle 434
Glass eye tube 498
Glasses, radio-active 498
Gonococcal conjunctivitis epidemic, in Egypt, and its relation with trachoma ... 308
Gonorrhœal conjunctivitis aborted by 2 per cent. solution of nitrate of silver... 498
——————————— of the new-born, involvement of the middle ear in 422
Gonorrhœal infection in eye diseases ... 64
——— inflammation, metastatic ... 252
——— iritis 631
Gram technique, a simplified... 491
Granulations, superficial cauterisation of ... 371
Graves' disease, exophthalmos of, and the nose 357
Groenouw's disease 488
Guaiacol diaphoresis in ophthalmology ... 347
Gumma of the eyelid 753
——— optic disc 750
Gummatous inflammation of the inner canthus 753
Haematoma of the orbit 180
Hæmorrhage, expulsive, after cataract extraction 614
Hæmorrhages, recurrent, into vitreous cured by thyroid extract 20
——— secondary, in the retina, in secondary anæmia 606
Headache, transient miosis associated with... 605
Hearing, disturbances of, sympathetic ophthalmia and 684
Heidelberg Congress 705
Hemeralopia and xerosis conjunctivæ 746
——— idiopathic, and xerosis conjunctivæ 746
Hemianopsia, bitemporal, ætiology of, with reference to diseases of the pituitary body 357
——— bitemporal, with acromegaly 553
——— bitemporal, with evidence of pituitary tumour 552
Hemianopia, permanent, following attacks of migraine 606
——— unilateral nasal, tabetic atrophy with 605
Hereditary transmission of retinitis pigmentosa in two generations 407

PAGE

Hereditary syphilis, parenchymatous keratitis after linear extraction of cataract ... 753
Herpes zoster, ionic medication in 372
Heterochromia and cataract, relation which exists between 601
Hexamethylenetetramine in the ocular humours, excretion of 53
Histogenesis theory of the vitreous... ... 601
Histological sections, a new method of bleaching 491
"Holes" at the macula 103
Homatropine and eserine, influence of upon accommodation 313
——— acute glaucoma excited by ... 73
Homonymous hemianopsia, incongruous ... 105
Hungary, present position of ophthalmology in 517
Hunterian Lectures on colour vision and colour-blindness 425
Hyaline bodies at the optic disc in a case of retinitis pigmentosa 716
Hyaline nodules in the optic disc in a case of retinitis pigmentosa 19
Hydatid cyst of the orbit 628
Hydrophthalmos, congenital, pathology and therapy of 242
——— with the preservation of good sight 550
Hyoscine, use of in refraction 182
Hyper-activity of anterior lobe combined with deficient action of posterior lobe ... 553
Hypophysis disease (from the ophthalmological standpoint) 553
Hypophyseal lesion, cerebellar ataxia with symptoms, of a 553
Hypopituitarism, dystrophia adiposa genitalis 553
Hysterical amblyopia, colour fields in ... 105
———of dental origin ... 626
Illuminating the field of operation, new method of 443
Immunity 479, 613
———in ophthalmology, researches upon 613
Indicanuria in diseases of the eye 415
Infarction of the posterior ciliary arteries ... 708
Infra-nuclear paralysis in abscesses and tumour of the temporal lobes 542
Infection, contact in carcinoma of the eye ... 202
Infective diseases of the eye, influence of anti-diphtheritic serum on 692
Inflammation, sympathetic, experimental ... 108
Inflammations of the conjunctiva ... 678
Inflammatory and vascular diseases of the choroid 118
Injuries in the eye caused by light 734
——— of the eye and sympathetic ophthalmia, relation of lymphocytosis to 684
——— syphilis and 178
Injuries to the eye by light 677
International Congress of Medicine (XVII) 61
——— of Ophthalmology (XII) 131
——— (XII) 572
Intestinal auto-intoxication in the pathogenesis of eczematous kerato-conjunctivitis 415
——— sepsis in ocular affections... ... 415
Interstitial keratitis 255
——— (congenital syphilitic) treated with Salvarsan) 342
——— influence of traumatism on the appearance of ... 178
——— injury in the genesis of ... 178

PAGE

Intracapsular extraction of cataract, details of vision of 132 cases 556, 747
———of the cataractous lens 747
Intracranial diseases, diagnostic value of unilateral choked disc and optic neuritis in 357
———disease, ocular phenonema in relation to 358
———surgery, importance of ocular symptoms in 240
Intra-ocular coagulation of the aqueous humour 424
———foreign bodies and sympathetic ophthalmia 684
———operations, dressings after ... 632
———pressure, influence of diathermy on the 52
———pressure, relations of kerato-conus to 490
———tension, raised and systematic blood tension, relation between 350
——— simple trephining for increase of 247
Iodine in corneal ulcer 372
——— internal medication with, in glaucoma 182
Ionic medication in herpes zoster 372
Iontophoresis, ocular researches on 371
Iridectomy and sclerectomy, combined operation of, for chronic glaucoma... 247
———peripheral, cataract extraction with 557
Irido-choroiditis following gastro-enteritis in infants 415
——— chronic, discussion on, ... 496
——— essential oils in the treatment of, 406
——— sympathetic, following cataract extraction, ... 684
——— unilateral (serous iritis) treated by subconjunctival injections of mercury cyanide 572
——— and neuritis, diabetes insipidus in 605
Iris and ciliary body, angiosarcoma of the ... 353
——— and choroid, microscopic examination of the 170
——— atrophy of the, and epibulbar carcinoma associated with xeroderma pigmentosum 357
——— fibrous tissue formation connected with fœtal vascular system, on the surface of the..... 743
——— human, pigmentation of the 234
——— leproma of, cured by radium therapy... 255
——— peripheric incision of the 747
——— posterior epithelium of the, in cataractous eyes 601
——— senile changes in the 224
Iritis, ætiology of 630
——— gonorrhœal 631
——— post-operative 580
——— serous 372
——— tubercular, double 692
Keratitis, acne rosacea and 561
——— acute purulent in exophthalmic goitre, treated by tarsorrhaphy ... 456
——— parenchymatosa 719
——— after injury ... 178
——— of traumatic origin, its medico-legal aspect 753
——— heredo-syphilitic, after linear extraction of cataract ... 753
——— reaper's 413

PAGE
Keratitis, suppurative, treatment of 561
Kerato-conjunctivitis, eczematous, intestinal auto-intoxication in the pathogenesis of 415
Keratoconus... 490
——— and ectopia lentis 490
——— and its relations to intra-ocular pressure 490
Keratomalacia 719
——— prognosis of 30
Keratome, operation for senile cataract with the 556
Labyrinthine origin, eye movements of ... 28
Lacrymal recess, formation of the 601
——— affections, ætiology of 414
——— ——— diagnosis and treatment of 758
——— apparatus, facts old and new about the 296
——— canaliculi, concretions of the ... 354
——— fistula, simulated by primary sporotrichosis of the eyelids ... 485
——— gland in surgical anasthesia ... 482
——— drainage apparatus, diseases of the 721
——— **passages** 296
——— catheterism of the ... 297
——— excretory disorders of the 296
——— obstruction of the ... 296
——— sac, blennorrhœa of the 296
——— congenital blennorrhæa of the 296
——— fistula of the 296
——— pneumocele of the 296
——— polypi, of the 297
——— polypoidal formation in the ... 297
——— treatment of the 296
——— tuberculosis of the 297
——— styles, the use of 297
——— suppurative disease, treatment of 297
——— therapeutics, practical results in ... 297
Lactation, optic neuritis during 38, 605
Lamellar cataract and tetany... 737
Latent convergence or divergence ? 660
Leipzig eye clinic, observations on sympathetic ophthalmia at the 684
Lens capsule and cornea, calcareous degeneration of the 234
——— growth of the 474
—— congenital coloboma of the 156
—— crystalline, fluorescence of the 544
—— extraction of in its capsule 747
—— microscopic examination of the ... 170
—— pathology of the 614
—— senile changes in the 226
—— spontaneous complete absorption of the 32
Leontiasis faciei and exophthalmos 604
Leproma of iris cured by radium therapy ... 255
Lesions of the oculo-motor paths 102
Leucocytes in the vitreous, extracellular action of the 235
Lids, upper, congenital coloboma of both ... 473
Light and the eye 734
Light, biology of 734
——— injuries in the eye, produced by ... 734
——— rays of, excitability of the retina caused by 734
Lighting, Committee on 451
Ligmentum palpebrarum mediale 216
Limbus, trephining at the 247
Lipoids and white plaques in albuminuric retinitis 614
Lipoid granules in the fixed cells of the cornea 614
Lipojodin in certain diseases of the optic nerve and in retina 693
Lipomata of the conjunctiva 34

PAGE
Lymph-canalicular system 95
Lymphangioma, cavernous, of the bulbar conjunctiva... 34
Lymphatic stasis and lymphorrhagia... ... 620
Lymphatics of the neck and throat, pathological conditions of the eye secondary to ... 357
Lymphyocytosis, relation of to injuries of the eye and to sympathetic ophthalmia... 684
Lymphorrhagia of the fundus oculi 620-621
Macula, holes at the 103
——— lutea, microscopic examination of the 233
Magdalena, basin of the, endemic ophthalmia of the 117
Malaria, optic neuritis due to... 605
Malformation of the cornea as a stigma of heredo-syphilis ... 617
Malingering, visual 442
Manchester University, proposed diploma in ophthalmology 388
Marmoreck, serum of, in the treatment of primary miliary tuberculosis of the bulbar conjunctiva 313
Maxillary antrum, relation of, to the naso-lacrymal canal 601
Measurement of ocular protrusions 612
Medico-legal aspect of keratitis parenchymatosa of traumatic origin 753
Meibomian glands, adenoma of the 632
Membranous conjunctivitis 622
Meningococcus conjunctivitis 75
Mercury cyanide, subconjunctival injections in irido-cyclitis (serous iritis) 372
Mesothorium in the treatment of papilloma of the cornea and conjunctiva 692
Metallurgy, modern, in ophthalmology ... 487
Metastatic gonorrhœal inflammation 252
Methods 491
Methyl alcohol, aqueous humour, acute intoxications due to 480
Microscopic examination of the eye, guide to 92, 170, 229, 288
Microscopical examination of the eye in choroidal tumour 742
Migraine, an optimistic view of 498
——— permanent hemianopia following attacks of 606
Miners', coal, nystagmus, visual fields in ... 727
——— nystagmus 57
———ætiology and treatment of 175
Minto Ophthalmic Hospital, Bangalore ... 386
Miosis, transient, associated with headache... 605
Miscellaneous communications 442
Morphology of the eye in the Urinatoridæ (Divers) 475
Motor phenomenon of the eye, a remarkable 632
Muscles, external, of the eye, senile changes in the 227
Myasthenia gravis 31
Mydriasis due to adrenaline 255
Myoclonus, ocular 424
Myopes, retinal, detachment in, cured by simple sclerectomy 429
Myopia 756
——— ætiology of 756
——— central green patch in 756
——— fundus changes in, scheme for the exact record of 335
——— high grade, and detached retina, new operative treatment of ... 429
——— high, rupture of the choroid and ... 756
——— in orbital new growths 756
Naso-lacrymal canal, relation of to the maxillary antrum 601

PAGE

National Physical Laboratory... 387
Negative afterimages with pure spectral colours 143
Neoplasms, retro-bulbar, rational surgery of 148
Neosalvarsan in the treatment of sympathetic ophthalmia 692
——— subconjunctival injections of... 692
Nerve-slight investigation of the eye with ... 734
Nervous symptoms associated with optic atrophy of the familial type ... 741
——— system, eye symptoms, and the early diagnosis of 605
Neuralgia, supra-orbital 632
Neuritis, acute retrobulbar caused by an intestinal toxæmia... 415
——— and iridocyclitis in diabetes insipidus 605
——— following treatment with Salvarsan 440
——— optic due to malaria 605
——— during lactation 38, 605
——— retrobulbar, with amaurosis ... 606
Neuro-retinitis, use of old tuberculin in the ætiology of 673
Neurosis, ocular, pseudo-sympathetic ... 109
Nitrate of silver in cases of gonorrhœal conjunctivitis 498
Nodular opacities of the cornea (Groenouw's disease) 488
Noguchi and the Wassermann reactions 541
Noguchi's cutaneous luetic reaction and its application in ophthalmology 541
Norfolk and Norwich Eye Infirmary... ... 573
Nose and the exophthalmos of Graves' disease 357
Notes and Echoes...59, 130, 195, 319, 382, 450, 503, 570, 701
Novelties 24, 160, 221, 287, 413, 540, 667, 730
Noviform ointment in external ocular therapeutics 758
Nystagmus, coal miners', visual fields in ... 727
——— without ophthalmoscopical abnormalities 721
Obituary...130, 195, 319, 382, 450, 503, 570, 701, 767
Ocular affections, cardiovascular disease associated with ... 415
——— ——— intestinal sepsis in ... 415
——— complications of African recurrent fever 604
——— of aortic aneurism ... 605
——— of the bony diseases of Paget 605
——— diathermy, experiments upon ... 371
——— humours, excretion of hexamethylenetetramine in the ... 53
——— excretion of salicylic acid in the 71
——— injuries, syphilis and 178
——— iontophoresis, researches in 371
——— manifestations associated with acne rosacea 560
——— of increased intracranial tension, relation of cerebral decompression to the relief of ... 114
——— of syphilis and parasyphilis of the nervous system ... 605
——— manifestations of tertiary syphilis in tabetics... 753
——— myoclonus 424
——— neurosis, psuedo-sympathetic ... 109
——— paralysis 606
——— pathology, rôle of syphilis in... ... 313

PAGE

Ocular phenomena in their relation to the diagnosis of intracranial disease ... 358
——— protrusions, measurement of... ... 612
——— sporotrichosis 485
——— symptoms in intracranial surgery ... 240
——— syphilis, researches upon 365
——— tension 367
——— increase of, caused by swelling of tissue colloid 367
——— therapeutics, electric colloidal mercury in 498
——— tissue, specific properties of 479
Ocular torticollis 113
——— trauma, bradycardia follows ... 357
——— tuberculosis, tuberculin and ...182, 561
Occupational diseases of the eye 443
Oculo-motor paths, lesions of the 102
Œdema of the eyelids, ætiology of acute recurrent 483
——— of the orbit, recurrent 484
Oils, essential, in the treatment of iridocyclitis 406
Operation, illuminating the field of 443
Operations, anti-glaucomatous 365
——— **cataract**... 747
——— for glaucoma ... 58, 191, 247, 365
——— intra-ocular, dressings after ... 632
——— new anti-glaucomatous 502
——— plastic 650
Ophthalmia Egyptian 308
——— endemic, of the basin of the Magdalena 117
——— **neonatorum** 59, 422
——— incidence of in London ... 422
——— in Hungary ... 386
——— notification of ... 385
——— prevention of ... 371
——— prophylaxis of... 371
——— the duty of the practitioner in cases of ... 422
——— **sympathetic** 684
——— sympathetic, deafness in ... 109
——— experiments on ... 108
——— in the Leipzig eye clinic 684
——— new observations on 109
——— pathogenesis of ... 108
Ophthalmic practice, electricity in 692
——— prize for 452
——— surgery, aseptic, antiseptic and prophylactic measures in ... 372
Ophthalmological Congresses of Oxford and Liverpool, 1912... ... 443
——— Society of the United Kingdom... ... ...134, 322
Ophthalmology and general medicine 357, 604, 670, 741
Ophthalmology at the University of Colorado: degree of doctor 443
——— autoserotherapy in 562
——— Wassermann's histopin ointment in 758
——— in Great Britain, present position of 518, 520
——— in India, post-graduate training in 453
——— modern metallurgy in ... 487
——— Noguchi's cutaneous luetic reaction in 541
——— present position of ... 508, 695

PAGE
Ophthalmology, present position of in Canada 513
——— present position of in Hungary 517
——— prize for 385
——— relation of to general medicine 513
——— researches upon immunity in 613
——— significance of scrofuloderma in 605
——— study of 453
——— value of the Wassermann reaction in 541
Ophthalmoplegia interna, ætiology of ... 604
Ophthalmoscope Diary 62, 134, 199, 266, 318, 388, 574, 663, 706, 770
Ophthalmoscopes, self-lit 317
——— self-lit, the use and management of... ... 145
Ophthalmoscopic, direct, examination with indirect vision and illumination 729
——— examination by direct method with indirect illumination 193
——— signs of erythæmia, "Vaquez's disease" 605
Optic atrophy, as a result of soamin poisoning 15
——— exophthalmos in 612
——— in tabes and general paralysis, pathological anatomy of ... 614
——— of the familial type, nervous symptoms associated with 741
——— tabetic, with unilateral hemianopsia 605
——— unilateral, after exposure to arc light 678
—— disc, gumma of the 753
——— hyaline bodies at the, in case of retinitis pigmentosa 19, 716
—— nerve, affections of the 720
——— and retina, ætiological role of tuberculosis in affections of the 498
——— atrophy of the 25
——— cavernous degeneration of the ... 235
——— concretions in the 390
——— lesions of the, following fracture of the optic canal 625
——— lipojodin in diseases of the ... 693
——— microscopic examination of the 288
——— sheaths, fracture of the skull with hæmorrhage into the ... 625
——— tabetic atrophy of the, forms of visual fields in... 105
—— neuritis and suppurative otitis 632
——— diagnostic value of in intracranial diseases 357
——— during lactation 38, 605
——— glaucomatous excavation of the disc, and 354
——— due to malaria 605
——— use of old tuberculin in the ætiology of 673
——— with retinitis and consecutive atrophy associated with pregnancy 597
—— papilla, partial rupture of the 618
Ora serrata, microscopic examination of the 233
Orbit, foreign body in the 159
—— idiopathic hæmatoma of the 180
—— recurrent œdema of the... 484
—— shape of the, its influence upon the eyeball (Stilling's theory) 601
—— spontaneous hæmatomata of the ... 180
—— syphilis of the 753

PAGE
Orbital affections, rôle of tuberculosis in ... 606
——— conditions, two unusual 466
——— new growths, myopia in 756
Orbito-temporal hydatid cysts 628
Otitis, suppurative, optic neuritis and ... 632
Ox, fluorescence of the lens of the 544
Oxford Diploma in Ophthalmology 571
——— Ophthalmological Congress ... 60, 134, 454
Paget, bony disease of, ocular complications of 605
Palpebral cysts, anophthalmus with 234
——— localisation, Recklinghausen's disease with 605
Panophthalmitis, enucleation in the treatment of 48
Papilla, solitary tubercle of the 234
Papillœdema, bilateral, with scotoma, from sinusitis 105
Papilloma of the cornea and conjunctiva, cured by mesothorium 692
Paralysis, general, optic atrophy in 614
——— infra-nuclear 542
——— ocular 606
——— of the third cranial nerve... ... 549
——— partial oculomotor, with contractions of muscles supplied by third cranial nerve 549
——— recurrent third nerve 605
Paraplegia following injection of arsenobenzol 255
Parasites in trachoma, formations taken for 492
Parinaud's conjunctivitis 120
——— a mycotic disease due to a filamentous organism 548
——— etiology of ... 679
——— dermo-epithelioma 369
Paris Hospitals 506
Pathogenesis of glaucoma 242
Pathological anatomy of embolic metastases in the eye ... 743
——— optic atrophy in tabes and general paralysis 614
——— the caruncula lacrymalis ... 614
——— and bacteriological memoranda 408, 537
——— conditions ef the eye, secondary to disease of the lymphatics of the neck and throat 357
——— report on retinitis pigmentosa ... 408
Pathology 234, 305, 353, 614, 742
——— and treatment of buphthalmos 242
——— of rodent ulcer of the cornea... 743
——— the lens 614
Pemphigus of the conjunctiva 679
Pericorneal syphilitic swelling 753
Perimeter, a hand 540
Periphlebitis retinalis adolescentium, tuberculosis in the, ætiology of 435
Periophthalmus kolreutheri, the light sense of 474
Perithelioma of the eyelids 401
Perléche and blepharo-conjunctivitis of diplobacillary origin, relationship between ... 679
Phorometer, a near vision 287
Physiology and anatomy 601
——— **of the eye ... ...** 474
Physostol, experience with 693
Phlegmon, post-traumatic enucleation of the eye for intense meningitis follows ... 48
Phlyctenular (eczematous) conjunctivitis, value of tuberculin in ... 619
——— inflammation of the eye ... 619
——— ætiology of 674
Phlyctenulosis 619

PAGE
Pigmentation of the human iris 234
Pituitary body and bitemporal hemianopsia 357
——— **disease of the** 552
——— without acromegaly 37
——— region, disease in the 552
——— tumour (Lorain type) 553
——— with early acromegaly ... 552
——— with symptoms of dystrophia adiposogenitalis 552
Plastic operations, some commonplaces with regard to 650
Pneumocele of the lacrymal sac 296
Pneumococcal infection of the eye, serum therapy of 372
——— infections of the cornea in the rabbit treated by alkaloids... 758
——— on the conjunctiva after extirpation of the lacrymal sac 682
Polypoidal formation in the lacrymal sac ... 297
Polypi of the lacrymal sac 297
Posterior ciliary arteries, infarction of the ... 708
Pons-cerebellar angle, tumour of the ... 357
—— tumours of the 605
Pregnancy, aneurism of the central retinal artery in the course of ... 357
——— optic neuritis and retinitis and consecutive atrophy, associated with 597
Pressure-massage, myotics, and myopia ... 53
Procrastination in diseases of the eye ... 443
Prophylactic measures for persons about to become blind... 176
——— measures in ophthalmic surgery 372
Prophylaxis of ophthalmia neonatorum ... 371
Prowazek bodies in the follicles and papillæ of trachoma 492
Pseudoglioma 719
Pseudo-membranous conjunctivitis cured by serum 53
Pseudoneuritis 530
Pseudo-sympathetic ocular neurosis 109
Ptosis: a general review 161
Pulsation in the retinal arteries ... 271, 338, 460
Pupillæ, sphincter, worm-like contractions of the 253
Purulent ophthalmia of the new-born ... 440
Radio-active glasses: their action on the eye and vision 498
Radium in the treatment of epibulbar epithelioma 693
——— therapy, in leproma of iris 255
——— treatment of spring catarrh ... 371
——— treatment of trachoma 182
Reaper's keratitis 413
Recklinghausen's disease with palpebral localisation... 605
Rectus tendon, lengthening of, in squint operations 17
Refraction and the use of cycloplegics, with hyoscine... 182
——— error of, correction of for microscopic work 442
——— in children, atropin for the determination of 759
Remedies 51, 182, 255, 313, 371, 440, 498, 561, 692, 758
Reptiles and amphibians, rudimentary visual organs of some 474
——— appartus of accommodation in ... 474
Retina, ætiological rôle of tuberculosis in affections of the 498
Retina, capillary angiomatosis of the ... 421
——— cyst formation of the... 614
——— detached and high-grade myopia, new operative treatment of 429
——— **detached, surgical treatment of** 429
——— treatment of 440
——— detachment of, a new theory in treatment of... 432
——— **detachment of the** 431
——— detachment of the, experimental and histological investigations upon ... 429
——— detachment, spontaneous cure of a...431, 432
——— excitability of the, by rays of light ... 734
——— lipojodin in certain diseases of the ... 693
——— microscopic examination of the ... 229
——— of the triton and frog, process of regeneration in the 474
——— pigment epithelium of the, the secretory and nutritive functions of the 601
——— rare anomaly of the central vein of the 632
——— secondary hæmorrhages in the, in secondary anæmia 606
——— secondary tuberculosis of the ... 435
——— structure of the ciliary portion of the 601
——— tuberculous lesions of the 435
Retino-choroiditis (Jensen) 33
Retinal and vascular changes associated with general disease 670
——— arteries, pulsation in the ... 271, 338, 460
——— changes following a fracture of the skull 620
——— detachment in myopes cured by simple sclerectomy ... 429
——— myopic 429
——— detachment, treatment of 255
——— with cystic appearance at the periphery ... 432
——— disease with detachment in a child ... 31
——— with massive exudate and detachment 632
——— lipæmia in severe diabetes 605
——— vessels, arterio-sclerosis of the ... 357
Retinitis, albuminuric 39, 303
——— lipoids and white plaques in 614
——— and optic neuritis and consecutive atrophy associated with pregnancy 597
——— pigmentosa: a pathological report 408
——— hereditary transmission of, in two generations 407
——— hyaline bodies at the optic disc in case of ... 19, 716
——— proliferans 20
Retractor, eyelid, a new 221
Retrobulbar neuritis with amaurosis, caused by infective multiple neuritis 606
Rheumatic eye affections, relationship of, to "secondary" tuberculosis 740
Rodent ulcer of the cornea, pathology of ... 743
——— treated with CO_2 snow ... 562
Rupture of the optic disc 618
Salicylic acid, excretion of in the ocular humours 71
Salts of zinc, action of in diplobacillary conjunctivitis 759
Salvarsan and neosalvarsan in the treatment of sympathetic ophthalmia ... 692
——— in the treatment of interstitial keratitis (congenital syphiltic)... 342
Salvarsan, neuritis follows treatment with ... 440
Sarcoma, flat, of the choroid... 614
——— of the choroid 742

PAGE

Schiötz's tonometer, in the investigation of glaucomatous and normal eyes 244
——————usefulness of 244
Schnabel's vacuoles and their significance in the development of glaucomatous excavation 354
Sclera and conjunctiva, tuberculosis of the... 435
"Sclerectome" a further note on the ... 220
—————— a new 160
Scleritis, brawny 2
Sclero-corneal trephining ... ...3[illegible], 4[illegible]
—————— (Elliot's) on some of the causes of failure after ... 640
Sclerosis, insular, eye lesions of 97
Sclerostomy 580
Sclerectomy and sclerostomy... 697
——————anti-glaucomatous 627
——————oblique, of Prof. Maklakoff and the filtering cicatrix ... ... 2[illegible]
——————posterior, superficial crossed ... 247
——————simple, in the cure of retinal detachment in myopes ... 429
Sclerotic, method of obtaining a filtering cicatrix of the ... ... 2[illegible]
—————— trephining the 219
Scotoma by solar eclipse and macular lesion 545
Scrofuloderma in ophthalmology, significance of 605
Senile changes found in the human eye ... 2[illegible]
Sensory pupil reflex in tobacco amblyopia ... 734
Sepsis, chronic, influence of upon eye disease 416
Septic infection in the causation of eye disease 4[illegible]
Serum and vaccine therapy in diplobacillary conjunctivitis 371
—————— therapy of pneumococcal infection of the eye 372
—————— used in pseudo-membranous conjunctivitis 53
Sideroscope, a modified ... ... 6[illegible]
Sight tests of the Board of Trade 319
"Signal" vision test type 667
Sinusitis, bilateral papillœdema with central scotoma, from 105
Snow, CO_2, rodent ulcer treated with ... 562
Soamin poisoning, resulting in optic atrophy 15
Spectacles, history of 737
—————— the invention and discovery of 7[illegible]
Spectral colours, pure, negative after-images [illegible] 143
Sphincter pupillæ, worm-like contractions of the ... ... 2[illegible]
Sporotrichosis by endogenous infection, experimental study of ... 354
—————— disseminated gummatous ... 485
—————— ocular 485
—————— primary, of the eyelids simulating a lacrymal fistula ... 485
Spring catarrh, clinical, experimental and microscopic studies of ... 492
—————— radium treatment of ... 371
Squint operations, a phantom for use in the practice of 285
—————— lengthening a rectus tendon in 17
Staining of microscopic specimens 294
Staphylococcal infection of the conjunctiva, a rare form of 679
Staphyloma, congenital anterior 551

PAGE

Staphylomatous leucoma, adherens, trephining the sclero-corneal limbus for 247
Streptothrix, action of, on the eye, with reference to reaper's keratitis 413
Strychnine, action of on the retinal functions of the normal eye 182
Sub-conjunctival injections in eye disease ... 372
——————of mercury cyanide in unilateral irido-cyclitis (serous iritis) 372
——————of neosalvarsan... 692
Sulphate of zinc, action of, on the diplobacillus of subacute conjunctivitis ... 759
Supra-orbital neuralgia 632
Surgical treatment of detached retina 429
Swanzy Memorial Fund 704
Sympathetic affections 108
—————— disease following cataract extraction, tuberculin treatment of 108
—————— inflammation, experimental 108
—————— irido-cyclitis following cataract extraction 684
—————— ophthalmia and disturbances of hearing ... 684
——————and injuries of the eye, relation of lymphocytosis to 684
——————and tuberculosis ... 684
——————cases observed in the Leipzig Eye Clinic 684
——————deafness in... ... 109
——————developing seven days after operation ... ... 4[illegible]
——————experiments on ... 1[illegible]
——————intra-ocular foreign bodies and ... 684
——————new observations on 109
——————pathogenesis of ... 108
——————relation of fermentations on the eye to [illegible]
——————treatment of with Salvarsan and Neosalvarsan ... 692
——————**ophthalmitis** ... ... [illegible]
—————— pathogenesis of [illegible]
Synchysis scintillans 663
Syphilis and injuries of the eye ... 178
—————— ocular injuries ... ... 1[illegible]
—————— traumatism ... ... 1[illegible]
—————— parasyphilis of the nervous system, ocular symptoms of 605
——————hereditary, malformation of the cornea as a stigma of 617
——————inherited, of the eye, recent investigations dealing with ... 7[illegible]
—————— of the orbit 753
—————— ocular, experimental researches upon 365
—————— rôle of in ocular pathology 313
—————— tertiary, in tabetics, ocular manifestations of 753
Syphilitic affections of the eye ... 755
——————diseases of the eye, congenital 753
——————swelling, pericorneal 753
Tabes and aneurism of the aorta 605
—————— optic atrophy in 614
Tabetic atrophy of the optic nerve, forms of visual fields in 105
—————— optic atrophy with unilateral nasal hemianopsia 605

PAGE

Tabes dorsalis, syphilis in ocular manifestations of 753
Tarsal cyst forceps 733
Tarsorrhaphy in the treatment of acute purulent keratitis in exophthalmic goitre 156
Tay-Sachs' disease 108
Teeth and eyes 620
Temperature, bodily, in diseases of the eye... 143
Tenotomy, partial, director forceps for use in
——— of a lateral rectus to secure vertical deviation 74
Tension, ocular... 367
———systematic blood, and raised intra-ocular tension, relation between ... 350
Test-type, "signal" vision 667
Tetany, lamellar cataract and 737
Therapeutics, external ocular, noviform ointment in 758
Thiocyanates in the body fluids 372
Thyroid extract, in treatment of recurrent hæmorrhages into vitreous ... 20
———with arsenic and its associated internal secretions in diseases of the eye 440
Tobacco amblyopia 573
———sensory pupil reflex in ... 734
Tonometer, Schiötz 244
——— Stephenson-Wolinski 381
Tonometry 244
——— with a description of a tonometer 244
Toxæmia, alimentary 416
——— **(alimentary and oral) as a cause of eye disease** ... 415
——— intestinal, as a cause of acute retrobulbar neuritis 415
Trachoma bodies, so-called, conjunctival affections associated with ... 679
———cell studies in 492
———clinical, experimental and microscopic studies of 492
———corpuscles 295
———diagnostic value of the "chlamydozoa" of Prowazek and Halberstädter in 492
———formations taken for parasites in 492
———prize, international ... 386, 705
———Prowazek bodies in the follicles and papillæ of 492
———treatment of, with radium ... 182
Transplanted amphibian eye, influence of the host on... 474
Traumatic conjunctivitis 678
——— enophthalmos, autopsy upon a case of 234
——— multiocular implantation corneal cyst 268
Traumatism, influence of, on the appearance of interstitial keratitis... ... 178
——— ocular, syphilis and 178
Trephine, glaucoma, a modified 668
——— worked by electric motor 669
Trephining at the limbus 247
——— (Elliot's) for glaucoma and its technique 588
——— modification in... ... 627
——— the technique of 484
——— for glaucoma, results of Elliot's 365
——— in glaucoma 523
——— acute and chronic... 580
——— sclero-corneal 324
——— (Elliot's), some cause of failure after ... 640
——— some cause of failure after ... 585
Trephining, technique of Elliot's operation ... 247
——— the sclera 484
——— sclero - corneal limbus for staphylomatous leucoma adherens 247
——— the sclerotic 219
Triton and the frog, process of regeneration in the retina of the 474
Tubercular disease of the uvea 435
——— iritis, double 692
Tubercle, solitary, of the papilla 234
Tuberculin and ocular tuberculosis 56, 182
———in diseases of the eye ... 561, 562
——— old, use of in the ætiology of optic neuritis and neuro-retinitis 673
———treatment 255
——— of sympathetic diseases following cataract extraction 108
———value of, in phlyctenular (eczematous) conjunctivitis 619
Tuberculo-rheumatic uveitis, chronic ... 435
Tuberculosis 434
——— ætiological role of in affections of the optic nerve and retina 498
——— epibulbar 435
——— in the ætiology of periphlebitis retinalis adolescentium ... 435
——— ocular, treatment of ... 56
——— tuberculin and ... 182
——— of the bulbar conjunctiva ... 435
——— conjunctiva and sclera 435
——— fundus 434
——— lacrymal sac... ... 297
——— primiary miliary, of the bulbar conjunctiva, cured by the serum of Marmoreck ... 313
——— rôle of, in orbital affections 606
——— secondary, of the retina ... 435
——— "secondary," relationship of rheumatic eye affections to 740
——— sympathetic ophthalmia and 684
Tuberculous lesions of the retina 435
Tumours of the caruncle 35
Tumours of the conjunctiva and cornea 34
——— of the pons 605
——— pons-cerebellar angle ... 357
pituitary 552
Ulcer, rodent, of the cornea, pathology of ... 743
——— treated with snow, CO_2 ... 562
Ulcus serpens corneæ and intra-ocular pressure 244
———treatment of 371
Urinatoridæ (Divers), morphology of the eye in the 475
Urine and fæces, importance of examining in eye diseases 692
Uvea, tubercular diseases of the 435
Uveal tract, ætiology and course of diseases of the 674
Uveitis, tuberculo-rheumatic, chronic ... 435
Vaccine and serum therapy in diplobacillary conjunctivitis 371
———immunity of the eye 613
———treatment in infections of the cornea 471
Vaccines in eye infections 758
Vascular and inflammatory diseases of the choroid 118
———and other retinal changes associated with general disease ... 670
Vaquez's disease 605
Vernal catarrh, pathology of... 614

PAGE
Vernal conjunctivitis 679
Vertical deviation, partial tenotomy of a lateral rectus, to secure 74
Vision, conservation of 704
——— **field of** 105
Visual acuity, peripheral, and colour sense, relationship between 25
——— disorders following direct observation of the last solar eclipse ... 545
——— fields, forms of, in tabetic atrophy of the optic nerve 105
——————— in coal miners' nystagmus ... 727
——————— of, studies on the 25
——— malingering 442
——— phenomena, cerebral localisation of some 741
——— troubles caused by dietetic poisoning 357
Vitreous and zonula, development of in man 601
——— body, injury to, as a factor in the production of secondary glaucoma 234
——— development of the central canal of the 474
——— extracellular action of the leucocytes in the 235
——— histogenetic theory of the 601
Vitreous immunity 479
——— methods of avoiding prolapse in operating for cataract 747
von Hippel's disease 421
Wassermann's histopin ointment in ophthalmology 758
Wassermann reaction 541
——————————in case of unilateral buphthalmos ... 364
——————————in ophthalmology... 541
Word-blindness, acquired and congenital, treatment of 546
Workman's Compensation Act, 1906 ... 703
Worm-like contractions of the sphincter pupillæ 253
Writing in elementary schools, practical value of upright and sloping 442
Xanthelasma of the eyelids 235
Xeroderma pigmentosum, atrophy of the iris and epibulbar carcinoma, associated with 357
Xerosis conjunctivæ, hemeralopia and ... 746
X-Rays in the treatment of epibulbar epithelioma 693
Zonula and vitreous, development of in man 601

THE

OPHTHALMOSCOPE.

A MONTHLY REVIEW OF CURRENT OPHTHALMOLOGY.

VOL. XI.—No. 7.—12 JULY 1, 1913. TWO SHILLINGS.

CONTENTS.

Original Communications.—

1. D. V. Giri, D.O.—On Concretions in the Optic Nerve 390
2. H. Herbert, F.R.C.S.—Some Complications recently met with in Glaucoma Operations 398
3. Robert Scott Lamb, M.D.—Perithelioma of the Eyelids ... 401

Clinical Memoranda.—

1. Arthur Zorab.—A Note upon Essential Oils in the Treatment of Irido-Cyclitis 406
2. George H. Oliver.—Thirteen cases of Hereditary Transmission of Retinitis Pigmentosa in two Generations 407

Pathological and Bacteriological Memoranda.—

1. Hanford McKee, B.A., M.D.—Retinitis Pigmentosa: a pathological report 408
2. Sydney Stephenson.—A case of Septic Endophthalmitis associated with the Diplococcus Lanceolatus 411

Novelties.

A New Cutting Cystitome. By F. R. Cross, M.B., F.R.C.S. ... 413

Current Literature.—

I. Streptothrix of the Eye 413
II. Ætiology of Lacrymal Affections 414
III. Toxæmia (alimentary and oral) as a cause of Eye Disease ... 415
IV. von Hippel's Disease 421
V. Ophthalmia Neonatorum 422
VI. Ocular Myoclonus 424
VII. Intra-Ocular Coagulation of the Aqueous Humour 424
VIII. Colour Sense 425
IX. Surgical Treatment of Detached Retina 429
X. Detachment of the Retina 431
XI. Tuberculosis 434
XII. Remedies 440
XIII. Miscellaneous Communications 442

Book Notices 446

Notes and Echoes 450

The Ophthalmoscope Diary... 454

ORIGINAL COMMUNICATIONS.

ON CONCRETIONS IN THE OPTIC NERVE.

BY

D. V. GIRI, D.O.(Oxon.)

JUNIOR ASSISTANT TO THE KLINIK FUCHS, VIENNA; FORMERLY CLINICAL ASSISTANT AT THE ROYAL LONDON OPHTHALMIC HOSPITAL.

IN going through the literature, one cannot help being struck by the attention that authors have, from time to time, devoted to the various kinds of concretions met with in the inner coats of the eye and the optic nerve. Yet our knowledge of them cannot be said to be by any means satisfactory. The nomenclature is highly misleading. When one finds a concretion called by this name or that simply because it has given such and such a staining reaction, as most authors have done, confusion becomes worse confounded. Terms like "colloid," "hyaline," and "amyloid" lose their meaning when applied to these concretions, as they possess neither the properties nor do they give the proper reactions of the bodies signified by those terms. Granting that the scantiness of our knowledge of the concretions and their approximation in staining reactions if not in properties to bodies properly called "colloid," "hyaline," "amyloid," has led to the use of such arbitrary names, and that it is difficult to get out of this usage, it becomes essential, if what is being spoken about should be intelligible, to keep rigidly to these conventions, and to call a concretion by this name or that, according to its anatomical position and its histogenesis, so far as it is known, no matter what reaction it gives, or use a non-implicating term, like the German "Drusen," in conjunction with the anatomical position. Otherwise, the error of calling the same concretion by one name at one time and by another at another, is easily fallen into, because the reaction to stains that a concretion gives is variable and dependent upon its age, position, and environment. In some microscopic specimens one sees this point very well brought out, inasmuch as in the same group of concretions one sees different grades of staining and in some cases even different staining reactions. As to the morphology of the concretions, one kind of concretion may simulate another kind so much that one is very likely to take the one for the other and hence to name them according to the form and structure would again lead to error. From what has been already said, it is evident that the structure and form and staining reactions of a concretion are variable, but that its anatomical position and histogenesis are constant and that on the basis of these constants a given concretion should be called by this name or by that, if the name is to convey a definite intelligible idea to the mind.

In the course of this contribution it is my desire to deal comprehensively with the least understood of these concretions, *viz.*, those in the intervaginal space, and also to cite a case of those most spoken of, *viz.*, those in the papilla.

The microscopical anatomy of the arachnoidal sheath, together with its relations to the dural and pial sheaths, is of special interest with regard to the concretions in question.—The arachnoid lies in intimate contact with the dural sheath, on which account, Schwalbe was led to look upon it as the innermost layer of the dura. If the optic nerve is macroscopically separated from the dura, the arachnoid remains almost completely in connection with the dural sheath and tears itself away only with the dura. The adherent arachnoid can then be torn off with forceps from the dura in the form of small

pieces of fine membrane. According to Key and Retzius, the arachnoidal sheath constitutes a fine membrane of exactly the same structure as the arachnoid of the central organs. It consists of a fine-meshed network of connective tissue bundles, which cross one another in different directions. The outer and inner surfaces of this membrane are covered with layers of endothelial cells. The arachnoidal sheath forms a complete tube round the optic nerve. It is connected with the dural sheath, on the one hand, and the pial, on the other, by means of strands of connective tissue (Greeff). The arachnoid contains no blood vessels whatever and no nerves.

A well-formed concretion in the intervaginal space, as seen microscopically in a section, has a regular rounded structure. It has a centre of very fine granular *débris* disposed in closely set, well-defined, regular concentric layers. The centre is marked off from the rest by its greater refractility and is encircled by a deeper-stained ring, in which the concentric lamellation is less defined, and the *débris* is not so finely granular as in the centre. The succeeding ring stains deeper still, is composed of coarse granules, and looks like a wavy fringe of tangled curly hair interspersed with faintly staining, malformed, breaking-down nuclei. The whole is enclosed in a capsule, which presents a fine fibrillary appearance, stains lightest, and contains here and there a degenerating nucleus. Outside the capsule are to be seen concentrically arranged rows of nuclei, which are short or long ovals, whose long axes run parallel to the circumference of the circle which they form. The smallest concretions often appears homogeneous. The diameter of these concretions varies from 22μ to 110μ, the average concretion having a diameter of 88μ (Figs. 1 and 2). They go by the name of "corpora arenacea."

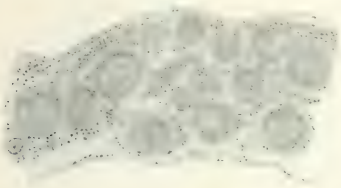

FIG. 1.

FIG. 2.

FIG. 1. Size $\frac{61}{1}$. *Corpora arenacea* in the intervaginal space, reproduced from a transverse section of the optic nerve.

FIG. 2. Size $\frac{300}{1}$. A *corpus arenaceum* magnified to show its structure in detail.

They occur almost invariably in the central nervous system, especially on the dura mater of the base of the brain (Obersteiner), in the choroid plexus (Finlay and Imamura), and in the lumbar enlargement of the spinal cord (Mattauschek). Here they hardly ever reach a greater diameter than 80μ, and are composed of calcium phosphate and calcium carbonate. When present in excessive numbers, they go to form sand-tumours—psammomæ (Obersteiner). In favourable sections one can well follow the mode of origin of these concretions. According to Imamura, there is at first a deposit of a clotted homogeneous mass between the connective tissue fibres of the arachnoid. Then the cells proliferate very profusely about this mass, and arrange themselves in superimposed layers. Finally, these masses take up calcareous salts from the plasma, and constitute the definitive corpora arenacea. According to Mattauschek, there is at first a proliferation of the endothelial cells, then an arrangement of these cells in concentric layers without any signs of degeneration in any of the groups of cells. With further increase of cells,

a process of central necrosis begins. At this stage one can see in the centre homogeneous, hazily stained masses, whose origin from the endothelial cells could hardly be doubted. At a further stage of development, there appears in the centre a rounded, homogeneous mass, which stains with eosin light red (hyaline), and it can be plainly recognised that these masses are passing on to typical calcareous concretions, and in many cases an obvious lamellation is seen. Besides this mode of origin from endothelial cells, there is a second way in which they could possibly arise. One finds sometimes a homogeneous hyaline mass with a ring of endothelial cells. This ring increases in thickness, owing to multiplication of the cells, which arrange themselves in concentric layers. In this case, it is likely that the concretion takes its origin from a connective tissue bundle that has undergone hyaline degeneration.

In the sections of the optic nerve that I have studied microscopically one can see the concretions in various stages of development. Some young concretions give evidence of their arising from a gradually developing hyaline degeneration of the connective-tissue trabeculæ; the fact that in occasional cases in which these degenerating bundles of connective tissue are seen in longitudinal section, the young corpus arenaceum is not spherical but elongated, strongly supports such a view (Fig. 3). Fuchs is not in accord with the

Fig. 3.

Size $\frac{1}{400}$. A young *corpus arenaceum* seen in longitudinal section.

view that the corpora arenacea are initiated by degenerating endothelial cells. Both Imamura and Mattauschek assert that already in the earliest infancy there is an indication of the commencement of endothelial conglomerations or pearls in the central nervous system; that they have probably no pathological significance; and that they cannot be brought into relationship with any particular disease. Zanda sees in these concretions the groundwork of the formation of osteomata in the arachnoid; finds them at all ages and in altogether unrelated diseases; and attaches no essential local significance to them. To Mattauschek it appears as though the whole arachnoid posesses a tendency to proliferation of its endothelium, and wherever conditions are favourable, this proliferation takes place, giving rise ultimately to the characteristic concretions.

Corpora arenacea occur very seldom in the intervaginal space. They are mentioned in the literature only three times, so far as I have been able to make out, but they were not recognised as such. I saw them for the first time in the sections here described. Fuchs says that he has never observed corpora arenacea in the optic nerve in the case of young patients, and that they are neither related to any particular disease nor have they any pathological significance in this space other than that of a kind of senile change. When present in large numbers, they may cause a distention of the intervaginal space just beyond the sclera, as in the case of Hirschberg and Birnbacher, cited by Streiff. In a case of the kind the swelling may simulate a tumour of the optic nerve, and cause pressure on the nerve.

In one case of which Professor Fuchs gave me the sections for examination, a body of unusually large dimensions and peculiar form is seen in the intervaginal space (Fig. 4). It is shaped something like a sausage, presenting bulges

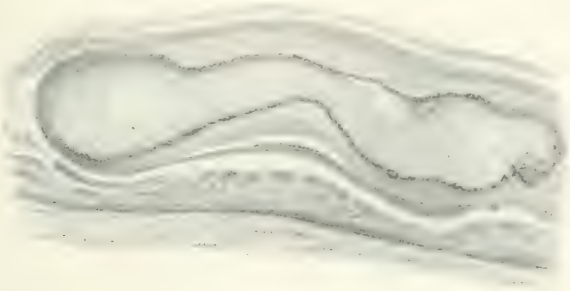

FIG. 4.

Size $\frac{64}{1}$. A *corpus arenaceum* of unusual size and form in the intervaginal space, reproduced from a longitudinal section of the optic nerve.

at either end owing to constriction in the middle, and measures no less than 1120μ long, 306μ broad at its broadest part, and 238μ broad at the constriction. The finely granular *débris* in the middle, forming the body of the concretion, is comparatively dense, stains light pink, and presents here and there a worm-eaten appearance; at either extremity the *débris* becomes rarified, stains very light, and resolves itself into a meshwork of wavy arches with the curves towards the middle of the concretion. At the rarified extremities are a large number of faintly staining breaking-down nuclei, on account of whose presence it is hardly possible that the concretion is old enough to be an early stage of bone-formation. External to this finely granular *débris* there is a coarsely granular coat looking like a wavy fringe of tangled curly hair interspersed with faintly staining nuclei. The enclosing capsule is one of close-set fibres, with thin elongated nuclei in it. In one place the concretion lies in intimate contact with the dural sheath. Why it is not seen all along its outer surface in contact with the dura, as one would expect from the relations of the dural and arachnoidal sheaths, is probably because the section happens to be somewhat oblique, passing partly through the surface of contact but mostly through the free surface of the concretion. The specimen is one of a series of sections of an eye with a perforated cornea from a man 46 years of age. The optic nerve is normal. The appearance of the concretion gives no room whatever for thinking that it has resulted from the fusion of two or more smaller concretions. In the specimens I have studied I have not come across an instance of fusion of two corpora arenacea; in the intervaginal space, at any rate, they tend to remain distinct. Hence, the concretion in question is to be looked upon as a non-conglomerate concretion, and there can be no doubt as to its being also a corpus arenaceum of unusual size and form.

The corpora arenacea in the intervaginal space have been taken for corpora amylacea. The latter concretions occur plentifully in the atrophic optic nerve, although, according to Greeff, Ginsberg, and others, they are not infrequent in the normal optic nerve, especially in old people. They are mostly met with in the proximal part of the optic nerve, especially in the optic tract and chiasma, and very seldom in the peripheral part. They are glassy, homogeneous-looking, round or oval bodies, varying in diameter from 15μ to 25μ and occasionally showing a concentric lamellation and enclosed in a homogeneous-looking capsule (Fig. 5). The observations

of Besser and Rindfleisch, that they arise from amyloid infiltration—or degeneration—of the round neuroglia cells, have been confirmed later by Leber and Greeff and are generally accepted, and in teased-out specimens one can see fine fibrous processes proceeding from the corpus amylaceum just as from neuroglia cells. Siegert, after careful investigation, divides the corpora amylacea occurring in the body into two groups—corpora versicolorata and corpora flava—and, according to his classification, the corpora amylacea of the optic nerve belong to the latter class, but distinguish themselves from the corpora flava of the central nervous system in that they react to stains partly like hyaline and partly like amyloid, and in that calcification has never been



FIG. 5.

Size $\frac{110}{1}$. *Corpora amylacea* in a transverse section of the optic nerve. Compare the size of these tiny, rounded, almost homogeneous-looking bodies with the size of *orpora arenacea* in Fig. 1, magnified only 61 times.

observed in them. The corpora flava of the central nervous system give the hyaline reaction, and calcification is frequent in them. As the corpora amylacea of the nervous organs do not give the characteristic amyloid reaction, they have to be carefully distinguished from the proper amyloid degeneration.

Notwithstanding the fact that the corpora amylacea develop only within the nerve-substance, and hence are never found in the intervaginal space, they have been confused with the corpora arenacea of this space owing to the fact that a concentric structure, as in the genuine copora amylacea of plants, may be present in both, and that they may both react similarly to stains. According to Greeff, Fuchs, and Obersteiner, a concentric lamellation is the exception rather than the rule in corpora amylacea of the optic nerve, and in the specimens I have studied the structure has been mostly homogeneous, and where a concentric arrangement was discoverable, it has been at best a faint indication of it. It is noteworthy how many authors have taken the exception for the rule and looked upon the concentric arrangement as a characteristic of corpora amylacea. Further, the corpus amylaceum hardly ever reaches a diameter greater than 25μ, whereas the average corpus arenaceum has a diameter of 80μ-88μ and the diameter of a very large one could go up to 110μ and in an exceptional case it may assume the enormous dimensions of 1120μ long and 238μ-306μ broad, so that the sizes of the two kinds of concretions form a striking contrast. Hence the only point of real similarity that the corpora amylacea and the corpora arenacea occasionally offer is the reaction to stains—an alluring and disastrous quicksand.

Coats has contributed fig. 485 to Parson's *Pathology of the Eye*. The explanatory note appended to the figure is as follows: "Corpus amylaceum in the arachnoidal sheath of the optic nerve, infiltrated with calcium salts." The diagram makes it evident that in this case corpora arenacea and not corpora amylacea are seen. In describing the corpora amylacea of the optic nerve, it has been pointed out that they never undergo calcareous infiltration and they never occur in the arachnoidal sheath. Here one's faith has been evidently

pinned mainly upon the staining reaction and probably on the appearance of the concretion also to some extent.

Streiff, also misled by the concentric structure and the similarity of staining reaction, looks upon concretions in the intervaginal space as of the same nature as *drusen* in the optic nerve-head. In speaking of the latter he observes: "According to my opinion, we have here much more probably to do with structures which are to be compared to the lamellated concretions of the dural sheath of the optic nerve and also similar bodies of the dura mater. The anatomical finding of Hirschberg and Birnbacher in the case of a sixty year old albuminuric female patient, tends to make such a relationship clearer. . . . . Among the masses filling the intervaginal space one comes across structures which fully resemble the already-described concretions, although the same appearance might arise from cross-sections of degenerate arachnoid strands." Further, he says: "In my earlier work I had laid special stress on the fact that one sees the concretions of the dural sheath always arising near the intervaginal space, and never in the outer layers of the dural tissue."

On account of the intimate apposition of the arachnoid to the dura in this situation (which led Schwalbe to look upon it as the innermost layer of the dural sheath), it is but natural that the concretions should appear to arise from the inner surface of it and give room for Streiff's calling them concretions of the dural sheath. In going through the work of Streiff, one gets the impression that all the time he has been unaware of the proper concretions of the arachnoid, and tends to bring *drusen* in the papilla and corpora arenacea under the same group, which it would be impossible to do, if one would only keep in view the histogenesis which determines, as it were, the situation of the concretion. His dependence on the misleading inconstants—the reaction to stains and the appearance—has been at the root of the confusion. To quote his own words: "Now that the staining and other properties of the concretions of the dural sheath correspond fully with the properties of *drusen* in the optic nerve-head, deeply gone into by Cirincione, de Schweinitz, and Sachsalber, the analogy between the structures concerned is, to my belief, sufficiently proved."

Drusen in the optic nerve-head have attracted more attention than any other kind of concretion in the eye, owing to their striking ophthalmoscopic appearance. H. Müller was the first to recognise *drusen* and to describe their ophthalmoscopic appearance. Since 1858, during which year Müller published his case, there have been hardly fifty cases recorded, so that these granular formations are rare. For a description of the condition and the findings of various authors, I cannot do better than refer the reader to the excellent chapter on Hyaline Bodies (Drusen) in Parson's "*Pathology of the Eye*" and Niel's exhaustive publication: "*Ueber Drusen in Sehnervenkopf*" in 1908.

I shall content myself here with an account of the case of *drusen* I have on hand, together with what I have been able to gather from the literature and what appears to me probable with regard to their mode of origin and development.

It concerns a man, 42 years of age, who came into the Klinik with iridocyclitis in his left eye, which had suffered from a severe perforating injury incidental to a dynamite explosion the year previous and which was consequently blind. The fundus was not visible. The eye was enucleated.

The right eye, but for some fine particles of stone on the surface of the cornea, was normal.

My personal knowledge of the case is derived from my study of a series of microscopical sections of the enucleated eye stained with hæmatoxylin-eosin. Incidentally, it may not be out of place to say that the specimens reproduced here were all stained with hæmatoxylin-eosin.

In Figure 6 one sees a large number of concretions of varying size in front of the lamina cribrosa, lying deep below the surface of the papilla. They are all made up of a fine granular *débris* disposed in delicate concentric layers. The granules are somewhat coarser towards the periphery of the concretions. The larger concretions have a well-defined irregularly nodular outline and the body is composed of a series of concentric systems. That this appearance of the larger ones is due to their being conglomerates of smaller ones, becomes self-evident on a study of the small non-conglomerate concretion, which shows a regular, rounded or oval outline and a single concentric system. The better the fusion, the less marked off are the concentric systems from one another. In the largest conglomerate in the specimen, the fusion is more advanced than in the others because most

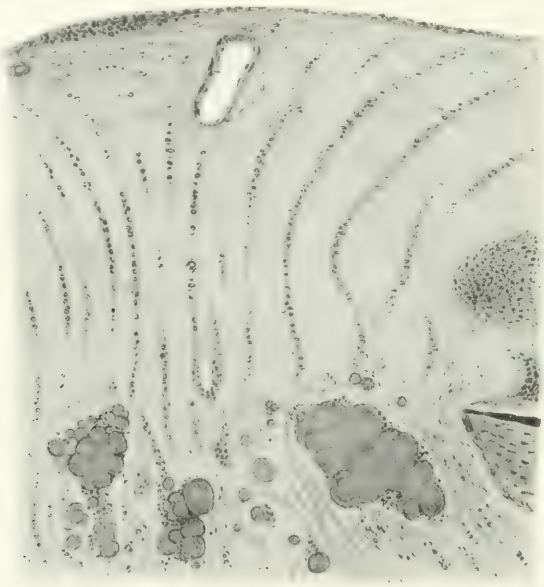

FIG. 6.

Size $\frac{6.1}{1}$. *Drusen in the optic nerve-head.*

of the concentric systems merge into one another at their margins. The other conglomerates show fusion at various earlier stages. In the smallest non-conglomerate concretion, concentric lamellation is hardly in evidence. There is just an indication of it in the difference of light reflex between centre a d periphery. They have all stained pinkish-red with eosin. The conglomerates have stained lighter in the centre than at the periphery. Some of the non-conglomerates have stained deeper in the centre than at the periphery, and some the other way about. In the neighbourhood of and between the smaller conglomerates, the neuroglia cells appear closely packed in a number of layers—an appearance probably due to neuroglia strands getting pushed together by the growing concretions—and some of the cells are superposed on the periphery, especially of the largest conglomerate—probably an appearance due to oblique section. There is no indication of capsule formation about the concretions.

In the area occupied by the concretions the fibres are frayed out and shrunken into thin wavy bundles with gaps between, especially in the district

occupied by a number of tiny concretions between the largest conglomerate and the three medium-sized ones close together. Behind the lamina cribrosa the nerve shows at the periphery an approximation of the pial septa and an increase of neuroglia cells—peripheral atrophy.

At one place in the pars plana of the ciliary body there is a similar concretion—probably a Russel's corpuscle.

Remarks.

Various theories as to the origin of *drusen* have been put forward. Iwanoff looks upon them as colloid bodies. Oeller dissents from Iwanoff: he compares them with similar bodies found in the central nervous system and possibly derived from the myelin of the nerve-sheaths. Hirschberg and Cirincione, after a thorough investigation, regard them as comparable to calcareous nodules in the lungs and not as colloid bodies. Gurwitch found them in the internuclear layer of the retina, where they could not have been derived from the lamina vitrea, and considers them identical with von Recklinghausen's "hyaline" regarded as the precursor of amyloid substance. Sachsalber looks upon them as hyaline in nature, at least in the early stages. The hyaline view is the one generally accepted.

Apropos the constitution of *drusen*, Parsons says, "It is probable that 'hyaline' is not a definite body at all and that hyaline deposits are really albuminous exudates undergoing gradual chemical change. This view is supported by the different tints which these deposits assume when treated with stains. It is probable that there are two classes of degenerative deposits found in the eye, *viz.*, (1) derived from activity of cells, (2) exudations. Exudates are mainly the coagulated plasma poured out from diseased blood vessels or deposited by a stagnant lymph stream, although the death of leucocytes and other tissue elements may contribute a share. Whatever be the source the 'exudate' is a dead, inert, proteid mass, and its future history is entirely dependent on its environment. According to position and circumstances, it may become (1) absorbed, (2) organised, (3) remain unchanged as hyaline, (4) calcareous (5) converted into bone."

Drusen have been noted in eyes functionally and objectively normal in apparently quite healthy individuals. They are often associated with retinitis pigmentosa. They have been mostly found in eyes atrophic as the result of injury, and in eyes with inflammation or degeneration of the optic nerve; in these cases they have not been found in the sound eye, as a rule. Cranial injuries have appeared to be responsible for the formation of *drusen* in some instances in which the occurrence of the concretions has been unilateral. In the case of two families a hereditary tendency has been shown.

Some authors think that although *drusen* are often associated with retinitis pigmentosa and other diseases and with inflammations or injuries of the optic nerve and injuries either of the eye or of the skull, and although in many of the reported cases in which the eyes, but for *drusen*, were apparently normal, the history gave room for a previous affection of the eye or the skull. Although it is admitted that it is possible for an affection to run its course without leaving any traces of it in the eye, *drusen* are not necessarily dependent on these conditions and may arise independently even in a perfectly normal eye—a view which finds an apparent support in the insignificant number of recorded cases. As it is difficult for me to conceive of an abnormal condition arising under quite normal conditions, I am inclined to agree with Streiff in thinking that an alteration in the constitution or a disturbance in the

circulation of the lymph in the eye lies at the root of drusen-formation. To my mind, this change may come on as one of short or long duration, may be general or local, leading to small deposits which afterwards grow by the same chemical process which caused the initial deposition of insoluble albuminoid substances from the lymph. That the deposition takes place in the neighbourhood of the central vessels or at the edge of the disc, as a rule, is probably because the edge of the disc and the surface of the vessel-walls act as points of resistance to the lymph stream and as scaffolding for drusen-formation.

In conclusion, it is my pleasant duty to tender warm thanks to Hofrat Professor Dr. Ernst Fuchs for his lively interest and kind help in my work.

REFERENCES.

1. **Graefe-Saemisch.**—"Handbuch der Gesammten Augenheilkunde": (*a*) Die Mikroskopische Anatomie des Sehnerven und der Netzhaut (Vol. I, Chap. 5); (*b*) Corpora Amylacea (Vol. I. Chap. 5, p. 43).
2. **Greeff.**—"Pathologische Anatomie des Auges" (Berlin, 1902-6). Corpora Amylacea, p. 418.

Given out from the Neurological Institute of Vienna, under the direction of Hof. Prof. Dr. Obersteiner:

3. **E. Mattauschek** "Ein Beitrag zur Kenntnis der Arachnoidea Spinalis" (1909): *Obersteiner Arbeiten*, Vol XVII, p. 150.
4. **Imamura** "Beitrage zur Histologie des Plexus Chorioidens des Menchen" (1902): *Obersteiner Arbeiten*, Vol. VIII, p. 272.

5. **Ginsberg** "Grundriss der Pathologischen Histologie des Auges (Berlin, 1903): Amyloidkörperchen," p. 403.
6. **Parsons** "Pathology of the Eye," Vol. II.: (*a*) Hyaline Bodies (Drusen); (*b*) Corpora Amylacea.
7. **Collins and Mayou.**—"Pathology and Bacteriology of the Eye" (London and Philadelphia, 1911): Hyaline Nodules in the Optic Disc, p. 491; Corpora Amylacea in the Optic Nerve, p. 492.
8. **Streiff.**—"Ueber die Entstehung der Optikus Drusen." *Klinische Monatsblätter für Augenheilkunde*, 1904, Vol. I, p. 149.
9. **Höeg Neil's.**—"Ueber Drusen im Sehnervenkopf": v. Graefe's *Archiv für Ophthalmologie*, Vol. LXIX, p. 355.
10. **Obersteiner.**—"Anleitung beim Studium des Baues der Nervösen Central Organe" (Leipzig and Wien, 1896): (*a*) Amyloidkörperchen, p. 205; (*b*) Corpuscula Arenacea, p. 534.
11. **Fuchs.**—"Lehrbuch der Augenheilkunde" (Leipzig and Wien, 1910): Die Scheiden des Sehnerven, p. 630.

SOME COMPLICATIONS RECENTLY MET WITH IN GLAUCOMA OPERATIONS.

BY

H. HERBERT, F.R.C.S.,

NOTTINGHAM, ENGLAND.

OUR knowledge of the degree and kind of risk pertaining to operation in glaucoma, primary and secondary, is at present somewhat vague. Upon the principle that we learn more from our failures than from our successes, the report of the following troubles should be of interest.

A B C

The triple flap modification of small flap sclerotomy was described briefly in the *Proceedings of the Royal Society of Medicine*, Ophthalmic Section (Meeting of November 6th, 1912, page 29), where two of the following cases were summarized. The method consists merely in cutting, with modified Bishop Harman's twin scissors, twice instead of once. Instead of two parallel incisions outlining one flap, four incisions are made to include three very

narrow flaps (Figs. A. and B.). A primary incision with a bent broad needle, 3·5 mm. wide, is sufficient to admit of this double cutting by twin scissors with blades 1·5 mm. apart. Personally, I have made this flap section under a conjunctival flap only upon three eyes, but have employed the same incision, cutting with the scissors through conjunctiva and sclera together, on eight eyes. In these latter cases the primary incision only has been made sub-conjunctival by sliding the conjunctiva. The operation has been reserved, in all but two cases, for secondary glaucoma likely to give an imperfect or negative result with the original small flap sclerotomy. It is obvious that in cases where the conjunctiva is cut through, iridectomy or irido-dialysis must usually be combined, lest prolapse of iris should occur, uncovered by conjunctiva.

Trouble with iris. Three cases.

(i) Right eye tension +2, secondary to iritis, but anterior chamber shallow (pupil, perhaps, partly excluded?). Triple-flap operation upwards and outwards under a conjunctival flap, with small irido-dialysis. No eserine was used before or after operation owing to the iritis and posterior synechiæ, and next day atropine was instilled in spite of some bulging of the scleral and conjunctival flaps. The elevation of the flaps became more pronounced, and after a few days, the tension rose again, and it was obvious that the base of the iris lay in contact with the wound, entirely preventing leakage through it. A little of the ciliary body lay pressed forward under the conjunctiva in the gap beyond the elevated scleral flaps. The cause of the trouble was not at first recognised, because the pupil remained round and central, and because moderate early prominence is at times seen after small flap sclerotomy with filtration perfectly free.

Six days after operation, the same incision was repeated in the lower and outer quadrant of the eye, cutting through the conjunctiva with the scissors; it was with iridectomy. After this the case did very well. Under the new drainage provided, the prominent flaps of the first operation slowly flattened down completely, and the iritis cleared up rapidly without the use of atropine. There was a slight temporary rise of tension about a month later, for which a little eserine was used for a week or two.

(ii) A little later the same operation was performed upon a case of chronic primary non-congestive glaucoma. Neither iridectomy nor irido-dialysis was made, although the anterior chamber was exceptionally shallow. And although eserine was instilled before and after operation, it was ineffective because of the quite unnecessary amount of adrenalin and cocaine used. Here the same adhesion of iris took place, again unrecognized for the first day or two, because of a perfectly central pupil. The same bulging of conjunctival and scleral flaps was seen. But in this case the conjunctival flap was either rather short or left somewhat folded, so that it failed to cover completely the ciliary body exposed beyond the elevated scleral flaps. There is little doubt that this narrow exposure of uveal tissue, remedied too late by a conjunctival stitch, allowed of the entry of infective organisms into the eye. The tension having risen three weeks after operation, was readily lowered by an ordinary small flap sclerotomy with combined iridectomy. But the vision slowly sank with the development of vitreous opacity and cataract, contraction of the field of projection of light, and subnormal tension. Five and a half months after operation, there was a quiet attack of iritis lasting for two or three weeks. The patient, who had glaucoma less advanced in the other eye, has, not unnaturally, passed from under my care.

(iii) In the third case an ordinary small flap sclerotomy was performed for chronic non-congestive glaucoma, without iridectomy or irido-dialysis. The trouble here was sub-conjunctival prolapse of iris, found the day after operation and removed (torn) then. It was mainly due to a very bad cough from which the patient suffered, but also to want of care to keep the pupil small after operation. Afterwards, doubtless owing to the persistent coughing, the anterior chamber quite failed to refill, and the wound continued obviously leaking much more freely than is usually the case. The lens, lying in contact with the cornea, gradually became opaque and was extracted. But opaque capsule remained adherent to the upper part of the cornea, and the anterior chamber re-formed below only. Thus, an optical iridectomy is still required, but has been deferred for various reasons.

It is of interest to note that the same operation—simple flap sclerotomy, without iridectomy or irido-dialysis—was performed upon the fellow eye for similar glaucoma with perfect success ten days after the first operation. The cough was then rather less troublesome, and care was taken to use sufficient eserine and not too much cocaine and adrenalin.

The gravity of the above preventible complications makes it one's duty definitely to ensure against their repetition. In these particular cases combined iridectomy would appear to have been indicated. Possibly, the triple flap incision should rarely be made without iridectomy, and possibly simple sclerotomy or sclerectomy should rarely be practised upon eyes with very shallow chamber. But I do not agree that some removal of iris is advisable as a routine measure in operating for chronic glaucoma. The more

peripheral one's incision or excision the greater the liability to iris complication, and troubles such as the above at least suggest the advisability of exploring the possibilities of incisions made at the limbus or as close to it as practicable. My colleague, Mr. W. G. Laws, has lately been operating with satisfaction by triple flap sclerotomy (or rather corneo-sclerotomy) above the cornea, dissecting the conjunctiva at the limbus in Elliot's manner, and so placing the primary incision as far as possible from the base of the iris (Fig. C.). He finds that quite short sclero-corneal flaps are effective. In operating by triple flap incision without reflecting a conjunctival flap, *i.e.*, by incisions through conjunctiva and sclera, I believe the incisions may safely be extended a little into the clear cornea in order to remove the whole wound from the immediate neighbourhood of the possibly adherent base of iris. But there is little or no object in doing this if an iridectomy be included in the operation. The whole objection to a moderately peripheral incision, *viz.*, the risk of iris complication, appears to be removed by iridectomy (at least by a complete iridectomy, as opposed to a basal buttonhole).

I am not in a position at present to discuss the value or applicability of the triple flap incision. The modification is certainly more effective than the original flap sclerotomy, and is therefore applicable to cases for which the original operation is unsuited. A special feature of its action is that the full effect is often very definitely delayed. An early recurrence of tension may pass off quickly and completely and apparently permanently. One or both of the two middle incisions tend to heal up imperfectly. As a striking example of this I wish to place on record the following extraordinary case. It is the only primary glaucoma upon which I have operated by the triple flap method of cutting both conjunctiva and sclera with the scissors, and it shows definitely the unsuitability of this precise procedure for non-congestive primary glaucoma. In the other cases upon which I have operated, secondary glaucoma, the results have never been excessive. There has not been the shrinkage of the middle flap recorded below.

A patient, 77 years of age, was operated upon first by forceps-stretching of a sub-conjunctival puncture. The field of vision was very small, and the (unaided) visual acuteness recorded on admission was the counting of fingers at about a foot distance. As the tension rose again within a week, the case was thought suitable for triple flap sclerotomy, and this was accordingly done without reflecting a conjunctival flap. Iridectomy was omitted because an iridodialysis was made with the knife. The anterior chamber, empty for nearly a week, re-formed but slowly. Three weeks after operation the V.A. with —4·5 D. was 5/18 partly. Seven weeks later still, the chamber had again become almost empty, and the refraction had increased correspondingly to —9 D. giving V.A. 5/24 partly. Soon after this the displaced lens, now quite in contact with the cornea, became cataractous, as in Case III above described, a small field of projection of light remaining unaffected. The tension became very low and the wound obviously leaked very freely, the central scleral flap being definitely shrunken. Apparently, this remarkable late emptying of the chamber was due to the need of a retaining intact conjunctiva to cover the leaking scleral wound. The divided-up conjunctiva had evidently undergone partial atrophy, corresponding with that of the underlying sclera.

Extraction of the lens and capsule by Wenzel's method six weeks ago (six months after the glaucoma operation) quickly restored the tension to normal, but is only slowly restoring the vision, with the clearing up of vitreous opacity. Shortly after the operation, the vision was only hand movements, but now permits of the counting of fingers at three feet without a lens.

PERITHELIOMA OF THE EYELIDS.*

BY

ROBERT SCOTT LAMB, M.D.,
WASHINGTON, D.C.

Introduction.

IN reporting tumours as peritheliomata one assumes great responsibility, and one must be prepared to have the diagnosis assailed by many dubious persons, who would much prefer to use such terms as "lymphangio-endothelioma" or "papillary sarcoma." In view of the infrequency with which perithelioma is found, it may be well to have a clear understanding of the histo-pathology of the growth. I therefore quote from the "Pathology" of Dr. Adami, page 824 of the 1910 edition, published by Lea and Febiger:

"A striking form of tumour is occasionally encountered exhibiting capillary channels cut in various directions, and lined by recognizable endothelium, around each of which capillaries is a collection of cells, many layers deep, arranged radially. The individual cells are not especially elongated, but the arrangement in rows at right angles to the capillary axis is most characteristic. The general opinion is that these cells gain their origin from the lymphoid endothelium of the perivascular space—that thus these tumours form one variety of lymphangio-endothelioma."

"Apparently those cells farthest removed from the central blood vessels are the oldest. Whether from this cause or from their more remote position, they are liable to exhibit degenerative changes and more particularly to undergo hyaline change."

In looking up the subject of perithelioma one finds only a few references to cases, with descriptions and comments. Some of the later books class these tumours under sarcoma, and others, as late as 1910-11, class them under the term lymphangio-endotheliomata. Reports in the literature indicate that such tumours have been found in the breast, subcutaneous tissue, ovary, and two in the eye. One of these, of the choroid, contained some pigment, and may or may not have been melanosarcoma, and the other, of the retina, although more likely perithelioma, may have been lymphangio-sarcoma. A report of a case somewhat similar to the present is one of papillary sarcoma of the lids by Fleischer and Bertscher, *Klinische Monatsblätter für Augenheilkunde*, Mai-Juni, 1911, p. 689.

One of the best articles on the subject is in the *Semaine Médicale*, Paris, 1911, which reviews the subject very thoroughly, going into the *pros* and *cons* of the origin of perithelioma, discussing thoroughly the possibility of there being a distinct type of tumour so characteristic as to warrant a separate term. The conclusion is that there is such a tumour with distinct characteristics distinguishable from the others, and that they are very likely sarcomata. The discussion is quite comprehensive, and includes perithelioma of the breast, ovary, kidney, testicle, nervous system, and a few of the blood vascular glands, as coccygeal, intercarotid, and adrenal. After due consideration of the subject, there is no doubt that perithelioma is a type of tumour distinguishable from others in the larger group of lymphangio-endothelioma.

Case.

The pathological report of the present case is by Major F. F. Russell, of the Medical Corps, U.S.A., whose description of the tumour mass, sent him May 28th, is as follows:

"The tumour from the eyelid sent here on May 28th, shows on microscopic

* Read before the American Academy of Ophthalmology and Oto-Laryngology, August, 1912.

examination a large mass of fibrous tissue containing a great many blood vessels and blood sinuses with thick proliferating walls of endothelium presenting a picture suggesting a perithelioma."

A later report from the same laboratory by Dr. Le Comte includes two slides, from one of which the microphotograph here shown is made.



It would be well to consider at greater length the subject of peritheliomata in general, and the possibility and probability of various portions of the eye and its appendages being affected by the growth; but time being limited, one feels constrained to devote it to a detailed description of this case of perithelioma of the eyelids.

On December 31st, 1910, there came to my clinic at Freedmen's Hospital

a patient by the name of J. H. A. C., whose age was fifty years. He was a light mulatto and a minister of the gospel, and he came for treatment of an inflamed left eyeball and eyelids. He gave a history of having been struck in the left eyeball. In August, 1910, while repairing a fence, driving an eight-penny wire nail, he struck it in such a manner as to cause it to pass between the lids, through the palpebral fissure, and its point was embedded in the bulbar structures of the left eye. He pulled it out immediately, and noticed nothing unusual thereafter, except a drop of blood, which came through the nose. There was no swelling, but occasional pain was experienced in the eye for about two days. About two weeks later, he noticed on the eyeball, half-way between the limbus and outer canthus, a small red swelling. On October 13th, 1910, he consulted Dr. Hundley, of Richmond, Va., who cocainized and removed the growth for microscopic examination. At this time there was no growth on either eyelid.

A letter addressed to Dr. Hundley brought a very courteous reply, in which he described the condition as seen by him on the above date, as follows:

"The tumour was about half the size of a pea, being suspended by a small pedicle and spread out over the sclera. I dissected it off and submitted it to two pathologists who pronounced it malignant."

He had no further treatment at this time, but on November 12th, being in Philadelphia, he called at the clinic of Dr. L. Brewer Hall, from whose reply to my letter I quote as follows:

"There was a white tumour or growth extending from the outer corneal border about 8 mm. long, 6 mm. wide, 2 mm. thick. Also a white membrane in patches, especially over the lower *cul-de-sac* of the conjunctiva; these I found later to exfoliate every few days, leaving a nearly normal appearance, but recurring not always in the same location. Vision not impaired and no pathological changes could be seen with the ophthalmoscope. Tension normal.

"I removed most of the growth with scissors and applied silver nitrate alternate days until he left this city, when the surface was nearly normal in height.

"In the press of dispensary work, no microscopical examination was made.

"The case is a unique one and suggested the keloid, so common in the negro race."

This last comment is particularly interesting in view of later developments.

When first seen by me, the immense amount of mucus present indicated a rather usual dirty sloughing surface of a gumma, and my first impression inclined me to suspect gumma, but closer inspection and manipulation showed the unusual character of the case. The upper and lower lids of the left eye were swollen, especially at the outer canthus, and the lids were pushed forward and away from the eyeball by the growth upon the eyeball itself. The palpebral fissure was narrowed, especially at its outer half. Its length was 34 mm. Its width toward the inner canthus 4 mm. At the nasal side of the limbus of cornea with the eye looking straight ahead, it was 7 mm., opposite the middle of the cornea 5 mm., and at the temporal side of limbus 4 mm. Toward the outer canthus, the lids were in apposition for 5 mm. Upon everting the lower lid, a soft, greyish, gelatinous mass, a sessillated, homogenous outgrowth with a suggestion of pseudo-membrane, was present, extending from the outer canthus to about the middle of the lower lid, and from the ciliary margin to the fornix, and any attempt to remove it was accompanied by bleeding from the underlying membrane. On everting the upper lid a similar growth, similarly located, but smaller in size, was found covered by a thick, yellowish, gelatinous exudate, which hung down and bathed the outer portion of the bulb. On the eyeball, half way between the outer

canthus and the outside of the limbus, was found a soft "mushy" tumour, apparently of subconjunctival origin, about 7 mm. in its horizontal diameter and 5 mm. in the vertical, overlying the external rectus and in no wise limiting motion of the eyeball. The vision, 20/13, was often obscured by superabundant secretion of mucus.

He was admitted to the Hospital, and on January 1st, 1911, was put on mixed treatment while waiting for a report. Locally, the eye was irrigated with 1 to 10,000 solution of cyanide of mercury every two hours, and 2 per cent. yellow oxide of mercury ointment applied. Hot boric acid applications for fifteen minutes were made every two hours. Mercury frictions were given until January 7th, when all treatment was discontinued except the cyanide irrigations. Wassermann reaction was reported negative. On January 7th, the eye being cocainized, the growth from the lower lid was removed close to the conjunctival surface, also that on the upper lid and part of the tumour of the eyeball. These were placed in separate bottles and properly labelled. There was little bleeding and all three areas were cauterized with the actual cautery. For several days the eye looked better. On January 16th all the original treatment was renewed, and by the 23rd the growth seemed to be recurring in all three places.

Report from the first specimens showed that those from the lids were negative, being absolutely without character. That from the eyeball contained tubercle bacilli, a few in the superficial portion. In the second set of specimens the report was indefinite, but suggested the probability of malignancy.

When the report of the possibility of tubercle was received, the patient was subjected to tuberculin tests. von Pirquet and Moro were negative, but Koch's tuberculin was given at intervals for several weeks.

A complete examination of refraction and by the perimeter and ophthalmoscope on January 23rd showed 20/13 vision in each eye, Jaeger 3 for near, and, with proper correction for near, Jaeger I. Slight limitation of outer and lower portions of field. The ophthalmoscope showed hyperæmia of the nerve head and retina, the cornea was clear, the anterior chamber was slightly shallow, the pupil was contracted. At this time the patient complained of very severe pain in his right side. This, however, proved to have no bearing upon the local condition.

Other specimens were removed on February 4th. That from the eyeball was reported as spindle-cell sarcoma.

On the 8th, there was sufficient recurrence to again remove some for microscopic examination. They were now broader and flatter than before and there was more congestion of the vessels surrounding. This time the report was probably epithelioma of the specimen removed from the eyeball, the others being negative.

In the face of such varying opinions of the character of these growths, radical interference seemed contra-indicated.

On February 25th, the tumour of the eyeball was excised well down to the base, upon which the cautery was used. At other times during the next two weeks, this portion of the bulb was cauterized under cocaine. The patient was allowed to return to South Western Virginia on March 15th.

On the 26th he returned. The tumour of the eyeball was quite small, though the area overlying it was still red. The eyeball looked almost normal. The growth on the lower lid was about the same size as when first seen. It was excised and part of it placed within the peritoneal cavity of a guinea pig, and another portion placed in the anterior chamber of its eye. The results were negative.

On April 25th the eye was quite normal, but the growth on the upper lid had grown somewhat larger, while the growth on the lower lid remained the same size. The growths were removed, and he was given yellow oxide of mercury ointment to use at home as he had previously been using boric acid ointment to keep the movements of the lids facile and the eyeball clean.

He was again seen August, 1911, when the condition was practically the same.

On May 17th, 1912, he returned to the city and came to my office, and, because of its nearness, I sent him to the Episcopal Eye, Ear, and Throat Hospital. The eyeball was clear and the vision normal. The upper lid was everted with some difficulty and presented a growth similar in character and covering almost all the conjunctival surface. It was firmer but still grey in colour, slightly vascularized near the margin, still sessile, the margin could be raised and a probe passed all around it to about the depth of 3 mm. That afternoon at the Hospital, part of the tumour of the upper lid was removed down through the mucous membrane to the cartilage and was sent to the laboratory of the Army Medical School. It was diagnosed by Major Russell as previously quoted. It would seem that the larger size and greater firmness of the growth had given it sufficient character for definition and identification.

As this was the first diagnosis indicating definiteness in the arrangement of cells and fibres among the several specimens of the growth from the lids which had been sent to the laboratories, and from the lack of any similarity to other tumours which occur occasionally in the lids (including gumma, primary chancre, sarcoma, epithelioma, fibroma, etc.), the diagnosis certainly seemed reasonable.

On June 17th, believing the growths to be malignant as are angio-sarcomata, cylindromata, and endotheliomata, they were removed, together with the mucous membrane and the cartilage overlying, except for those portions containing the lashes and puncta. The conjunctiva of the *culs-de-sac* was dissected away from the ball to some extent, the loosened portions were brought up and down and united to the remnants of cartilage and mucous membrane.

After this there was good motion in the lids, and the swelling in and around them subsided. The growths returned at the junction of the cartilage with the lid along the line of the previous incision entirely across from the outer to the inner canthus. The vision of the eye remained normal. He was allowed to go home July 3rd. All went well with him, and I had intended to present the patient at this session, until July 29th, when I found the cornea dull and the superficial layers slightly opaque below the horizontal meridian due to mechanical irritation of the tumor of the lower lid.

On August 3rd, the cornea was becoming vascularized at the limbus below, and an ulceration had occurred in the superficial layers of the cornea. The tumours of the lids were increasing in size. The eye was becoming quite inflamed, and it was decided to have him return to the Hospital. Within the next week the eye became very painful, and it was determined that it was best to do a complete exenteration.

On August 12th, on examination, the bulbar conjunctiva was very red, vision had decreased to good projection, the cornea was beginning to be like ground glass, and there was an ulcer of the cornea from the horizontal meridian down almost to the limbus. With the ophthalmoscope, the fundus reflex was present but no detail visible. The eye was very painful. The growths on both lids were increasing, the lower lid was everted by the growth, and the upper one was also turning out. At two o'clock in the afternoon of the same day complete exenteration was done down to the periosteum. The skin at the outer canthus was divided and the skin of the

upper and lower lids, dissected away from the underlying tissues, was retained as a partial lining for the orbital cavity.

August 17th.—Patient is recuperating from the operation.

Remarks.

As to the probable outcome of this case, one might say that the chances for prolonged life were very good, in view of the fact that exenteration was done at a time when the only manifestation of the growth was the presence of tumours in the upper and lower lids. As far as is known, all glands communicating by lymphatic vessels with this part are perfectly normal in size.

There can be little doubt that the growth upon the eyeball was a granuloma, for it healed perfectly and the vision was not disturbed, nor was there any limitation of motion of the eyeball.

As to the growth on the lids, after repeated examinations of the specimens removed for examination during the early stages of the growth, with nothing characteristic being found, an examination made of the specimen removed on May 17th unmistakably showed perithelioma, and the more radical ones removed June 17th corroborated this fully.

BIBLIOGRAPHY OF PERITHELIOMA.

Zietzschmann.—*Ztschf. f. Thiermed.*, Jenna, 1904, Bd. VIII, S. 417.
Genotti, F.—*Ercolani*, Pisa, 1905, Vol. X, pp. 25, 47, 81.
Vignard, P. and Moriquand, G.—*Rev. de Chir.*, Paris, 1905, T. XXXII, p. 476.
Bevacqua, Gior.—*Med. d. r. Esercito*, Roma, 1906, Vol. LIV, p. 337.
Carless, A.—*Practitioner*, London, 1906, Vol. LXXVI, p. 228.
Bayon, P. G. E.—*Brit. Med. Jour.*, 1907, Vol. II, 1400.
Bruckner, J.—*Compt. rendu Soc. de Biol.*, Paris, 1908, T. LXIV, p. 966.
Palazzo, G.—*Clin. Chir.*, Milano, 1909, Vol. XVII, p. 781.
Roussy, G. and Arneuille, P.—*Semaine Méd.*, Paris, 1911, Vol. XXX, p. 385; also *Bull. de l'Assn. Franç. l'Etude du Cancer*, 1911, pp. 111, 143.
Pierre-Nadal.—Same journal, page 156.
Hektoen-Riesman.—*Amer. Text-book of Pathology*, 1902, p. 1076.
McFarland.—*Text-book of Pathology*, 1910, 226.
Adami.—*Principles of Pathology*, 1910, Vol. I, 824.
Coplin.—*Manual of Pathology*, 1911, p. 355.
Schiek F.—"Perithelioma of Retinal Vessels," Graefe's *Archiv f. Ophthalmologie*, Bd. LXXXI, S. 328.
Fleischer and Bertscher.—"Papillary Lid Sarcoma," *Klinische Monatsblätter für Augenheilkunde*, Mai-Juni, 1911, S. 689.

CLINICAL MEMORANDA.

A NOTE UPON ESSENTIAL OILS IN THE TREATMENT OF IRIDO-CYCLITIS.

BY

ARTHUR ZORAB,

SOUTHAMPTON, ENGLAND.

FOR the last nine or ten months I have been using essential oils in the treatment of iritis and cyclitis of non-specific origin, and have had most encouraging results. I am not sure that the subject is not worthy

of more detailed treatment. In this note, however, I wish to draw attention to the fact that the essential oil of cinnamon, cloves, or peppermint, given internally in doses varying from ♏ ii three times a day to ♏ iv every four hours, cuts short the duration of attacks of iritis and irido-cyclitis in a remarkable manner. I have used cinnamon oil more extensively than the others, but cannot say that it has any advantage. It has one disadvantage, being comparatively expensive. I have tried it in more than fifty cases in patients varying in age from ten years upwards, and have never once seen any ill effects. It is always prescribed in gelatine capsules, to be taken after meals—never on an empty stomach, or gastric pain may result. At the Free Eye Hospital at Southampton, all non-specific cases are, as a routine measure, put on to one of the above oils. Gonorrhœal cases respond very well, but the most dramatic results are seen in those cases where the original source of sepsis is obscure—such as we attribute to bad teeth, intestinal sepsis, etc., etc. I have also found great benefit from these drugs in a few obstinate cases of scleritis and interstitial keratitis.

It must, of course, be understood that in conjunction with these drugs, I have used mydriatics, warmth, cold, etc., locally exactly as used to be done before. But by substituting these essential oils for mercury and iodide, most cases are cured in three or four weeks *and some in a few days.*

The drug is continued for a month after all inflammatory signs have subsided with the hope that a recurrence may be avoided. My observations have not been of sufficient duration to offer an opinion on this point.

THIRTEEN CASES OF HEREDITARY TRANSMISSION OF RETINITIS PIGMENTOSA IN TWO GENERATIONS.

BY

GEORGE H. OLIVER,

BRADFORD, ENGLAND.

IT must be a rare event in the experience of most ophthalmic surgeons to meet with such a well-marked instance of the hereditary transmission of retinitis pigmentosa as is shown below.

In the history of the cases, as represented by the appended short family tree, ancestral consanguinity, one of the two principal factors in the production of this disease, is excluded. There are no symptoms of syphilis in any form in any of the patients.

The patient who consulted me was B. She complained that for many years she had been unable to see at night, and her vision had gradually failed to such a degree that now she was unable to read even large print by daylight.

Examination by the ophthalmoscope showed typical retinitis pigmentosa, almost entire absence of the retinal vessels, and advanced optic atrophy.

Enquiry revealed the fact that among her ancestors, as far as she knew, the patient's mother was the only one who suffered from night-blindness.

A brother and sister have the disease, and an unmarried sister, who died two years ago, was night-blind. The patient has five children, two boys and three girls: one boy and two girls are night-blind; her married sister has five children, two boys and three girls: one boy and all the girls are night-blind; her married brother has six children, three of each sex: two boys cannot see at night. Of these cases I have examined all except four, *viz.*,

the patient's mother and sister and two of the married sister's children. All those examined suffer from retinitis pigmentosa. From the account I received of those I have not examined, I have no hesitation in saying they are, or were, instances of the same affection.

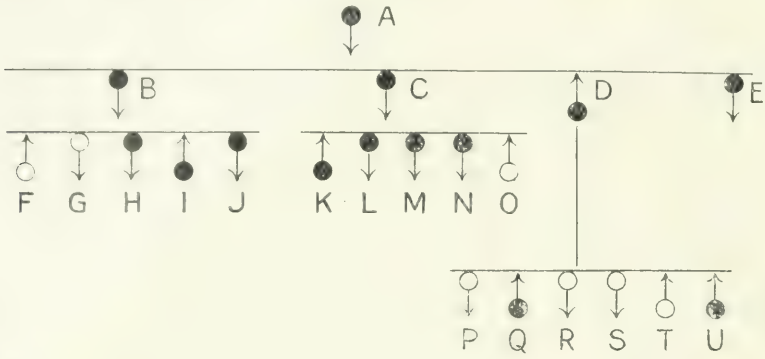

A and E are dead. These, as well as M and N, were not examined.

As the object of this memorandum is merely to put on record the occurrence of this serious disease in thirteen of twenty descendants in two generations from one ancestor similarly afflicted, no other details are given.

PATHOLOGICAL AND BACTERIOLOGICAL MEMORANDA.

RETINITIS PIGMENTOSA: A PATHOLOGICAL REPORT.*

BY

HANFORD MCKEE, B.A., M.D.

MONTREAL, CANADA.

ACCORDING to Greeff and Parsons, the first case of retinitis pigmentosa, or primary pigmentary degeneration of the retina, anatomically studied, was reported by Maes, who noted the adhesions between the retina and the choroid, and the displacement of the retinal pigment. Leber and Landolt next reported their findings, and, still later, cases were examined by Hirschberg, Wagenmann, Deutschmann, Burstenbinder, Greeff, Stein, Stock, and Lister. All the reports were similar (allowance being made for the different stages of the disease), in that the process was shown to be one in which the nervous elements of the retina had become atrophied, or perhaps disappeared, with displacement of the retinal pigment. The latter was insisted upon by

* From the Pathological Laboratory of the Montreal General Hospital.

Leber as the true anatomical basis of the disease, a view which Landolt supported. In a case studied by Lister, the vessels were very minute; the retina and choroid were intimately adherent, and in some places the choroid was adherent to the sclerotic. Close to the optic disc and macula were the only areas where any trace of normal retina was found. The layer of rods and cones was everywhere absent. Greeff describes his findings as follows: "In my case, which I can give as a typical example, the central parts of the retina, around the macula, were fairly normal, but between the ora and the macula there was a large zone in which one could see microscopically that the retina was adherent to the choroid. One would expect from this to find a ring scotoma, as in the case of Burstenbinder. I examined this case *in vivo*, but as the patient was demented, the field could not be proved. Both membranes had lost their structure, and from the pigment epithelium layer, which in certain spots failed entirely, the pigment had spread through all the layers of the



Fig. 1.

retina, and sat as thick clumps, in the circular lymph sheaths of the large vessels in the nerve fibre layer. There was a marked hyaline thickening of the walls of all the visible vessels, up to obliteration of the lumen. It is remarkable that not only in the retina, at the adherent areas, the nervous elements were missed, and a pure fibrinous structure with long drawn out cells remained, but also in the corresponding places in the choroid there was a similar atrophy with only some of the larger vessels recognizable. Also, outside of these areas, the choroid showed sclerosis of the vessels, as we often see it ophthalmoscopically."

Case.

Some time ago, W. W., an adult male, of about forty years, came to autopsy at the Montreal General Hospital, following a forty days' fast, or "water

cure." The autopsy findings were, fatty heart, fatty liver and kidney, passive congestion of the spleen, emphysema of the lungs, and retinitis pigmentosa. I am indebted to A. R. Pennoyer for notifying me about this case. The patient had been a farmer in a neighbouring township, where he had taken a prominent part in local affairs. He was a man of a high order of intelligence. As far as I have been able to find out, there was no history of syphilis or consanguinity of parents. Some years ago he consulted Dr. Buller, when a diagnosis of retinitis pigmentosa was made.

Pathological Report.

The posterior halves of the eyeballs were obtained, fixed in formalin, and cut in paraffin. For a short distance on each side of the optic nerve the retina seems fairly normal except that the layer of rods and cones is everywhere absent. The retina is entirely detached from the choroid at the point where the layer of rods and cones should be, but as only the posterior halves of the globes were obtained, the separation

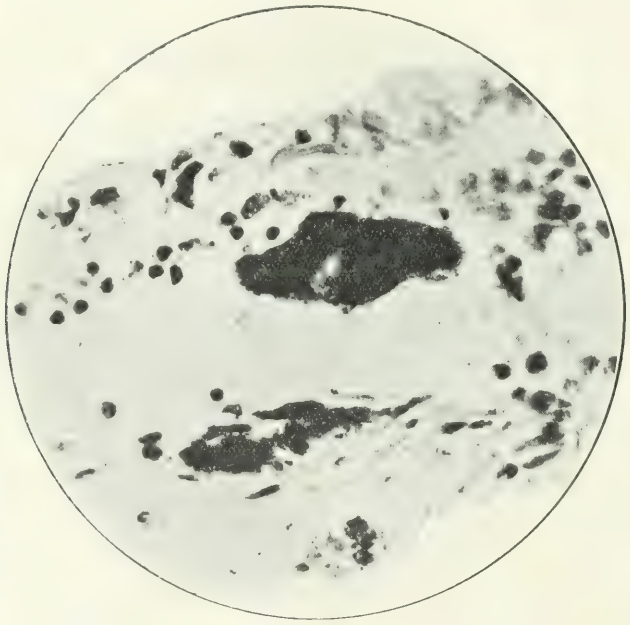

Fig. 2.

and absence of the layer of rods and cones may be due to manipulation during removal. The external part of the choroid is firmly adherent to the sclerotic, and marked by linear deposits of pigment. The vessels of the choroid are noticeably elongated and dilated, and the endothelial lining of many of these is deeply discoloured with pigment. Other vessels are entirely free, although there is a perivascular deposition of pigment everywhere. Here it seems definitely a deposit in the perivascular lymph channels, as it tends to mark out the latter distinctly. The retina varies a good deal in centre and periphery, but through the whole length of it, a noticeable feature is the increase in thickness of the nerve fibre layer. In some places it is equal to half the width of the whole retina. There is a marked atrophy of the whole, which is most complete in the anterior layers. There is not

only atrophy, but in some places the retina is not a histological unit. Degeneration is marked, especially towards the periphery, the retina being in much the best state of preservation at the centre. The contrast between centre and periphery is sharp. The striking histological change is in the position of the retinal pigment. It is easily seen that the pigment forms a layer around the vessels, that it is contained within the endothelial cells, but there is also pigment in the tissue spaces. It is probable that the pigment has been brought forward by the lymphatics and blood vessels, whose endothelial lining has taken it up, causing the latter to stand out as a browny black tube. There is marked fibrosis of the areas where the pigment is deposited to replace the degenerated nerve tissue.

There are no inflammatory signs noted anywhere. The fibres of the optic nerve are thickened by œdema, although there is no cellular exudate.

Figures 1 and 2 are microphotographs, of different magnification, which show well the degeneration of the retina and the deposits of pigment.

REFERENCES.

Greeff.—Orth's *Pathologische Anatomie*, Bd. II, S. 378.
Parsons.—*The Pathology of the Eye*, Vol. II, p. 602.

A CASE OF SEPTIC ENDOPHTHALMITIS ASSOCIATED WITH THE DIPLOCOCCUS LANCEOLATUS.

BY

SYDNEY STEPHENSON,

LONDON, ENGLAND.

Case.

Lucy———, aged six weeks, was brought to the Eye Department of the Queen's Hospital for Children, London, on September 10th, 1908, with the history that both eyes had become inflamed on the third day after birth. The ophthalmia had been treated with boric lotion by the medical man who attended the confinement.

The baby (born in the seventh month), when brought to the Hospital, was small for her age (six lbs.), and was obviously in a poor state of health. There were then no particular signs of ophthalmia, such as discharge from the eye, although both corneæ had been damaged by the disease. As regards the right cornea, the iris was entangled in a perforated ulcer, which had a transverse diameter of about 3 mm., and which involved the central part of the cornea. A mushroom-like mass (5 mm. by 3 mm.), of pinkish colour, issuing from the perforation, doubtless represented a bead of granulation tissue growing from the prolapsed iris, and constricted by the aperture through which it passed to reach the outside. As regards the left cornea, a small adherent leucoma lay toward the centre of the lower third, and the entangled iris was seen as a black speck, surrounded by a whitish rim.

The granulation of the right cornea had become considerably smaller by September 25th, and on October 8th, it was no longer visible, having become incorporated in the leucoma. At that date there was little difference in the appearance of the two eyes, in each of which the upper part of the pupil was free from entanglements. The position of the incarcerated iris was in each case shown by a black speck. Before the baby left the Hospital, an upward iridectomy was performed upon each eye (January 5th and 28th, 1909). A satisfactory coloboma was obtained in the case of the left eye, but in the right,

only a small gap in the iris resulted from the operation. The child was discharged on February 4th, 1909, after a stay in Hospital of about five months.

Nothing was seen of the patient for some twenty-one months, when she attended the out-patient department on account of a mild phlyctenulosis. The condition not improving under the usual remedies, she was admitted as an in-patient four days later (November 28th, 1910). At that date, there was a large phlyctenule in the lower part of the limbus of the left eye, accompanied by photophobia and a watery discharge from the eye. A small ulcer, thought to be of phlyctenular origin, lay over the leucoma adherens. The child's temperature was normal, but despite a slight cough and poor general condition (weight, 21 lbs. 8 ozs.), no physical signs could be found in the chest or elsewhere.

Four days after admission, the clinical picture had changed entirely. The lids of the affected eye had become red and œdematous, and on opening the eye, thickish pus escaped from the palpebral fissure. Micro-organisms could not be found in films taken from the discharge, which merely contained polymorphonuclear leucocytes and a very fibrinous ground substance. Five days later (December 7th), the left eye was somewhat proptosed; pus was seen in the anterior chamber; and inflammatory symptoms had become more pronounced. A diagnosis was then definitely made of *Septic Endophthalmitis.*

On the following day the contents of the suppurating eyeball were eviscerated, and the material thereby obtained was sent for report to Dr. A. W. G. Woodforde, the Hospital Pathologist. From the onset of the septic complication to evisceration of the affected eyeball, the temperature, although never above 99·2° F., touched normal on one occasion alone. On the morning after operation, it sank to 97·8° F., and remained normal (save once) during the rest of the child's stay in Hospital.

The patient made a speedy and uneventful recovery, and was finally discharged from Hospital on December 24th, 1910.

Bacteriological report..

Dr. Woodforde reported that the examination of films showed *débris* of the tissues of the eye, leucocytes, and an organism resembling the diplococcus lanceolatus. In cultures a pure growth was obtained of the same organism, the identity of which was established beyond peradventure by further experiment.

Comments.

It must remain a matter for conjecture whether the ophthalmia from which the baby originally suffered was or was not caused by the pneumococcus. From the grave results as regards the corneæ, however, it was more likely to be due to the gonococcus, although severe cases of pneumococcal ophthalmia are by no means unknown in babies. The endophthalmitis evidently resulted from exogenous infection reaching the interior of the eyeball through the small ulceration observed on November 28th to be present over the adherent leucoma of the left cornea. This is a well known danger of such corneal conditions. Iridectomy (as performed on January 5th and 28th, 1909) may avert the probability of secondary glaucoma, but it can never shelter the eye against the risk of inoculation through the adherent cicatrix. If the original ophthalmia were caused by the pneumococcus, it would raise interesting questions as to the latency of that organism, and its bearing upon the infection of the cornea, which took place at a long subsequent date.

Under any circumstances, the case seems worthy of report, inasmuch as the identity of the pneumococcus, obtained from the contents of the eviscerated eyeball, was proved up to the hilt.

NOVELTIES.

A NEW CUTTING CYSTITOME.

BY

F. R. Cross, M.B., F.R.C.S.,

CLIFTON, BRISTOL, ENGLAND.

The use of a blunt cystitome in cataract extraction is a danger, by tending to fix and displace the lens, rather than cutting or tearing the capsule, and the ordinary Graefe cystitome has the same tendency.

I have been using and am well satisfied with a new *cutting cystitome*, made for me for Messrs. Weiss.

It consists of a narrow double-edged knife, 5 mm. long, one edge cutting in the whole length, the other for 2 mm. at the point.

The woodcut represents what appears to be the most convenient type. We have tried it slightly varying in width and length, and with different degrees of angle between the blade and the shaft. It will be found to pass readily through the capsule and along the lens in any desired direction.

CURRENT LITERATURE.

NOTE.—Communications of which the titles only are given either contain nothing new or else do not lend themselves to abstract.

I.—STREPTOTHRIX OF THE EYE.

Calderaro.—On the action of the varieties of streptothrix on the eye, with special reference to reaper's keratitis. A clinical and experimental study. (Sull'azione delle streptotricee nell'occhio con particolare riguardo alla cheratite dei mietitori Richerche cliniche e esperimentali.) *La Clinica Oculistica*, Gennaro-Feb., 1913.

Calderaro, in 1903, confirmed the results obtained by other investigators as to the almost constant presence of Fränkel's diplococcus in "reapers' keratitis" (a special form of hypopyon-ulcer), although he pointed out that the negative result obtained by sero-therapy threw doubt on the relationship. This diplococcus is an almost constant guest in the conjunctiva, and it seemed strange that no wounds other than those produced by such small injuries as reapers receive from the ears of corn should be followed by hypopyon-keratitis, if Fränkel's coccus were the sole cause. He therefore

made researches into the nature of the wounds and of the bodies which produce the lesion, but the sole finding of importance was that streptothrix was a constant inhabitant of the wheat-ear. As a result of the renewed experiments which are recorded in this paper, he concludes that the streptothrix has a causal relation to the hypopyon, both by preparing the ground after an injury for the reception and growth of the diplococcus and also by increasing the virulence of this germ.

He finds that not all streptothrices have the same virulence; but that when the cornea of a rabbit is inoculated with a streptothrix, whatever its virulence, the inoculated germ is replaced, within twenty-four or forty-eight hours, by the diplococcus of Fränkel or by the S. pyogenes.

When the streptothrix is virulent, the resulting inflammation is severe, but when the streptothrix is innocuous, the course is the same as if it were absent.

The conditions necessary to bring about in the rabbit keratitis similar to that observed in reapers, are three: there must be an abrasion of the cornea with implantation of fragments of the teeth of the husk or "beard"; there must be development of a streptothrix of some virulence; and, lastly, there must be a secondary inoculation of the diplococcus or of some other germ.

Calderaro divides the streptothrix into three groups: (1) alba which is largely diffused, and is an innocent saprophyte; (2) certain strains of chromogena, which are moderately virulent; and (3) the strains of chromogena and violacea, whose virulence is great. HAROLD GRIMSDALE.

II.—ÆTIOLOGY OF LACRYMAL AFFECTIONS.

Brunszlow.—A contribution to the ætiology of chronic affections of the lacrymal apparatus. (Beitrag zur Ætiologie der chronischen Erkrankungen der träuenableiten den Wege.) *Zeitschrift für Augenheilkunde*, Mai, 1913.

Brunszlow, a rhinologist, working at Bonn, has made careful examinations of the nose in sixty-three cases of lacrymal disease. Kuhnt has expressed the opinion that in almost every case of dacryocystitis there is a nasal origin, generally a sinusitis. In most cases, the antrum of Highmore is at fault, but the anterior ethmoid cells are constantly implicated. Kuhnt says that the sinus maxillaris should always be carefully examined. Gerber and Kuhnt, after further research, concluded that the anterior ethmoids were even more frequently diseased than the antrum. Rhese came to the same conclusion. Dacryocystitis is caused not so much by changes in the inferior meatus and turbinals as by a chronic anterior ethmoiditis. Brunszlow obtained the following figures.—In forty cases, that is, 65·5 per cent. of all the cases, there was a definite affection of the nasal sinuses. In three there was a para-sinusitis; in three, sinusitis of the frontal sinus, the maxillary sinus, and the ethmoid cells; in three, of the maxillary and ethmoid cells; in eighteen there was ethmoiditis, with a suspicion of affection of the antrum of Highmore, and in eighteen the ethmoid cells were alone implicated. In 22·2 per cent. of the remaining cases the sinuses were suspected of being diseased. In 11·3 per cent. there was endo-nasal disease of other kinds, and in only 3 per cent. of the cases was the nose normal!

The foregoing figures are worthy of careful study. For some time past the reviewer has submitted all our cases to an expert rhinologist for examination, and in not one of these has sinusitis been reported. In a small percentage of the

cases distortion of the inferior turbinal has been treated, and one or two have had atrophic rhinitis (ozœna). A careful study of the paper makes it evident that definite empyema of the sinuses was not often found—there were "suspicious secretions," "changes in the mucous membrane," and "hazy Röntgen ray pictures." When the ethmoid cells were opened, they were found to be soft and "mushy" (*morsch*), and the endothelial lining was diseased. Generally speaking, it is only necessary to consider the antrum and the ethmoid cells, and in every case these must be examined with the minutest care and X-Ray pictures carefully considered. We gather that at Bonn in most cases the ethmoid cells are opened out before anything else is attempted. The question arises whether such a painful proceeding is really justified, because this chronic ethmoiditis seems to do no harm to the patient and most purulent sacs have eventually to be extirpated if an aseptic conjunctival sac is to be obtained. At Bonn Kuhnt often excises the sac and does a radical ethmoidal maxillary operation by the external route (Jansen). In the reviewer's experience, simple extirpation of the sac cures the patient. T. HARRISON BUTLER.

III.—TOXÆMIA (ALIMENTARY AND ORAL) AS A CAUSE OF EYE DISEASE.

(1) Calhoun.—Acute retrobulbar neuritis caused by an intestinal toxæmia. *Ophthalmic Record*, March, 1911.

(2) Shoemaker, J. F.—Some further observations on the ætiology of certain cases of conjunctivitis and asthenopia. *American Journal of Ophthalmology*, May, 1911.

(3) Villard.—Irido-choroiditis following gastro-enteritis in infants. (Irido-choroidite consécutive à la gastro-entérite des jeunes enfants.) *Archives d'Ophtalmologie*, juillet, 1911.

(4) Risley, S. D.—Intestinal sepsis as an ætiologic factor in cardiovascular disease and associated ocular affections. *Ophthalmic Record*, November, 1911, and *Trans. Amer. Ophth. Society*, Vol. XII, Part 3, 1911, p. 950.

(5) Risley, S. D.—Intestinal sepsis in ocular affections. *Ophthalmology*, January, 1912.

(6) Stuelp, O.—Is the so-called gastro-intestinal auto-intoxication (Indicanuria) a common cause of eye trouble? (Ist die sogenannte auto-intoxication (Indicanurie) eine haüfige Ursache von Augenkrankheiten?) von Graefe's *Archiv f. Ophthalmologie*, Bd. LXXX, Heft iii, 3 Januar, 1912.

(7) von Hippel, E.—Upon Indicanuria in Diseases of the Eye. (Ueber Indicanuria bei Augenkranken.) von Graefe's *Archiv f. Ophthalmologie*, Bd. LXXXI, Heft i, 13 Februar, 1912.

(8) Colombo, Gian Luigi.—Intestinal auto-intoxication in the pathogenesis of eczematous kerato-conjunctivitis. (Die Autodarmintoxikation in der Pathogenese der ekzematösen Keratokonjunktivitis.) *Klin. Monatsbl. f. Augenheilkunde*, November, 1912.

(9) Lang, B. T.—**The influence of septic infection in the causation of eye disease.** *British Medical Journal*, February 22nd, 1913.

(10) Lawford, J. B.—**A discussion on alimentary toxæmia; its sources, consequences, and treatment.** *Proceedings of the Royal Society of Medicine*, May 1913, p. 121.

(11) Clarke, Ernest.—*Ibidem*, p. 315.

(12) Lang, William.—**The influence of chronic sepsis upon eye disease.** *Lancet*, May 17th, 1913.

(1) **Calhoun**, of Atlanta, Ga., records a case of double acute retrobulbar neuritis in a boy, aged twelve years. Vision was reduced to 6/60, but there was no ophthalmoscopic change, beyond perhaps some pallor of the discs. The condition was ascribed to intestinal toxæmia, because the fæces showed evidence of undigested food, and the urine a trace of albumen and a considerably increased quantity of indol and skatol, urea 16·8, phosphates 2·61, chlorides 8·02. Treatment, by means of a buttermilk diet and Basham mixture, was followed by complete recovery in a little over a month. J. JAMESON EVANS.

(2) **Shoemaker's** (St. Louis) article is a continuation of a previous one in the same journal in January, 1910, an abstract of which will be found in THE OPHTHALMOSCOPE for 1910, page 464. He gives a number of interesting cases in which local treatment entirely failed, and in which treatment aimed at the elimination of digestive troubles was immediately successful. He is led to the conclusion that faulty metabolism, as well as intestinal auto-intoxication, is responsible for some of the stubborn cases of conjunctival irritation and asthenopia with which we meet. ERNEST THOMSON.

(3) **Villard**, of Montpellier, records two cases of unilateral plastic irido-choroiditis, one in a child of three years and the other in a baby of four months. Both suffered from a grave attack of gastro-enteritis, during the height of which slight redness of the eye was noted in each case, but disregarded as unimportant as compared with the general condition. The vision was subsequently lost in both cases.

Villard thinks that the ocular condition was due to toxæmia from intestinal micro-organisms. He has failed to find records of a similar case.

BERNARD CRIDLAND.

(4) **Risley,** of Philadelphia, quotes a number of ocular diseases which have a probable relationship to intestinal sepsis, among them phlyctenular ophthalmia of childhood. In this condition he says "the intestinal tract is often, if not always, the source of infection." He finds corroboration of this view in the fact that local treatment is usually unavailing until the fermentation and putrefaction going on in the bowels are prevented by suitable treatment and regulation of diet. The rebellious asthenopia of many young people who have fluffy, honeycombed choroid, fronto-occipital headaches, and impaired health, comes under the same ætiological category.

Three special cases of ocular affections due to intestinal toxæmia are cited:

CASE I.—A lady of 45 years suffered from rapid failure of vision, concentric contraction of the visual fields, advanced atrophy of one optic disc and œdematous haze of the other, which progressed eventually to atrophy, leaving her with just enough vision to enable her to get about alone in familiar surroundings. The only cause that could be found for the atrophy of the nerves was an impacted colon, following chronic constipation.

CASE II.—A lady of 65 years suffered from rapid failure of vision. R.V. = 6/30, L.V. = hand movements. Central fixation defective in each eye, owing to central scotoma. The right field was also concentrically

contracted at the periphery. There was advanced neuroretinitis in the left eye, and the disc was grey-red and opaque, with obscured margins and distended veins in the right eye. Blood pressure was increased to 172 systolic, and 145 diastolic. Auto-intoxication was regarded as the ætiological factor.

CASE III.—A man, aged 51 years, complained of impaired vision, attacks of general faintness with tachycardia, vertigo, extreme nervousness, and hallucinations. He suffered from gastro-intestinal troubles, but was a heavy eater and smoker. Central scotoma in each. Vision R. = 6/60 L. = 6/20 eccentrically, and some concentric contraction of the fields. Blood pressure 200 mm. Opthalmoscopically.—Right eye: macular choroido-retinitis, papillary haze, fundus red and fluffy. Web-like vitreous opacities. Left eye: macular area maroon coloured and "wooly with a granular nest at the fovea." There was a trace of albumen in the urine, a decided amount of indican, with hyaline and granular casts. Under a diet of skimmed milk and stale bread, purgation by sulphate of magnesia daily, and the administration of five grains of calcium chloride four times daily, symptoms rapidly improved. A more generous diet was afterwards allowed and he was given 1/100 gr. of bichloride of mercury with a nux vomica tonic after each meal, and in about five weeks, the symptoms had entirely disappeared. R.V. = 6/22, L.R. = 6/8. Blood pressure, 145 mm.

J. JAMESON EVANS.

(5) **Risley**, of Philadelphia, is of the opinion that ophthalmologists do not take sufficient account of the factor of auto-intoxication in the ætiology of eye conditions. Taking cataract as an example, he holds that many hard cataracts are caused by some general dyscrasia or some specific infection or auto-toxæmia. This explains many disappointments and disasters following correct surgical treatment. He advises postponement of operation until the intestine is free from toxic contents, the urine is of normal specific gravity and free from albumen, indican, and excessive acidity, and blood pressure is approximately normal. A. J. BALLANTYNE.

(6) It was Elschnig especially, who drew attention to the great importance of indicanuria as a clinical symptom of gastro-intestinal auto-intoxication in the causation of diseases of the eye. He even thinks that where tuberculosis and syphilis have been positively established, the absence of other specific symptoms renders it very doubtful whether the eye-trouble is really directly traceable to these agents and not really due to auto-intoxication.

Stuelp, of Mülheim, a.d. Ruhr, subjected all his cases of iridocyclitis (82 in all) to careful examination as to their ætiology, but could find no confirmation of Elschnig's suggestion. At the most, it could be argued that indicanuria might help or hasten the production of a disease which is really due to other influences, but even then only if it has been of considerable duration and severity. It will be always most important to direct our therapeutical resources towards combating the original trouble, especially as our modern methods of diagnosis make the specific treatment more rational and effective.

R. GRUBER.

(7) **von Hippel**, of Halle, returns to this question and considers that, contrary to Elschnig's assertion, indicanuria does not play any considerable part in the causation of eye troubles. Amongst 416 cases the reaction was positive 16 times only, and even there a different ætiology seemed often enough to be much more plausible. R. GRUBER.

(8) **Colombo**, of Parma, in a former paper, reached the conclusion that in individuals predisposed to eczematous kerato-conjunctivitis the changes are excited by the presence in the circulation of substances due to intestinal intoxication. Taking the indican reaction of the urine as evidence of the

existence of a state of intestinal intoxication, the researches of von Hippel led him to attribute less importance to this than the present author, but Colombo's further investigations have confirmed his previous conclusions as to the frequency with which a pronounced indican reaction is given by the urine of these patients. He emphasises the importance of testing the urine early, before the institution of treatment, and of testing it frequently. He quotes cases to show how the excessive indican reaction may disappear with improvement of the eye condition, and return during the relapses. Of 115 cases of eczematous kerato-conjunctivitis which he has investigated since the date of his last paper, 82·6 per cent. gave a strong or pronounced indican and urorosein reaction, while 17·4 per cent. gave a trace or none.

A. J. BALLANTYNE.

(9) One of the various reasons for not abstracting an article very fully is that it is of such importance that it should be read in the original, and another occurs when the article is readily accessible. Both of these reasons are present in the case of the very suggestive article by **B. T. Lang**, of London, on septic infection as a cause of eye disease. Basing upon an analysis of 176 cases (of which 172 occurred in the practice of his father), Lang suggests that many of the inflammatory lesions of the eye, classed as regards any particular case, as gonorrhœal, syphilitic, rheumatic, myopic, diabetic, and so on, are infective, and depend for their origin on some septic focus from which the exciting substance travels to the seat of the disease in the sclera, the cornea, the ciliary body, the choroid, or the iris. Direct evidence is unobtainable for the proof of this view, because no eye is excised during the onset of the acute stage. The evidence is that obtained by treating the supposed source of the infection and thereby curing or ameliorating (in most instances curing) the disease. One of the most remarkable facts brought out by Lang, is that in 71 cases out of the 176 buccal sepsis was traced as the cause. "It may be worthy of note that the areas of septic infection which are found by analysis of these 176 cases to give rise most often to eye troubles are those that are subjected to frequent mechanical disturbance. For example, infection of the gums, which are massaged at each meal, or of the male urethra, which is continually disturbed during micturition, are each more productive of eye trouble than infection of the mucous membrane lining the frontal or any other sinus, or of the cervix uteri."

The individual cases quoted by Lang in support of his view may well be left for the reader to study in the original. ERNEST THOMSON.

(10) **Lawford**, of London, discusses, from a detached and eminently judicial standpoint, what may be conveniently called the "septic" origin of certain eye diseases. It really amounts to a study of the evidence so far adduced, and as such is valuable to those who (like the reviewer) have not already quite made up their minds on this somewhat vexed question

The numerous observations recorded during recent years "render it increasingly probable that alimentary toxæmia is a contributory factor, if not the sole agent, in inducing these lesions." Auto-intoxication from the alimentary tract as a cause of diseases of the eye may be looked upon as a good working hypothesis, and one that helps to explain the clinical appearances of some diseases, especially of the corneo-sclera and the uveal tract, better than any other. As to the relationship between oral sepsis and diseases of the eye, Lawford apparently regards as proved the dependence of some forms of mild chronic irido-cyclitis upon pyorrhœa alveolaris. At the same time he does not omit to mention the several facts that most persons in whom pyorrhœa alveolaris exists do not suffer from irido-cyclitis, and, contrariwise, that irido-cyclitis with similar

characteristics is met with in patients whose mouth and teeth are above suspicion. The dependence of episcleritis, scleritis, and sclero-keratitis upon a similar cause does not appear to him to be so certain. At all events, his personal experience of the diseases named does not support any such view of their ætiology. "Careful and thorough treatment of the mouth has frequently failed to exert any beneficial influence upon the ocular conditions, and vaccine treatment has in most instances been disappointing."

Lawford agrees that some forms of localized exudative choroiditis may be one of the consequences of pyorrhœa alveolaris. It is, however, certain that the condition often occurs in patients free from Rigg's disease or other septic conditions of the mouth. Lawford has yet to see any example of widely-spread choroidal disease in which oral sepsis seemed to be a likely factor.

The relationship between ocular diseases and enterogenous toxæmia opens up more complex questions. We cannot see what is going on in the intestine, and laboratory tests for putrefaction are not yet altogether trustworthy. It is nevertheless likely that in a proportion of cases of inflammatory diseases of the eye, in which syphilis, rheumatism, gout, and gonorrhœa can be excluded, intestinal toxæmia may be the cause. But this is not the same thing as saying that toxæmia should be accepted as the cause for all cases that cannot be accounted for in other ways. In a sense, cataract may be due to intestinal toxæmia, the link intermediate between the two conditions being chronic uveitis. In episcleritis and sclero-keratitis, if tubercle may be put on one side, the possibility of their dependence upon toxæmia should be considered. Cases are on record which suggest the toxæmic origin of some forms of inflammation of the optic nerve, although such a connection has been denied by good authorities, as Uhthoff. As in a striking case by Wirtz (1907), some obscure cases of retro-ocular neuritis may be attributable to auto-intoxication. Lawford thinks it by no means improbable that recurrent vitreous hæmorrhage in young men may be due to the consequences of intestinal stasis. The further investigation of these cases, with the help of modern laboratory methods, should be undertaken. The possible dependence upon alimentary toxæmia or oral sepsis of the delayed irido-cyclitis that sometimes follows extraction of cataract and other operations upon the eye is touched upon.

Lawford concludes a philosophical article with the following words: "I think I may state, without fear of contradiction, that even if positive proof of the dependence of certain ocular lesions upon alimentary toxæmia is still wanting, much evidence from clinical and laboratory investigation may be adduced in support of the contention. It is therefore incumbent upon us so to pursue our investigations that we may ultimately be able to dispel the doubt which now exists as to the effect of alimentary toxæmia upon the eye."

SYDNEY STEPHENSON.

(11) **Clarke**, of London, traces premature loss of accommodative power and sclerosis of the lens to intestinal stasis, for the relief of which he has great belief in the administration of petroleum oil. Experience has taught him the importance of obtaining a clean mouth and tongue, and of emptying the bowels, as a first step in the treatment of all diseases of the eye.

SYDNEY STEPHENSON.

(12) The contribution by **W. Lang**, of London, to the discussion on alimentary toxæmia at the Royal Society of Medicine is of the utmost importance. Lang's attention to the subject of oral sepsis began after the observation of Wm. Hern that pyorrhœa alveolaris is a cause of acne rosacea. From this time onwards (though the date is not stated), Lang examined the

gums in all the cases of inflammatory infections where the ordinarily accepted causes of the disease were absent, and came to realise that pyorrhœa caused inflammation in every part of the eye. The next step was to look for sepsis elsewhere when pyorrhœa was absent. He then recognised that the source of sepsis might be in any of the mucous membranes, in a chronic sore on the skin, or in a sinus opening on the skin or on a mucous surface. So far he has failed to discover the exact nature of the poison.

An examination of 10,000 private case records has afforded astonishing results, for, out of this number it was found that 215 cases of eye inflammation were due to sepsis, while only 168 were attributed to other causes. Tabular statements are given which show that of the 215 septic cases, 139 were due to pyorrhœa, 33 to infection of the large intestine, 20 to disease of the male urethra, and small numbers only to disease of the lacrymal sac, antrum of Highmore, nose, tonsils, appendix, kidney and bladder, uterus and appendages, skin, and to "indigestion."

Of the 215 septic cases, the iris was the part of the eye affected 87 times, the ciliary body 79, the choroid 68, the retina 28, the sclerotic 20, the lens (secondary cataract) 14, the cornea 12 times, and there were 3 cases of detached retina, and 4 of optic neuritis or atrophy.

In accordance with the size of the figures for pyorrhœa, most of the paper is concerned with the importance of the elimination of this factor in treating inflammatory eye disease. It seems incomprehensible to Lang that a surgeon, whose single aim is to avoid sepsis in his operations, can think it a matter of no importance that a person should have a chronic source of sepsis in any part of the body. With regard to the usual objection made to this idea of the importance of pyorrhœa, namely, that one sees many bad cases of pyorrhœa in people who are apparently in good health, Lang points out that Nature begins to raise a protecting barrier the moment that the tissues are irritated by bacterial toxins or are invaded by the bacteria. The enormous number of cases of pyorrhœa that one sees and the comparatively small number of diseases resulting therefrom, shows how very efficient Nature's barrier is. Lang considers that the present teaching of the dental profession with regard to the crowning of teeth and the building of bars and bridges that cannot be kept clean is responsible for pyorrhœa and loss of sight. If the Zulu habit of cleaning the mouth after every meal were taught in early childhood, and practised throughout life, there would be fewer blind eyes and much less ill-health in the world. With regard to treatment of the pyorrhœa, when the protecting barrier has broken down, and the eyes are affected by a serious inflammation which may destroy the sight, it is then too late to do anything except to remove the teeth at once. Before the extraction, the gums should be carefully cleansed and treated with antiseptics in order to reduce the amount of septic absorption from the tooth sockets. If the sight is to be restored in a recent case of keratitis or of central choroiditis, the affected teeth must come out, on the chance that they are the cause, and if the inflammation does not then subside, other possible causes must be investigated. Then, again, the question of the presence of a septic focus should be remembered before operations on the eye, and, if found, it should be treated.

A number of illustrative cases are given in this most interesting article, the abstract of which may be concluded with the following quotation:—"I am convinced that central senile choroiditis is no more caused by old age than is the senile edentulous jaw; both are due to pyorrhœa, and if the mouth were looked after from youth onwards, two of the attributes of old age, *sans teeth*, *sans eyes*, would not occur." ERNEST THOMSON."

IV.—VON HIPPEL'S DISEASE.

Frenkel.—Capillary angiomatosis of the retina. (Angiomatose capillaire de la rétine.) *Ann. d'Oculistique*, mars, 1912.

Frenkel, of Toulouse, gives a detailed history of a case of capillary angiomatosis of the retina occurring in a man, aged 24 years. The affection came on very insidiously in both eyes at the same time, causing at first a sensation of mist in front of the eyes, followed in about a year, by diminution in visual acuity, while scotomata developed in the periphery of the visual field. The abnormal appearances seen ophthalmoscopically at an early stage of the disease were small clear spots, more or less distant from the optic disc, situated between afferent and efferent vessels. These enlarged by degrees, while at the same time the vessels between which they were situated became more apparent, so that when the spots reached a certain size, the arteries and veins corresponding to them were dilated and tortuous. At this stage there were spots into which more than two vessels opened, and in some instances two spots were connected by dilated vessels.

The author gives *résumés* of eighteen cases of this rare disease, which he had found recorded in ophthalmic literature, and from which he draws the following conclusions.—There is a tendency to bilaterality, and the onset usually occurs in early life, the greatest age at which it has been noted being 36 years. The length of time during which the cases were kept under observation varies from five to six months to five years, but eyes blinded by the disease have been removed thirteen and sixteen years after the onset. The earliest symptoms were fogs, mists, grey clouds, greenish spots, and, in one instance, rainbows around luminous objects. These may be accompanied by scotomata. Later, the vision begins to fail, and the fields for white and colours become contracted in sectors or irregularly. The predominant feature of the disease is the ophthalmoscopic appearance, which is more characteristic the earlier the case is seen, and which consists in: (1) distention and tortuosity of one or more retinal arteries and veins with an alteration in their walls which makes it impossible to distinguish between arteries and veins; (2) the formation of characteristic round, oval, or fusiform areas, varying from sizes barely visible to spots three disc-diameters in size. These may be reddish, yellowish, or whitish in colour, and are intercalated on the course of the distended vessels in such a way that vessels are seen entering and leaving them, but not crossing or passing through them. They may be raised above the surface of the flat and may vary in size and colour, but their relation to the distended vessels is constant from their very first appearance. As the case progresses, these appearances become modified by the presence of whitish streaks, and fresh or old retinal hæmorrhages in the neighbourhood of the vessels or in the macula region. These lesions continually invade fresh parts of the retina, with a tendency to spread towards the equator and anterior segment of the globe. Ultimately, the fundus presents the appearance associated with detachment of the retina, except that the vessels are perhaps larger and more numerous. All cases, which have been watched sufficiently long, have ended in blindness, with either secondary glaucoma or diminished tension. For the pathology of the condition we are dependant on the examination of six eyes, three by Treacher Collins, two by Czermak-Ulbrich, and one by von Hippel, which show that the diseased areas consist of masses of capillaries which give rise to gliomatous proliferation with ultimate formation of a thick fibrous partially ossified shell, adjacent to the choroid.

R. J. COULTER.

V.—OPHTHALMIA NEONATORUM.

(1) Dalmer.—Involvement of the middle ear in a case of gonorrhœal conjunctivitis of the new-born. (Ueber Mittelohrbeteiligung bei einem Fall von gonorrhoischer Konjunktivitis eines Neugeborenen.) Deutschmann's *Beiträge zur Augenheilkunde*, Heft lxxxi., 1912.

(2) Stephenson, Sydney.—On the duty of the practitioner in cases of ophthalmia neonatorum. *Lancet*, November 16th, 1912.

(3) Harman, N. Bishop.—The incidence of ophthalmia neonatorum in London. *British Medical Journal*, May 24th, 1913.

(1) The case reported by **Dalmer,** of Giessen, was that of a female infant in very poor health, in whom discharge was noticed from both eyes on the fifth day after birth. Opacity appeared in the right cornea thirteen days later, and on the twenty-first day of illness, there was great increase in the purulent secretion, associated with the onset of a severe purulent rhinitis. On the thirty-second day of illness, suppuration set in in the left ear. The nose and ear discharges contained Gram-negative diplococci (*believed* to be gonococci) and Gram-positive diplococci. Both corneæ perforated, and both lenses were lost. The child was removed from hospital after two months, when discharge was still active, and died shortly thereafter. The author looks upon the nasal and aural affection as due to a mixed infection of gonococci and staphylococci. A. J. BALLANTYNE.

(2) The general medical practitioner assuredly ought to be grateful to **Stephenson**, of London, for this most pithy and concisely written contribution to his knowledge on the subject of ophthalmia neonatorum. It is probably safe to say that nothing quite so good in such a small compass has been written since the era of notification began.

The introduction deals with the methods of infection and the organisms concerned, with special reference to the gonococcus. "It is important to note that all the micro-organisms associated with ophthalmia neonatorum are known to occur in the genito-urinary passages of pregnant or parturient women, and that the same microbes have been found in the male urethra. In the ultimate analysis every case of opthalmia may therefore be said to have originated from the male."

The author then deals in succession with prevention, notification, and treatment.

With regard to prevention, he urges medical men to note that recent investigations have shown that the disease is quite as common in confinements attended by medical men as in those by midwives. Midwives are compelled to adopt well-known preventive measures, but medical men are left free. The occurrence of this, in most cases, eminently preventable disease reflects no credit on whoever is in charge of the labour. Preventive measures are then detailed and preference given to the 1 per cent. silver nitrate solution for instillation. The treatment, familiar to ophthalmic surgeons, is given for ordinary cases in which the cornea is not involved and the practitioner is recommended, if possible, to seek skilled advice should such ulceration occur. For himself, in corneal ulceration the author prefers eserine to atropine, and if the case does not improve, he proceeds to the actual cautery.

For routine cleansing Stephenson strongly upholds the use of Merck's perhydrol either pure or diluted with an equal quantity of freshly boiled water. The *débris* left by the perhydrol can be readily washed away by any ordinary lotion.

Attention is called to the late infection with Morax-Axenfeld bacillus which we have now all learned to look for. If the reviewer is not mistaken, Stephenson was one of the first, if not the first, to realise that this infection takes place.

No general practitioner can afford not to read, mark, learn, and inwardly digest this article. S. E.

(3) In 1907 **Harman,** of London, published some figures respecting the incidence of ophthalmia neonatorum in about 12,000 births occurring in the private practice of several medical men in one quarter of the Metropolis. There were 110 cases in 12,680 live births, or 0·867 per cent. In March, 1911, the disease was made compulsorily notifiable within the London County Area, and the official figures of the London County Council show that 673 cases of ophthalmia were notified among 100,830 live births from that date until the end of the same year. If the figures be calculated for the whole year instead of for the nine-and-a-half months, as above, the incidence of the malady would work out at 0·843 per cent. It is, therefore, obvious that the official return tallies closely with Harman's estimate.

According to the official figures, injury to the eyes resulted in 5·6 per cent. of the cases. It may be noted that of the total number (13) where injury occurred, three children were blinded in both eyes, and five in one eye alone. In seven of these babies, there was a history of vaginal discharge in the mother.

The fact that of the babies affected with ophthalmia neonatorum (673) seventeen died whilst the disease was in progress lends support to the idea that the infants born of gonorrhœal mothers are less viable than the offspring of healthy mothers (Lobenstine and Harrar).

The table gives details as to the date of onset of the ophthalmia :—

Day ...	1	2	3	4	5	6	6	7	8	10	Later.	Not Ascertained.
Cases ...	18	23	38	33	28	29	18	23	19	11	26	4

The difficulty of nursing the affected babies speedily became manifest. During the time under review the services of four nursing societies were made use of in 68 cases. The London County Council had under consideration the question of hospital treatment for severe cases, and an endeavour was made to secure accommodation for mother and child (infant), so that while the child was being treated it would not be deprived of the advantage of being breast-fed. The ophthalmic hospitals and the general hospitals had difficulty in providing such accommodation, but in some instances both mother and child were admitted to the Poor Law infirmaries. Of the cases occurring in the practices of midwives during the year, in 12 instances mother and child were admitted to hospitals or infirmaries, and in 20 the child alone was admitted, 101 other cases were treated by the ophthalmic and general hospitals as out-patients.

Harman concludes a most useful communication by again urging, in the light of the figures he has quoted from official sources, the undesirability of the compulsory use of silver nitrate or other similar agents at birth. The universal employment of antiseptics to the eyes, he thinks, may be used to cloak dirty practice, to say nothing of the likelihood that they may be used carelessly. SYDNEY STEPHENSON.

VI.—OCULAR MYOCLONUS.

Thomson, Ernest.—Ocular myoclonus. *Lancet*, 18th January, 1913.

The principal facts of the case described under the title "ocular myoclonus" by **Ernest Thomson,** of Glasgow, are as follow:—

A young man of 18 years had suffered all his life from attacks of closure of the left eye of a clonic nature, these attacks varying in severity from time to time. Investigation showed that the muscles involved were the orbicularis palpebrarum and the frontalis on the left side, and the pupil sphincters on both sides. Elevation of the eyebrows associated with lid closure gave the patient a peculiar appearance. Treatment with bromide of potassium greatly modified the condition, the spasm tending to become quite irregular and occasional in character. There was hypermetropia 4 D. in the left eye, which had V.A. only 5/36, not improved by glasses. Right eye emmetropic, with full vision. Fundi normal.

The author considers the case in relation to the theories which have been held as to the mechanism of the lid-closure reflex first described by von Graefe, (Westphal-Piltz phenomenon, Gifford-Galassi reflex, orbicularis reflex), and concludes that the facts seem to support the view of that reflex which regards it as an indication of the truth of the theory of Mendel, namely, that the orbicularis and frontalis are really eye muscles which are ultimately supplied by the third nerve, although the fibres arrive *via* the facial nerve. AUTHOR.

VII.—INTRA-OCULAR COAGULATION OF THE AQUEOUS HUMOUR.

Barraquer—(1) Intra-ocular coagulation of the aqueous humour following each of three operations on one eye. (2) Spontaneous cure of secondary cataract. [(1) Coagulation intra-oculaire de l'humeur aqueuse à la suite de chacune de trois opérations pratiqués sur un seul œil. (2) Guérison spontanée de cataracte secondaire.] *La Clinique Ophtalmologique*, 10 février, 1913.

Both the cases recorded by **Barraquer**, of Barcelona, are interesting; but the first, in particular, seems very extraordinary.

(1) A man, aged 46 years, and of poor health, with tuberculous family history, was first operated on for cataract by de Wecker in 1904. On the fourth day, according to the patient, he lost the sight of this eye entirely, and de Wecker was astounded to find the eye entirely white. There was no pain, hardly any redness, and the eye was brilliant but quite white. Nothing of the iris colour was to be seen. This condition remained for more than a month, and then quite quickly the eye recovered its transparency and became almost normal.

In 1907 Barraquer did a preliminary iridectomy on the other eye without accident. On the second day there was nothing unusual, but on the third day the anterior chamber was filled "with a white, greyish, very feebly bluish" substance. The iris could just be made out at the periphery. No pain, redness, or conjunctival secretion. Preservation of light perception and of phosphenes. Subconjunctival injections of cyanide were tried, but given up, as they were useless. At the end of a month, and within the space of two

days, the eye spontaneously recovered its colour and transparency. The opaque substance had entirely disappeared from the anterior chamber.

At the end of 1910, the cataract was extracted successfully. For six days things went all right, and the vision was good. On the seventh day, exactly the same thing happened as upon the occasion of the preliminary iridectomy. A 2 per cent. subconjunctival injection of sodium chloride was given. In twenty-four hours the opacity in the anterior chamber had entirely disappeared. Secondary cataract ; pupil dilated fully with atropine. In due course V.A. was 1/2 without further operation, which latter was advised but not accepted.

The author concludes as follows :—" Evidently it is not a question here of an inflammatory process, it is not an infection ; the opacity in the anterior chamber is not composed of pus. It has not the colour of pus. There is no inflammatory reaction ; there are no synechiæ nor corneal opacities. The rapidity of appearance and disappearance of the opacity, and the absence of a greater density in the lower parts, added to the other points, prove that the trouble is not inflammatory. I believe that it is due to coagulation of the aqueous humour secondarily formed (*coagulation de l'humeur aqueuse de deuxième formation*), produced perhaps by a particular state of the biochemical reactions in the anterior chamber, a state due to the anæmia (from which the patient suffered) or to an internal undiscovered tuberculosis. It is necessary to say that between the second and the third operation the general condition of health had been much improved, and this improvement may explain why the opacity was late in appearing, and was cured in twenty-four hours with a single subconjunctival injection of sodium chloride."

(2) The second case recorded by Barraquer is that of spontaneous cure of a secondary cataract (post-operative), and consequent improvement in vision from 1/6 to 2/3, which took place in the course of a different illness two years after the original extraction. An absolutely black pupil had appeared. The author is careful to exclude the possibility of an operation by another surgeon.

ERNEST THOMSON.

VIII.—COLOUR SENSE.

(1) Edridge-Green, F. W.—The Hunterian lectures on colour vision and colour blindness. *Lancet*, February 4th, 1911.

(2) Edridge-Green, F. W.—The discrimination of colour. *Lancet*, August 19th, 1911.

(3) Köllner.—On the line of demarcation between normal colour vision and colour weakness. (Ueber das Grenzgebeit zwischen normalem Farbensinn und Farbenschwäche.) *Bericht der Ophthalmologischen Gesellschaft*, Heidelberg, 1911.

(4) Hilbert, Richard.—A complete system of colour sensations, with some remarks on the pathology of colour perception. (Ein vollständiges System der Farbenempfindungen nebst einigen Bemerkungen über die Pathologie des Farbensinnes.) *Klin. Monatsbl. f. Augenheilk.*, März, 1912.

(5) Augstein.—Remarks upon the examination of the colour sense. (Bemerkungungen zur Farbensinnuntersuchung.) *Zeitschrift für Augenheilkunde*, Oktober, 1912.

(6) **Lenz.—A contribution to our knowledge of the colour sense centre. (Zur Lehre von Farbensinnzentrum.)** *Bericht der Ophthalmologischen Gesellschaft*, Heidelberg, 1912.

(1) **Edridge-Green's** Lectures, delivered before the Royal College of Surgeons on February 1st and 3rd, 1911, appear to represent the last word of this talented writer on the subject of the facts of colour blindness (Lecture 1), and the detection of colour blindness from the practical point of view (Lecture 2). Most of the subject matter has already appeared in print in recent years in British journals, and it is of such interest, importance, and complexity that we have no hesitation in saying that it must be studied in the original papers and in this series of lectures (which brings many of these papers together) in order to be appreciated.

(2) **Edridge-Green's** short article is a reply to the statement of Lord Rayleigh (*Proceedings Royal Society*, Decr., 1910), that he was able to distinguish between the wave lengths included in a monochromatic division to the extent of discriminating between the colours of the two D lines. The author concludes that when special precautions are taken to have as pure a spectrum as possible, he can find no method which will enable him to distinguish the colours in a monochromatic region. He continues to regard the appearance of the monochromatic region as a fundamental physiological fact.

ERNEST THOMSON.

(3) **Köllner**, of Berlin, read a paper to the Congress which discussed colour weakness as distinct from normal colour sense, on the one hand, and colour blindness, on the other. He pointed out that all kinds of intermediate forms existed between normal colour vision, decided colour weakness, and complete colour blindness, and that this circumstance introduced great difficulties in diagnosis. Rayleigh's matching test was responsible for much of the confusion which existed. In the form of Nagel's Anomaloscope it had been adopted by the railways, and had almost brought the method into discredit, because candidates who showed abnormalities with the Anomaloscope appeared to be normal when tested with other apparatus, The reverse condition has also been noted: candidates rejected by ordinary tests matched the Rayleigh spectral colours without difficulty. This apparent paradox only applies to the match between yellow and the red-green mixture, and depends upon the relative brightness of the colours. With correct regulation of this factor, Köllner finds that all individuals with colour weakness can be unmasked with Rayleigh's apparatus.

Köllner comes to the following conclusions:—

1. Up to the present every case which has appeared abnormal when tested by other methods has made mistakes with the Anomaloscope.

2. On the other hand, Rayleigh's apparatus has detected abnormalities which do not render the individual incapable of distinguishing colour for all practical purposes.

3. The difference in brightness of the fields has so much influence upon the test that great care must be taken to exclude this source of error.

Directions are given in the use of the instrument which are not very intelligible to those who, like the reviewer, are unacquainted with it. The same consideration applies to the plates which accompany the article.

Köllner gives no definition of what he means by *colour weakness*. Does he include those who cannot distinguish between orange and yellow or between green and blue in this category? This absence of precision and the loose use of terms renders the communication difficult to follow.

T. HARRISON BUTLER.

(4) This article, by **Hilbert,** of Sensburg, sums up the contents of a

number of papers which he has contributed within recent years, to the *Klin. Monatsbl.* and other journals. He accepts Hering's theory, and all his work is based on it. The more important part of his summary is as follows :—

All colour sensations are subjective. They belong to three main groups, viz.,—i, the physical, ii, the physiological, and iii, the pathological.

Group I embraces the so-called "objective colours," which are capable of physical investigation, and in which the sensation of one individual can be compared with that of another. They arise from stimulation of the colour centre by adequate stimuli, *i.e.*, ether vibrations of certain wave lengths. In this group we have (1) the spectral colours, (2) interference colours (3) those produced by chromatic polarisation of light, (4) phosphorescence, (5) fluorescence, (6) pigments.

Group II comprises colour sensations produced (1) by auto-activity of the colour centre, (2) by stimulation of the centre by non-adequate stimuli. Under (1) we have simultaneous contrast, successive contrast, colour blindness due to dazzling, permanent light and colour sensations (light chaos of Purkinje), and under (2) colour sensations due to mechanical, to electrical, and to chemical stimuli.

Group III contains (1) the sensations due to stimulation of the colour centre, *i.e.*, pathological colour sensations, and (2) the sensations due to inactivity or destruction of the centre, *i.e.*, colour blindness. Under (1) we have colour sensations in diseases of the nervous apparatus of the eye, colour hallucinations of the psychoses, *audition colorée*, the chromatopsies (red-, green-, blue-vision), and the appearance of colour spots in the visual field, coloured sensations produced by the circulation of chemical poisons, by internal diseases, and by mechanical cerebral lesions, the colour sensations of migraine, and the rare examples of anomalous reaction of the colour centre. Under (2) fall congenital colour blindness, transient colour blindness in hypnosis, epilepsy, hysteria, etc., and colour blindness, more or less complete, due to destruction of the colour centre.

Other colour sensations which might be added under some such term as "accidental colour sensations" are: those resulting from optical defects, astigmatism, opacities, glaucoma, and those due to staining of the media.

A. J. BALLANTYNE.

(5) **Augstein,** of Bromberg, has during the past twenty-five years examined the colour sense of 3,044 individuals, and has reported in doubtful compensation cases upon 600 more for the Railway Department at Bromberg. Before 1907 he employed the tests recommended by Holmgren, Adler, and Daae, and also the coloured light tests of Grossmann and Eversbusch. Since 1907 he has only used four tests, *viz.*, Cohn's cards, Nagel's cards, Stilling's cards, and Nagel's Anomaloscope.

He notes that the deeper one goes into the difficult question of colour-vision, the more all observers are agreed that all defects occur in a graduated manner (*gradweise*). They gradually increase from the smallest anomalies, which are only detected by the Anomaloscope, to gross forms, in which spectral red and green are confused. He then discusses the question as to what degree of abnormality must be held to render a man incapable of service on the railway, and what tests enable us to settle this question. He has examined individuals who were slightly abnormal under service conditions with signal lamps, both under ordinary, and trying conditions, such as fog. These lamps were rapidly changed from red to green, and *vice versa*, at a distance at which they were easily recognised by the normal sighted. He found that only a minority failed to make mistakes. This was before the Anomaloscope was invented. Such practical tests are not convenient, and we fall back upon

scientific methods. The paper then deals with Nagel's test, and the author agrees with Stargardt and Oloff that it is not a perfect method. It has the advantage that the colours have not to be named. Naming colours is difficult for the unlearned and stupid, who are not uncommonly met with in East Prussia. Such may wrongly name a colour when they are not really colour blind. Here we would at once say that a man who is so stupid that he does not know the difference between red and green, a question any intelligent child from three to five could answer, is too lacking in intelligence for any position of importance upon a railway. He would also be far too dense to use the Anomaloscope. In any case, Augstein says Nagel's cards are not sufficient alone, although they are good. They are useless for a differential diagnosis between the abnormal trichromatic and the dichromatic.

The author finds Cohn's test very useful, especially when it is employed with Mayer's contrast paper (*Florkontrastpapier*). He is surprised at the small recognition this test has received. It consists of black circles with a gap in them upon a red background. When they are covered with the paper, the rings appear green and the normal sighted can at once perceive where the gap is. Success proves normal colour sense, failure demands further tests. Augstein has only found three exceptions in 1,000 cases, in which Stilling's cards and the Anomaloscope showed slight colour weakness. Nagel himself praises this test and advises it as a preliminary to his own method.

Stilling's cards are excellent, and every examiner ought to use them.

The question of how many degrees of error should be allowed on the Anomaloscope is fully discussed in the paper, and the conclusion is reached that *this instrument alone can tell us whether or not the examinee is sufficiently colour-blind to be unsafe or not.* Augstein has found three persons in 1,000 who passed all the tests but failed with the Anomaloscope, and so he decides that it can never be dispensed with if accuracy be demanded.

The final conclusion is, that to detect colour-blindness two tests are needed, Cohn's and Stilling's. In compensation cases, Nagel's test and the Anomaloscope must be added. It is of no use to place the Anomaloscope into the hands of the ordinary railway doctor, because he rarely has the necessary knowledge to use it.

The paper absolutely neglects the Edridge-Green lantern, which is the simplest and surest of all tests. If a railway man passes this lantern test, no matter what he does with the Anomaloscope, he is fit for duty.

The Stilling test should certainly be adopted in this country.

It will be observed that the Holmgren test is not even discussed. In Germany, although the whole country is still true to Helmholtz, the wool test has disappeared. It is utterly dead, and yet our precious Select Committee has bolstered it up afresh, and the Board of Trade still use it as the main test for seamen. And this in face of their own results, which are a standing disgrace to an intelligent nation. T. HARRISON BUTLER.

(6) **Lenz**, of Breslau, describes two cases of acquired colour blindness which affords some confirmation of Edridge-Green's theory that colour sensation is a function of the central sensorium. Edridge-Green, however, receives no mention in the paper. The question of the physical existence of a definite centre for colour sensation has never been settled, although isolated cases in which a cerebral lesion has destroyed colour sensation and left form vision intact suggests that it exists. The author described two such cases to the Congress, one of whom was a private patient of Professor Uhthoff. Both patients were old men who became apoplectic, and when the urgent symptoms had passed away, a defect in colour vision remained, which was extraordinarily similar in the two cases. In each the left halves of the visual fields were

totally colour blind, partial defects were present in the right halves. In the first case there was found at the autopsy an area of softening in the calcarine region. There was also a lesion in the optic radiation. Another focus of softening was present in the right præ-cuneus region. In the brain of the second patient there were disseminated foci in the optic radiation, and on the right a lesion in the occipital lobe which pressed upon the radiation. This specimen has not yet been studied histologically. The author concludes that there is no special isolated centre for colour vision; it is far more likely that part of the calcarine region is associated with light and form sense. We fail to follow the author's reasons for this conclusion. He says that a centre for colour vision is improbable upon physiological grounds, and we fear that the Helmholtz theory of colour perception has influenced his opinions.

T. HARRISON BUTLER.

IX.—SURGICAL TREATMENT OF DETACHED RETINA.

(1) **Birch-Hirschfeld, A.—Experimental and histological investigations upon detachment of the retina and the effect of its surgical treatment.** (Experimentell-histologische Untersuchungen ueber Netzhautablösung und die Wirkung Operativer Therapie.) von Graefe's *Archiv f. Ophthalmologie*, Bd. LXXIX, Heft i, 30 Mai, 1911.

(2) **Holth, S.—New operative treatment of detached retina and high grade myopia.** (Præ-æquatorial trephining of the sclera). [Neue operative Behandlung der Netzhautablösung und der hochgradigen Myopie (Trepanatio scleræ præ-æquatorialis).] *Bericht der Ophthalmologischen Gesellschaft*, Heidelberg, 1911.

(3) **Bettremieux, Paul.—Two cases of retinal detachment in myopes cured by simple sclerectomy.** *Ophthalmology*, July, 1912.

(4) **Bettremieux.—On the technique and method of action of the operations recently proposed for detachment of the retina** (Technique et mode d'action des opérations récentes proposées contre le décollement retinien.) *Ann. d'Oculistique*, August, 1912.

(5) **Bettremieux, Paul—The technique and mode of action of the recent operations proposed for retinal detachment.** *Ophthalmology*, October, 1912.

(6) **Teulières.—Cure of a myopic retinal detachment.** (Guérison d'un décollement rétinien myopique.) *Archives d'Ophtalmologie*, janvier, 1913.

(1) Detachment of the retina can be produced in the eye of the rabbit by withdrawing about ½ c.cm. of the vitreous, after puncture of the sclera (Birch-Hirschfeld and Inouye.) The detachment appears after a few minutes, sometimes disappears after a few days, but if not, increases and remains stationary after about eight days. In these cases the retina shows one or more tears. **Birch-Hirschfeld**, of Leipzig, thinks that this detachment offers a favourable opportunity for testing the clinical and anatomical effects of the various forms of surgical treatment, although he freely admits that the cases are not identical. He experimented with the simple puncture, puncture and cauterization,

drainage of the subretinal fluid (he uses a catgut thread), electrolysis and Deutschmann operation (double puncture with division of the vitreous adhesions). A few cases were healed after any of these operations, and he thinks that a successful result is most likely where the subretinal fluid has been completely removed and where the retraction of the retina from the formation of præretinal fibres and adhesions is least developed. Cauterization leads to a broader adhesion than simple puncture, but does not give any better results, electrolysis produces changes in the choroid. Deutschmann's operation was successful in one out of two cases and did not lead to any particular disturbance of the vitreous. Author is mildly in favour of this operation, although he recognises its limitations, and does not think that the fibrillary deposits upon the inner layers of the retina can be effectively separated by this method. R. GRUBER.

(2) **Holth**, of Christiania, described to the Heidelberg Congress a new operation he has devised for detached retina. Finding that the ordinary scleral puncture healed at once, allowing the subretinal fluid to re-collect, he tried the effect of removing a piece of sclera with a punch. In the first operation no subretinal fluid escaped, but only a few drops of vitreous. But in spite of this, the case was so much benefited by the procedure that Holth decided to develop the *technique* of this operation of scleral puncture without draining the sub-retinal fluid. So far, six cases have been operated upon, and of these, two were improved, and four cured. Holth uses a Bowman trephine, which he has slightly modified. This he sterilises by dry heat at 100 C. and uses to trephine the sclera between the rectus externus and the rectus inferior after an opening has been made in conjunctiva and Tenon's capsule. The 2.5 mm. trephine is adjusted to cut from $\frac{3}{4}$ to 1 mm. deep. If the trephined disc is not entirely separated, it is removed with scissors or Holth's punch. It may now be advisable to enlarge the aperture backwards, with the punch forceps. The conjunctiva is then sutured in such a manner that the silk does not touch the wound.

Not only has this operation led to the improvement of detached retina, and improvement which sets in after some months, but at the same time the myopia gradually diminishes. T. HARRISON BUTLER.

(3) It will be remembered that the simple sclerectomy of **Bettremieux**, of Roubaix, consists in cutting away scleral tissue so as to form near the limbus a gutter which has a width of about two millimetres and a length of ten millimetres, and finally covering it with the previously elevated conjunctiva. The author's belief is that it produces its good effects in glaucoma and other diseases by setting up anastomoses between the deep pericorneal vessels, *i.e.*, the efferent vessels of the canal of Schlemm, and the subconjunctival vessels. He reports two cases in which it gave satisfactory results in myopic detachment of the retina. In one of these, which was of fifteen days' duration before treatment, the cure was maintained after an interval of two and a half years.

A. J. BALLANTYNE.

(4) **Bettremieux**, of Roubaix, reiterates his belief in the value of anterior sclerectomy in the treatment of detachment of the retina, and quotes communications from Doctors Vile and Cusner of Brussels, confirming his opinion. He discusses the operation recently proposed by Lagrange (*colmatage de l'œil*) and expresses the opinion that so far from closing or diminishing the excretory paths of the eye, as he intends, he in reality increases them by destroying the impermeable superficial layers of the sclerotic and allowing anastomoses to form between the deep scleral vessel and those in the subconjunctival tissue. He points out that both he and

Lagrange in their respective operations dissect the conjunctiva and subconjunctival tissue off, so as to leave the sclera clean, and claims that Lagrange's "*colmatage*" is practically an anterior sclerectomy in which the superficial layers of the sclera are removed with the cautery instead of the knife. He expresses the opinion that to diminsh excretion from the eye the subconjunctival tissue and not the superficial layers of the sclerotic should be destroyed. R. J. COULTER.

(5) Since 1907 **Bettremieux**, of Roubaix, has been practising his operation of simple sclerectomy for retinal detachment, and both he and others have been satisfied that good results are thus to be obtained. The operation may be repeated if necessary. The theory of the effect of this operation, is, that it relieves the high pressure under which the aqueous is believed to accumulate, by lowering the tension in the anterior uveal veins. Bettremieux compares his operation of simple sclerectomy with the method proposed by Lagrange for the treatment of retinal detachment. The latter consists in destroying with cautery the external layers of the sclera round the limbus, that is to say the parts removed with the knife and scissors in Bettremieux's operation. But, while the two methods seem to accomplish the same objects, they are based on different theories, for Bettremieux holds that the pressure of the aqueous is high, and that he relieves this pressure, while Lagrange, on the supposition that the pressure is low, aims at blocking the filtration channels and thus encouraging the accumulation of aqueous.

A. J. BALLANTYNE.

(6) **Teulières** records the cure of a simple detachment of the retina by the method he usually adopts, and which has been maintained for two years.

The patient was a myope of 41 years and the detachment a progressive one of ten days' standing in the left eye. The vision was reduced to "finger counting" in a small area in the lower and outer quadrant of the field of vision 20° away from the fixation point. The ophthalmoscope showed a retinal detachment corresponding to the blind area, but the retina itself, although apparently much congested, seemed in good condition.

The sclera, bared by turning down a conjunctival flap in the region of detachment, was cauterised in fifteen places by means of a blunt cautery, and then perforated with a fine point in two places to evacuate the sub-retinal fluid. The flap was then sutured in place. Injections of ten per cent. saline solution were then made around the globe subconjunctivally, and repeated five days later. Dorsal decubitus.

In thirteen days from the commencement of treatment, no sign of detachment or congestion of the retina could be seen. The visual acuity was 1/3 with —16 D. sph., and the field of vision normal. The eye was in the same condition two years later. BERNARD CRIDLAND.

X.—DETACHMENT OF THE RETINA.

(1) **Hirschberg, J.—An unusual case of the spontaneous cure of a detached retina. (Ein ungewöhnlicher Fall spontan geheilter Netzaut-Ablösung.)** *Centralbl f. prak. Augenheilk.*, Oktober, 1911.

(2) **Greeves, R. A.—A case of retinal disease with detachment in a child.** *Ophthalmic Review*, December, 1911.

(3) Laws, W. G.—Case of retinal detachment, with cystic appearance at the periphery. *Transactions Ophthalmological Society*, Fasc 3, 1912.
(4) Vail, Derrick T. An inquiry into the results of the established treatment of detachment of the retina, and a new theory. *Transactions Seventeenth Annual Meeting of the American Academy of Ophthalmology and Oto-Laryngology*. (Received May, 1913.)
(5) Harman, N. Bishop.—Spontaneous recovery from detachment of the retina. Royal Society of Medicine: Section of Ophthalmology, June 4th, 1913. *Medical Press and Circular*, June 18th, 1913.

(1) **Hirschberg**, of Berlin, reports an interesting case of spontaneous cure of a detached retina. A male patient was first seen in 1890, and was then 48 years of age. He came on account of cataracts. Both lenses were removed, and the visual result one year later, was very good in both eyes, and remained good for ten years. In 1902, he was seen, and said that his vision had been failing for two years. The cause was found to be a retinitis centralis, with fine hæmorrhages in the central parts of the retinæ, and on the left side, in addition, vitreous opacities. There was some arterio-sclerosis, but nothing abnormal could be found in the heart or kidneys.

He was seen again in May, 1911, *i.e.*, 21 years after the cataract operations, and the patient was now 69 years of age. The history was that the right eye had been blind since January, 1911. The cause was an extensive detachment of the retina, which itself was the seat of many hæmorrhages. The left eye, as before, showed only many fine hæmorrhages. There was now albumen in the urine. He was put under appropriate treatment and returned two months later in much better general health, and stated that his right eye had also improved considerably. It was then found that the retinal detachment had completely disappeared, and vision with glasses was now 5/50, and the field full, and only the remains of old hæmorrhages were to be seen. Hirschberg adds that never has he seen a similar case, and his moral is that apparently one ought *never* to give a really bad prognosis. A. LEVY.

(2) This is the record of a case of a painful glaucomatous eye in a boy, aged six years, with a history of one week's duration and occasional divergence over a longer period. After removal, examination showed the presence of chronic disease in the form of new tissue formation in the outer layers of the the retina with recent hæmorrhages and cysts containing fibrinous coagulum; there was also extensive detachment, and the secondary glaucoma appeared to be recent. **Greeves**, of London, considers that this case belongs to the group described by Coates under the name of "retinal disease with massive exudation." (*R. L. O. H. Rep.* 1908). A. H. PAYAN DAWNAY.

(4) **Vail**, of Cincinnati, issued a circular letter to 460 American ophthalmic surgeons, enquiring whether they had any successes to record in the treatment of non-traumatic detachment of the retina. He received 281 replies. His correspondents had employed the most varied methods of treatment, local, surgical, and general, but, on the whole, the answers indicated "the incurability of this dread disease of the eyes by the established methods of treatment." Of the total number of correspondents (281), 250 had never succeeded in curing a single case, although many had obtained promising results for a time, followed by ultimate failure. Forty-one cases, in the practice of thirty-one ophthalmic surgeons, were cured. Twenty-five surgeons had a single cure each; four had two cases and two had four cases (total forty-one cases). A very elaborate analysis of the answers received leads Vail to express the strong conviction that "we are not really justified in resorting to anything but the mildest and most humane measures in the treatment of detachment of the retina until we have a 'cure' that cures." The following

are his conclusions.—1. The established medical treatment is a failure, because the ætiology of the trouble is not recognised. 2. The surgical treatment is not founded on scientific principles, and is therefore brutal. 3. Detachment of the retina is not a disease, it is a symptom. 4. The disease, of which detachment is a symptom, is paralysis of function of the ciliary processes, causing arrest of aqueous secretion within the eye. 5. The treatment should be the use of those measures and only those which have for their objects the re-establishment of the lost function of the ciliary processes.

Discussion.

S. D. Risley, of Philadelphia, alluded to one instance of permanent recovery of detachment due to complicated myopia. The immediate cause of the detachment was a fall from a street car. Treatment (commenced at once) consisted of complete rest, binocular bandage, eserine salicylate to the eye, and electric light baths.

Elschnig, of Prague, had never succeeded in curing a myopic detachment of the retina, although he had seen many cases undergo spontaneous cure.

G. C. Savage, of Nashville, narrated some remarkable cures and ameliorations from the subconjunctival injection of fifteen drops of a solution of sodium citrate, twenty-five grains to the ounce. He also gives small doses of potassium iodide and mercury bichloride in order to improve the nutrition of the ciliary body.

A. Greenwood, of Boston, has seen one cure in a nurse treated by subconjunctival injections of salt, rest in bed without a pillow, pilocarpine, and bandaging.

G. B. Jobson, of Franklin, had one cure after posterior sclerotomy followed by the subconjunctival injection of normal salt solution.

I. L. Doane, of Butler, had seen a re-attachment take place in a hyperopic patient. SYDNEY STEPHENSON.

(5) **Bishop Harman,** of London, showed a case of spontaneous recovery from detachment of the retina. The patient had had complete detachment for three months, and during it she was treated by rest in bed. She refused operation. Shortly after that date the sight came suddenly back, and now there was no trace of any detachment; all that could be seen were one or two cobwebby lines in the disc. She had 6/36 (one-letter) vision. She had 10 D. of myopia, but there had been no accident of any kind. She was a cook in a good family, and one February night she walked out from a hot room to the cold air, and her description was that something black suddenly fell over her eye, and she could not see anything more with it.

Discussion.

W. G. Goudie, of Glasgow, described the case of a child which came to Glasgow Eye Infirmary with detached retina, and in whom three months later the retina became reattached. Two months afterwards, it again became detached, only to become attached again. There was fair vision, and no iritis.

Rayner D. Batten, of London, said he had a case with nearly 20° of myopia and detachment. Detachment occurred also in the other eye, and the patient was so blind for a year or two that she had to be led about. Later she came and said she saw a glimmer of light, and from that date her sight began to return; she accepted her lenses again, and was able to find her way about. He believed her vision was 6/24.

Herbert Parsons, of London, said he, like others, was sceptical about spontaneous recovery from detachment being possible, until he had a case which altered his view. It occurred in hospital, and though a little later the patient was carefully examined, no trace of the detachment could be detected, not even streaks to mark what had occurred. Eighteen months later, however, there was a relapse.

Macnab, of London, described a case of double detachment which underwent spontaneous cure. In another case in which the condition occurred there had been irido-cyclitis, and he believed it was due to tubercle of the eye; there was a large vitreous opacity, and very extensive detachment; the eye was very soft, being practically devoid of tension; the cornea could be seen to be dull and crinkled. Vision was reduced to mere perception of light. He gave tuberculin, and vaccine cultivated from the patient's own coli bacilli. For four months now the tension had been normal, and the patient could count fingers at 5 or 6 metres.

Jessop, of London, reminded the meeting that when the Ophthalmological Society discussed the subject, only one case was reported as having been cured, and that was spoken to by Nettleship and Sir John Tweedy. Many cases of cure of the condition had been reported, but they had not been lasting.

Ormond, of London, did not share Jessop's scepticism, and described a case of his own, in a patient who had been treated by glasses for high myopia, and a little later she said her vision suddenly went in one eye. She had obvious detachment of the outer side of the retina. He did a sclero-puncture, and removed some fluid, and in three days the detachment had disappeared. He had seen her a number of times since, and the detachment remained absolute. Vision was 6/36.

Leslie Paton, of London, reminded the meeting that Harman's case was one of spontaneous re-attachment, not after operation. He was more optimistic than Jessop on the subject. He had seen a case of 35 years' standing cured after operation, though it was a double case. In another case, that of a lady with 15 D. of myopia, and vision 6/18 in either eye, there was detachment in one eye, resulting in blindness, and that was followed by detachment in the other eye. After operation her vision was better than before the detachment. In the case of a girl with detachment, she was put on her back and treated with mercury and iodide, and in three months the retina had become re-attached, leaving only a curious distribution of retinal pigment. In a series of 28 cases of detachment which he had looked up, 7 were cured.

Nettleship and **Jessop** suggested that in the near future a further discussion on the subject should be held by the Section. Nettleship said he had records in his case-books of several cases of detachment which had recovered.

XI.—TUBERCULOSIS.

(1) **Dupuy-Dutemps.—The glaucomatous form of choroidal tubercle. (Tuberculose choroïdienne a forme glaucomateuse.)** *Fondation Ophtalmologique Adolphe de Rothschild. Bulletin et Travaux*, 1911, p. 43. (Received March, 1913).

(2) **Gebb.—A contribution to tuberculosis of the fundus. (Beitrag zur Augenhintergrundstuberkulose.)** *Archiv f. Augenheilk*, Bd. LXXI, Heft i, S. 89, März, 1912.

(3) **Peter, Luther C.**—Tuberculosis of conjunctiva and sclera, following removal of a pigmented papilloma of the conjunctiva. *Archives of Ophthalmology*, May, 1912.

(4) **Butler, T. H.**—Tubercular disease of the uvea. *Birmingham Medical Review*, May, 1912.

(5) **Igersheimer, I.**—Tuberculosis in the ætiology of periphlebitis retinalis adolescentium. (Tuberkulose als Aetiologie der Periphlebitis retinalis adolescentium.) von Graefe's *Archiv f. Ophthalmologie*, Bd. LXXXII., Heft ii, 25 Juni, 1912.

(6) **Truc.**—On chronic tuberculo-rheumatic uveitis. (Des uvéites chroniques tuberculo-rhumatismales.) *Ann. d'Oculistique*, juillet, 1912.

(7) **Rados, Andreas.**—Contributions to our knowledge of the tuberculous lesions of the retina. Beiträge zur Kenntnis der tuberkulösen Veränderungen der Retina.) *Klin. Monatsbl. f. Augenheilkunde*, September, 1912.

(8) **Opin.**—Tuberculosis of the bulbar conjunctiva. (Tuberculose de la conjonctive bulbaire.) *Archives d'Ophtalmologie*, septembre, 1912.

(9) **Guzmann, E.**—On epibulbar tuberculosis. (Ueber epibulbäre Tuberkulose.) *Zeitschrift für Augenheilkunde*, Januar, 1913.

(10) **Agricola, B. and Thies, O.**—Secondary tuberculosis of the retina. (Zur Kenntnis der sekundären Netzhauttuberkulose.) *Klin. Monatsbl. f. Augenheilkunde*, Januar, 1913.

(11) **Friedenwald, Percy.**—On tuberculosis of the eyelid. *American Journal of Ophthalmology*, March, 1913.

(1) **Dupuy-Dutemps** does not agree with a statement common in text-books, that in tubercle of the choroid the tension tends to be lowered, or, at least, not raised. In support of this contention, he reports the case of a man, aged 20, who had complained of failing vision in the right eye for three weeks. A detachment was present upwards and outwards, which showed none of the appearances characteristic of cases of new growth. The tension was normal. Two days later, there was a slight attack of scleritis, and after a month, the detachment had become total. Glaucoma followed in about two months from the onset of symptoms; the iris became discoloured, the eye congested, and the anterior chamber deep; transillumination was negative. The eye was enucleated.

Consolidation was present in the apices of both lungs, and the patient was admitted later with hæmoptysis. The family history was negative.

Pathological examination showed the globe to be enlarged, and the sclera bosselated. The retina was detached, and the choroid at the posterior pole was converted into a mass of typically tuberculous, caseating granulation tissue. Inflammation was present in the choroid elsewhere, as well as in the ciliary body and iris. There was some invasion of the sclera.

Reference is made to similar cases reported by Dupuy-Dutemps himself and by other authors. They have been most commonly confused with glioma. As regards diagnosis, in the early stages a sarcoma forms a single well-defined mass; tubercle an area surrounded by a whitish halo, and sometimes by satellite foci of infection. In the stage of detachment, or glaucoma, there are no certain means of diagnosis from the examination of the eye alone, but tubercle usually occurs in younger subjects than sarcoma. Between the ages

of 6 and 20 especially, a diagnosis of tubercle is probable, the patient being, on the whole, too young for sarcoma, and too old for glioma. The course of tubercle is also generally more rapid than that of sarcoma, and scleral ectasia usually occurs at a shorter interval after the onset of glaucoma. Evidence of iritis, especially if developed at an early stage, is also in favour of tubercle, and as the disease is seldom primary in the choroid, the examination of other organs is of importance. The tuberculin reaction may be untrustworthy, and is not always free from danger. The injection of the aqueous into a guinea pig should be tried, but in the early stages of tubercle confined to the choroid is likely to be negative. GEORGE COATS.

(2) Tuberculosis of the retina is rare, so that every case should be reported in detail and, where possible, with a picture, so that a comparsion of these interesting cases might be made.

Gebb, of Greifswald, reports the case of a bricklayer of thirty years who, for thirteen years, had noticed a gradual diminution in the sight of his right eye. Five weeks previously, the sight had diminished to such a degree that he was referred to the eye clinic. The following history was obtained.—His mother had died twenty-five years previously from lung disease, and he had an invalid sister. Examination of the patient in the medical clinic showed involvement of the apices of the lungs. Heart and urine normal. The vitreous of the right eye was liquified, and contained relatively thick spots. The disc was reddened with its borders raised especially on the nasal side, while no changes in the vessels were observed. One half a disc width to the nasal side was found a wide circular spot of varying width, which occupied nearly the whole upper part, and in the lower, reached as far as the macula. This white circle surrounded a yellowish coloured part of the fundus. The temporal part of the disc was distinctly redder than the nasal. Close to the disc was seen two pigmented areas. The second was of oval form, and in the pigmented accumulation there was an irregular surface with yellow bands passing through it. The seat of the pigment was easily seen to be in the retina. Gebb calls special attention to two parts of this diseased region—one, the yellow-white girdle, two, the red part enclosed. The outer limit of the white zone was not sharp. There were larger and smaller yellow white spots, and between these fine shiny crystals in the upper layers of the retina. The white girdle was seen to be deeper in the retina than the vessels. On the course of the latter one could see that the white zone protected the surface of the retina. The swelling of the white zone measured from four to six dioptres. Towards the outer part of the white girdle, signs of pigmentation were seen, the remains of very small hæmorrhages on the ends of two very tiny vessels. The tendency to hæmorrhage here was shown by the appearance of a small hæmorrhage, after tuberculin injection. On the inside of the white girdle were seen small whitish yellow spots, and shiny crystals. The process was composed of a row of larger yellow nodes, which were surrounded by healthy retinal tissue. One got the impression that the yellow spots were about the prominences of a deeper lying process. The spots were characterized, too, by their distinct contrast in colour to the healthy retina. The retinal vessels showed no changes worth mentioning. They went over the single yellow spots with an average prominence of from three to five dioptres. Gebb refers the reader to the accompanying coloured picture and discusses this in detail. The next question was, the ætiology of this condition. The Wassermann reaction was negative. The physical examination and the von Pirquet pointed to tuberculosis. With the general re-action following the subcutaneous injection there was a local one in that there occurred in the course of one of the retinal vessels a small hæmorrhage just above the white zone. From the history,

general examination, and local re-action, Gebb believed the case one of tuberculosis of the fundus. HANFORD MCKEE.

(3) A small pigmented growth, which had recently slightly increased in size, was removed from the conjunctiva of a girl of 13 years. The wound healed, but redness continued with slight thickening of the conjunctiva. Ulceration supervened, and a piece of the diseased area was then removed for examination. It was found to be tuberculous. The original growth was examined, and found to be a pigmented papilloma. Ordinary methods failed to produce any favourable effect upon the tuberculous process and it was not until weak doses of tuberculin were injected that improvement set in; with continued doses, the improvement continued until now the disease is practically cured. The author thinks that infection at the time of operation may be excluded, and that there must have been a focus of infection somewhere in the body, although careful examination failed to discover any such focus, and there was no nearer history of family infection than an aunt and some grandparents. The first very weak dose of tuberculin, however, gave a positive general reaction without any local reaction, a point which **Peter** thinks in favour of a hidden focus. Peter thinks that the diagnostic dose of tuberculin should aim at avoiding a local reaction, since in some cases this has an unfavourable effect upon the local condition; very weak doses being then continued, weak enough not to produce any local reaction. ROSA FORD.

(4) This communication was read by **Butler**, of Leamington, before the Midland Ophthalmological Society on April 2nd, 1912. It was illustrated by seven cases of actual tuberculous lesions of the uveal tissues, some still florid and some cured by tuberculine treatment. Coloured drawings of fundi were shown, six of which form the coloured plate attached to the paper.

The author pointed out that tuberculosis is found to be playing a more and more important *rôle* in ocular pathology as our methods of diagnosis improve. Many cases once ascribed to syphilis or to rheumatism are now known to be tuberculous. He finds that one per cent. of all cases coming to his clinics are affected with uveal tuberculosis. These cases have all recovered, and he regards ocular tuberculosis as very benign in nature. He strongly combats the view expressed in a recent text-book that "in large tubercle of the choroid the eye should be enucleated." Uveal tuberculosis is only a sign of a primary focus elsewhere and on no account should the eye be removed. The author is a strong believer in tuberculine therapy, but it must be continued for a long time. The most valuable clinical test of the presence of tuberculous disease in the eye is the appearance of a local reaction after the injection of old tuberculine *sub cute*. Calmette's reaction is dangerous and untrustworthy. von Pirquet's reaction is too universally obtained to be of any value. The author has used new tuberculine (T.R.) in a dose of 1/2000 m.mg. repeated once a week as his routine treatment. This has been continued for months. Occasionally, the dose has been raised to 1/1000 and 1/500. The reaction which follows the test injection of old tuberculine has frequently a marked therapeutic effect.

It was suggested that many cases of simple iritis, generally called "rheumatic," were in reality due to tuberculous toxæmia, and the joint pains were to be ascribed to the same cause.

Solitary massive tubercle of the choroid was prone to relapse. A case was shown with a recent florid but retrogressive tuberculous mass which had developed upon the edge of a typical obsolescent tubercle.

The work done by Sydney Stephenson and George Carpenter in drawing attention to the ubiquity of tuberculous eye disease is duly noted in the paper.

(5) Affections of the retinal vessels occur not only in advanced age, but also, although more rarely, in the young, mostly as periphlebitis, and are the cause of recurrent hæmorrhage into the vitreous. It seems to **Igersheimer**, of Halle, that a considerable portion of these cases are of tuberculous origin, and react to the tuberculines, which should be used for therapeutical purposes, although their success is rarely very striking. The first changes, almost invariably, affect the small veins of the periphery, and it is absolutely essential in all cases where hæmorrhage, or a similar process (retinitis proliferans) affects one eye, to examine closely all veins on the retinal periphery of the other one, as slight changes, or small hæmorrhages, are often seen there as a preliminary symptom of impending trouble. R. GRUBER.

(6) **Truc**, of Montpellier, considers that in many of the cases of quiet uveitis which, from their association with arthritic troubles, are usually regarded as of rheumatic origin, the condition of both the joints and the eyes is tuberculous. He gives notes of three cases in support of his contention, and suggests that further clinical, anatomo-pathological, and experimental investigation of the subject would lead to valuable theoretical and practical results.

R. J. COULTER.

(7) **Rados's** contribution to the subject is an account of the case of a boy of ten, whose right eye was enucleated on account of tuberculosis of the iris with *seclusio* and *occlusio pupillæ*. At the time of the operation there was no evidence of constitutional tuberculosis, but a year later the boy died of tuberculous meningitis.

The microscopic examination of the eye showed tuberculous disease in the iris and ciliary body, and changes in the lens. Below and to the temporal side of the disc a small typical tubercle was found in the nerve fibre layer of the retina. In the nerve fibre layer elsewhere small submiliary tubercles were discovered. The other retinal changes were cystic degeneration of the inner nuclear layer, increase of the size of the interfibrillary spaces in the nerve fibre layer, dilatation of the arteries and veins, endo- and peri-vasculitis, and œdema of the retina, as a whole. The choroid and pigment epithelium were quite unaffected.

The author points out that tuberculosis of the retina is very rare, especially with giant cells in the tubercle, as in this case. He is of the opinion that the disease began in the anterior part of the globe, and that it passed back to the retina *via* the vitreous. A. J. BALLANTYNE.

(8) **Opin** presents a case of tuberculosis of the bulbar conjunctiva in a boy of 15, who died eight months after its first appearance from general tuberculosis. When first seen, the left eye shewed an epibulbar tuberculoma in the upper limbal region, the neighbouring conjunctiva being much injected and thickened, with a number of "pin's-head" nodules, of yellowish, translucent appearance, dotted here and there. The nature of the growth was determined by the usual clinical and laboratory methods.

Histological examination of the globe, removed after death, shewed that the conjunctiva in the upper ciliary region was replaced by granulation tissue, that infiltration had taken place between the anterior epithelial layer of the cornea and Bowman's membrane, and that the outer scleral layers were eroded but not infiltrated. The rest of the eye was unaffected. The association on the bulbar conjunctiva of both a tuberculoma and miliary nodules, *i.e.*, the bulbar and palpebral types, is noteworthy.

The finding of caseous bronchial glands and an intracranial tuberculoma shewed the endogenous origin of the ocular condition.

BERNARD CRIDLAND.

(9) **Guzmann**, of Vienna, has been fortunate to obtain an eye immediately after the death of a patient from miliary tuberculosis. There had for an

undetermined time been a node, the size of a pea, upon the sclera of the right eye close to the limbus. A very clear uncoloured drawing gives an excellent idea of the histology of the growth. Giant cells and caseating areas proved the tuberculous nature of the node. T. HARRISON BUTLER.

(10) The patient whose case is reported by **Agricola** and **Thies**, was a boy, 16 years of age. The cornea was opaque, and on its posterior surface there were several large precipitates surrounded by numerous smaller ones. The aqueous was cloudy, and there was a mass of exudate in the lower angle of the chamber. A single nodule was seen on the upper pupillary border of the iris. Both local and general reactions to tuberculin were obtained. After three or four months tuberculin treatment the eye quietened and the lustre of the cornea was restored, but the iris was atrophic and the precipitates and exudate in the anterior chamber were still present. Two months later the eye was in the same condition, but slight cerebral symptoms were complained of. Enucleation was refused. Three months later, very pronounced meningeal symptoms came on. The eye was enucleated, with the result that the cerebral symptoms rapidly cleared up, the patient being quite well in three weeks. The microscope showed chronic tuberculosis chiefly affecting the ciliary body. On the posterior surface of the cornea there was a layer of new formed tissue with numerous tubercles implanted in it. The choroid was very little affected, but there were numerous tubercles in the retina. There was no evidence of infection of the retina from the choroid, and the author thinks that the infection took place through the vitreous direct. A mass of tissue, like that of retinitis proliferans, was found in some of the sections near the disc. The retinal tubercles were chiefly perivascular. The author discusses a number of topics, such as the tuberculous nature of retinitis proliferans and of perivasculitis, whether these conditions are due to toxins or to the direct action of bacteria, and whether the infection is through lymph or blood channels.

A. J. BALLANTYNE.

(11) **Friedenwald**, of Baltimore, in a short article, refers to the scantiness of consideration of tuberculosis of the eyelids in British and American literature. As a result, we do not consider tuberculosis as an ætiological factor when small areas of infiltration or ulceration of the eyelids are met with, unless there is a clearly marked appearance of lupus. The German and French handbooks make a clinical distinction between the various forms of lid tuberculosis. Michel, in the second edition of the Graefe-Saemisch handbook, following Mracek, gives the following classification.—(1) Lupus, presenting yellowish-gray or brownish-red nodules from the size of a pin's head to that of a hempseed. (2) Scrophuloderma, in which the lesion usually begins in the lymph glands or lymph vessels, *i.e.*, "cold abscess." (3) True tuberculous ulcer, or miliary tuberculosis of the skin. (4) Tuberculous warts (classed, however, by Michel under the head of lupus). (5) Tuberculous fistula.

Two cases are described by Friedenwald.—In the first the margin of the lid was thickened and inflamed, and somewhat ulcerated, while the skin and conjunctival surfaces were rough, looking much like an inflamed chalazion. In spite of treatment by yellow oxide ointment, the appearances became more and more like those of an incipient epithelioma. A small portion was removed, and proved to be tuberculous. There was no evidence of tuberculosis elsewhere, and the patient was otherwise quite well. There was no enlargement of the preauricular gland. He was given X-ray treatment, and the applications were discontinued when marked reaction occurred. Improvement was slow, but recovery was complete. The second case is that of a child who, aged at the time 13 years, was seen in 1910 by Friedenwald's

assistant. She was then suffering from interstitial keratitis. She had had severe ophthalmia neonatorum. There was no evidence of inherited syphilis, nor was there any history of tuberculosis in the family. Under iodide internally, and atropine and dionine locally, the cornea cleared up, and she was discharged as cured in the spring of 1911. In December of that year she returned with a circumscribed, inflamed, and swollen area around the inner canthus of the left eye. This had been present for three months. The swollen area was smooth, showed no granulation or other irregularities, nor was there any evidence of ulceration. The line of demarcation was not sharp. The redness and swelling extended for a short distance on the conjunctival surface, but here also evidence of ulceration was wanting. Iodide internally and yellow oxide ointment locally had no influence. A piece of tissue from the skin surface was examined microscopically, and shown to be tuberculous. The whole thing disappeared as the result of X-ray treatment, about twelve applications being given before marked reaction set in, and led to discontinuance thereof.

It seems a pity, considering the interesting nature of his cases, that the author has contented himself with diagrams of the situations of the lesions. Coloured drawings would have been much appreciated. ERNEST THOMSON.

XII.—REMEDIES.

(1) **Ochsner, A. J. Practical points in the treatment of exophthalmic goitre.** *Journal of Ophthalmology and Oto-Laryngology*, February, 1912.

(2) **Savage, G. C.—Treatment of detached retina.** *Ophthalmic Record*, July, 1912.

(3) **Muncaster, S. B.—Thyroid with arsenic, and its associated internal secretions in diseases of the eye.** *Ophthalmic Record*, July, 1912.

(4) **Gebb.—On the therapy of diplobacillary infection of the eye. (Zur Therapie der Diplobazillen-Infection des Auges.)** *Bericht der Ophthalmologischen Gesellschaft*, Heidelberg, 1912.

(5) **Terson.—Purulent ophthalmia of the new-born. (De l'ophtalmie purulente des nouveau-nés.)** *La Clinique Ophtalmologique*, 10 novembre, 1912.

(6) **Neves da Rocha.—The use of euphthalmine in nuclear cataracts. (El empleo de la euftalmina en las cataratas nucleares.)** *Anales de Oftalmologia*, February, 1913. (Translated from *Riv. Med. Cir. de Brazil.*)

(7) **Werncke, Th.—On neuritis following treatment with Salvarsan. (Ueber die Neurorezidive nach Salvarsanbehandlung.)** *Zeitschrift für Augenheilkunde*, Mai, 1913.

(1) **Ochsner**, of Chicago, deals with a number of practical points bearing on this subject.

(1) Indication for operation.—Generally, surgical treatment should be employed in every case which does not permanently recover upon treatment with rest, hygiene, diet, and the use of a few harmless remedies, and possibly

also treatment by serum, provided, first, that the patient is not suffering from temporary exacerbation of the hyperthyroidism, and, second, that the condition has not lasted sufficiently long to leave the circulation and the nervous system in an absolutely hopeless condition.

(2) Margin of safety.—Many of these patients have only a very slight margin of safety. Care must be taken that this be not transgressed.

(3) Drainage.—The use of good drainage is indicated.

(4) Traumatism increases hyperthyroidism. It is extremely important to guard against violence in connection with operative manipulations.

(5) Anæsthesia.—This is most important. Ether is used. One per cent. of cocaine injected locally will avoid the use of a general anæsthetic. Ether is administered by the drop method. Morphine and atropine are given hypodermically before operation.

(6) The avoidance of injury to the recurrent laryngeal only needs to be mentioned.

(7) Supply of liquid after operation, by the mouth, by the rectum, or subcutaneously. This to relieve post-operative hyperthyroidism.

(8) After-treatment.—Avoid overwork, excitement, alcohol, tobacco, tea and coffee, late hours, social and business worry.

Diet.—Select a diet largely composed of milk, cooked vegetables and fruits.

(9) Youthful patients.—Young girls, about the time of puberty or a little later, may show symptoms which will justify a diagnosis of incipient exophthalmic goitre. The tremor, the muscular weakness, the nervous excitability, some tachycardia, and many of the minor symptoms are often present. There may be present a slight degree of exophthalmos. These cases will usually improve with general treatment. HENRY L. G. LEASK.

(2) **Savage,** of Nashville, Tenn., found marked and immediate improvement in three cases of detached retina from the subconjunctival injection of a solution of sodium citrate (25 grains to 1 oz.). None of the cases was under observation more than a few days. J. JAMESON EVANS.

(3) **Muncaster**, of Washington, has found the following tablet beneficial in cases of retinitis pigmentosa, choroiditis with old pigment deposits, and cretinism with chronic glaucoma :—

Thyroid gland	...	1 grain.
Adrenal	...	1/60 ,,
Sodium cacodylate		1/200 ,,

He also finds that this combination has not the depressing effect of the thyroid substance alone. J. JAMESON EVANS.

(4) **Gebb**, of Greifswald, has investigated the bactericidal action of various aniline dyes upon the cultivation of diplobacilli ; among them he used methylene water blue, pure blue, and toludine blue. He found that some of these stains definitely inhibited the growth of the organism. He accordingly had a mixture of some of them made by Grübler, and used them in solution as an instillation in cases of diplobacillary conjunctivitis. We cannot gather from the abstract in the *Bericht* which dyes were used, nor are we told what advantage these decidely messy applications have over the salts of zinc, which have proved their specific action in these cases.

T. HARRISON BUTLER.

(5) **Terson,** of Toulouse, while a strong upholder of the classical treatment of purulent ophthalmia by means of silver nitrate, is also convinced of the value of the organic salts of silver, more especially in the early or pre-purulent stage. His prediliction is for argyrol because it is absolutely

painless and therefore causes less disturbance of the infant who is to be treated hourly, day and night, with this drug. In many cases the organic salts can be used right through the case, but if they fail then, as of yore, silver nitrate is the corner stone of the treatment.

When the cornea is affected, silver nitrate should be replaced by the inorganic salts if the ulcer is large. If the ulcer is small the lids may be everted and nitrate used by the specialist in such a way that the cornea escapes from the application. Terson prefers the use of eserine to that of atropine in these cases.

No mention is made by Terson of the now well-recognized fact that these cases frequently become infected with the Morax-Axenfeld bacillus, an occurrence which tends greatly to prolong the treatment if it be not recognized. ERNEST THOMSON.

(6) **Neves da Rocha** has found euphthalmine, in 3 per cent. solution, of great value in certain cases of nuclear cataract, to produce temporary dilatation of the pupil; and thus to allow an improvement of vision. da Rocha states that euphthalmine has no action on the tension or accommodation, and that patients are able often to make life bearable and useful, when they are unable to bring themselves to face an operation. To counteract the blurring which may follow the dilatation of the pupil, he advises the use of glasses coloured yellow, and to avoid all risk of glaucoma (although he has never seen any rise of tension, and thinks this risk minimal), he does not allow the use of euphthalmine after 6.0 o'clock p.m. H. GRIMSDALE.

(7) **Werncke,** of Odessa, discusses the question of the numerous cases of neuritis of cranial nerves which have been associated with the treatment of syphilis with Salvarsan. He criticises the usual explanation that the neuritis is caused by the syphilis and not by the drug. He notes that these cases were becoming very common in Odessa until a death was caused by a Salvarsan injection. The case was ventilated in the public press, and now Salvarsan is little used. It cannot be a coincidence, he thinks, that he no longer sees these cases of syphilitic neuritis! He regards Salvarsan as a very valuable drug; it should be used when mercury and iodides have failed, when they are not well tolerated, or when it is essential to get a very rapid action. He believes that it has a great tendency to cause optic neuritis and neuritis of other cerebral nerves. T. HARRISON BUTLER.

XIII.—MISCELLANEOUS COMMUNICATIONS.

(1) Würdemann, H. V.—Visual malingering. *Ophthalmology*, April, 1911.

(2) Dunn, Percy.—On the tragedies of ocular disease. *Clinical Journal*, September 13th, 1911.

(3) Devaux, Ernest.—The practical value of upright and sloping writing in elementary schools. (Valeur pratique de l'écriture droite et de l'écriture penchée dans les écoles primaires.) *Rev. d'Hygiene*, septembre, 1911.

(4) Hessberg, R.—The eye clinic at the Municipal Hospital at Essen-Ruhr. (Die Augenklinik de Städtischen Krankeranstalten.) *Zeitschrift für Augenheilkunde*, Dezember, 1911.

(5) Leishmann, Lieut.-Col. William B.—The correction of errors of refraction for microscope work. *British Medical Journal*, January 20th, 1912.

(6) **Henderson, F. L.**—A case which demonstrates the hardihood of the human eye. *American Journal of Ophthalmology*, March, 1912.

(7) **Holden, Ward A.**—On occupational diseases of the eye. *Medical Review of Reviews*, June, 1912.

(8) **Spencer, Frank R.**—Recent observations in the eye, ear, nose and throat clinics of Vienna and Berlin. *Journal of Ophthalmology and Oto-Laryngology*, July, 1912.

(9) **Stoll, K. L.**—Procrastination in diseases of the eye. *Journal of Ophthalmology and Oto-Laryngology*, July, 1912.

(10) **Stock, W.**—A new method of illuminating the field of operation. (Ueber eine neue Operationsfeldbeleuchtung.) *Klin. Monatsbl. f. Augenheilkunde*, Juli, 1912.

(11) **Dor, Louis.**—The Ophthalmological Congresses of Oxford and Liverpool (July, 1912). (Les Congrès d'Ophtalmologie d'Oxford et de Liverpool [juillet, 1912].) *La Clinique Ophtalmologique*, 10 octobre, 1912.

(12) **Fox, L. Webster.**—A course in ophthalmology at the University of Colorado. The degree of doctor of ophthalmology. *Ophthalmology*, October, 1912.

(13) **Igersheimer.**—On the behaviour of the bodily temperature in diseases of the eyes. (Ueber das Verhalten der Körpertemperatur bei Erkrankungen des Auges.) *Zeitschrift für Augenheilkunde*, Januar, 1913.

(1) This article by **Würdemann**, of Seattle, is an interesting summary of the different problems which are grouped under the head of malingering. These include self-inflicted injuries of the conjunctiva, cornea, and lens, actual simulation of non-existent amaurosis or amblyopia, simulation or self-infliction in hysterical subjects, exaggeration of real conditions, and the difficulties which arise in cases where one eye was defective, whether known to be so or not, before an accident for which compensation is claimed. Illustrative cases are quoted. A. J. BALLANTYNE.

(2) **Dunn,** of London, touches, in the course of an interesting lecture, upon such affections as intra-ocular growths, orbital sarcomata, glaucoma, ophthalmia neonatorum, ocular syphilis, and infective cyclitis (sympathetic ophthalmitis). SYDNEY STEPHENSON.

(3) In a thesis on this subject, **Devaux** discusses the claims of each type of writing. He is of the opinion that neither type has anything to do with the production of scoliosis or myopia. The following are of greater importance: bad deportment of the scholars, defective illumination, want of adaptation between desk and bench, lessons of lengthy duration. The author thinks, however, that for pupils up to eight or ten years, upright writing offers some advantages; it is easily acquired, does not encourage haste, and is more legible. Sloping writing is recommended for children above ten years. The position of the child should remain the same; all that is necessary is to incline the copy-book fifteen or twenty degrees to the left. P. A. HARRY.

(4) **Hessberg,** of Essen-Rhur, describes the new eye department attached to the Municipal Infirmary which has just been built at Essen-Ruhr. The Eye Clinic was added by the munificence of Frau Hirschland in memory of her former husband. The clinic, which, when completed, will hold fifty beds, cost 152,747 Marks. The space allotted to the out-patient department appears small in comparison with the size of the building, and no dark room is

provided. The examination rooms, of which there are two, can be darkened by blinds. This plan, excellent in a very small clinic where only one surgeon is working, must lead to much loss of time in a large clinic, and will eventually result in cases not being examined with the ophthalmoscope because there is no time to stop all other work by darkening the whole room. We notice no dispensary in the whole building. The water closets and bathrooms are not isolated, in fact those on the ground floor are in the middle of the building, opening out of the main passage. The operation room is tiled, but we are not told that these tiles are dark in colour. If not, with the large bow windows shown there must be much dazzling. On the whole, the arrangements hardly appear to be quite ideal. T. HARRISON BUTLER.

(5) In order to prevent eye-strain from prolonged use of the microscope, and to do away with the need of employing spectacles, **Leishmann** has designed a cap-like aluminium carrier, into the centre of which any lens necessary to correct ametropia is fixed. The little device is placed over the ocular of the microscope. SYDNEY STEPHENSON.

(6) Under the above utterly useless title, (a title which no editor who values his journal as a work of reference ought to allow) **Henderson,** of St. Louis, describes an important case, in which a large fragment of glass remained in the eye for forty days, without doing more harm than that resulting from the actual mechanical injury of the retina and choroid There was found to be, when the patient complained of a sensation as of a foreign body under the lid, a vertical wound of the conjunctiva about 5 mm. long, situated 5 mm. from the limbus in the region of the insertion of the external rectus When the space between the lips of the wound was cleansed of an accumulation of muco-pus, a transparent substance was seen, which proved to be glass, not vitreous. It was removed, after slightly enlarging the wound, and was found to measure 12 mm. by 5 mm. by 1 mm. The wound was closed by a suture. On the fourth day the ophthalmoscope revealed a long tear in the retina and choroid extending from the wound of entrance toward the macula. There were no remnants of intra-ocular hæmorrhage or evidence of there ever having been any. V.A. one week after removal of the foreign body was 6/12, not improved by glasses.

The case is a most remarkable one in view of the total absence of any inflammation of the iris or ciliary body, and of the fact that the patient had worked every night as a machinist from the fourth day after the original injury with a whiskey glass until the intruding portion was removed.

ERNEST THOMSON.

(7) **Holden**, of New York, has a very practical article upon occupational diseases of the eyes, and the means whereby they should be avoided. He regards the occupation of the scholar, from the Kindergarten up, as one of the occupations most harmful to the eye. Although he quotes the muscular origin of miners' nystagmus, yet he says nothing of the important part nowadays believed to be taken by defective lighting in the causation of the condition. In New York, lead and wood alcohol head the list of accidental trade poisons liable to damage sight. There are one hundred and fifty trades in which lead is used sufficiently to be dangerous to the eyes. Enquiries into industrial lead poisoning are now proceeding in the United States, doubtless as a step preliminary to legislation. Blindness is common among the more ignorant population of the city, either from drinking wood alcohol, wittingly or else unwittingly, in cheap adulterated alcoholic beverages. In America, it appears, wood alcohol is rectified, and in that way rendered more palatable. A campaign is now on foot to advertise people of the dangerous properties, as regards sight and life, of wood alcohol. It is

suggested also that wood alcohol, sold under no matter what name by druggists, should be labelled " poison."

An interesting article concludes by discussing the preventive part likely to be played in the future by the Museum of Safety (incorporated three years ago in America), the notification of industrial diseases and poisonings, workmen's compensation laws, and last, but not least, the work of medical societies and boards of health. SYDNEY STEPHENSON.

(8) This contribution is a lengthy and an interesting one. The criticism is candid and fair. Much information is given regarding the American Medical Association, and as to the various courses and fees, in Vienna. The clinics commence on the first day of any month, and it is recommended that one should arrive ten days before, and spend the interval in inspecting the various clinics. One visit is allowed free of charge.

He did not take the course in refraction: a cycloplegic is not used so much as in America. There is a great wealth of clinical material. The people are poor, and take full advantage of the various clinics, and the various clinics work well with one another. There are excellent facilities for teaching. Plenty of well-trained assistants, willing to teach, and in English.

In Berlin, the clinics are, as a rule, smaller, and more scattered, than in Vienna. He says nothing of the eye clinics.

Haab's clinic at Zürich, is singled out as one of the best in Europe. Cleanliness and completeness of equipment, and good results in surgery and treatment are the marked features.

The author evidently prefers the clinics of Vienna to those of Berlin.

HENRY L. G. LEASK.

(9) This paper is a plea to be as wide awake and as up-to-date as possible. The value of the smear, and its microscopical examination, is emphasised and commended in differential diagnosis. Loeffler's methylene blue is a good stain; it only takes two minutes. The solution of Gram-Jadassohn is still better; it takes a little longer, but gives so much more information, and is more exact. The secretion should be obtained from the upper fornix. The differential diagnosis of iritis and glaucoma is considered. Many examples of procrastination are given, and of the resulting evils. " Procrastination is the thief of time," and of a great deal more. Procrastination is too often identical with neglect, and may do irreparable damage. HENRY L. G. LEASK.

(10) The principle underlying the illuminating apparatus of **Stock**, of Jena, is that the light from an arc lamp is thrown on to the same spot simultaneously from three different directions. At a distance of 1 to 1½ metres it brightly illuminates a spot of 15 to 20 centimetres diameter. Its advantages are that the illumination is good, there is no excessive heat, it hangs above the table and therefore is not in the way of operator or assistants, and the interference of a hand with one of the beams of light does not cast a shadow. It is claimed to be especially useful for the illumination of cavities. The lamp itself costs 280 Marks, the fixture from 60 to 120 Marks, according to its nature. The apparatus as made by Zeiss, of Jena. A. J. BALLANTYNE.

(11) It is always interesting, and frequently amusing, to see ourselves as others see us. **Dor**, of Lyons, has written to his journal a report of the Liverpool and Oxford Congresses of the year 1912, which is a curious mixture of seriousness and fun. The British temperament is so diametrically opposite to that of the French that it is not surprising the " chiel amang us takin' notes " should be astonished at the reticence of the British members of Congresses. In connection with a certain very debatable subject, Dor says: " In a German or French Congress ten speakers would have demanded the

opportunity to speak, but at Liverpool there was no response at all, although Mr. So-and-so's objection had been made in an absolutely courteous tone." There occur in the article some strange words to find in a French special journal, such words as "whisky," "American cocktail," "music-hall," "banquets," "garden parties," "toasts," from which it will be evident that the author does not confine his remarks solely to the serious business of the Congresses. ERNEST THOMSON.

(12) The paper by **Fox,** of Philadelphia, describes in detail the arrangements for the course and degree in ophthalmology of the University of Colorado, which were referred to in a recent number of THE OPHTHALMOSCOPE. We note the erroneous statement that "Oxford University in England has the power to confer the degree of *Doctor* of Ophthalmology upon its graduates." A. J. BALLANTYNE.

(13) **Igersheimer**, of Halle.—The burden of the paper is that phlegmon of the lacrymal sac, and other septic conditions around the eye, cause a rise of temperature. The same is true of panophthalmitis. There is a slight rise of temperature in corneal ulcer with hypopyon. Operations upon the globe cause no rise, but the excitement of the operation may send the temperature up slightly. The author was associated with Jagielski in collecting the materials for their instructive work. We cannot, however, agree with Igersheimer when he states that "practically nothing is known about the behaviour of the temperature in diseases of the eye." Perhaps in Germany no charts are kept in eye hospitals, but in England every patient has his daily chart, and everything is known as to the behaviour of the temperature in these cases. T. HARRISON BUTLER.

BOOK NOTICES.

The OPHTHALMOSCOPE offers a hearty welcome to a new journal devoted mainly to refraction. The *Zeitschrift für Ophthalmologische Optik mit Einschluss der Instrumentkunde*, of which the first number, dated 10th May 1913, is before us, emanates from the publishing firm of Julius Springer in Berlin, and is edited by R. Greeff (Berlin), E. H. Oppenheimer (Berlin), and M. von Rohr (Jena). The names of many well-known ophthalmologists are associated on the title page with those of the editors.

In this first number all three editors contribute original articles. Two pages are then devoted to new instruments. Here, we regret to note the carelessness as to English names so often exhibited by our Continental friends; for in a description of Bardsley's Sclerectome the inventor is called "Dr. Hardsley."

A page is devoted to book notices, and two pages headed "*Fragekasten*" correspond to "Queries and Replies" in a British journal.

There are to be six parts per year, and the subscription is 12 Marks.

Le Nystagmus. (Tremblement Oculaire.) By Dr. H. COPPEZ, Agrégé à l'Université Libre de Bruxelles. Paris: G. Steinheil, 2, Casimir-Delavigne. 1913.

This volume contains the report prepared by Dr. H. Coppez as the introduction to a debate on nystagmus at the annual meeting of the *Société Française d'Ophtalmologie* on May 5th, 1913, and includes an exhaustive summary of what is known about the condition.

The author accepts the term nystagmus in its widest sense as including all cases characterised by trembling of one or both eyes, and deals in succession with the forms due to stimulation or disease of the vestibular apparatus, optical causes (*e.g.*:—looking at objects in motion through the window of a railway carriage), diseases of the central nervous system and amblyopia, finishing with coal-miners' nystagmus and the secondary varieties of the disease, *e.g.*, rhythmic physiological nystagmus and voluntary nystagmus. As is natural from the ease with which the condition can be studied, much space is devoted to the consideration of the phenomena and explanation of vestibular nystagmus, with regard to which an interesting theory is developed. Coal-miners' nystagmus is treated in a systematic and practical fashion. Most of the views expressed with regard to it are in accord with those generally accepted in the country, but we notice that the author still regards the abnormal position of the eyes as the predominating factor in causing the disease, and we consider as too dogmatic the statement that there is nothing to prevent a man who has been cured of the disease from resuming his former work.

The book contains a number of tracings taken with Buy's nystagmograph which illustrate well the various forms which the oscillations of the eyeballs may assume. One interesting point is, that in vestibular nystagmus they are always jerky (*à ressort*), while in coal-miners' nystagmus they are undulatory. Other distinctions between the two forms of the disease are that in the former the oscillations are checked by fixation and increased by looking to the side, while the reverse is the case in the latter.

The book is well written, and should be read by anyone who wishes to obtain a comprehensive account of a somewhat complicated subject.

R. J. COULTER.

Transactions of the Seventeeth Annual Meeting of the American Academy of Ophthalmology and Oto-Laryngology. Held at Niagara Falls, Ontario, August 20th, 21st and 22nd, 1912.

This volume reached us in May, 1913, some nine months after the communications it embodies were read. The first 221 pages of this volume of 445 pages is devoted to the eye, and the rest to oto-laryngological subjects. The anniversary address on sympathetic ophthalmia was delivered by Professor A. Elschnig, of Prague, Austria. He was followed by Dr. John McReynolds, of Dallas, Texas.

In addition to the foregoing communications, the volume contains twenty-one other papers read at the meeting. It is, by the way, a thousand pities that the *Transactions* is not provided with an index. S. E.

Ophthalmic Semiology and Diagnosis. (Pyle's System of Ophthalmic Practice.) By CHARLES H. BEARD, M.D. Chicago. Philadelphia: P. Blakiston's Son & Co. 1913. Pp. 400, with 13 coloured plates and 71 figures in the text. Price, $4.00 net.

Beard's contribution to Pyle's International System of Ophthalmic Practice is open to so much criticism on various grounds that the reviewer wishes to say at the outset that it is a book to be welcomed as apparently the first of its kind and that it will be put upon the library shelf with a feeling of certainty that references to it will be very frequent. As the author suggests in his preface, it fills a gap hitherto occupied by no other single work in any language. The amount of information it contains is very great, and must have involved much labour to get together.

The task set himself by the author is thus referred to in the preface: "This book is the outcome of a long-standing conviction on the part of the writer that the rank and file of the medical profession would welcome a treatise of this nature: one that would deal systematically, succinctly and solely with questions of symptomatology and diagnosis as concerns the eye." To say that the author has given us a welcome treatise is one thing; to say that he has exactly succeeded in carrying out his purpose is another. It is plainly visible in the text that in the earlier part of the book the scope has been kept down, and we think too much kept down, to the self-imposed limits, while in the latter part these limits have been considerably widened. Further, the system upon which the author has proceeded, that of dealing with the signs and symptoms of disease as such, rather than with the disease itself as a whole, has led to a certain regrettable want of proper perspective and proportion, and to the omission of certain things which ought not to have been omitted.

The text is divided into two parts.—Part I deals with the lids, lacrymal apparatus, conjunctiva, the globe (deviations, displacements, disturbances of motility, tonicity, modifications in size), the cornea, the iris, the anterior chamber, the pupil, and the lens and cataract. Part II is wholly concerned with the fundus.

In whatever way the general practitioner may regard the work, it is fairly certain that the specialist will consider the second part—that on the fundus—and the chapter on cataract better than the remainder of the first part. The author's powers of observation are acute, his descriptions are excellent, his similes are often much to the point. All the same, the style sometimes becomes lax, the statements loose, and the spelling incorrect. Curious and unfamiliar words abound, and the text is badly marred by errors which should never have been allowed to pass. Thus, we find these:—"Since the centre of motion for the globe lies within the lens, it is easy to locate by their parallactic displacement the variously distributed opacities"; and again, "marking the site of the porous (*sic!*) opticus or physiologic cup." The latter contains a double error. The words "porous opticus," are repeated further on. Typographical errors are very numerous.

In dealing with the fundus the author is at his best. It would be difficult to find better verbal descriptions of the "fine points" of choroidal and retinal disease. The plates of the fundus (some reproduced in colours, others not) are from the author's original drawings, and in the main are excellent. That of leukæmic retinitis, however, does not, to the reviewer's colour sense, represent the magenta tint of the background referred to in the text. We would ask the author why, having devoted six pages of an earlier chapter to the *pathological anatomy* of cataract, he has said so little about the changes in albuminuric neuro-retinitis? Why also does he so aggravatingly touch upon the prognosis of this disease when referring to diabetic retinitis, without actually mentioning the prognosis in the former?

If the book is remarkable for the amount of valuable information which it contains, it is no less remarkable for its omissions. A glance at the contents will show that there is no chapter on diagnostic methods of any kind. These are taken for granted. A second glance will reveal that while there is a *separate* chapter on cataract—a long and excellent chapter it is—there is none on glaucoma, none on the vitreous, none on sympathetic disease. The index is incomplete; it is a poor guide to what the book contains, as we have found by reading the text and comparing with the index. In a book addressed to the "rank and file," corneal ulcer is not discussed in any proper manner; the references to this enormously important subject are most casual. So far as we can find, chalazion is not referred to at

all, while hordeolum is merely mentioned. Deposits on the back of the cornea are dismissed in a word or two: no stress is laid on their examination or significance. No doubt these and other matters which are insufficiently discussed may be taken up in other volumes of the series, but the same might surely be said of signs and symptoms which receive generous treatment at our author's hands.

These criticisms seem to support the contention that the plan of the book has led the author to a kind of wrong perspective. He appears to be looking at one time through one end, and at another time through the other end, of the telescope. We hope that when he gets time to regard his work as a whole, he will see that in many places undue weight has been put on certain points, and very much too little on others, and that the second edition of this really useful work—and in spite of many present defects it is such—will be more perfectly balanced, and also, may we suggest, more carefully read before going to press. ERNEST THOMSON.

Researches in Colour Vision and the Trichromatic Theory. By SIR WILLIAM DE W. ABNEY, K.C.B., D.Sc., D.C.L., F.R.S. Pp. iii and 418. London: Longmans, Green and Co. Price, 21s. net.

This is one of the most important books that has appeared for a long time. Briefly, it may be consulted for the following subjects:

A full description of the colour-patch apparatus in which none but spectral colours are employed. Also of the sector apparatus for modifying the intensity of the light—known in foreign catalogues as the "Episkotiston"—with a most ingenious suggestion for using an American twist drill for the shaft of it. Then follow full directions for applying this method to the study of the absorption of transparent media and pigments, and of the measurement of their luminosity—and we may note that such results, being expressed in terms of sensation, have for some practical purposes a greater value than those of the spectro-photometer which they supplement. Then in Part II come the subjects more immediately interesting to readers of THE OPHTHALMOSCOPE. About 100 pages are taken up with the general phenomena of colour vision and then 135 pages are devoted to the discussion of colour blindness. From the unrivalled opportunities enjoyed by Sir W. Abney, it will be gathered that his collection of cases is most valuable, and the method by which they are recorded is especially adapted to enable us to compare them with other cases. Not the least interesting of the chapters is that in which he describes how to examine for colour blindness with a box of water colour paints and a brush.

For myself the book has a peculiar interest. Sir W. Abney's experiments on colour-vision cover much the same period as my own. We both use none but spectral colours, but his method is almost the exact opposite of my own. Yet we both arrive at the same result, namely, that the theory of Thomas Young is essentially the true one.

Sir W. Abney's method is synthetic. He projects upon a white screen a colour-patch, consisting of light from three selected regions of the spectrum. By varying the proportions of these he matches any given colour. It is the method of Clerk Maxwell, but he has elaborated and improved it, and applied it also to compare the colour-sensations of colour-blind and normal people.

My own method is analytic. It consists in the use of a spectroscope of such wide dispersion that not than one-tenth of the spectrum can be seen at once, and the study of those portions of the spectrum in which a change of hue can be detected, irrespective of the name given to the colour, and also of

the change of position of those parts after exposure of the eye to light of certain standard wave-lengths.

No two methods could be more unlike, yet both lead to Young's theory. There is a slight difference between Sir W. Abney's views and mine, to which he refers, which is, however, easily explained. I advocate the recognition of a fourth colour-sensation, violet, as distinct from blue—as also did Thomas Young in the earlier stages of his theory. But it would be practically impossible to work the four-colour theory with an objective colour-patch method, for two reasons. In the first place, the luminosity of the violet where it gets clear of the blue is so low, and the majority of illuminants are so deficient in violet except in the form of bright lines, which are very unmanageable for quantitative work, that it would be difficult to get enough of it—and, in the second place, the violet excites so strong a green fluorescence in nearly all the available white substances that the colour-equation is entirely altered. It is only by the subjective method of observation that the distinction between blue and violet can be demonstrated. But for the projected colour patch the three colours selected by Sir W. Abney are the best possible, and he states the relation of his theory to mine on p. 364. "The sensation which in this book is called the blue sensation, seems to be intermediate between Dr. Burch's blue and violet."

Five and twenty years ago English physiologists were all in favour of Hering's theory, so that it was quite hard to get a hearing for any arguments in favour of Thomas Young—only the physicists held to him, and they were considered to be behind the times. Now, both in England and on the Continent, there is a strong reaction in his favour, and some of the leading physiologists look upon Hering's theory as disproved. Sir William Abney for five and twenty years has stood to his guns and gone on accumulating an enormous mass of measurements, and he is amply justified in saying—I quote from the preface—"the Trichromatic Theory of Colour Vision does not yet require a funeral oration over its remains. It is not by any means as moribund as some seem anxious it should be considered, but is, in fact, very much alive."

GEORGE J. BURCH, F.R.S.

NOTES AND ECHOES.

The following has been contributed by Mr. H. Holmes, assistant-surgeon to the Liverpool Eye and Ear Infirmary :

Deaths. CHARLES GEORGE LEE, whose death was announced in your last issue, was born at Chester on September 16th, 1852, and educated at Wesley College, Sheffield, and at Guy's Hospital, of which hospital he always remained a sincere admirer. He settled in Liverpool in 1877. Appointed assistant surgeon at the Liverpool Eye and Ear Infirmary in 1878 and elected junior surgeon in 1885, he was keenly interested in the work of the Infirmary, and when the time came for him to retire from active work there (1911), it was a great blow to him. His kindly sympathy and courteous manner made him greatly beloved by his patients, many of whom feel they have lost a true friend. He was highly esteemed by his colleagues, who greatly valued his opinion in all diseases of the eye. As an operator he was, perhaps, always a little wanting in self-confidence. He was a great believer in simple cataract extraction with Teale's knife, and certainly had excellent results with this method. As a man, he was kind, straightforward, and sympathetic, and always ready to lend a

helping hand to one and all. As an eye surgeon he was very conservative in his methods.

Publications.—Actual Cautery in Ulcer of Cornea. *Liverpool, Med.-Chir. Journal*, 1886. Chloroform Administration in Presence of Coal Gas, *Med.-Chir. Journal*, 1895. Simple Extraction of Cataract: Teale's Method, *Med.-Chir. Journal*, 1905. Condition of Eyes in 213 Epileptics, *Med.-Chir. Journal*, 1905. Case of Sinus Thrombosis, *Trans. Otolog. Soc.*, 1907. Treatment of Corneal Ulcerations, *Med. Press and Circ.*, 1908, etc.

As we go to press, we learn with deep regret that Sir Jonathan Hutchinson, F.R.S., died on June 23rd, at his house at Haslemere, Surrey.

* * * *

Appointments.

MR. R. A. GREEVES has been appointed ophthalmic surgeon to the Paddington Green Children's Hospital, London.

Mr. W. H. F. Eales, son of the late Mr. Henry Eales, has been appointed surgeon to the Birmingham and Midland Eye Hospital. His father was a member of the honorary staff of the Hospital for upwards of forty years.

Mr. A. Reginald F. Evershed has been appointed ophthalmic surgeon to the London Association for the Blind.

Dr. Aubaret has been appointed extraordinary professor of ophthalmology at Bordeaux.

* * * *

Committee on Lighting.

THE Home Secretary has appointed a committee to inquire and report as to the conditions necessary for the adequate and suitable lighting (natural and artificial) of factories and workshops, having regard to the nature of the work carried on, the protection of the eyesight of the persons employed, and the various forms of illumination. The members of the committee are: Dr. R. T. Glazebrook, C.B., F.R.S., Director of the National Physical Laboratory (Chairman); Mr. Leon Gaster; Dr. Francis Gotch, Professor of Physiology in Oxford; Mr. J. Herbert Parsons, Ophthalmic Surgeon to University College Hospital; Mr. W. C. D. Whetham, Fellow of Trinity College, Cambridge, well known as a writer on heredity, and Sir Arthur Whitelegge, K.C.B., M.D., Chief Inspector of Factories. The Secretaries of the Committee are Mr. D. R. Wilson, an Inspector of Factories, and Mr. C. C. Paterson, of the National Physical Laboratory. All communications should be addressed to Mr. Wilson at the Home Office.

* * * *

Prizes for Ophthalmological Students.

DR. J. SCHNEIDER, of Milwaukee, the eminent American ophthalmic surgeon who recently gave £5,000 to the Eye Clinic at Würzburg, has just sent £500 more for prizes for students.

* * * *

Memorial to the late Sir Henry Swanzy.

IT is proposed to erect a memorial to the late Sir Henry Swanzy, and a committee, with Dr. J. B. Story as honorary secretary, has been formed to that end. The committee appears to be a strong one. In addition to personal friends of Sir Henry, it consists of members of the medical profession, including ophthalmic surgeons, and members of the public who recognise the benefits conferred upon the Irish poor by the erection in Dublin of an eye and ear hospital which owes its creation almost entirely to Sir Henry's energy and public spirit.

* * * *

Ehrlich as "Hoflieferant."

THE illustrious inventor of "606" being of Jewish origin, the German Emperor has been put to some pains to reward him for his discovery. The Prussian law, as a matter of fact, does not allow of Israelites being decorated or granted patents of nobility. Always ingenious, the Emperor has named him *Hoflieferant*, that is to say, Court purveyor. . . . . "Honi soit qui mal y pense."—*L'Actualité Médicale.*

* * * *

The French Société d'Ophtalmologie.

THE thirtieth congress of the Société d'Ophtalmologie on May 5th brought together a large number of ophthalmologists from Paris, the provinces, and abroad. M. Coppez, of Brussels, dealt with nystagmus, for the study of which, he said, many measures might be utilised, such as direct examination and graphic, kinematographic, and ophthalmoscopic methods. The author dealt with his subject under the following five heads: (1) Vestibular nystagmus, divisible into induced and spontaneous nystagmus; (2) the nystagmus of affections of the central nervous system; (3) the nystagmus of amblyopia; (4) miners' nystagmus; and (5) secondary varieties of nystagmus. Tracings of nystagmus, anatomical pictures, and kinematographic representations were thrown on the screen. M. Marc Landolt, M. Aubineau, M. Morax, M. Terrien, M. Terson, M. Moreau, M. de Lapersonne, and M. Majewski took part in the discussion. The important subject of surgical intervention in glaucoma formed the next item. M. Lagrange described the later results of his operations. M. Kalt, M. van Lint, M. Dor, M. Villard, M. Dehenne and M. Bailliart, M. Chevallereau and M. Offret, M. Bourgeois, M. Dupuy-Dutemps, M. Abadie, M. Polack, M. Armaignac, and M. Cuénod related their observations on different subjects. On the last day M. Terson gave the results of his personal experience in the best method of sterilising the hands before operating, and M. Landrieu, M. Brunetière, M. Liégard, and M. Page related some personal observations. The treatment of ocular syphilis was selected as a subject for consideration at the next meeting in 1914.—*Lancet*, June 14th, 1913.

* * * *

Education for Ophthalmic Practice.

A CONFERENCE on education for ophthalmic practice was held on June 16th at Minneapolis, U.S.A., when the following communications were submitted:—

How Ophthalmologists Have Prepared Themselves for Practice. Dr. Edward Jackson, Denver.

The Obstacle of the Stand-pat Attitude in the Medical Schools. Dr. Frank Allport, Chicago.

Preparation and Needs of Students seeking Post-Graduate Instruction in Ophthalmology. Dr. A. Edward Davis, New York.

Teaching Pathology of the Eye to those Preparing for Ophthalmic Practice. Dr. Casey A. Wood, Chicago.

Systematizing and Improving the Teaching of Ophthalmology in Post-Graduate Medical Schools and Eye Hospitals. Dr. William Zentmayer, Philadelphia.

* * * *

The Study of Ophthalmology.

MEANWHILE, that earnest educationalist, Dr. Edward Jackson, of Denver, U.S.A., has unburdened himself upon the "Supervised and Systematic Study of Ophthalmology" (Seventeenth volume of the *Transactions of the American Academy of Ophthalmology and Oto-Laryngology*). He complains that inadequate provision is made to supply knowledge appertaining to diseases of the eye, the correction of errors of refraction, and so forth. The opticians, seeing their chance, promptly attempted to seize it. Their foremost leader, Mr. Prentice, who formulated the striking statement, "A lens is not a pill," wrote not long ago: "I now unreservedly state my personal conviction that the public will receive the best service from practitioners who shall have in the future collegiately qualified in both optics and medicine." The ideal towards which the American Optical Association is working is that the future eye practitioner should undergo two years of optometry and one of medicine. He should then pass a State Board examination, as independent of medical influence as the present dental examinations are, and should have the title of "Dr." The civilised public will not tolerate much longer the unsupervised practice of ophthalmology. The opticians' scheme is, at all events, a definite proposal to end a situation that has become impossible, As a remedy for this undesirable state of things, Dr. Jackson advocates a modified medical course for those who intend to devote themselve to eye work, together with systematic instruction in ophthalmology, including clinical and laboratory work. The school of ophthalmology should be an integral department in the university. The university should supervise the educational methods, and control the recognition of scientific attainment by proper certificates or degrees. To quote Dr. Jackson's words: "The service of the community, the standing of ophthalmologists as a definite class of professional advisers, and their ability to secure the proper recognition even in the ranks of the medical profession, have suffered greatly from the lack of provision for such supervised systematic study." He mentions incidentally the action taken by the Universities of Oxford, Liverpool, and Colorado in the desired directions.

* * * *

XVII International Congress of Medicine, 1913, Section of Ophthalmology.

IT has been arranged to hold the dinner of the Section of Ophthalmology on Thursday, August 7th, at the Connaught Rooms, Great Queen Street, London, W.C. Price of dinner (inclusive of wine), 21s. Applications to Mr. W. H. Jessop, 73, Harley Street, London, W.

* * * *

Post-graduate training in Ophthalmology in India.

A GOVERNMENT Order has recently been promulgated, the effect of which will be that in future officers of the Indian Medical Service will be allowed to undergo a three months' course of training in ophthalmic work at the Government Ophthalmic Hospital, Madras, an institution under the superintendentship of Col. R. H. Elliot, I.M.S. Officers must be specially selected by the Surgeon-General. Not more than two officers from mufassal stations shall be in attendance at the same time. So far as possible, junior officers of the Indian Medical Service stationed at Madras shall undergo a course of training at the Ophthalmic Hospital without prejudice to their other duties. The Government also consider that selected Civil Assistant Surgeons should be given similar facilities for gaining a special knowledge of eye work. The Government of India, when the arrangements are complete, will be asked to sanction to all officers selected for ophthalmic training the

same concessions as to pay and allowances as are now granted to officers deputed for malaria training, including "halting allowance" for the entire period of training.

Surgeon-General W. B. Bannerman has taken a most prominent part in urging the reform now accomplished by the Government Order.

* * * *

Oxford Ophthalmological Congress.

READERS need scarcely be reminded that the Congress will assemble at Keble College, Oxford, on Thursday and Friday, July 17th and 18th. The programme is most attractive. We can mention only a few of the items here. Addresses are announced by Professor E. v. Grósz (Budapest), Dr. F. Deutschmann (Hamburg), Dr. Igersheimer (Halle), Dr. Mawas (Paris), Dr. McReynolds (Dallas, Texas), Lieut-Col. R. H. Elliot (Madras), Dr. F. W. Edridge-Green (London), Mr. N. C. Ridley (Leicester), and Mr. T. Harrison Butler (Leamington). There will be demonstrations of operations by Col. H. Herbert (Nottingham), Mr. D. Priestley-Smith (Birmingham), Dr. John Hern (Darlington), Mr. W. H. Brailey (Hove), and others. The Scientific Museum will include numerous exhibits of macroscopic and microscopic specimens of interest. Interesting clinical cases will be shown at the Eye Hospital by Mr. P. H. Adams, the reader in ophthalmology, Mr. A. Zorab, and Mr. Harries-Jones. On the afternoon of July 18th there will be a discussion, to be opened by the Master of the Congress, Mr. Robert W. Doyne, "On the Present Position of Ophthalmology." The official dinner of the Congress will be held on July 17th, in the Hall of Keble College, when the chair will be taken by Sir William Osler, Bart. On the afternoon of the 18th it has been arranged to have tea in the Gardens of Worcester College, when members will be received by Sir A. F. Bradshawe, K.C.B., and Lady Bradshawe. Golf has been arranged for devotees of that "ancient and honourable sport."

THE OPHTHALMOSCOPE DIARY.

Oxford Ophthalmological Congress.	July 17th and 18th	Keble College, Oxford.
Section of Ophthalmology, *British Medical Association.*	July 23rd to 25th	Brighton.
Belgian Society of Ophthalmology	Aug. 2nd and 3rd	Ghent
Section of Ophthalmology, *XVII. Int. Congress of Medicine.*	Aug. 7th to 12th	London.
American Academy of Ophthalmology and Oto-Laryngology.	Oct. 27th to 29th,	Chattanooga, Tenn., U.S.A.

THE

OPHTHALMOSCOPE.

A MONTHLY REVIEW OF CURRENT OPHTHALMOLOGY.

VOL. XI.—No. 8.] *AUGUST 1, 1913.* [TWO SHILLINGS.

CONTENTS.

Original Communications.— PAGE

1. F. A. Juler, F.R.C.S.—Acute purulent Keratitis in Exophthalmic Goitre, treated by repeated Tarsorrhaphy, resection of the Cervical Sympathetic, and X-rays: Retention of Vision in one Eye ... 456
2. Arthur J. Ballantyne, M.D.—Pulsation of the Retinal Arteries (concluded) ... 460
3. Wm. Campbell Posey, M.D.—Two Unusual Orbital Conditions. 466

Clinical Memoranda.—

1. Thos. A. Peel, M.B., B.S.—Notes on the Vaccine Treatment of Infections which involve the Cornea ... 471
2. George A. Paul, M.B., Ch.M.—Congenital Coloboma of both Upper Lids ... 473

Current Literature.—

I. Comparative Anatomy and Physiology of the Eye ... 474
II. Immunity ... 479
III. Anaphylaxis in Eye Work ... 480
IV. General Anæsthesia ... 482
V. Eclipse Blindness ... 482
VI. Recurrent Œdema ... 483
VII. Sclero-Corneal Trephining ... 484
VIII. Ocular Sporotrichosis ... 485
IX. Modern Metallurgy in Ophthalmology ... 487
X. Nodular Opacities of the Cornea ... 488
XI. Keratoconus ... 490
XII. Methods ... 491
XIII. Cell Bodies in Trachoma ... 492
XIV. Discussion on Chronic Irido-Cyclitis ... 496
XV. Remedies (seventh notice) ... 498

Book Notices ... 500

Correspondence ... 502

Notes and Echoes ... 503

ORIGINAL COMMUNICATIONS.

ACUTE PURULENT KERATITIS IN EXOPHTHALMIC GOITRE, TREATED BY REPEATED TARSORRHAPHY, RESECTION OF CERVICAL SYMPATHETIC, AND X-RAYS: RETENTION OF VISION IN ONE EYE.*

BY

F. A. JULER, F.R.C.S.

ASSISTANT-SURGEON TO THE CENTRAL LONDON OPHTHALMIC HOSPITAL.

Case.

Mrs. S., age 36 years, was seen on May 27th, 1912, by Mr. Henry Juler, to whom I am indebted for permission to publish the case. She was suffering from extreme exophthalmos, with hypopyon and suppurative keratitis, of the right eye.

The details of the previous history have been kindly supplied by Dr. P. C. Bent, who first attended the patient in July, 1911, for general debility and indigestion. In September of that year she began to lose weight, œdema of the eyelids appeared (there was no albuminuria), and the skin showed a yellowish-brown tint. In the following November, there was tachycardia, pulse 135 per minute, very marked tremor, slight enlargement of the thyroid, and exophthalmos.

In January, 1912, the exophthalmos increased, especially in the right eye; pulse 100 to 120 per minute. She went into a nursing-home for six weeks, and until May, with rest and medical treatment, all the symptoms improved except the proptosis. This was treated with lotions, ice compresses, and protective bandaging.

The general treatment was altered from time to time: internally, belladonna and arsenic, Blaud's pills and digitalis, and thyroidectin tabloids.

On May 24th the right eye had become more proptosed and inflamed. At the time of the visit three days later, there was marked proptosis of the right eye, the conjunctiva showed intense congestion and chemosis, the cornea was hazy in its whole extent, its lower half being ulcerated and purulent, and hypopyon was present. There was nearly complete immobility of the globe: the upper lid could by an effort cover the upper part of the cornea only, the lower lid could not ascend over the chemosed conjunctiva.

The left eye at this time showed marked exophthalmos, but no signs of inflammation: movements of the globe were full.

Under local anæsthesia, several incisions into the right orbit were made, and paracentesis of the anterior chamber was performed. It was then possible to bring the lids together, and they were bandaged under a wet dressing.

During the next three days, the proptosis recurred, and the cornea became purulent in its whole extent: as the condition was progressing to panophthalmitis, the eye was removed under general anæsthesia. There was no excessive hæmorrhage at the operation, nor was there any persistent oozing from the socket afterwards.

On May 31st, the surface of the left cornea appeared roughened in its lower

* Communication read at a meeting of the Ophthalmological Society held on April 24th, 1913.

third, the ocular conjunctiva in the palpebral fissure was somewhat congested, and the movements of the globe were slightly limited. The patient was seen by Mr. E. Treacher Collins.

On the evening of the same day, despite wet compresses and irrigation, the immobility of the globe had increased, the lids could meet only with an effort, and the corneal patch was assuming a yellow appearance. Under general anæsthesia, the external canthus was divided, the orbital tension relieved by deep incisions, and tarsorrhaphy performed after splitting the lids. It was found that the yellow appearance was due to adherent muco-pus and washed off in irrigation. After four days, the lid stitches gave way, and the proptosis and corneal condition soon became as threatening as before.

On June 7th, Mr. F. F. Burghard exposed the left cervical sympathetic, and removed the lower half of the superior ganglion, together with an inch of the adjacent nerve. The orbit was incised, the conjunctiva detached from the limbus and brought together over the cornea, and the tarsorrhaphy repeated.

On the third day after operation, the proptosis was thought to be slightly less, and the globe could be felt to move under the lids. After ten days, the stitches came away or were removed, and the few strands of union broke down. Although the tension behind the globe was not so great, and the cornea had improved, yet the condition of the latter still looked threatening. The lids were then kept in apposition for a time by a few mattress sutures, but the corneal suppuration recurred.

On June 29th, under general anæsthesia, orbital incision, canthotomy, and conjunctivoplasty were repeated, and tarsorrhaphy was performed with more extensive flap formation. The lids remained closed for some ten days, but only one narrow band of union persisted. The cornea, however, healed, and no further ulceration has taken place, whilst the conjunctiva gradually became less congested.

X-ray treatment to the thyroid gland was commenced by Dr. Harrison Orton on June 20th. The patient had six treatments up to August, and then went away much improved in health. In September, a second course of six treatments at weekly intervals was commenced, followed by three at fortnightly intervals, and, finally, three more at intervals of one month.

Progress and Course.

Condition on April 4th, 1913.—Patient looks and feels in good health: she has gained over two stones in weight since July, 1912. Pulse 80 per minute; thyroid normal to palpation; tremor very slight, and sometimes absent.

The left eye is still proptosed, although the exophthalmos is less than it was. The lids cover the globe almost completely without any effort. A narrow fibrous band connects them at the junction of the outer and middle third of the lid border. The movements of the globe are full. The right socket is fuller than is usual after enucleation. Vision $= \frac{5}{12}$. There is a nebula on the lower part of the cornea: the pupil is active but small (2 mm.).

Remarks.

The rarity of this complication of exophthalmic goitre decided me to bring this case forward, and to investigate the literature on certain points, especially (*a*) the pathology of the corneal involvement, (*b*) the effect of sympathectomy on exophthalmos, and (*c*) treatment.

Sattler[1] has collected the published cases of corneal involvement in exophthalmic goitre up to 1907. Such range from a mild desquamating keratitis to an acute suppuration, resulting in loss of the eye. He refers to

forty cases in which both eyes were lost, nine cases with complete loss of vision in one eye and partial loss in the other, and fourteen cases with complete opacity of one cornea. There have also been published milder cases resulting in partial opacity of the cornea of one or both eyes.

In the severe types, local therapy has often availed but little: the condition has progressed in spite of bandaging, tarsorrhaphy, lotions, cautery, curetting: in some cases the suppuration has even started after prophylactic tarsorrhaphy; others have been relieved by tarsorrhaphy.

The cause of the keratitis was thought by A. von Graefe[2] to be neuroparalytic, but evidence of this is not forthcoming: the sensibility of the cornea is diminished early, but the same fact can be demonstrated over most corneal infiltrations: further, there is no evidence of loss of function in other branches of the ophthalmic division of the fifth cranial nerve.

Keratitis e lagophthalmo explains the majority of the mild cases, by desiccation of the epithelium from exposure, followed by secondary infection and ulceration.

In the more acute types the chief features are increase in exophthalmos, immobility of the globe, congestion of the lids, marked chemosis, and destruction of the cornea; the latter commences as a superficial desquamation in the lower part and continues as a rapid purulent infiltration, which extends to the whole cornea, and results in perforation or total necrosis.

There are several factors at work:—Firstly, an exacerbation of the exophthalmos from a vascular turgescence of the orbital contents; this is probably due in some way to thyroid activity, although there are those who still hold that the sympathetic is at fault. Secondly, the pressure of the sclera against the separated lids; this causes a partial strangulation of the ocular conjunctiva, increasing the congestion and chemosis in the palpebral fissure, and must impair the nutrition and natural resistance of the cornea. Finally, the desiccation of the exposed cornea, which permits the entrance of micro-organisms.

This course was well seen in the first eye of the case above related, and the explanation is borne out by observations on the second eye. Although orbital incision and tarsorrhaphy had to be repeated three times, on each occasion when the lids separated again, the corneal condition had improved and the globe was more mobile.

von Poppen[3] had a case in which he obtained temporary improvement by snipping the outer canthus to relieve the pressure of the globe against the lids, but tarsorrhaphy was not performed, and both corneæ finally necrosed.

Pooley[4] has related a case in which the left eye was lost, but the right was only slightly affected. In this patient the left had always shown a much higher degree of exophthalmos.

Sattler[1] points out that corneal suppuration is commoner in the more severe cases of exophthalmic goitre; for twelve patients out of sixty-three died not long afterwards. He considers that there must, in addition, be some toxæmia which reduces the corneal resistance. The present patient, on the other hand, was in very fair condition, and Dr. R. W. Collum administered chloroform and ether mixture four times with no ill-result.

The non-union of the first tarsorrhaphy in the present case gave warrant for the performance of sympathectomy on the left side. Since 1895 this operation has been done for exophthalmic goitre in France, and especially by Jaboulay and Jonnesco.

I have been able to find only a few cases in which the operation was performed in the presence of corneal suppuration.

One was a case of Reclus and Faure[5], with marked proptosis and nearly

complete immobility of the globes. It is reported that on the evening after the operation the lids could be closed for the first time in ten years, and in three weeks the exophthalmos was very much diminished. In another case, operated on by G. Marchant[6], there had been exophthalmos for four years with slight keratitis. Bilateral resection of the superior cervical ganglion, with four centimetres of the cord below, resulted in immediate diminution of the exophthalmos, whilst two days later, the globes were completely covered by the lids.

Jonnesco[7] had a case in which sight had been lost for one-and-a-half years owing to corneal opacity; vision amounted to perception of light, and the patient had to be led about. Total bilateral resection of the cervical sympathetic was followed by great diminution in the exophthalmos, the vision improved, and the patient was able to get about by himself.

The results of this operation were collected by Balacescu[7] in 1902 We are here chiefly interested in the effect on exophthalmos; out of 41 cases improvement in this symptom was noticeable in 34 after a few hours or days, in 3 cases one eye only was improved, in 4 there was no effect. Later results, given in 25 cases, showed marked improvement in or disappearance of the symptom in 19 cases, no change in 3, increase in 3; the last observation being two-and-a-half months to five years after operation.

Of the 3 cases which showed increase of exophthalmos, one (Peugniez) improved at first, but the patient returned with exaggeration of the general symptoms, suppuration of both corneæ took place, and death occurred seven weeks after the second operation. In another case (Sonlié) there was initial improvement, but recurrence set in and exophthalmos appeared for the first time.

Jaboulay's[8] later results, published in 1911, do not give the effect on the exophthalmos, but he expresses himself as pleased with his results.

In the present case there was no marked recession after section of the nerve, although it was thought that the proptosis showed a slight reduction on the third day. It has been suggested that some improvement might follow any operation in the neighbourhood of the thyroid gland.

On the whole, therefore, when allowance is made for the enthusiasm of the early operators, it appears that in some cases exophthalmos has decreased after section of the cervical sympathetic, but that this result is by no means always attained, and in one case at least, suppuration of both corneæ has occurred some time after resection of both sympathetics in the neck.

The question of partial thyroidectomy in exophthalmic goitre has been discussed by Berry[9] in the Lettsomian Lectures of this year and he gives his reasons for viewing the operation with favour in suitable cases. The same matter was also before the Royal Society of Medicine[10] last year, when varying opinions were stated. Several surgeons had noticed greater diminution in the exophthalmos on the side from which the thyroid lobe had been removed. On the other hand, I have recently heard of a case in which acute purulent keratitis caused total loss of vision a considerable time after apparently successful thyroidectomy.

Treatment with *X*-rays in exophthalmic goitre is still *sub judice*. Many observers have reported favourably of the procedure; but it appears that some care is necessary in order to avoid too extensive fibrosis of the gland; for a condition of myxœdema may be the final result.

Dr. Orton reports that he has treated a large number of cases with *X*-rays, and that they nearly all show marked improvement. In his experience, the exophthalmos persists longer than any other manifestation, although even this ultimately yields.

Conclusion.

In conclusion, with regard to treatment of this complication of exophthalmic goitre, consideration of the present case suggests that orbital incision and free tarsorrhaphy should be the first step, and may be repeated if necessary. It is important to relieve the pressure of the globe against the lids, and after splitting the latter, skin flaps can be obtained from the region of the outer canthus and brought together, so as to diminish tension.

The question of partial thyroidectomy or sympathectomy must remain doubtful, and in each case the general condition of the patient is of importance. Contra-indications given by Berry include enlarged thymus, dilated heart, or other evidence of visceral degeneration. X-ray treatment may prove of value, especially if operation is contra-indicated.

Some of the cases with severe general symptoms may appear hopeless, but it is to be remembered that, as Sattler[1] has pointed out, such cases have sometimes improved remarkably when the acute eye manifestations have subsided.

REFERENCES.

1. **Sattler.**—Graefe-Saemisch *Handb. der Ges. Augenh.*, Teil ii, Kap. XIV, 1908, S. 126.
2. **A. von Graefe.**—*Berlin klin. Wochenschr.*, 1867, Bd. IV, S. 319.
3. **von Poppen.**—"Ueber die Erkrankung der Hornhaut bei Morbus Basedowii mit Exophthalmus. *Deutsche med. Woch.*, Bd. XXXVI, S. 2002.
4. **Pooley.**—"Atypical exophthalmic goitre." *New York Medical Journal*, 1910, Vol. XCI, p. 23.
5. **Reclus et Faure.**—"Résection bilatérale du grand sympathique cervical dans le goitre exophtalmique." *Annales d'Ocul.*, T. CXVIII, p. 38.
6. **H. Herbet.**—"Le sympathique cervical." *Thèse de Paris*, 1900, p. 94.
7. **Balacescu.**—"Die totale und bilaterale Resection des Sympathicalis Cervicalis beim Morbus Basedowii." *Archiv f. klinische Chirurg.*, 1902, Bd. LXVII, S. 105.
8. **Jaboulay et Chalier.**—*Lyon Médical*, T. CXVII, 1911, p. 501.
9. **Berry.**—"The surgery of the thyroid gland." *Lancet*, 1913, p. 583, p. 668.
10. *Proc. Royal Soc. Med.* (Surgical Section) 1912, Vol. V, p. 66

PULSATION OF THE RETINAL ARTERIES.

BY

ARTHUR J. BALLANTYNE, M.D.

SURGEON, EYE INFIRMARY, GLASGOW.

(*Concluded.*)

Is it possible to determine what diseases favour the occurrence of the pathological pulse, and the circulatory conditions, in virtue of which they do so? The following facts emerge from a review of the cases of our first group, the medical cases :—

(a) *The locomotor pulse.*—This was found in 75 cases. Of these 25 suffered from organic disease of the heart, 5 being cases of aortic regurgitation, and the remaining 20 having lesions of the tricuspid or mitral valves, chiefly the latter. The other conditions which were found among the 75 cases were anæmias (including 10 cases of other diseases in which anæmia was a prominent feature), 21 cases, debilitating diseases (malignant, gastric ulcer, syphilis, diabetes), 11 cases, chronic nephritis, 10 cases, and one or two cases each of acute nephritis, pleurisy, bronchitis, phthisis, pneumonia, sciatica, ataxic paraplegia, epilepsy, exophthalmic goitre and eczema. There is no important difference between this list and that of the 211 medical cases which did not exhibit an arterial pulse, which was as follows: Cases with organic heart disease 51, chronic nephritis 28, acute nephritis 7, anæmias 15, chronic debilitating diseases 26, and in smaller

numbers pneumonia, rheumatism, pleurisy, empyema, bronchitis, phthisis, tabes, disseminated sclerosis, Landry's paralysis, paraplegia, hemiplegia, sciatica, chorea, epilepsy, neuritis, neuralgia, hysteria, thoracic aneurysm, uterine disease, arteriosclerosis, Raynaud's disease, exophthalmic goitre, duodenal ulcer, gallstone, otitis, psoriasis and erythema nodosum. Of the 51 cases of this series which had evidence of organic heart disease only 2 had the murmur of aortic regurgitation.

(b) *The expansile pulse.*—This was found in 32 cases, all of which had organic heart disease. One was a case of profound anæmia, with doubtful mitral regurgitation, two were acute rheumatism with mitral regurgitation, one was convalescent from acute rheumatism with pericarditis. All the others (28=87·5 per cent.) gave evidence of aortic regurgitation. In only two of the 28 did the aortic incompetency seem to be uncomplicated. Eleven had the double aortic murmur, 12 had the double aortic murmur and that of mitral regurgitation, and 2 had aortic regurgitation and mitral regurgitation. In another aortic regurgitation was only one element in a severe case of endocarditis, pericarditis, and pleuro-pneumonia.

(c) Of the 13 cases which showed the *capillary pulse*, 12 had the signs of aortic regurgitation (complicated with other murmurs in 11), while the remaining case had cardiac disease apparently not aortic (subacute rheumatism with double mitral disease and anæmia.)

(*d*) The pressure pulse was observed only once among the medical cases, the example being one of aortic regurgitation.

Returning to the lists of diseases in which the *locomotor* pulse did or did not occur, there are three classes of cases which occur in comparatively large numbers, *viz.*, organic heart disease, chronic nephritis, and anæmias. Twenty-five heart cases showed the locomotor pulse, and 51 did not, which means that in heart cases as a whole the proportion of positive* to negative was about the same as among healthy subjects, *viz.*, 1-2, and the same is true of chronic nephritis, but of 36 anæmias, 21 had the locomotor pulse, a much higher proportion than in the case of normal subjects. Again, if we select from the cardiac cases those which had aortic regurgitation, eight in number, six were positive and two negative, and here also the percentage is much above the 33 per cent. of the normal (refraction) cases. Although for the other diseases on the lists the numbers are small, we find that the frequency of the locomotor pulse is higher than that for healthy subjects in the case of diarrhœa, debility, and malignant disease, while for all others the pulse is less frequent than under physiological conditions.

From these figures it appears that two pathological conditions, *viz.*, anæmia and aortic regurgitation, are peculiarly liable to be accompanied by a pronounced, and probably pathological, locomotor pulse. The figures referring to the expansile pulse are even more instructive. Here 28 out of 32 had aortic regurgitation, while anæmia was a prominent feature in one of the others. In this group, by far the most important condition is aortic regurgitation, and the same applies to the cases showing the capillary pulse, for here 12 out of 13 had aortic regurgitation. The same disease was responsible for the only example of the pressure pulse.

Anæmia and aortic regurgitation are thus seen to be the diseases most liable to produce an arterial pulse in the retina, anæmia being of secondary

*The positive cases included cases of aortic regurgitation (in combination with aortic stenosis, mitral stenosis, mitral regurgitation, or tricuspid regurgitation), mitral stenosis, mitral regurgitation with pericarditis and pleurisy, stenosis of the pulmonic valve, and myocardial disease, indeed it may be said that there is scarcely a valvular lesion, or combination of lesions, which may not be associated with the locomotor pulse in the retina.

importance, since the more fully developed phenomena of the expansile, pressure, and capillary pulses, were to a much greater extent conditioned by the presence of aortic regurgitation.

It is unnecessary to give further details to prove that aortic regurgitation is the condition *par excellence* in which the arterial pulse is found in the retina, and experience of these cases shows that it is by far and away most pronounced in all its forms in that disease. That being so, it will probably help us to understand the pulse better if we bear in mind the conditions present in a typical case of aortic regurgitation. The incompetence of the valve allows more or less of the blood expelled at systole to regurgitate into the ventricle during diastole, hypertrophy and dilatation of the left ventricle occur, and hence at each systole an abnormally large volume of blood is forcibly thrown out into the aorta, while at diastole the volume of blood in the aorta abruptly falls through failure of the valves to prevent its return. This results in the transmission into the arteries of a pulse wave which is of large amplitude, abrupt in its rise and fall, and of short duration. The great variations of pressure to which the arteries are subjected by these abnormal conditions, make it impossible for them to maintain their normal tonicity, they become more lax, and this not only renders more manifest the abnormal character of the pulse wave, but allows it to be propagated to a greater distance than under normal conditions, even to the capillaries. The laxity of the arteries is also manifested by a tendency to elongation, showing itself as tortuosity in the retina as elsewhere. Hence we have the familiar symptom of a pulse which is short, sudden, of large amplitude, and collapsing in character. The pulse is visible or palpable in the smallest accessible arteries, and the capillary pulse may be easily elicited in the skin and mucous membranes. As a rule the mean blood pressure is low, and it is not uncommon to find a distinct anæmia of the simple secondary type. These circulatory conditions are just those most favourable to the occurrence of even the locomotor pulse in its most striking form, and they are essential to the occurrence of the well-marked expansile pulse, or of the capillary pulse.

We have seen that the great majority of the cases which show a distinct arterial pulse in the retina, are cases of *aortic incompetence*, and broadly speaking it may be said that cases not suffering from this condition, which show a distinct expansile or capillary pulse in the retina, do so only in so far as they present circulatory conditions resembling those above described.

It would seem that *anæmia* does not, as a rule, cause the expansile or capillary pulse, although there are exceptions to this, but that it is an important, and often the only discoverable cause of the locomotor pulse. Two factors probably come into play here, (1) the tortuosity of the retinal arteries, a recognised feature of the anæmic fundus and evidence of the longitudinal stretching of the vessels due to loss of tone, (2) the height of the pulse wave which reaches the peripheral vessels, also due to loss of tone in the arteries of larger size. Raehlmann[18] attributes the occurrence of the locomotor pulse in anæmic conditions to increased mobility of the blood due to hydræmia, and diminution in the number and size of the blood corpuscles. At the same time he recognises the part played by the sudden high pulse wave due to the energetic action of the heart. The increased mobility of the blood acts by allowing an exaggeration of the velocity pulse, the accellerated stream tending to straighten out the arteries where it meets resistance at the bends. Raehlmann's hydræmic and oligocythæmic theory is refuted by Schmall[21], but supported by Friedrichson[22] on the basis of actual measurements of specific gravity, and of number and size of red corpuscles, in

cases of anæmia. In my own cases I have not found any definable relationship between the percentage of hæmoglobin and corpuscles and the presence or absence of the pulse. In any case, as I have already pointed out, the locomotor pulse is not due to straightening of the bends, but to increase of their amplitude, and is an expression of the pressure variation, not of the velocity pulse.

The occurrence of the pulse in anæmia and allied conditions is due to the propagation into the retinal arteries of a high, short, and steep pulse wave, and to the loss of arterial tone which favours the appearance of the locomotor pulse by causing tortuosity of the retinal arteries.

One would be glad to be able to accept the suggestion of Thoma[23] that the presence of the locomotor pulse in tortuous arteries may indicate the early stage of arteriosclerosis, and enable us to adopt treatment when it is likely to prove beneficial. My observations, however, do not bear this out. It is certain that in many cases of retinal arteriosclerosis the silver wire appearance and other evidences are associated with undue tortuosity of the arteries, and that the arterial pulse is conspicuous by its absence in such fundi, but it is equally certain that in many cases all the characteristic sclerotic changes are shown by vessels without undue tortuosity, nor could I find in cases at an age when arteriosclerosis might presumably be commencing, that either the locomotor pulse, or tortuosity of the vessels, was particularly frequent.

Several writers (Becker[11], and Raehlmann[18]) have described cases of *aneurysm* of some part of the arch of the aorta, in which there was inequality in the degree of arterial pulsation in the two retinæ, and an attempt was made to use this as a means of determining the situation of the aneurysm in relation to the great branches of the arch. But since the different observers were not agreed about the phenomena in apparently similar cases, their inferences have no value. My own observations of such cases are few. My series includes seven cases diagnosed as aneurysm of the thoracic aorta. In five there was no arterial pulse in the retina. In two there was equally marked pulse in both retinæ. One of the latter came to *post mortem* examination, and an aneurysm was found occupying the arch between the innominate and the left common carotid, so that some influence on the retinal pulse might have been expected. The possible value of any such difference is, however, entirely discounted by the fact that in all classes of cases inequality of the pulse in the two eyes, or its presence in one eye only, is not at all uncommon. In my cases the pulse was noted twenty times as being more pronounced in the right eye, and eleven times in the left.

From references by one or two authors, the arterial pulse in the retina seems to be rather more frequent and pronounced in *exophthalmic goitre* than in healthy individuals. Raehlmann would trace the presence of the pulse in these cases to an accompanying anæmia with hydræmia. I saw an arterial pulse in two out of four cases of this disease, and in one of these there was certainly no anæmia. I am inclined to explain the pulse in these cases by the combination of loss of vascular tone with energetic action of the heart, leading to circulatory conditions somewhat resembling those found in aortic incompetence.

No reliable statement can be made as to the frequency of the various forms of pulse in *glaucoma*. The phenomena have been described most frequently in cases of the subacute or chronic non-inflammatory types. The characteristic pulse in these cases is, of course, the "pressure" pulse, but this is not by any means always present. As von Graefe pointed out, if not present it may be easily elicited by finger pressure. In two cases of chronic glaucoma I have seen a well marked expansile pulse in the parts of the arteries on or near the

disc, which became more distinct on slight pressure, and had added to it the pressure pulse on the disc.

Summary.

We may now sum up what we have learned as to the clinical significance of the different forms of the arterial retinal pulse.

(1) *The locomotor pulse* in its slighter form may be considered physiological or at least not pathological. Excitement is probably responsible for its temporary appearance in some cases. The only forms of illness which appear to favour the occurrence of a locomotor pulse, apart from the pronounced degrees of it associated with the expansile pulse, are anæmia, and perhaps certain forms of debilitating disease, such as diarrhœa and malignant disease, and the latter probably act in the same way as anæmia, namely, through loss of vascular tone. In its most pronounced form the locomotor pulse has the same significance as the expansile pulse.

(2) *The expansile pulse* has also been observed in healthy persons, but not nearly so frequently as the locomotor pulse. In the great majority of cases it is associated with incompetence of the aortic valves, and apart from this it seems to occur only when the circulatory conditions characteristic of aortic incompetence are more or less in evidence. So frequent is its occurrence in this disease, that its absence leads one to look for some feature of the case which would explain this. Various writers have stated that the pulsation does not occur, or is less likely to occur, in aortic regurgitation complicated with aortic stenosis or with mitral disease, but my notes do not fully bear out these statements. The cases which showed pulsations included examples of aortic regurgitation in combination with stenosis, and with every other valvular lesion, as well as with pericarditis. As regards the influence of aortic stenosis, it has to be remembered that the presence of a systolic murmur referable to the aortic valve does not necessarily indicate the presence of stenosis. This well known fact is borne out by my cases. Three cases came to *post mortem* examination, in which there was supposed to be both incompetence and stenosis of the aortic valve, but stenosis was not found in any of them. I have no positive case in which the presence of stenosis was confirmed *post mortem*, so that I am not in a position to say that pulsation may occur in the presence of aortic stenosis, but if this lesion does prevent the occurrence of the pulse, it will do so in so far as it reduces the height of the the pulse wave, and generally, neutralises the circulatory peculiarities due to the aortic incompetence. The truth of the statement already made, that the occurrence of the arterial pulse in aortic regurgitation is dependent on the high pulse pressure and the laxity of the vessels, is borne out by the cases of aortic regurgitation in which the pulse was slight or absent. Two had no arterial pulse at all. In one of these the heart was not enlarged, its beat was not strong, and there was arterio-sclerosis. The other case, although presenting the murmur of aortic regurgitation, had none of the circulatory symptoms already referred to, and probably suffered from a fatty or fibroid condition of the myocardium. Four cases had the locomotor pulse only. The first had obvious failure of compensation, and was complicated with mitral stenosis. The second also had mitral stenosis in addition to the aortic regurgitation. In it the locomotor pulse was very pronounced. The third and fourth, in which the pulse was only very slight, had aortic regurgitation merely as an inconspicuous element, along with mitral and tricuspid disease. There was one exceptional case in which the radial pulse had the waterhammer character, and in the retina the locomotor and capillary pulses were seen. The expansile pulse was not noted, but may have been missed.

It will be noticed that mitral stenosis was present in several of these cases, while it never occurred among the 32 cases in which the expansile pulse was found. One is therefore tempted to assume that mitral stenosis is antagonistic to the occurrence of the expansile pulse, and accounts to some extent for its absence in cases where it would otherwise be expected. But probably in this, as in the case of aortic stenosis, the determining factor is not the mere presence of the valvular murmur or even of the lesion, but the presence of conditions of the general circulation which can be diagnosed by attention to the action of the heart and the characters of the peripheral pulse.

An apical systolic murmur was quite commonly found in cases showing the expansile pulse. This may or may not have denoted mitral regurgitation in every case, but that the presence of this lesion does not interfere with the occurrence of the pulse is proved by the results of *post mortem* examinations.

When a well marked expansile pulse is present it is practically always accompanied by an equally well marked locomotor pulse.

(3) About one half of the cases which showed the expansile pulse had at the same time a *capillary pulse* on the disc, and, as the latter is rarely seen apart from aortic regurgitation, its significance is similar to that of the expansile pulse. I have seen it in a case of subacute rheumatism with double mitral disease and anæmia, and have also produced it in normal eyes by finger pressure.

(4) *The pressure pulse* has been most frequently described as a symptom of glaucoma, and as a regular or persistent event it has only been found in that connection, but it has been seen in cases of aortic regurgitation, and on several occasions its sudden appearance during ophthalmoscopic examination has given warning of the onset of syncope.

REFERENCES.

1. **Helmholtz.**—*Beschreibung eines Augenspiegels*, etc., 1851.
2. **Van Tright.**—*Nederlandische Lancet*, Bd. II, 1853.
3. **Coccius.**—*Ueber die Anwendung des Augenspiegels*, 1853.
4. **Jaeger, Ed.**—*Wiener med. Wochenschr*, 1854, Hefte II, III, IV, V.
5. **Quincke, H.**—*Berliner klin. Wochenschr*, 1868, Heft 34.
6. **Graefe A. von.**—*Archiv f. Ophthalm*, Bd. I, Heft 1, 1854, S, 371.
7. **Graefe, A. von.**—*Archiv f. Ophthalm.*, Bd. I, Heft 1, 1854, S. 382.
8. **Graefe, A. von.**—*Archiv f. Ophthalm.*, Bd. X, Heft 1, 1864.
9. **Quincke, H.**—*Berlin. klin. Wochenschr.*, 1870, Heft 21.
10. **Becker, O.**—Zehender's *Klin. Monatsbl.*, 1871.
11. **Becker, O.**—*Archiv f. Ophthalm.*, Bd. XVIII, Heft 1, 1872.
12. **Becker, O.**—*Wiener med. Wochenschr.*, 1873, Heft 24.
13. **Mackenzie, Stephen.**—*Medical Times and Gazette*, Vol. I, 1875.
14. **Jacobi, J.**—*Centralbl. f. d. Med. Wissenschaften*, 1875, Heft 2.
15. **Jacobi, J.**—*Archiv f. Ophthalm*, Bd. XXII, Heft 1, 1876.
16. **Pflüger, E.**—*Archiv f. Ophthalm.*, Bd. XXIV, Heft 2, 1878.
17. **Becker, O.**—*Klin. Monatsbl. f. Augenheilk.*, 1880.
18. **Raehlmann, E.**—Virchow's *Archiv*, Bd. CII, 1885.
19. **Ulrich**—*Archiv f. Ophthalm.*, Bd. XXXIII, Heft 2, 1887.
20. **Wordsworth.**—*Royal London Ophthalmic Hospital Reports*, Vol. IV, 1863-65.
21. **Schmall, B.**—*Archiv f. Ophthalm.*, Bd. XXXIV, Heft 1, 1888.
22. **Friedrichson, A.**—*Archiv f. Ophthalm.*, Bd. XXXIV, Heft 3, 1888.
23. **Thoma, R.**—*Archiv f. Ophthalm.*, Bd. XXXV, Heft 2, 1889.
24. **Raehlmann, E.**—Zehender's *Klin. Monatsbl.*, Bd. XXVIII, 1890.
25. **Quincke, H.**—*Berl. klin. Wochenschr.*, 1890, Heft 12.
26. **Haab, O.**—*Atlas and Epitome of Ophthalmoscopy.*
27. **Smith, Priestley**—Norris and Oliver's "System of Diseases of the Eye." Vol. III.
28. **Schulten, M. W. von.**—*Archiv f. Ophthalm.*, Bd. XXX, Hefte 3 & 4, 1884.
29. **Roy and Brown**—*Jour. of Physiol.*, Vol. II, 1879-80.
30. **Türck, S.**, *Archiv f. Ophthalm.*, Bd. XLVIII, Heft 3, 1899.
31. **Howell, W. H.**—"Text-book of Physiology," 1911.
32. **Janeway, T. C.**—"The Clinical Study of Blood Pressure," New York, 1904.
33. **Czermak, W.**—*Centralbl. f. prakt. Augenheilk*, 1883.
34. **Henderson and Starling.**—*Jour. of Physiology*, Vol. XXXI, No. 5, 1904.

TWO UNUSUAL ORBITAL CONDITIONS.*

BY

WM. CAMPBELL POSEY, M.D.

PHILADELPHIA, PA., U.S.A.

CASE I.—*Chronic inflammatory tumour, with cyst and giant-cell formation, in the floor of the orbit and connected with the lacrymal sac, arising after false passages made with lacrymal probes.*

In February of this year the writer was consulted by Mrs. Z. on account of a peculiar swelling below the eyeball, which she claimed had arisen in consequence of the forceful passage of probes into the lacrymal duct, this operation having been performed about a year previously to relieve a persistent watering of the affected eye. Following the passage of the probes there had been marked swelling of the lids, and the lids and skin adjacent to them had been discoloured for weeks by the blood which had invaded the tissues under the skin. As soon as the pain consequent upon the operation had subsided, the patient noticed that much of the swelling could be made to disappear by firm pressure, and she averred that this phenomenon was attended by a peculiar crackling sensation. Although the discolouration disappeared after a time, the swelling and the crackling sensation elicited by pressure remained, and she soon noted that the former began to assume a definite shape, taking the form of a more or less rounded kernel at the inner angle of the eye. She noted, too, that the swelling was not always of uniform size, being larger in the morning and growing smaller during the day, and being also apparently enlarged by exertion. Blowing the nose did not seem to increase its volume. The mass was always larger when she lay down and at the menstrual epoch. In spite of various local applications prescribed by several oculists, the mass slowly increased in size, occasioning considerable disfigurement. It was in this stress that the patient consulted the writer, expressing her readiness to undergo whatever radical treatment was necessary for the relief of the condition.

Examination revealed a swelling the size and form of a small butternut in the lower and inner part of the orbit, which gave the impression of a bunch of small angle worms to the examining finger. Firm pressure elicited crepitation and caused the swelling to disappear. The mass appeared to have no connection with the adjacent bone below or with the lacrymo-ethmoidal cells internally, which presented nothing unusual in their external appearance. The eyeball was normal, nor was there evidence of any involvement of its external muscles. Although the mass was thought to be vascular, having arisen in consequence of the injury done to the tissues by the probing, the patient was subjected to a careful study of the orbit and of the adjacent sinuses by the X-ray, and by a rhinologic examination, the former by Dr. H. K. Pancoast, of the University Hospital, and the latter by Dr. George B. Wood, a colleague of the Howard Hospital staff. The reports received from both of these gentlemen were, however, negative.

Rejecting any attempt at extirpation of the growth by electrolysis or other subcutaneous method, the writer determined to expose the mass by free incision into the orbit, and the patient was accordingly admitted into the Howard Hospital, where she was placed under ether narcosis. With the aid and counsel of Dr. G. B. Wood, a free curvilinear incision was made over the inner and lower margins of the orbit, and the dissection rapidly carried

* A Communication read before the American Ophthalmological Society on May 7th, 1913.

through the skin and subcutaneous tissues to the mass. This was found to be almost the size of a large butternut, to be free from connection with the bone, but to be closely blended with the tissues in the region of the sac and those directly below the conjunctival fornix. The surface of the mass was studded with numerous small cyst-like elevations, which crackled under the finger. No distinct capsule could be defined. The dissection and removal of the mass from the surrounding tissue were accomplished without great difficulty and with but little hæmorrhage. A careful exploration of the region of the sac revealed no trace of this structure, nor could any defect be found in the exposed walls of the orbit. The lips of the wound were coaptated by silk sutures and a pressure bandage was applied. Healing was prompt, the

Fig. 1. Low power drawing showing large and small cysts surrounded by loose connective tissue. Some of the smaller cysts are partially obliterated by granulation tissue, while the larger cysts are free from contents and have thin walls.

scarring slight, and there has been no return of the mass. About as much lacrymation is complained of as is present after the successful removal of a sac, but pressure elicits no crepitation and there is no swelling.

The pathologic report by Dr. George B. Wood is as follows: "The tumour mass, measuring 3 cm. by 1 cm. by 1 cm., was soft, with numerous small empty cysts scattered irregularly through its substance. None of these was larger than a split pea. The smaller cysts were semi-translucent and distinctly palpable; the larger ones were soft. There was no capsule or definite limit to the mass. The histologic examination shows a fibrotic stroma with occasional small collections of lymphocytes, and scattered through it numerous small cysts varying in size and without contents (Fig. 1). The walls of these cysts were

made up of concentrically arranged fibrous tissue and lined with a thick layer of epithelioid cells, although in the larger cysts this layer was thinner and less well marked. Some of the smaller cysts were apparently occluded by these epithelioid cells and showed very little fibrosis. Numerous foreign body giant-cells were present, more commonly in the smaller cysts, though occasionally very large giant-cells, flattened out apparently by some form of pressure in the cyst cavity, could be observed in the walls of the large cysts (Figs. 2 and 3). At places the layer of epithelioid cells seemed distinct from the fibrotic tissue, and at other places the epithelioid cells merged into the surrounding fibroblasts. The walls of the blood-vessels were not altered, and there was no proliferation of their endothelium. The tissue was very vascular, but not of angiomatous character. There was considerable muscle tissue in the mass, probably a portion of the orbicularis palpebrarum. No evidence of glandular tissue could be seen, nor could any accumulation of cells suggesting a neoplasm be found.

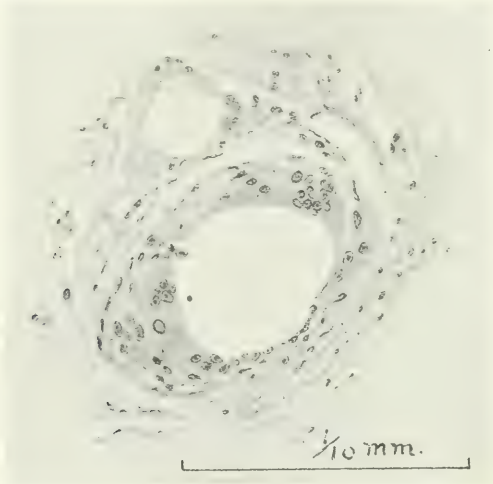

Fig. 2. High power drawing of a small cyst showing compressed giant cells lining the walls.

"It seems probable that this specimen is not a true tumour, but the reaction of tissue to some form of foreign body irritation. From the history of the case, the deduction is reasonable that at the time of the operation upon the naso-lacrymal duct the walls of the lacrymal sac or part of the duct were torn and in some way air was forced into the tissues of the lower lid. Subsequent inflations of this tissue due to blowing the nose, etc., kept this opening patulous, and either the pressure of the air in the tissues or the forcing in of lacrymal secretion and minute foreign bodies, produced a reaction in the tissues with the formation of giant-cells. In the smaller cysts the process is apparently one of obliteration, but it is probable that as long as a communication with the nasal duct was kept up, pressure in the larger cysts would prevent their closure. The larger cysts apparently communicate with each other, though intercommunication of the smaller ones is not shown. As far as I can ascertain, the specimen is unique, though a somewhat similar condition was reported by Dr. Blatters several years ago to the New York Pathological Society. In that case there were distinct cyst-like spaces with giant-cell formation in the wall of the intestine."

Dr. Wood says that, as far as he is aware, the specimen is unique, and the writer, speaking from his own experience and after a fairly comprehensive review of the ophthalmic literature bearing upon orbital and lacrymal conditions, can substantiate this opinion. The entrance of air into the tissues of the orbit following fracture of one of its walls is a common condition, but the emphysematous condition soon disappears and no complications follow. Serous cysts may at times follow hæmorrhages into the orbit resulting from degeneration of a blood clot, and in very exceptional cases emphysema of the orbit has arisen in consequence of gangrenous decomposition of fluid which has escaped into the tissues after a penetrating wound. In the case under con-

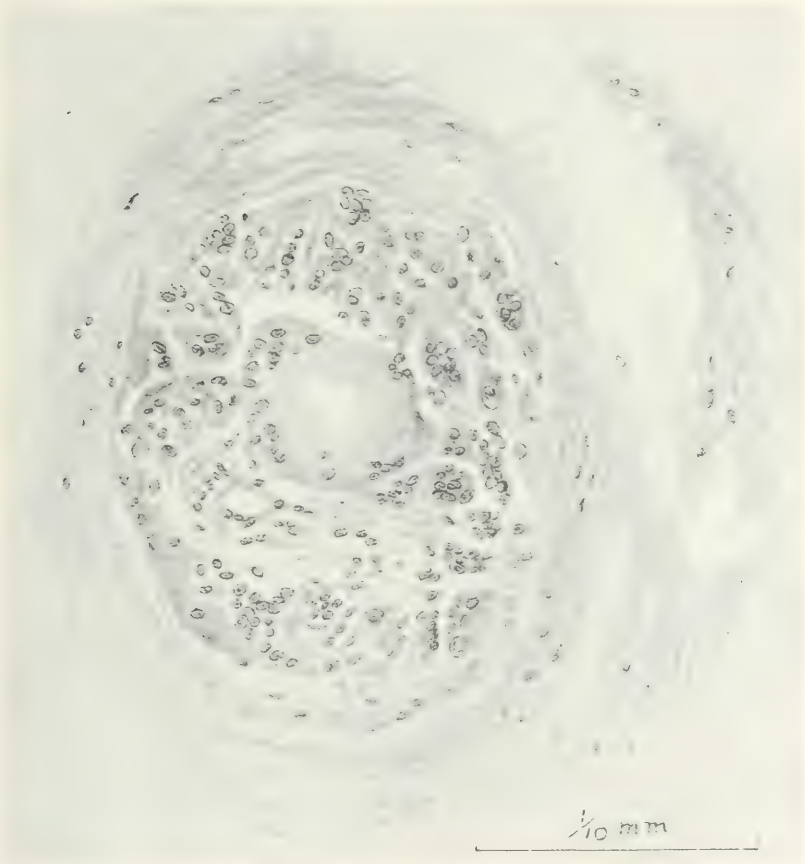

Fig. 3. High power drawing of a small cyst obliterated by granulation tissue with numerous giant cells, some of them very large, also showing the concentric arrangement of the fibrous tissue composing the wall of the cyst.

sideration, however, the pathologic findings were not that of a broken-down clot, and there is no history of a phlegmonous inflammation. The air doubtless entered the tissues in the region of the sac, through a small fissure or fissures in the inner orbital wall, in consequence of the false passages made by the probes, and the neoplastic mass or air tumour, as it might be designated, arose, in all probability, as Dr. Wood has surmised, by the reaction in the tissues neighbouring upon the sac to some form of foreign body irritation.

CASE 2.—*Large lacrymal mucocele occasioned by pressure exerted externally by the distended walls of the anterior ethmoidal cells, in consequence of the retention of mucus within that cavity.*

In January, 1912, the writer was consulted by a young man with a large mucocele of the left lacrymal sac. There was but little of moment in the history, lacrymation having been complained of for some years past; at no time had there been any inflammatory reaction in the affected eye. The patient was coloured, and had the low broad nose and scaphoid face not unusual in his race. He had never suffered from nasal catarrh, and his health otherwise had been good.

Extirpation of the sac was easily and completely effected by Meller's method, and, save the slight lacrymation which is the rule after extirpation of the sac, the patient had nothing to complain of. About a year later, however, following an attack of influenza, the writer was again consulted on account of a swelling which had recently appeared in much the same position as that previously occupied by the sac. This was somewhat sensitive to pressure, and would doubtless have been slightly reddened had the patient's colour permitted this sign of inflammation to be manifested. Examination showed this swelling to be due in all probability to a distention of the anterior ethmoidal cells, for the walls of the sinus had been apparently pushed forward, and palpation gave the impression of fluid beneath the tense periosteum, the bony framework of the sinus having evidently been eroded by long-continued pressure from dammed up-secretion within.

The patient was accordingly etherised, and, with the assistance of Dr. Wood, the writer made a careful curvilinear incision over the tumour, the line of the incision following the outlines of the lower inner margin of the orbit. A deeper incision opened the mucous sac, which immediately came into view, and a large mass of mucoid material, partially tinged with blood, oozed out of the wound. The diagnosis of mucocele of the ethmoidal cells being confirmed, a free opening was established by the use of bone gouges and chisels into the roof of the nose, and drainage obtained by the passage of a good-sized drainage tube from the sinus into the nose. No dead bone was encountered, and there was no evidence of involvement of any of the cells of neighbouring sinuses. The incision into the orbital tissues was then carefully closed, and a firm pressure bandage applied. Healing was rapid and uneventful. The sinus was syringed daily through the nasal end of the tube for some weeks. At the end of a month, the tube was removed, though the patient reported to Dr. Wood at frequent intervals for some time longer, to insure the patency of the orifice from the sinus into the nose. Five months have now elapsed since the operation and there is apparently no obstruction to the flow of the mucus into the nose; the scar of the incision is barely perceptible.

The writer is of the opinion that the sequence of the double mucoceles in this case may be explained as follows.—The patient, already predisposed by the anatomic formation of his skull to retention of the mucous secretion from the ethmoid cells presumably by too small avenues of exit, had doubtless had these completely closed from some catarrhal condition of his nose. In consequence of this obstruction to the orifice, the mucus within the cells had slowly distended its lateral wall, thereby exciting gradual and continued pressure upon the lacrymal sac, displacing this structure from its position in the lacrymal groove and hindering the escape of its contents into the nose by a compression of the lacrymonasal duct and perhaps closing the canaliculi by a similar process. The lacrymal mucocele was extremely large, and none of its contents could be expressed either through the canaliculi or into the nose.

The writer has already called attention to this secondary closure of the sac

from pressure exerted externally by the walls of the ethmoidal cells,* and referred to Peters' paper,† in which that author stated that, in his opinion, many cases of ectasia of the lacrymal sac were to be regarded as nothing more than a manifestation of disease of the accessory sinuses of the nose.

CLINICAL MEMORANDA.

NOTES ON THE VACCINE TREATMENT OF INFECTIONS WHICH INVOLVE THE CORNEA.

BY

THOS. A. PEEL, M.B., B.S.Durh.

LATE OPHTHALMIC HOUSE-SURGEON
TO THE NEWPORT AND MONMOUTHSHIRE HOSPITAL.

Introduction.

IN view of the attention recently directed to the use of vaccines in ophthalmic practice, the following notes of cases treated in the out-patient department of the Newport and Monmouthshire Hospital may be of interest. The vaccines were administered by hypodermic injection into the fore-arm, so that the local reaction might be accurately observed.

No record of the reactionary temperatures was taken, but in none of the cases did the patients complain of any discomfort, beyond the local reaction. In some instances there was pain and swelling around the site of the injection, but the axillary glands were not enlarged. (In the cases treated by tuberculin the doses refer to fractions of a milligram.)

Cases.

CASE 1.—*Phlyctenular Keratitis. Local treatment three weeks, no improvement; tuberculin three weeks, cure*

A.P., male, æt. 10 years. History of inflammation in right and left eyes for several months. First seen February 28th, 1913, lacrymation and blepharospasm. R. E. corneal opacities and general superficial infiltration. L. E. active phlyctenular ulcers, ciliary injection, pupils dilate well under atropin. Local treatment. March 17th, R.E. now shows spreading phlyctenules, L.E. slight improvement, T.B.E., 1/4,000. March 20th, good local reaction; injection less, ulcers beginning to heal. March 29th, T.B.E., 1/2,000. April 1st, ulcers healing. April 8th, R.E. ulcers healed, slight injection still present. L. E. clear, free from irritation.

CASE 2.—*Phlyctenular Keratitis. Local treatment seven weeks, no improvement; tuberculin six weeks, cure.*

M. T., female, æt. 10 years. History: eye inflamed one month. First seen January 24th, 1913. R. E. clear. L. E., lacrymation and blepharospasm, spreading phlyctenular ulcer, deep ciliary and conjunctival injection. Pupil dilates well under atropine. Local treatment. February 6th, ulcer healing slowly. February 7th, ulcer has again become active, with increased injection and irritability. February 12th, ulcer still active. T.B.E., 1/2,000. February 14th, good local reaction, ulcer healing, injection less. March 10th, ulcer healing, no injection. T.B.E. 1/1,000. March 29th, ulcer healed, eye clear.

CASE 3.—*Phlyctenular Keratitis. Tuberculin treatment with relapse and ultimate cure, seven weeks*

P. W., female, æt. 11 years. History: eye inflamed two weeks. First seen February 7th, 1913. R. E. clear. L. E. blepharospasm, active phlyctenule with general corneal efflorescence, ciliary and conjunctival injection, pupil dilates well under atropin. February 12th, T.B.E. 1/2,000, February 14th, marked local reaction, ulcer healing. February 24th, ulcer healed, eye clear. March 27th, ulcer has again broken down. T.B.E. 1/2,000. April 4th, ulcer healed, eye clear.

CASE 4.—*Keratitis. Local treatment two years, slight improvement; tuberculin ten days, cure.*

*Trans., Sect. on Ophth., A.M.A., 1905.
†*Zeitsch. f. Augenh.*, 1899, S. 154.

O. N., female, æt. 18 years. History: eyes inflamed one month. First seen May, 1911. Blepharospasm, photophobia, right and left corneæ show deep infiltration with general ground-glass appearance, ciliary injection, pupils dilate well under atropin, local treatment, with slow improvement, and slight exacerbation. March 29th, 1913, photophobia, cornea hazy, ciliary injection. T.B.E., 1/2,000. March 31st, marked local reaction, injection less. April 8th, cornea almost clear, no injection, no irritability.

CASE 5.—*Keratitis. Local treatment three years, no improvement; tuberculin six weeks, improvement.*

A. E., male, æt. 9 years. History: six months ago eyes became acutely inflamed, during recovery from measles; patient was able to attend school until 3 weeks ago, when photophobia became acute. First seen April 13th, 1910, R. and L. photophobia, corneæ show deep central haze, marked ciliary injection, pupils dilate well, enlarged submaxillary glands, local and general treatment with varied improvement and acute exacerbations. February 10th, 1913, both corneæ show dense, ground-glass appearance, persistent ciliary injection, pupils do not dilate under atropin, T.B.E. 1/2,000. February 13th, good local reaction, injection less. March 1st, T.B.E. 1/2,000. March 4th, cornea clearing. March 28th, T.B.E, 1/1,000. March 30th, cornea much clearer, no injection. April 6th, cornea clearing, no irritability, general condition greatly improved.

CASE 6.—*Keratitis. General treatment, three months, slight improvement; tuberculin one week, marked improvement.*

S. S., male, æt. 6 years. History: eyes have been affected since three months old, and have become worse during the last two years. First seen December 13th, 1912, photophobia and lacrymation. R. E. diffuse infiltration of cornea, with some nebulæ. L. E. diffuse infiltration with leucomata. Both eyes deep ciliary injection. Pupils dilate well. Local treatment. March 5th, 1913, corneæ clearer, injection less but still marked. T.B.E. 1/2,000. March 7th, very marked local reaction. Injection less. March 11th, corneæ clearer, slight injection; there is a small cyst-like swelling at site of the injection; massage to arm. April 6th, corneal infiltration less, no ciliary injection or photophobia. Swelling at site of injection, clearing.

CASE 7.—*Keratitis and Iritis. General treatment six weeks, slight improvement; tuberculin four weeks, cure.*

E. L., female, æt. 5 years. First seen January 31st, 1913, photophobia and lacrymation. R. E. hazy cornea with central infiltration, pupil dilates slightly. L. E. hazy cornea with central infiltration, no dilatation under atropin, R. and L. deep ciliary and conjunctival injection, local treatment. March 5th, slight improvement, T.B.E. 1/4,000. March 7th, marked local reaction, no injection. April 2nd, corneæ much clearer, no injection or irritability, T.B.E. 1/2,000, April 5th, cornea clear.

All these cases were treated with freshly made dilutions of pure bacillary emulsion (T.B.E.). The negative phase following the injections must have been very short, as all the cases showed definite improvement on the second or third day.

CASE 8.—*Gonococcal ophthalmia. General treatment six weeks, slight improvement; vaccines two weeks, cure.*

F.H., male, æt. 24 years. Patient has had urethritis, two weeks; a week ago eyes became inflamed. First seen January 6th, 1913.—R. E. clear. L. E. profuse purulent discharge, intense conjunctival injection and chemosis, cornea dim, and margins infiltrated, no fundus reflex. The examination of the discharge shows numerous gonococci, treated local irrigations, antiseptics, and astringents. February 10th.—R. E. clear. L. E. decreased discharge and chemosis, otherwise no improvement; gonococcus vaccine 20,000,000. February 13th, slight local reaction, discharge almost ceased. February 14th, gonococcus vaccine 40,000,000. February 17th, discharge ceased, slight injection, cornea clear. February 18th, gonococcus vaccine 50,000,000. February 24th, eye perfectly clear, urethral discharge has ceased.

In this case the local treatment was carried on in conjunction with administration of the vaccine. The pain and burning in the eye were relieved on the second day, following the first injection.

CASE 9.—*Chronic pneumococcal coniunctivitis. Local treatment three weeks, no improvement; tuberculin, five weeks, no improvement; vaccines, two weeks, cure.*

T. P., male, æt. 12 years. History of inflamed eye, one week; no known means of infection. First seen January 20th, 1913,—L. E. unaffected. R. E., lacrymation and photophobia, deep conjunctival injection, and slight ciliary injection and chemosis, slight watery discharge, uniform superficial infiltration of cornea. Pupil dilates well under atropin. Lacrymal sac clear, carious teeth, and enlarged submaxillary glands. Local treatment. February 10th, no improvement. Swab from eye shows pneumococci; these were regarded as accidental, since the condition seemed too chronic to be of pneumococcal origin, and resembled some which had improved under tuberculin. February 12th, T. B. E. 1/2,000. February 14th, no reaction, no improvement. March 9th, T.B.E. 1/1,000. March 11th, slight reaction, no improvement. March 19th, no improvement, pneumococcal vaccine, 5,000,000. March 21st, fair local reaction, injection less, symptoms relieved. March 22nd, pneumococcal vaccine 10,000,000. March 25th, great improvement, pneumococcal vaccine 10,000,000. March 31st, pneumococcal vaccine 20,000,000. April 4th, pneumococcal vaccine 50,000,000. April 8th, cornea clear, no injection, no irritability. During the administration of the vaccines, the pupil was kept under atropin.

This case is of special interest, as it suggests the occurrence of chronic conjunctivitis of purely pneumococcal origin: the supposed rarity or non-occurrence of this condition led to five weeks being wasted in trying the effect of tuberculin, after pneumococci had been found in the discharge.

Remarks.

All these cases seem to suggest the suitability of vaccine therapy in small localised infections, such as infections of the eye, and also the practicability of applying the treatment in out-patient practice.

I beg to acknowledge my indebtedness to Mr. R. J. Coulter, F.R.C.S.I., Hon. Ophthalmic Surgeon to the Newport and Monmouthshire Hospital, under whose supervision the treatment was carried out, and through whose kindness I am enabled to publish these notes.

CONGENITAL COLOBOMA OF BOTH UPPER LIDS.

BY

GEORGE A. PAUL, M.B., Ch.M. (Syd.),

HONORARY ASSISTANT OPHTHALMIC SURGEON TO SYDNEY HOSPITAL, N.S.W.

E. E. B., *æt.* 3 years, male. As seen by the accompanying photograph, the inner third, or slightly more, of each upper lid is wanting. The defect is roughly

rhomboidal in shape, and at the upper-inner angle there is an attachment between the conjunctiva of the small inner portion of each upper lid and the conjunctiva bulbæ, this attachment being of the nature of a symblepharon, and more marked in the case of the left lid.

The small inner remnant bears a few lashes, and there is no trace of the upper puncta. In all other respects the eyes are normal, the corneæ are unharmed, (the white spot seen in the photograph on the left cornea is a light reflex), and vision appears to be perfect.

The child is one of a family of nine, of whom only four are living, the remaining five having died at ages under six months; according to the mother, three died of marasmus, one of tetanus, and in one case the cause of death is indefinite. There is a history of one miscarriage. There is no consanguinity between the parents.

As regards the treatment, I propose at a later date to perform an extensive canthotomy and pushing the outer portion of the lids along to meet the inner piece, and to stitch after freshening the edges. Joining the upper and lower lids at the same time would probably prevent the stitches from cutting out.

CURRENT LITERATURE

NOTE.—Communications of which the titles only are given either contain nothing new or else do not lend themselves to abstract.

I.—COMPARATIVE ANATOMY AND PHYSIOLOGY OF THE EYE.

(1) Weve, H.—The light sense of Periophthalmus kolreutheri. A contribution to our knowledge of the light sense of fishes. (Der Lichtsinn von Periophthalmus kolreutheri. Ein Beitrag zur Kenntnis des Lichtsinnes der Fische.) *Arch. f. vergleich. Ophth.*, Bd. III, Juni, 1913, S. 265.

(2) Drualt, A.—On the growth of the lens capsule. (Sur l'accroissement de la capsule du cristallin.) *Bull. de la Société d'Ophtalmologie de Paris*, mars, 1913, and *Arch. f. vergleichende Ophth.*, Bd. III, S. 279, Juni, 1913.

(3) Stilling, J.—On the development of the central canal of the vitreous. (Ueber die Entwicklung des Glaskörperkanals.) *Arch. f. vergleichende Ophth.*, Bd. III, S. 290, Juni, 1913.

(4) Fritzberg, W.—Contributions to our knowledge of the apparatus of accommodation in reptiles. (Beiträge zur Kenntnis des Akkommodationsapparates bei Reptilien.) *Arch. f. vergleichende Ophth.*, Bd. III, S. 292, Juni, 1913.

(5) Hanke, V.—The rudimentary visual organs of some amphibians and reptiles. (Die rudimentären Sehorgane einiger Amphibien und Reptilien.) *Arch. f. vergleichende Ophth.*, Bd. III, S. 323, Juni, 1913.

(6) Uhlenhuth, E.—The influence of the host on the transplanted amphibian eye. (Der Einfluss des Wirtes auf das transplantierte Amphibienauge.) *Arch. f. vergleichende Ophth.*, Bd. III, S. 343, Juni, 1913.

(7) Fujita, H.—The process of regeneration in the retina of the triton and frog. (Regenerations Process der Netzhaut des Tritons und des Frosches.) *Arch. f. vergleichende Ophth.*, Bd. III, S. 356, Juni, 1913.

(8) **Ischreyt, G.—The comparative morphology of the eye in the duck family. Second contribution. (Zur vergleichende Morphologie des Entenaudes. Zweiter Beitrag.)** *Arch. f. vergleichende Ophth.*, Bd. III, S. 369, Juni, 1913.

(9) **Ischreyt, G.—The morphology of the eye in the Urinatoridae (Divers). [Zur Morphologie des Auges der Urinatores (Taucher).]** *Ibidem*, p. 380.

(1) By a series of ingenious experiments Hess showed that fishes apparently see the spectrum in much the same manner as a totally colour-blind man. The yellow-green and green zones are the brightest, the blue less so, and the red very much less than the blue. *Periophthalmus kolreutheri*, however, is a fish which seeks its food on land, springing after small insects with extraordinary activity. It has been shown that it is not myopic like other fishes, but emmetropic or slightly hypermetropic, and that it has an active accommodation. It is therefore a matter of much interest to investigate whether its luminous perceptions are the same as in other fishes.

The method adopted by **Weve**, of Amsterdam, was to cover one side of an aquarium with tissue paper and illuminate a certain area of it by means of a lamp contained in a long blackened tube, the end of which could be furnished with glasses of various colours. A glass plate was placed against this side of the aquarium, so that flies which had been stuck to it came within the illuminated area. By gradually bringing the lamp nearer, the observer could note when the area itself, and when the adherent flies, became visible to him. The conditions for the observer and the fish were not indeed precisely similar, since the observer was further off; moreover, in arriving at the exact strength of the stimulus which was sufficient to enable the *periophthalmus* to see the fly, it was necessary to make a correction for the fish's larger pupil, which admitted more light. When these corrections had been made as nearly as might be, it was found that the fish seemed to see as well as man in red light—a great contrast to what obtains in other members of the species. As proving that the animal used sight alone in finding its prey, Weve found that in the dark it made no attempt to seek it; smell was excluded by the observation that it took pieces of black paper as well as flies, until it penetrated the cheat, when it became sulky, and would take neither flies nor paper.

To light of short wave lengths the animal was extremely sensitive. After making the corrections mentioned above, Weve calculates that it could see with an illumination of 1/23 to 1/35 of that which the dark-adapted human eye required. When a spectrum was thrown on the aquarium wall, the flies were taken first from the green, then from the blue, then from the red. That the fish's eye is capable of considerable adaptation is shown by the much better results which were obtained when it had been kept in the dark.

GEORGE COATS.

(2) In the adult human eye the lens capsule, as is well known, is thicker anteriorly than posteriorly. But embryologically the capsule is first laid down, and for some time is thicker, at the posterior pole. **Drualt,** of Tours, traces the steps by which this reversal is brought about. He finds that after the fourth month the central portion of the posterior capsule ceases to thicken, and undergoes no further increase throughout life. The post-equatorial segment of the posterior capsule, however, continues to thicken, and up till birth is the thickest region of the capsule. Thereafter the anterior capsule gradually overtakes it, and continues to thicken throughout life. In the fœtal lens, while the cells are in process of transformation into fibres, they are active in laying down capsule, but when they are so transformed their activity

ceases. This accounts for the deposit of capsule, first at the posterior pole and subsequently more towards the periphery. The continued growth of the anterior capsule is evidently associated with the constant presence of a layer of epithelial cells in this situation. GEORGE COATS.

(3) The view that the vitreous is in the main a derivative of the retina, and is, in fact, a very much swollen basal membrane of the inner layer of the secondary optic vesicle, carries with it as a probable corollary the further hypothesis (insisted upon by Franz) that the canal of Stilling represents the remains of the cavity of the secondary optic vesicle. Against this **Stilling** (Strassburg) objects that the canal in many animals is very small in the young, but increases considerably in later life, a phenomenon which seems unlikely in the case of the remnant of a fœtal structure. As a congenital abnormality he has also found the canal replaced by a large cleft in the vitreous, and also by a large space with two small canals leading into it posteriorly, and one anteriorly. If the canal of Stilling be a remnant of the cavity of the secondary optic vesicle, the first of these abnormalities would seem to require a gap also in the walls of the vesicle. On these grounds Stilling believes the canal to be a structure which develops with the development of the eye, and which is first formed when the hyaloid artery is laid down. GEORGE COATS.

(4) Some recent observations by Hess have shown that the mechanism of accommodation in reptiles and birds differs completely from that of man. The pressure of the ciliary processes and iris on the extremely plastic lens of these animals causes a conical projection to bulge through the pupil, which adds, of course, to the refractive power of the dioptric media. During accommodation, therefore, the sauropsidan lens is under increased, the mammalian (if the v. Helmholtz theory be accepted) under diminished, pressure.

It is evident that animals which have to see under water as well as in the air must be provided with a very powerful accommodation ; for, as soon as they dive under the surface, the whole refractive power of the cornea is abolished, and the eye must become very hypermetropic. **Fritzberg** (Berlin) maintains that if the above explanation of Hess be correct, the musculature of the ciliary body and iris must be developed, in the case of birds and reptiles, in proportion to the accommodative requirements, whereas this is not necessarily the case in mammals ; because if complete relaxation of pressure on the lens capsule is obtainable by a certain muscular effort, no object can be served by any further muscular development. In the case of birds and reptiles, the range of accommodation could be increased to almost any extent by increased muscular power ; in man, on the other hand, an increase of muscular power would be useless without a change in the constitution of the lens, and, indeed, in the case of presbyopia the muscular power which he possesses becomes useless owing to loss of plasticity in the lens. If this reasoning be correct, the intra-ocular musculature of the powerfully accommodating amphibious reptiles and birds ought to be greatly in excess of that of the purely terrestrial members of these classes. Hess has already shown that this holds good in the case of the cormorant, which sees its prey from above and chases it under water. Fritzberg takes up the same question in the case of the land and water tortoises. In all the water animals he finds the muscles of the iris and ciliary body much more highly developed than in their terrestrial relations. The great development of the iris muscle is very characteristic of the water animals. It is obviously far in excess of what is required for the movements of the pupil ; indeed, it can be shown experimentally that the pupil in these animals does not respond to light, but

only to accommodation. Therefore the muscle fibres of the iris must form a part of the accommodative mechanism, and, in fact, they are well placed to exercise pressure on the lens in the manner described above.

Fritzberg describes also some details of the reptilian iris and ciliary body. He finds that in amphibious animals there is a much more richly developed plexus of vessels in the iris. This he believes to represent a mechanism for the regulation of the intra-ocular pressure. It is evident that if a portion of the lens is projected through the pupil, room must be made for the displaced aqueous. Fritzberg explains that the vascular plexuses are supplied from the ciliary body behind. When therefore the ciliary muscle goes into powerful contraction, the supplying vessels are more or less constricted, while at the same time the venous outflow by the vessels at the sclero-corneal junction is unobstructed. Hence the plexuses empty, room is made for the displaced aqueous, and the outflow of fluid is promoted.

A section is devoted to the "Transverse muscle" described recently by Hess in the tortoise. According to that author, it is a muscle which arises below from a large ciliary process and runs temporalwards to be inserted into the choroid. Fritzberg confirns the description, except that he finds the course of the muscle to be always nasalwards. Observations are given of its presence and degree of development in other reptiles. GEORGE COATS.

(5) **Hanke**, of Vienna, has had the opportunity of examining the rudimentary eyes of some rare amphibians and reptiles, both in their larval and fully developed states. For exact details the reader must be referred to the paper itself, but a few of the leading facts may be mentioned. *Blanus cinerea* is a reptile belonging to the amphisbæna family. The eyes consist of the secondary optic vesicle, invaginated by the lens vesicle and surrounded by mesoblast. It seems as if the fœtal cleft had closed without including any mesoblast, as the vitreous and iris are absent. The lens is very large, and touches the cornea in front and the retina behind.

Ichthyopsis glutinosus is an amphibian belonging to the family of the Cæcilidia. The eye presents a curious combination of rudimentary with fairly advanced differentiation. The choroid and retina are quite highly developed. The lens is present. Hyaloid remains are found in the vitreous. The pigment epithelium ends anteriorly in a knob-like swelling. The anterior parts of the eye, however, are exceedingly rudimentary. The globe is buried in the skin, and no proper cornea has been differentiated. The iris is totally absent.

Hypogeophis is a related animal from the Seychelles. A thick connective tissue capsule encloses the secondary optic vesicle and lens. The anterior end of the vesicle turns back in the form of a hook. No iris is present, and the cornea is undifferentiated.

The fairly high development of the retina in these two animals shows that they must have at least perception of light. In view of the absence of a transparent cornea, it is scarcely possible that they have much more. There is no apparatus of accommodation, and the globe is incapable of movement. Hanke attributes these defects to retrogression, rather than to arrested development. GEORGE COATS.

(6) The observations of **Uhlenhuth**, of Vienna, are curious and interesting. In the amphibia it is comparatively easy to transplant an eye with its surrounding tissues into another animal. At first the retina degenerates, but it very soon undergoes regeneration, and if the nerve has been placed in the vicinity of a spinal ganglion, a connection may even be formed with it. Uhlenhuth has animals which have carried a transplanted eye, not differing in appearance from the normal organ, for as long as two-and-a-half years.

The author's experiments were made on *Salamandra maculosa.* During its larval stage the animal has a yellow iris, which, however, becomes black, when the salamander undergoes transformation to its adult form. This pigmentation, therefore, may be taken as an indicator of the occurrence of metamorphosis in the eye and permits a judgment to be formed as to whether metamorphosis has taken place when the eye is transplanted on to another animal. The method of experimentation was as follows.—The eye of a young larva was implanted on an old larva, the younger animal being still kept alive. It was found in every case that the transplanted eye underwent metamorphosis at the same time as its host, and very much sooner (seven months in one case) than its fellow eye in the head of the younger larva. The opposite experiment also succeeded—if the eye of an old larva were transplanted into a young one, its metamorphosis was delayed, and occurred synchronously with that of the young larva. Hastening or delaying the metamorphosis of the animal itself by alterations of diet, had no influence on these phenomena – the metamorphosis of the eye was always strictly synchronous with that of the host. The only exception occurred in very old larvæ, in which metamorphosis, or the physiological changes associated with its inception, had already begun, though the form of the animal might not yet show any change. In this case the eye transplanted on to the younger larva underwent metamorphosis at once, not synchronously with that of its host.

These experiments show how preponderant is the influence of the host. They prove also that the factor which sets pigmentation going does not reside in the eye itself, and that once the process is started it goes on independently of the host. They show also that the physiological change which induces metamorphosis may be already present before the actual transformation has begun.

Whence is the pigment derived? Is it simply an increase in the pigment already present in the eye, or is it newly elaborated from the circulating blood? In order to answer this question Uhlenhuth had recourse to the following experiment.—The triton, like the salamander, has a yellow iris in the larval stage, but retains it throughout life. A larval triton's eye was therefore implanted on a salamander larva, and a salamander's on a triton. It was found that the metamorphosis pursued its usual course in both instances, the triton's eye remaining unpigmented, and the salamander's becoming black. The increase of pigment therefore is derived from the eye itself. Some analogous observations from other transplantation experiments are quoted. GEORGE COATS.

(7) The power which many cold-blooded animals have of regenerating lost tissues is well known, the reproduction of a new lens from the epithelium of the optic vesicle in the case of the triton being a conspicuous example. **Fujita** has studied the regenerative processes which occur in the retina after dividing the nerve or evacuating the contents of the globe. When the nerve is cut, the nerve fibre and ganglion cell layers begin to degenerate within 24 hours, the middle layers suffer next, and the outermost layers remain longest intact, and sometimes undergo little or no change. The process reaches its height in about six or seven days, and is then followed by regeneration. This takes place chiefly from the pars ciliaris retinæ, the nuclei of which become enlarged and show active karyokinesis. The new cells travel backwards, taking the place of the degenerated retinal elements, and so form a new, but undifferentiated, retina. Two layers of cells now become distinguishable, from the inner of which the ganglion cell layer takes origin, while the outer again divides to form the inner and outer nuclear layers. From the latter the rods and cones sprout, and the differentiation of

the retina is completed by the formation of a nerve fibre layer. If the degeneration of the outer layers has not been complete, they also share in the regeneration. The process is much quicker in summer. It is less complete in the frog than in the triton, differentiation usually remaining imperfect.

GEORGE COATS.

(8) **Ischreyt's** work on the comparative morphology of the duck's eye has already been reviewed in THE OPHTHALMOSCOPE (Vol. X, p. 597, 1912). In the present paper he gives details of the examination of four more species, three of them swimming ducks, one of them a diver. On the whole, with slight modifications, his new observations confirm his previous conclusions, of which a sufficiently full summary has already been given.

(9) The paper, by **Ischreyt**, of Libau, on the eye of the divers deals with similar problems. He has examined specimens from all three classes, the Podicipidæ or grebes, the Urinatoridæ or loons, and the Alcidæ or auk family, the first being represented by Colymbus cristatus, the second by Gavia lumme gunn, the red-throated diver, the third by Alca torda, the razorbill. In all three the eye is elongated antero-posteriorly, as in the diving ducks. The sclera is thin at the limbus, thicker in the region of the ciliary muscle, and again thinner towards the equator. Colymbus has a thin iris and comparatively poorly developed ciliary muscle; the other two have a highly developed intra-ocular musculature. The eye in Colymbus is most nearly related to that of the duck family, while Gavia and Alca differ in several particulars from the duck, but are related to one another. There seems to be no difference in the mode of life of the three species to account for this variation. For exact details of histological structure, the reader is referred to the original paper.

GEORGE COATS.

II.—IMMUNITY.

(1) **Kuffler, O.—On the question of vitreous immunity. (Zur Frage der Glaskörper-Immunität.)** *Bericht der Ophthalmologischen Gesellschaft*, Heidelberg, 1912.

(2) **Urao Arisawa.—On the specific properties of ocular tissue. (Ueber die spezifischen Eigenschaften der Augengewebe.)** *Bericht der Ophthalmolgischen Gesellschaft*, Heidelberg, 1912.

(1) **Kuffler,** of Giessen, points out that a large variety of organisms may cause suppuration of the vitreous, a circumstance that complicates the study of its immunity. Many of the experiments made in this direction were untrustworthy because a platinum needle was used to infect the vitreous, and so the number of organisms introduced was unknown. In other cases such an excessive quantity of septic material was injected that direct toxic action was set up. By a special method of dilution Kuffler has avoided these sources of fallacy. He found that bacillus acidi lactici (950 organisms), vibrio Metschnikoff (460 organisms), vibrio Dumbar (200 organisms), thyrotrix (900 organisms), and alkaligenes (600 organisms), injected into the vitreous all caused severe suppurative inflammation of the whole eye. Various yeasts caused only slight transient reactions. Experiments to determine the presence of immune bodies in the vitreous showed that these bodies did not pass from the general circulation of an actively immunised animal into the vitreous.

T. HARRISON BUTLER.

(2) **Urao Arisawa**, of Osak, Japan, working with v. Szily at Freiburg in Breisgau, deals with the specific nature of ocular tissue. They conclude that several antigen properties may be present in an organ. The carriers of these antigens are primarily present even in the embryo. For this reason it is only possible to excite a specific production of antibodies when embryonic tissues are employed. As the various organs take up their specific functions special antigen properties appear due to alterations in the cells. These new substances, which may be the same in the organs with identical functions in different animals, are able to produce antigen. They are the substances which in biological researches excite the production of the so-called organo-specific antibodies. T. HARRISON BUTLER.

III.—ANAPHYLAXIS IN EYE WORK.

(1) **Szily, Aurel v.—The significance of anaphylaxis in eye work. (Ueber die Bedeutung der Anaphylaxie in der Augenheilkunde.)** *Klin. Monatsbl. f. Augenheilk.*, Februar, 1913.

(2) **Grignolo, Federico.—Biochemical changes in the aqueous humour in acute intoxications due to methyl alcohol and the toxipeptides. (Biochemische Veränderungen im Kammerwasser bei akuten Intoxikationen durch Methylalkohol und durch Toxipeptide.)** *Klin. Monatsbl. f. Augenheilk.*, Februar, 1913.

(1) **v. Szily**, of Freiburg, opens his paper with a lucid account of the accepted theory as to the nature of anaphylaxis in general, and then proceeds to deal with researches and observations on the ophthalmological aspects of the subject. He refers to experiments on the sensitisation of guinea pigs to emulsions of eye tissues, and next discusses the possibility of a general anaphylaxis being brought about from the eye as a centre. He points out that this is still an open question as far as an animal's own tissues are concerned. He casts doubt on the trustworthiness of the statement of Krusius that if one lens of a guinea pig is needled fourteen days after discission in the other eye, a general anaphylactic reaction is set up from absorption of the lens protein.

The author describes a series of experiments on the eyes of rabbits, designed to illustrate what he believes to be the separate types of anaphylactic reaction. In the first experiment one or two drops of sterile inactivated horse serum were injected into the rabbit's cornea. In some cases the eye remained entirely free from reaction. In others a mild keratitis appeared after an interval of fourteen days. In either case if the second eye now received a similar injection it developed a keratitis within twenty-four hours. The second experiment began in the same way, with injection into one cornea. Whether the fourteen days reaction occurred or not, a second injection into the *same* cornea produced in twenty-four hours, a very severe interstitial keratitis complicated with iritis. In the third experiment 4 cc. of the horse serum were injected into a vein fourteen days after the original injection into the cornea. Twenty-four hours later a severe interstitial keratitis set in in the treated eye. In the fourth experiment a general (subcutaneous or intravenous) injection was first given, and two weeks later an injection was made into the cornea of one eye. The characteristic local changes occurred twenty-four hours later.

The author thinks it probable that the inflammation which begins in the cornea fourteen days after the first injection is of the nature of a local anaphylaxis, due to the toxic effect of slowly accumulating disintegration products of the tissues. A somewhat analogous explanation has been offered for the illness which sometimes occurs in man ten or twelve days after an injection of serum.

In the cases in which no reaction follows the first injection, we must assume that the disintegration products have been absorbed and dealt with by the tissue cells. The conflict, however, leaves its mark on the cells, which, on the repetition of the injection, give a more intense reaction. This obviously is not an explanation but merely restates the problem.

It is interesting to note that, although there are many examples of hypersensitiveness and adaptation to the effects of chemical poisons, these processes are distinguished from anaphylaxis and immunity by the facts that the latter can only be produced by bodies of an antigen character, that the symptoms differ for each different chemical poison, while the symptom-complex of anaphylaxis is the same for all antigens, and that hypersensitiveness to a chemical poison cannot be transferred through the serum to a normal animal, while anaphylaxis can be so transferred.

The most interesting application of the question of anaphylaxis in ophthalmology is in the direction of explaining sympathetic ophthalmitis and interstitial keratitis. Elschnig's theory of sympathetic assumes that an injury to one eye liberates uveal pigment, the absorption of which sensitises the whole organism to this antigen. The occurrence of some slight affection of the other eye associated with disturbance of pigment leads to a local anaphylatic inflammation. Since the sensitising process affects the exciting as well as the sympathising eye, the same pathological changes are found in both. There is still no proof of the anaphylactic nature of sympathetic ophthalmitis, as it is still open to doubt whether sensitisation to homologous tissue products can occur; but if such a process can be shown to be possible, it may explain many little understood phenomena of eye disease. It is particularly tempting to offer anaphylaxis as the explanation of interstitial keratitis, and in view of the experiments here described we may be on the point of discovering the true relationship between interstitial keratitis and trauma. Many other interesting topics are touched upon in this paper, which is worthy of perusal in the original. A. J. BALLANTYNE

(2) The so-called toxipeptide intoxications, or intoxications due to the products of protein disintegration, include such conditions as "anaphylactic shock," poisoning by anaphylatoxines, cholera, meat poisoning, and botulism, and these sometimes give rise in man to acute symptoms similar to those of poisoning by methyl alcohol and other related bodies. It has been shown by Segale that the two groups of toxines differ in the resulting serum reactions. **Grignolo,** of Genoa, undertook some researches to determine the condition of the aqueous under similar circumstances. The points investigated were the osmotic pressure, the index of refraction, and the concentration of hydrogen ions in the aqueous and in the blood serum. After poisoning with methyl alcohol, there was a pronounced rise in the osmotic pressure both of the aqueous and of the blood serum, a slight and unimportant increase in the concentration of hydrogen ions in aqueous and blood serum, no change in the index of refraction of the aqueous, while the index of refraction of the blood serum showed a diminution. A similar series of experiments conducted with peptonic poisons gave no change in the osmotic pressure, refraction index, and concentration of hydrogen ions in the aqueous, while in the blood serum all three showed a rise. Taking the

results as a whole they show that the active substances, whatever they may be, diffuse easily into the aqueous in the case of the methyl alcohol group of poisons, but not so in the case of the peptonic poisons. This probably depends on a selective action on the part of the cells of the ciliary body.

A. J. BALLANTYNE.

IV.—GENERAL ANÆSTHESIA.

(1) **Rollet.—New apparatus for etherisation in eye surgery. (Nouvel appareil à l'etherisation pour la chirurgie oculaire.)** *Revue Général d'Ophtalmologie*, 31 décembre, 1912.

(2) **Rutherford, L. T.—The lacrymal gland in surgical anæsthesia.** *British Medical Journal*, June 21st, 1913.

(1) **Rollet**, of Lyons, has entirely given up chloroform in eye work. If local anæsthesia does not suffice, he sometimes uses ethyl chloride, but if the anæsthesia is too short for the use of this, he employs ether. There does not seem to be anything specially new about Rollet's apparatus. It is certainly simple, consisting of a mouth-piece, a bag, and a bent tube, so arranged that the bag can be rotated to lie either by the right or the left shoulder. An opening near the bag allows ether to be poured in, and also acts as an air admittance.

ERNEST THOMSON.

(2) **Rutherford,** of Cambridge, draws attention to the fact that the behaviour of the lacrymal glands during the administration of chloroform or ether gives accurate information with regard to the progress of the anæsthesia. The lacrymal secretion is judged by the presence or absence of the "canthal tear"; that is to say, the flooding of the inner canthi with watery secretion. This varies in accordance with the stage of the anæsthesia. Thus, in the second stage, that of excitement, the secretion is copious. In the third stage, that of surgical anæsthesia, the canthi remain dry, and the cessation of the lacrymal secretion usually takes place a few breaths before the complete abolition of the corneal reflex, although the disappearance of reflex and secretion may occur simultaneously. To put the matter in another way, the lacrymal secretion bears a definite relation to the depth of the narcosis. Now the state of the pupils in impending vomiting and in over-dose are very similar, and it is in instances such as this that the value of the "canthal tear" becomes apparent. To quote the author's words:—"If the canthi have been kept dry up to the moment at which the pupils commence to dilate, and if they remain dry after the pupils are dilated, then the anæsthetist should at once withhold the anæsthetic, and prepare to deal with a case of relative or absolute overdose; but if the canthi are seen to be flooded with tears, then the anæsthetic must be pressed to secure an adequate anæsthesia by abolishing the vomiting reflex."

SYDNEY STEPHENSON.

V.—ECLIPSE BLINDNESS.

Birch-Hirschfeld.—On eclipse blindness. (Zur Kapital der Sonnenblendung des Auges.) *Zeitschrift für Augenheilkunde*, Oktober, November, and Dezember, 1912.

Birch-Hirschfeld, of Leipzig, had the opportunity of examining 34 cases and 50 eyes which had suffered by observing the eclipse of April 17th, 1912, and he has communicated the clinical results and some experimental researches in a long paper which extends into three numbers of the *Zeitschrift*.

Eighteen of the patients had only injured one eye, sixteen had suffered in both. One patient had used a smoked glass to watch the phenomenon, three had employed an opera glass, one a prismatic glass, one had looked through a dark-coloured glass, the remainder had merely watched the eclipse through the slit formed by holding the fingers close together.

Almost all the patients' experienced subjective sensations; in one erythropsia was complained of.

Six patients had a normal visual acuity, 6 had slight loss of acuity (6/9—6/15) and in 15 the acuity sank to 6/18, 6/24, and 6/20, and in 5 cases to 6/60. Only four of the patients were blonds and three of these had full acuity, one only slight loss of vision. The central scotoma is the most important symptom; it may occasionally be paracentral, and a ring scotoma has been described. It is a positive scotoma. It is sometimes so small that it may be overlooked unless a scotometer is carefully used. The author used the Priestley Smith instrument and also one of his own design. Thirty-one of the cases had a central scotoma, 19 a paracentral. No ring scotoma was detected. The size of the scotoma is generally proportionate to the degree of blindness, but not always. It is not an exact optogram of the sun's disc The positive scotoma was always surrounded by a relative scotoma for yellow.

In two only of his cases did the author fail to find changes at the macula. Generally they took the form of increase in the foveal reflex, which was veiled and often irregular. The periphery was dark reddish-brown. In other cases there was irregular pigmentation of the macula with irregular punctate spots. The extent of the ophthalmoscopic changes does not correspond in any way to the degree of functional loss.

The paper discusses the anatomical basis of eclipse blindness, all knowledge of which is derived from experiments upon rabbits. The essential elements are necrosis of the nervous elements, associated with a transudation from the choroid and coagulation of albumin. The author notes swelling and distortion of the rods and cones with choroidal exudation.

The concentrated light rays are the chief agents which produce the changes, although it is impossible absolutely to exclude all action of the heat rays.

The best treatment is to wear dark glasses. The prognosis must be very guarded, for permanent loss of acuity is very common.

The paper ends with an analysis of the answers Birch-Hirschfeld received to questions he sent to all the ophthalmologists in Saxony. He estimates that in Germany 3,500 individuals suffered from the eclipse, and of these 500 were permanently damaged. T. HARRISON BUTLER.

VI.—RECURRENT ŒDEMA.

(1) Brunetière, C.—A contribution to the ætiology of acute recurrent œdema of the eyelids. (Contribution à l'étiologie de l'œdème aigu récidivant des paupières.) *La Clinique Ophtalmologique*, 10 octobre, 1912.

(2) **Maklakow, A.—A case of recurrent œdema of the orbit. (Un cas d'œdème recidivant de l'orbite.)** *La Clinique Ophtalmologique*, 10 décembre, 1912.

(1) **Brunetière,** of Bordeaux, after referring to the hitherto non-committal type of ætiology usually given in explanation of cases of recurrent palpebral œdema, namely, arthritism and hysteria, comes to the conclusion that while these conditions are doubtless more or less important factors, it is only as predisposing factors that they play a *rôle*. The real exciting cause of this kind of œdema is a toxic one. This type of œdema is analogous to urticaria. Sometimes the intoxication is exogenous, whether alimentary or medicamentous, but more often is due to toxic intestinal products the result of gastro-intestinal disturbance Among the exogenous medicamentous agencies which can cause this œdema of the eyelids may be mentioned antipyrine, iodide of potassium, and bromide of potassium. The author brings forward several striking cases of the condition due to auto-intoxication.

ERNEST THOMSON.

(2) Recurrent œdema of the orbit is extremely rare. In the Graefe-Saemisch *Handbuch* five cases are recorded, Motais published a sixth in *Annales d'Oculistique*, Vol. XCV, and to these **Maklakow,** of Moscow, has now added a seventh. This case, which unfortunately the writer did not actually see, seems from the description of the patient to have presented symptoms identical with those in the cases of Gruss, Teillais, and Motais, namely, in this case of Maklakow's, sudden sharp pain, swelling of the lids, redness of the eyeball, fever, shivering, and great heat in the eye. After six or seven hours, there were vomiting and diarrhœa, while the swelling of the eye gradually diminished. This sort of thing takes place every year or two. Sometimes the right, sometimes the left, eye is affected, but, while the right has full vision, the left eye suffers from optic atrophy.

The author thinks these cases represent a form of Quincke's disease, angio-neurosis, and that in this ocular form optic atrophy may be a sequel.

ERNEST THOMSON.

VII.—SCLERO-CORNEAL TREPHINING.

(1) **Dupuy-Dutemps.—A modification in the technique of Elliot's trephining. (Une modification à la technique de la trépanation d'Elliot.)** *Bull. de la Société d'Ophtalmologie de Paris*, mars, 1913.

(2) **Reeve, R. A.—Notes on trephining the sclera.** *Trans. Seventeenth Meeting of the American Academy of Ophthalmology and Oto-Laryngology*, p. 81. (Received May, 1913.)

(1) Even in cases of acute glaucoma, **Dupuy-Dutemps**, of Paris, recognises that trephining entails little surgical risk. He has carried out the following modification of Elliot's *technique* in ten cases of subacute or chronic glaucoma. As shown in Fig. 1, the conjunctiva is detached from its corneal insertion for about one-quarter of the circumference of the cornea, and separated by a few snips of the scissors for a height of about one centimeter from the sclera above. The conjunctiva, thus liberated, retracts readily. As shown in the figure, a couple of silk threads are passed symmetrically. With a 2 mm. trephine, a disc of sclera is removed from immediately behind the narrow strip

of conjunctiva left adherent to the limbus. Iridectomy is practised only if iris presents in the wound. In the final step (see Fig. 2) the sutures are drawn together and tied, so that the scleral flood-gate (*le pertuis scléral*) is completely covered by conjunctiva.

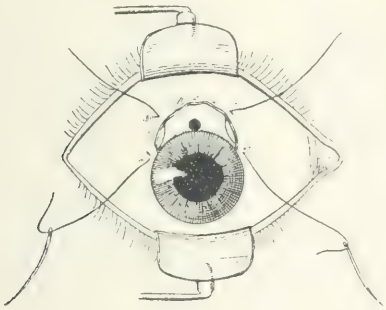

Fig. 1.

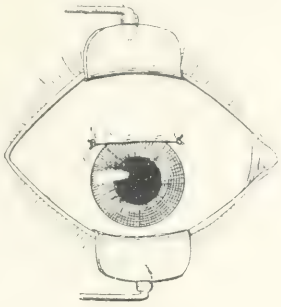

Fig. 2.

Discussion.

Morax, of Paris, had not met with the difficulties that led Dupuy-Dutemps to modify Elliot's operation. It was doubtless a simpler operation than that devised by Lagrange, but which yields the better results it will scarcely be possible to say until several years have elapsed. There would appear to be the danger in the Dupuy-Dutemps' modification that displacement of the conjunctival flap might leave the scleral fistula without covering.

SYDNEY STEPHENSON.

(2) **Reeve**, of Toronto, Canada, reports five cases in which Elliot's operation yielded good results. Nature of cases follows:—painful absolute glaucoma; intumescent cataract; results of irido-cyclitis with increased tension; blind and painful and cataractous eye with increased tension; glaucoma secondary to perforation of the cornea. Reeve suggests that such is the simplicity of Elliot's operation that it might be substituted for posterior sclerotomy.

SYDNEY STEPHENSON.

VIII.—OCULAR SPOROTRICHOSIS.

(1) **Dor, L.—A case of ocular sporotrichosis.** *La Clinique Ophtalmologique*. 10 mars, 1911.

(2) **Jocqs, R.—Complementary note on ocular sporotrichosis.**

(3) **Chaillous, J.—Disseminated gummatous sporotrichosis, intra-ocular gumma, perforation of the sclerotic.** (Sporotrichose gommeuse disséminée, gomme intra-oculaire, perforation de la sclérotique.) *Ann. d'Oculistique*, novembre, 1912.

(4) **Morax, V.—Primary sporotrichosis of the eyelids simulating a lacrymal fistula.** (Sporotrichose primitive des paupières simulant une fistule lacrymale.) *Bull. de la Société d'Ophtalmologie de Paris*, février, 1913.

(1) **Dor**, of Lyon, is reminded by the review (by Jocqs) on ocular sporotrichosis, a translation of which was published in THE OPHTHALMOSCOPE, of March, 1911 (p. 184), of a case of his own:

An infant of a few months had been vaccinated with a vaccine which had not hitherto given any trouble. The vaccinal eruption had been violent, and one of the inoculation points had become deeply ulcerated. The child suffered in succession from boils, pleurisy, and enteritis with false membranes. Dor was called in on account of a peculiar kind of keratitis. There was no photophobia, and no redness of the conjunctiva. Just as if it had fallen upon the cornea, there was a round, yellow, shining spot, like a drop of wax. Dor's first impression was that it was a mycosis. He curetted it, but in a few days, there was a recurrence of even greater extent. The general state of the patient became worse and worse, and then one day the mother pointed out a gumma-like swelling on the child's sternum. This was a revelation to Dor, who at once prescribed the administration of iodide in large doses. The temperature fell, and the child rapidly became convalescent—too late, however, to save the eye from a prolapse of the iris. As far as the translator gathers, some mistake was made about the investigation of the contents of the gumma, a sample of which was sent to a bacteriologist; but fortunately for the completion of the evidence, the mother became infected on the lip, and the abscess which formed was found to contain the parasite.

Dor does not know whether to blame the vaccine for the infection, or to consider the latter as secondary. ERNEST THOMSON.

(2) **Jocqs**, of Paris.—We have omitted from the list of works on ocular sporotrichosis quoted in our review in the number of March, 1911, that of M. Aurand, of Lyon ("Recherches sur la sporotrichose expérimentale," *Revue Générale d'Ophtalmologie*, juin, 1909). Aurand carried out five series of inoculation experiments on rabbits; on the conjunctiva, the sub-conjunctival tissue, the cornea, the iris, and the vitreous, the whole series comprising a total of thirty experiments. Although we ourselves had only in view clinical sporotrichosis, these experiments deserve recognition as being of service to other experimenters, and because they give indications as to the diagnosis of human sporotrichosis, especially in fundus lesions (of which very little has hitherto been known as regards man), which are shown in beautiful coloured plates.

As we have foreseen, publications upon sporotrichosis are multiplying. At the meeting of the Ophthalmological Society of Paris held on January 3rd, 1911, two new cases were published. In the case reported by G. Chaillous there was an ulcerative and vegetating conjunctivitis of the upper cul-de-sac. The other case was by Morax; there was primary sporotrichosis of the lacrymal sac, suppurative dacryocystitis, with pericystic abscess, pre-auricular adenopathy, and a gumma in the thickness of the cheek at the level of the horizontal branch of the inferior maxillary. In both cases the diagnosis was made by culture. ERNEST THOMSON.

(3) **Chaillous**, of Paris, records the case of a woman, aged 72 years, who suffered from sporotrichosis, which, commencing as an ulceration of the left lower eyelid, gave rise to generalised infection with an intraocular focus, which caused perforation of the eyeball. When the patient was seen by the author, the ocular lesions were ectropion of 3/4 of the left lower eyelid, accompanied by a curved band of cicatricial thickening in the skin below the outer 2/3 of the lid, separated from its margin by a band of supple skin, and thickening over the upper and outer part of the eyeball, with two ulcers in it, the larger, 1 cm. in diameter, discharging a yellow viscid pus, and the smaller, 3 or 4 mm. in diameter. There were signs of old iritis with seclusion of the pupil. The

general lesions consisted of gummata, some in the infiltration stage and some ulcerating, on the parieto-temporal, scapular, and thoracic regions, over the internal surface of the right tibia, and on the right hand. There was no glandular enlargement. The presence of sporotrichosis was proved by cultures. Under treatment with potassium iodide, commencing with 2 grammes and increased to 4 grammes daily, all the lesions were much improved in a fortnight. The thickened band on the cheek is of interest, as a very similar condition existed in a case of sporotrichosis of the lower lid, under the care of Thibierge. R. J. COULTER.

(4) A man of 38 years suffered towards the end of November, 1912, from "Grippe," and at about the same time he noticed a small, red prominence in the region of the left lacrymal sac. It was not painful, and was not accompanied by watering of the eye. On examination by **Morax**, of Paris, a reddish oval swelling, 1 cm. by 6 cm., was found in the usual site of lacrymal fistulæ. A slight depression was seen at its centre. A sound introduced through this opening entered a small superficial cavity. The integrity of the lacrymo-nasal canal was proved in the usual way. The preauricular gland was swollen, but free from tenderness. Tubes of potato and of ascites-agar were inoculated with material obtained by scraping the cutaneous gumma, and at the end of four days at incubation temperature, they contained several colonies of the *S. Beurmanni*. Much improvement under the internal administration of potassium iodide. Morax surmises that the infection had probably gained entrance through the lacrymal sac.

SYDNEY STEPHENSON.

IX—MODERN METALLURGY IN OPHTHALMOLOGY.

Rollet, E. and Aurand, L.—Experimental researches on the intra-ocular action of the new Metals. Recherches expérimentales sur l'action intra-oculaire de métaux nouveaux.) *Revue Générale d'Ophtalmologie*, 31 mai, 1913.

It will be within the recollection of most readers that Rollet recently investigated the newer metals with regard to their magnetic qualities, when combined with iron in the form of the various steels (abstract in THE OPHTHALMOSCOPE, 1911, p. 591).

Rollet and **Aurand**, of Lyons, have now completed a series of experiments to determine the influence of these metals on the ocular tissues, and have compared them in this respect with iron, steel, and copper. Most of the usual metals have been already fully investigated. The action of iron in causing siderosis, and the very intense chemical action of copper in the eye are well known. Modern metallurgy has called for a number of alloys of iron with other metals (*ferros*), of which the important ones are aluminium, chromium, and tungsten. The authors have made experiments with nickel, chromium, aluminium, tungsten, manganese steel, and also with iron and copper, the experiments being, so far as possible, similar in each case. The splinters chosen were of approximately the same volume and were sterilized at 140 degrees C. Every possible precaution was taken to avoid sepsis at the operations and afterwards. The animals selected were rabbits. In the case of each metal a fragment was introduced into each of four different regions, namely, the anterior chamber, the iris, the ciliary body, and the vitreous.

The iron employed contained 0·05 per cent. of carbon, traces of manganese, and 0·03 per cent. of silicon. The manganese steel contained 0·660 per cent. of carbon, 0.512 per cent. of manganese, and 0·432 per cent. of silicon.

The following are the authors' main conclusions :—

I. Aluminium, tungsten, iron, and steel provoke such a slight reaction that it is invisible and consists simply in a fibrous transformation of the aqueous resulting in a slight false membrane.

II. Aluminium causes no reaction in the vitreous and remains free in this tissue.

III. Only nickel and chromium cause a suppurative inflammatory reaction, comparable to that of copper, in the anterior chamber and iris

IV. Nickel alone can like copper, but to a lesser degree, cause degenerative lesions of the retina and a chronic sclerosing hyalitis.

V. In the ciliary body, all the metals experimented upon, even copper, produced only a slight and transitory reaction, doubtless due to their spontaneous expulsion. This happened in every case.

VI. Not a single one of the experiments was followed by panophthalmitis. Clinically, therefore, the suppurative reactions caused by nickel and chromium are due to a chemical action proper to each metal, analogous to that of copper, which leads more or less rapidly to encystment in the majority of cases.

VII. Encystment resulted in one-half of the experiments, especially in the anterior chamber and iris : it seemed to be favoured by the oxidation of the metal.

VIII. In none of the experiments upon iron, steel, or copper, not even in the longest (which lasted six months), did the authors see the ocular tissues take on "the reddish tint of siderosis or of the diffusion of copper."

IX. Sympathetic ophthalmia did not occur as the result of the experiments on the ciliary body. The authors suppose that this may be due as much to the asepticity of the metallic fragments as to their rapid spontaneous expulsion. ERNEST THOMSON.

X.—NODULAR OPACITIES OF THE CORNEA.

Puscarin, Elena.—Two cases of nodular opacities of the cornea (Groenouw's disease). [Deux observations d'opacités nodulaires de la cornée (maladie de Groenouw).] *Archives d'Ophtalmologie*, juin, 1913.

Nodular opacities of the cornea, although admittedly very rare, is so well marked a condition that its appearance must be familiar to most of the readers of THE OPHTHALMOSCOPE.

Puscarin, of Bucarest, first touches upon the literature of the subject. A perusal of the list of references shows that she is acquainted imperfectly, if at all, with the British and American work dealing with the subject. She mentions one paper alone couched in the English language, and that is the work of an American writer.

The published cases appear to show that (1) the malady is commoner in males than females ; (2) it often affects several members of the same family ; and (3) it begins in most instances between the tenth and thirteenth year. There is considerable difference of opinion with regard to the microscopic appearance of the corneal lesions. For example, Groenouw insists upon the presence of hyaline deposits in the interstitial tissue ; Fuchs upon a colloid transformation of the corneal lamellæ ; and Wehrli upon chronic inflammatory lesions, and more particularly upon the presence of Koch's bacilli. As to the

pathogeny of the malady, Fuchs believes that it represents a local manifestation of a general disturbance of nutrition, while Wehrli concludes that the nodular opacities of the cornea are manifestations of a primary chronic tuberculosis involving the anterior layers of the cornea—a lupus of the cornea, in fact.

Both Puscarin's patients, aged 20 and 45 years respectively, suffered from pulmonary tuberculosis, but in the one case where it was tried, the use of tuberculin led to no improvement in the state of the cornea.

By means of a von Hippel's trephine, a disc of corneal tissue was removed from the second case. Microscopical examination showed the following points.—The epithelium was thinned, and often reduced to from two to four layers of cells. The deepest layer of cells had become round, cubical, irregular, with round nuclei, which stained strongly with hæmatoxylin. The lower limit of the epithelium, instead of being a straight line, as under normal conditions, was very irregular and was often festooned. Bowman's membrane was frequently absent, and when it did exist, it was often reduced to one quarter of its normal thickness, detached from the epithelium, and thus formed spaces in which one saw a granulous mass, which took stains feebly. As regards the tissue proper, there were alterations in the lamellæ, the interstitial spaces, and the cells. In general, the lamellæ took eosin-hæmatoxylin and van Gieson more feebly than in the normal state. In the superficial layers the lamellæ were extensively dissociated, and in limited regions, lying immediately beneath the epithelium, they formed a large-meshed network. In the regions named the lamellæ were very thin, and were indeed reduced to undulating filaments. The cavities were partially filled with the swollen nuclei of corneal cells embedded in a granular mass, scarcely coloured violet with eosin-hæmatoxylin, and yellow with van Gieson's stain. The interstices became smaller in the deeper parts of the tissues, and were almost filled with granular tissue, in which nuclei could be recognised.

When thionine was used, the appearances were much more instructive. The superficial lamellæ stained much less feebly than the deep ones. The latter often presented a border stained violet-purple. The fibrillation of the lamellæ was very obvious. Here and there the lamellæ presented limited swellings, like knots, having a homogeneous appearance and staining blue. The granular masses could be studied readily, inasmuch as they were stained dark-blue. The masses were formed of granules, 1 μ to 3 μ in size, irregularly rounded, and having a colloid aspect. These granulations filled the small interstices, while in the larger interstices they tended to accumulate toward the periphery. There was an evident relationship between the granulations and the corneal cells.

It will be evident, then, that the nodular opacities, according to Puscarin, are due to a degenerative process involving the substantia propria of the cornea, consisting of (1) swelling of the cells and an accumulation within their cytoplasm of abundant granulations, probably of colloid nature, and (2) an alteration of the corneal lamellæ, leading to the dissociation and destruction of the last-named. In consequence of these profound changes, the epithelial layer suffers in its nutrition, and undergoes a process of atrophy. It is of importance to note that Puscarin's preparations showed not the least trace of inflammatory reaction. Lastly, no support is lent to Wehrli's theory by the microsopical examination of Puscarin's specimens.

The author considers that all the changes found by her were of degenerative nature, and she rallies to the opinion of Fuchs, namely, that Groenouw's disease is the local manifestation of some as yet unknown disturbance of nutrition.

SYDNEY STEPHENSON.

XI.—KERATOCONUS.

1 **Shoemaker, J. F.—Keratoconus and ectopia lentis.** *American Journal of Ophthalmology*, February, 1913.

2 **Strebel, J. and Steiger, O.—On keratoconus: its relations to the internal secretions and to the intra-ocular pressure. (Ueber Keratokonus. Seine Beziehungen zur inneren Sekretion und zum intraokularen Druck.)** *Klin. Monatsbl. f. Augenheilk.*, März, 1913.

(1) **Shoemaker**, of St. Louis, reports the case of a woman of twenty-seven years who stated that her vision had always been poor, as was that of her mother and a number of relatives, one or two of whom had become practically blind. She had been wearing the same glasses for ten years. These were R. + 7·5 D. Cyl. ax. 155°, V. = 18/30. L. + 11·5 D. Cyl. ax. 15° V. = 18/96, She read J.1 at 2 inches with the right and at 1 inch with the left without glasses.

On ophthalmoscopic examination, it was found that in addition to the conical corneæ, the lenses were displaced directly downwards, leaving the upper parts of the eyes, corresponding to a little less than half the pupils, aphakic. Both lenses were perfectly clear. The refraction was examined under homatropine and the final result was R.V. = 18/24 and L.V. = 18/96 with a minus correction. She could read J.1 with either eye up to 4 inches. Orientation, however, was poor, and then it was found that better vision was obtained through the aphakic parts. R. −1·50 D. sph. + 8 D. Cyl. ax. 155° V. = 18/19. L.—3·00 sph. + 8 D. Cyl. ax. 15° V. = 18/75. With the plus cylinders alone, the patient could obtain R. 18/30 and J.1 at 6 inches; L. 18/96 and J.2. These were ordered, and the patient was comfortable with good orientation. The remainder of the article is concerned with general references to the ætiology and treatment of keratoconus and of lental dislocation. ERNEST THOMSON.

(2) Siegrist and Kottmann have recently stated that in cases of keratoconus there is a constant blood condition, which includes an increase in the percentage of lymphocytes and an excessive coagulability. They seem to have expressed the opinion that these changes are evidence of hypothyroidism, and that this metabolic disturbance, in combination with some other factor, astigmatism for example, is responsible for the occurrence of keratoconus.

Strebel and **Steiger**, of Zürich, being in doubt as to the accuracy of this view, undertook a detailed examination of seven cases of keratoconus which were available in the Zürich clinic. They give in considerable detail the case-histories of these seven patients, as well as the results of a general blood examination, the ocular tension, the blood pressure, and the Wassermann reaction. The following are some of their results :—

Anæmia and chlorosis were not found. In some of the cases the amounts of hæmoglobin and erythrocytes were above the normal. No case showed any large increase of lymphocytes. In most cases they were in normal proportion, and where they were increased in number this could be explained on other grounds. There was no abnormality of the rate of coagulation, but there was slight elevation of the viscosity of the blood. Wassermann's reaction was negative in every case. In recording the tonometer results they distinguish between "absolute" and "relative" intraocular pressure. The former was found to be low, but the latter somewhat high. They do not accept the view that keratoconus is due to a developmental anomaly, chiefly because of the absence of other congenital defects in these cases and because the condition usually appears as late as the period of puberty. In several of

their cases they found "Axenfeld's sign," namely, anæsthesia of the apex of the cone. Almost all the cases had opacities at the affected part of the cornea. These opacities were of two kinds, *viz.*, interstitial maculæ, and a number of more superficially placed fine lines which might be folds or ruptures in Bowman's membrane or in the most superficial layers of the stroma. In two cases nerve fibres could be seen with the *loupe* passing into the first-mentioned deeper seated opacities.

The authors are disposed to assume the existence of a neurotic affection of the cornea. This brings about a weakened resistence of the cornea, and thus leads to the relative elevation of the intraocular pressure, increased by the movements of the globe and by the pressure of the lids.

A. J. BALLANTYNE.

XII.—METHODS.

(1) **Snyder, W. H.—A simplified Gram technique.** *Archives of Ophthalmology*, November, 1912.

(2) **Mawas, Jacques.—On a new method of bleaching histological sections. (Sur un nouveau procédé de dépigmentation des coupes histologiques.)** *Bull. de la Société d'Ophtalmologie de Paris*, avril, 1913.

(1) **Snyder**, of Toledo, proposes to do away with the difficulties of using the Gram stain by employing a stable solution. His methyl-violet stain has the following formula: Melted carbolic acid crystals, 12·5 cc., absolute alcohol (ethyl), 25 cc., methyl-violet 6B Gruebler, 1 gr. Dissolve, keep in a warm place for twenty-four hours, and filter. This solution keeps indefinitely and only requires dilution when using (1:4). He has also replaced the flexible platinum loop by one of irido-platinum bent into a triangular-shaped loop 3 mm. by 2 mm., which loop is soldered shut with gold, and afterwards polished and burnished on the puffing wheel until perfectly smooth. The advantage is that this is stiff and permits the stroking movements necessary to dislodge epithelial cells containing gonococci with greater ease and success. The handle is a dental metallic broach-holder. Snyder prefers slides to cover-glasses in making smears. He makes the smear by placing two drops of distilled water in formalin (1 in 1,000) on the slide, one for each eye; the loop then transfers some secretion to each drop and mixes it evenly with the water; the smear is dried by a drop of absolute alcohol, which soon evaporates, leaving a thin smear, securely fixed to the slide. When staining 3 or 4 drops of distilled water are dropped upon the slide and the stain is added to this (the reverse method is not so satisfactory). One drop of the alcoholic methyl-violet solution should be used and left on for only 25 seconds; it can then be washed off under the tap. Lugol's solution is now added and left for 15 seconds, and then, without washing, the slide is decolourised with absolute alcohol until no colour washes off. It may then be washed in water, and counter-stained with 5 per cent. watery safranin or weak fuchsin solution. Finally, it is necessary thoroughly to wash with water, dry, and examine in water, oil, or Canada balsam, with or without cover glass. After examination the slides are always placed in nitro-hydrochloric acid, which disposes of infection and cleans the slide. The Lugol's solution used is as follows: iodine crystals 1, pot. iod. 2, distilled water 300.

ROSA FORD.

(2) **Mawas**, of Paris, is convinced that all methods of bleaching microscopic sections give rise to oxidation of the pigment, with consequent discolouration of the latter. With a view of avoiding this complication, he employs chromic acid in the following way.—The sections, whether embedded in celloidin or paraffin, are left for from twenty to twenty-four hours in a 2 per cent. watery solution of chromic acid. The embedding material should be dissolved from paraffin sections before they are placed in the chromic acid. When treated in this way, sections do not become friable, and take ordinary stains quite well. The acid appears to decolourise the pigment of tumours more rapidly than the pigment of the normal eye.

SYDNEY STEPHENSON.

XIII.—CELL BODIES IN TRACHOMA.

1) Isabolinsky and Spassky.—Upon the question of the diagnostic value of the "chlamydozoa" of Prowazek and Halberstädter in Trachoma. (Zur Frage über den diagnostischen Wert der "Chlamydozoa" Prowazek-Halberstädter beim Trachom.) *Zeitschrift für Augenheilkunde*, Februar, 1912.

2) Botteri, A.—Clinical, experimental, and microscopic studies of trachoma, inclusion blennorrhœa, and spring catarrh. (Klinische, experimentelle und mikroskopische Studien über Trachom, Einschlussblennorrhöe und Frühjahrskatarrh.) *Klin. Monatsbl. f. Augenheilkunde*, Juni, 1912.

3) Addario C.—About the presence of the Prowazek bodies in the follicles and papillæ of trachoma. (Ueber das Vorkommen des Prowazek Körper in den Follikeln und Papillen des Trachoma.) *Centralblatt für Bakteriologie*, v-vi Heft, S. 393, 12 Oktober, 1912.

4) Junius.—Cell studies in trachoma. (Zellstudien bei Trachom.) *Zeitschrift für Augenheilkunde*, November, 1912.

5) Addario.—About the importance of some of the formations, taken for parasites, in trachoma. (Ueber die Bedeutung einiger bei Trachom gefundener und für parisitar gehaltener Bildungen.) *Archiv für Augenheilkunde*, Bd. LXXII, Heft iii and iv, S. 191, November, 1912.

(1) **Isabolinsky** and **Spassky,** working upon the rich material available in the Government Hospital at Smolensk, have carefully examined 200 patients to determine whether the cell inclusions are specific for trachoma or not. Eleven cases had acute trachoma, and 96 chronic trachoma. The remaining 93 suffered from other diseases; follicular catarrh, acute conjunctivitis of various kinds, chronic conjunctivitis, gonorrhœal conjunctivitis, and vaginal secretion of gonococcal origin. In cured trachoma 39 per cent. gave a positive result; in active trachoma 53 per cent. contained the inclusions. In the control non-trachomatous cases the inclusions were present in 53 per cent. of the active cases, in 39 per cent. of the chronic cases. The authors naturally conclude that the bodies have nothing whatever to do with the causation of trachoma, an opinion which is now generally held; so much so that even Greeff himself no longer believes that they are specific for this disease.

T. HARRISON BUTLER.

(2) A very useful feature of this paper by **Botteri**, of Trieste, is a review of the now somewhat complicated story of the cell inclusions, first described by Halberstädter and von Prowazek, in 1907, and since subjected to so much investigation by others. He also appends a very complete bibliography of the whole subject. The paper should be consulted by all interested in the problems of the so-called "trachoma bodies."

It may be useful to give here a summary of the characteristics of "inclusion blennorrhœa of the newborn," based on his twenty-two cases :

It is always bilateral. Onset between fifth and twelfth day of life, usually in form of a mucopurulent conjunctivitis of sudden onset, reaching its height in the second week and passing into a chronic stage, which lasts for from eight to twelve, or more, weeks. Never corneal complications. No follicle formation. No cicatrices in conjunctiva. In more than half of the cases a severe rhinitis coming on from the third to the fifth week, and lasting from four to seven weeks. Inclusion blennorrhœa never recurs. It is met with in regions where trachoma is uncommon.

It would be impossible to deal here with Botteri's experiments, but some of his conclusions may be stated :

It was found that the trachoma *virus* loses its infectivity after exposure for three-quarters of an hour to a moist temperature of 0°C. to 10°C., for four hours at 15°C., or for half-an-hour to a dry heat of 15°C. Cell inclusions are not constantly found in human trachoma, nor is their abundance proportionate to the severity of the case. In all cases of gonococcal conjunctivitis of the new-born gonococci were found, but cell inclusions were absent. Bodies resembling cell inclusions were found in follicular catarrh, tuberculosis of the conjunctiva, and chronic gonorrhœal urethritis, but positive inclusions were found only in trachoma, spring catarrh, and 'inclusion blennorrhœa.'

In animal experiments it was found that the baboon was much more easily infected than the *Macacus rhesus*. Cultures of the gonococcus gave no infection of the conjunctiva of the baboon. Secretion from trachoma which contained no cell inclusions likewise gave a negative result in the baboon. Secretion from trachoma with inclusions produced, in the baboon, the characteristics of trachoma with inclusions in the secretion, but gave a negative result in the *Macacus*. Secretion from inclusion blennorrhœa produced in the baboon a much more severe conjunctivitis than that from trachoma, while the same secretion produced a slight conjunctivitis in the *Macacus*. The actual virus of inclusion blennorrhœa cannot be the cell inclusions or the "initial bodies" of Lindner, since the virus passes through a Berkefeld filter, the filtrate giving a severe conjunctivitis in the baboon, like that produced by the unfiltered secretion.

In the conjunctival secretion from spring catarrh, cell inclusions and initial bodies were found, indistinguishable from those of trachoma and inclusion blennorrhœa, but this material gave a negative result in the conjunctiva of the baboon. A. J. BALLANTYNE.

(3) In this detailed article **C. Addario**, of Palermo, begins by quoting Greeff, who stated, at the Heidelberg Congress in 1911, that the trachoma bodies had not been precisely differentiated by most of the reporters. After five years' study entirely on this subject, Greeff would not offer an opinion as to their importance. Soon after their discovery, the error was made of calling trachoma an epitheliosis, because the bodies were found only in the conjunctival epithelium. This opinion passed lightly over the well-founded belief that trachoma consisted in a specific enlargement of the adenoid layer, which goes through a scarring phase with a remarkable new

conjunctival formation. Addario examined some cases many years ago and described round cap-like enclosures which are always in the vicinity of the nucleus. It is now time to ascertain precisely what the enclosures are which are peculiar to trachoma, and to distinguish these from the pseudo-forms. The epithelium of the conjunctiva and genitals, in both the normal and pathological state, has enclosures which are not easily defined, but which, for the most part, are of a secretive and degenerative nature, and which may be easily confused with the enclosures of trachoma. Addario found trachoma bodies in the subepithelial tissue of the conjunctiva and in the real substance of the follicles in large numbers. Di Santo could not explain the fine free granulations which he discovered. The coccus and diplococcus-like bodies which Greeff described outside and within the large cells are also of no importance. The same may be said of the bodies described by Junius. The author examined some sections which he stained by Heidenhain's method. The preparations must be entirely decolourized by the iron-ammonia until the nuclei and nucleated granulations remain just coloured. This is controlled by microscopic examination. A few drops of alcoholic eosin are used as a contrast stain. He then describes in detail a number of the micro-photographs which illustrate the article. In the first one the field is marked by two bodies, A and B. A seems as if it were between two nuclei, but by changing the focus it is seen to cover, cap-like, a segment of the underlying nucleus. Each of these two formations is of a homogeneous substance in which can be distinguished black coloured grains. They do not differ in any way from the elementary bodies described by Prowazek in the epithelial cells. From his findings, Addario goes on to show that Prowazek and A. Leber found in what they call "epitheliosis," identically the same thing, and he draws the conclusion that their so-called "epitheliosis" is nothing but acute trachoma. Micro-photographs are further described in detail, any description of which, without the illustrations, would not be satisfactory.

Addario draws the following conclusions from his observations.—The Prowazek bodies, elementary or initial, are found in the real tissue of the follicles. This disposes of the claim that where these bodies are present we have to deal with an epitheliosis. We have rather a specific proliferative inflammation of the adenoid layer of the conjunctiva, with the formation of follicles, followed by cirrhosis of the conjunctiva. A further characteristic is the hydrops-like swelling, and the dissolution of the large and small body cells, which is followed by a dissolution of the entire follicle. The drawings of Lindner represent follicles of the normal mucosa, and exclude trachoma at a glance. The Prowazek bodies are often found in the developing follicles where mitosis is advanced. In the large and softened follicles the enclosures with initial bodies fail. In acute trachoma, the cell enclosures are met with first in the epithelium. In the second stage, as soon as the follicles begin to show themselves, they are found to be numerous in the follicles and papillæ. HANFORD MCKEE.

(4) **Junius,** of Cologne, has continued his studies upon the cellular pathology of trachoma, working at Budapest, where it was easier for him to get trachoma material than in Cologne. He has examined the cells in hanging drop preparations, and after staining them with a vital stain (neutral red) has succeeded in obtaining the micro-photographs which form the subject of the plate. Junius admits that he has reached no conclusion, but he believes that the secret of trachoma lies in the cell granulum. T. HARRISON BUTLER.

(5) **Addario,** of Palermo, first describes the findings of other workers. Vennemann, in 1892, found numerous round formations, which gave the reaction of hyaline, in a case of trachoma with ectropion. The formations seem to originate in the plasma cells at the expense of the basophile

granulations. Kamochi had, in 1886, described similar bodies in hyaline degeneration of the conjunctiva, and he regarded them as degenerated protoplasm. Soon after Katherine Kastalsky found similar bodies in all of forty cases of trachoma where there was no trace of hyaline degeneration. Kamochi, Marchi, and del Monte reported similarly in papillary hypertrophy of the conjunctiva. In 1896, Gonella described in seven of eight cases of trachoma formations with blastomycetic characters. They were found in the papillæ and in the underlying infiltrated connective tissue, and were as numerous in old as in fresh cases. From their constant regular formation, Addario believes that they were either hyaline or colloid formations. In the same year Guarnieri described round bodies, which occasionally had membranes of different sizes, from fourteen cases of trachoma. Parisotti also found blastomycetes in tissue from trachoma, pterygium, and spring catarrh. Fortunati, in 1904, isolated from the limbus tissue of spring catarrh two kinds of blastomycytes which were pathogenic for rabbits. Allesandro, in 1906, in ten cases of chalazion, found blastomycytes in the region of the giant cells, while Lodato, in 1908, in sections stained after the method of Mann, discovered red-violet bodies of different sizes. Lodato did not think that they were the bodies described by Leber and Gonella, even though somewhat similar, or that they were blastomycetes or hyaline or colloid substances. Addario, in 1909, stained sections of trachoma after Heidenhain's method, and found in the superficial part of the follicles, where proliferation is greatest, accumulations of small round or kidney-shaped black bodies. Each body was covered with a fine eosin coloured membrane. There were also long oval forms, enclosed by a thick capsule, probably blastomycetes. Spote also described similar formations in seven cases of fresh trachoma, and believes, as does San Felice, that the Russell fuchsinophile bodies, which are found in all chronic swellings, are only a re-formed blastomycetic body. Against the specificity of the bodies described above, and against their parasitic nature, must be noted the fact that they are observed in diseases which have nothing to do with hyaline or amyloid degeneration of the conjunctiva or trachoma. Further, they have been found in the optic nerve (Leber) and in the sympathising eye (Fuchs). These little bodies, which have always the same appearance, are met with particularly in cancer. Russell, in 1890, in forty-five cases, found these small red grains in the vacuole of the cell body, in forty-three. Many hypotheses were constructed to explain these formations. One considered them to be partly the same as the psorospermia of Albarran, 1899, and Malassez, 1890; some as red blood or epithelial cells with endogenous formations (Borel), descendants of leucocytes (Schuetz); or as degenerated nuclear products (Hansemann). Cazin and Duplay found similar bodies in tuberculous tissue. Thoma in 1890 expressed the opinion that they were parasitic, as did Sgrosso and Siobring; others that they were only the product of cell degeneration. Pianese in 1896, with new methods, showed that the supposed parasites of Thoma, were, in reality, nuclear changes. The constant appearance of such bodies in trachomatous tissue has given rise to similar different opinions. One holds them to be hyaline cell products; others blastomycetes.

To throw some light on the question, Addario examined specially the trachomatous conjunctiva in all its parts, also the hypertrophied lacrymal gland, and ear polyps. The fresh cut tissue was fixed in sublimate solution, alcohol, or Flemming's solution, and different stains, such as eosin-hæmotoxyln, methelene blue-eosin (Mann), Borrel, van Gieson, and others were used. In the submucosa of the trachomatous tissue, Addario found small round formations singly or in numbers. Surrounding the larger ones were found fine net-like

tissue with protoplasm reaction. They can be seen in all phases of their formation. First, one sees two or three bodies, which are lying in the cytoplasm of the cell, which is not quite normal. Later, they fill the entire cell body, when they show different dimensions. The smallest were near the nucleus, the others nearer the free border, as if they were preparing to get out. In other cases the arrangement was just the opposite. Further, some of the nuclei of the epithelial cells contained point-like violet grains, so that perhaps the nuclei participate in the formation of these bodies.

Addario draws the following conclusions from his examination of thirty cases of trachoma:

(1) The bodies described above are found mostly in trachoma with pannus, as well in the hyperplastic tissue between the follicles, as also inside the latter. We can follow their development from rare little formations inside the cell near the nucleus, to the final development, in which they fill out the enlarged cells.

(2) In acute or chronic trachoma, with marked development of the follicles, the bodies are found but rarely, and nearly always within the cells.

(3) In trachoma with moderate hypertrophy of the adenoid tissue and scar formation, they are often found singly or in groups.

(4) In trachoma of the tarsus, they are found regularly outside of the cells. Here an acidophile peripheral part can be distinguished from a basophile central part. The inside of the cells shows a larger round body which pushes the nucleus to the border, and reduces the protoplasm to a small rim.

(5) Only in one case of trachoma with pannus, was Addario able to find outside of the follicles the oval forms with a capsule. These probably represent parasites. In one lacrymal gland, also, the small grains were found singly and in groups. From these findings, Addario believes that he is able to exclude the little globes from having anything to do with the parasitic nature of trachoma, because they fail, or are very rarely found, in fresh cases and because they are found in organs which are not the seat of chronic inflammatory processes, such as the normal lacrymal gland. On the other hand, they cannot be looked upon as transformation products of blastomycytes affected by anti-bodies, because one never finds in fresh cases forms which can be recognised as blastomycytes.

The bodies which I have described are not identical with the fuchsinophile formations of Russell, because they take with van Gieson a yellow-orange instead of a red colour. By other staining they show a characteristic metachromatic reaction, or, finally, show a middle basophile, and a peripheral acidophile zone. The mass which forms the little globes is very similar to hyaline. They appear in trachoma, in the epithelial and lymphoid cells from protoplasm changes; but I cannot tell precisely how the end-result comes about.

HANFORD MCKEE.

XIV.—DISCUSSION ON CHRONIC IRIDO-CYCLITIS.

(1) Coats, George.—Discussion on chronic irido-cyclitis. (Annual Meeting of the British Medical Association at Liverpool, 1912.) *British Medical Journal*, 19th October, 1912.

(2) Ormond, A. W.—Discussion on chronic irido-cyclitis. (Annual Meeting of the British Medical Association at Liverpool, 1912.) *British Medical Journal*, October 19th, 1912.

(1) In the words of the writer himself, **Coats**, of London, "rambles rather freely" over the subject of chronic irido-cyclitis, but his rambling is productive of much that is of extreme interest to every ophthalmologist. Touching, first, on the subject of auto-intoxication as the cause of such cases, and omitting the question of pyorrhœa, Coats takes up a guarded attitude as to the influence of an abnormal state of the alimentary canal. It would be a desirable link in the chain of evidence, he says, if the same microbe could be cultivated from the eye and from the fæces . . . . or if clear evidence could be brought forward of improvement in the eye condition under the use of a vaccine prepared from the fæcal flora. The second subject taken up is the much debated one of the association of chronic cyclitis with heterochromia and cataract. Fuchs has put forward the two possibilities, namely, (a) either the iris may become bleached in consequence of the cyclitis, or (b) the blue colour of the iris may be the primary phenomenon and the cyclitis and cataract secondary. Fuchs rejects the first hypothesis, and with this summary rejection Coats is not inclined to agree. He considers it probable that the process is primarily a cyclitis of very insidious and chronic type, which is associated with bleaching of the iris and with the formation of a secondary cataract.

The third type dealt with is that known as sympathetic ophthalmitis. Modern research seems likely to establish that the disease is due to a living organism, and this organism reaches the second eye not by the nerves or orbital veins but by the general circulation. While the work of Gradle and of Price-Jones and Browning seems to point to protozoal infection similar to that of syphilis, the histological structure characteristic of sympathetic, on the other hand, is more nearly allied to that of the bacterial infection tubercle than to that of the protozoal infection syphilis. The treatment of sympathetic based upon these findings, that namely by Salvarsan, is, in the opinion of Coats, worthy of more extended trial.

The writer then deals with Elschnig's view, that sympathetic ophthalmia is not due to an organism but to anaphylaxis, brought about by the breaking down and resorption of uveal tissue in the injured eye He concludes that even supposing it to be proved that injury of one eye produced an anaphylactic state of hypersensitiveness in the other, it would still be necessary to postulate a specific organism as the cause of sympathetic disease. Lastly, having in view the occurrence of extremely mild cases, have we any pathological criterion whereby a certain diagnosis of sympathetic ophthalmia can be arrived at? Coats concludes that where there is a history of injury, and where the changes described by Fuchs are typically present, the diagnosis of sympathetic disease can be made with the utmost confidence. ERNEST THOMSON.

(2) **Ormond**, of London, read the second of the opening papers on this subject, the first having been read by George Coats. Ormond takes up the question of rheumatism and gout as ætiological factors in the causation of iritis. He develops his argument mainly along the line of want of proof, and gives at the end of his paper a useful summary, which we transcribe here.—"I would urge that cases of iritis and irido-cyclitis of the prolonged and intractable kind are due to the presence of specific organisms in the uveal tissue; that there is no evidence that toxins alone are capable of producing a localised inflammation of the uvea; that for this reason gout as an ætiological factor in producing iritis must be abandoned; that in the face of the widespread occurrence of rheumatic fever and the absence of any evidence to show that iritis is generally associated with it, rheumatism as an ætiological factor must be given up; the arthritic lesions which are frequently associated with iritis and cyclitis being due to microbic infections, derived from septic

absorption; and the causative factor of both the iritis and the arthritis is probably the same. In my opinion, all intractable cases of iritis and iridocyclitis are due to the presence of micro-organisms in the uveal tissue, and the pathological changes produced are the result of their presence there."

In the discussion which followed the reading of the two opening papers, the majority of the speakers disagreed with Ormond's conclusion as to the harmlessness of the toxins alone. ERNEST THOMSON.

XV.—REMEDIES.

(*Seventh Notice.*)

(1) Alger, Ellice M.—An optimistic view of migraine. *New York State Journal of Medicine*, March, 1913.

(2) Bruno, D.—Electric colloidal mercury in ocular therapeutics. (Le mercure colloïdal électrique—Hg.-en thérapeutique oculaire.) *La Clinique Ophtalmologique*, 10 mars, 1913.

(3) Darier, A.—Autoserotherapy and subconjunctival injections. (Autosérothérapie et injections sous-conjonctivales.) *La Clinique Ophtalmologique*, 10 mars, 1913.

(4) Frank.—On a case of bismuth excretion upon the cornea after insufflation of airol. (Ueber einen Fall von Wismuthausscheidung auf der Hornhaut nach Airolpuderung.) *Woch. f. Ther. u. Hygiene des Auges*, 20 März, 1913.

(5) Claiborne, J. Herbert.—Another case of gonorrhœal conjunctivitis aborted by a 2 per cent. solution of nitrate of silver. *New York State Journal of Medicine*, April, 1913.

(6) Calhoun, F. Phinizy.—The report of a case of sympathetic ophthalmia, developing seven days after operation. Treated by Neo-salvarsan; recovery. *American Journal of Ophthalmology*, April, 1913.

(7) Wicherkiewicz, B.—On the result of the action of atropine in diffuse parenchymatous inflammation of the cornea. (Einiges über den Ausfall der Atropinwirkung bei diffuser parenchymatöser Hornhautentzündung.) *Woch. f. Ther. u. Hygiene des Auges*, April 3rd, 1913.

(8) Precerutti.—On radio-active glasses; their action on the eye and on vision. (Sur les verres radioactifs; leur action sur l'oeil et sur la vision.) *La Clinique Ophtalmologique*, 10 avril, 1913.

(9) Dutoit, A.—The ætiological rôle of tuberculosis in affections of the optic nerve and retina. The curative action of tuberculin. (Le rôle étiologique de la tuberculose dans les affections du nerf optique et de la rétine. Action curatif de la tuberculine.) *La Clinique Ophtalmologique*, 10 avril, 1913.

(10) Frankenstein, J.—The glass eye tube: a contribution to treatment of the eye. (Die Augenstabtube: ein Beitrag zur Augentherapie.) *Woch. f. Ther. u. Hygiene des Auges*, 19 Juni, 1913.

(1) **Alger**, of New York City, discusses what may be done from the eye point of view to relieve and to cure migraine. He has found that the majority of his patients have benefited materially from attention to their eyes. If we remove the exciting cause, attacks cease, but the underlying nervous instability remains, and is still capable of reacting to a competent irritation. In short, Alger believes that "while the symptoms of migraine must be ascribed to angioneurotic cerebral disturbances, there are many reasons for thinking that these in turn are often dependent on eye-strain." In examining the eyes of this class of patient, Alger attaches importance to:—(1) the securing of cycloplegia; (2) the correction of even very small amounts of astigmatism; (3) the careful adjustment of the glasses; and (4) the cordial co-operation of the patient. SYDNEY STEPHENSON.

(3) **Darier**, of Paris, after very briefly reviewing the work of Rohmer and others on the subconjunctival injection of pathological serum from the thorax or peritoneum of the patient, in cases of tuberculous eye disease where such serum exists, or of serum from a blister in other cases, points out that it is very necessary to enquire whether this method gives any better results than subconjunctival injections of saline, cyanide of mercury, and so on, not to speak of the good results obtainable by the administration of anti-diphtheritic serum. Further, in any case, why obtain serum from a blister? This is a "pathological serosity" rather than a serum, and entails, perhaps, the inconvenience of repeated blistering, It is far better, in the opinion of Darier, to obtain a few cubic centimetres of blood from a vein, and so prepare a serum. Darier concludes that we must wait for further clinical facts before pronouncing an opinion upon autoserotherapy. ERNEST THOMSON.

(4) **Frank**, of Landsberg a. Warthe, records an interesting case in which pure metallic bismuth made its appearance as a brownish mass, about 3 mm. wide, in the cornea after several local applications of airol to the eye. Damp compresses and sublimate, 1 in 2,000, had been employed as well. Frank thinks that the moral pointed by the case is to avoid the simultaneous use of airol and sublimate to the eyes. SYDNEY STEPHENSON.

(5) **Claiborne**, of New York City, has obtained such good results in a case of adult gonorrhœal ophthalmia by the use of silver nitrate (2 per cent.) that for him the disease has been robbed of its chief terrors.* There was no ascertained source of infection. Indeed, the course of the disease was so mild as almost to suggest that some blunder had crept into the report of the laboratory, according to which "gonococci" were "present in large number." No culture was made. Nothing of the kind was found in the secretion from the second eye, which despite a protective appliance, became somewhat inflamed shortly after the first. Furthermore, no gonococci could be demonstrated in the eye originally affected when examined within twenty-four hours after the silver treatment had been commenced. Yet nothing is more striking than the indefinite length of time during which gonococci may persist in these cases. The silver was allowed to act on the inflamed parts for thirty seconds, and was not neutralised by normal salt solution. Bichloride lotion (1 to 3,000) was used in addition to the silver. SYDNEY STEPHENSON.

(6) In the case reported by **Calhoun**, of Atlanta, sympathetic ophthalmia came on seven days after an iridectomy operation on a slightly soft eye with occluded-excluded pupil. The exciter was immediately excised and treatment directed to the sympathiser. In spite of atropine, dionine, and, internally, sodium salicylate, mercury, potassium iodide, and hexamethylenamine, the eye became worse. Wassermann reaction was negative, but nevertheless 0·7 gram

*See THE OPHTHALMOSCOPE, 1911, p. 379.

of neo-salvarsan was given. For the following four days the sight rapidly diminished, and then improved slowly for ten weeks, and was, when the patient was dismissed, 20/40 corrected. Alterative treatment was continued after the intra-venous injection of neo-salvarsan, but the patient's tolerance of iodide, mercury, and sodium salicylate was not great. It is not definitely stated what was the cause of the original iritis, the first attack of which occurred when the patient—now a young man of 21 years—was about seventeen, and the second and third attacks when he was 20. The patient had suffered from rheumatism and tonsillitis. ERNEST THOMSON.

(7) In cases of severe interstitial keratitis, atropine, applied in the usual way, often fails to dilate the pupil. Under such circumstances **Wicherkiewicz**, of Cracow, recommends that a $\frac{1}{4}$ per cent. solution be injected daily or less frequently beneath the conjunctiva. In an alternative plan, one of the preparations of supra-renal gland is freely applied to the eye before atropine is instilled. SYDNEY STEPHENSON.

(8) The article by **Precerutti**, of Turin, is little more than a string of statements, utterly unsupported by any scientific evidence, on the healing virtues of radio-active glass when employed in the form of spectacles. S. E.

(9) The article by **Dutoit**, of Montreux, is of the nature of a review, with bibliography.

BOOK NOTICES.

Over de Accommodatie en Refractie van het Oog. Een Kort overzicht van het Wekk van Donders en ven de Vorderingen die in de laatste 50 Jaar zijn Gemaakt. By ERNEST CLARKE. Amsterdam : Scheltema and Holkema's Boekhandel. 1913.

Mr. Ernest Clarke, of London, sets forth the epoch-making work accomplished by Donders, and gives an account of the progress made in that direction since Donders' time. Mr. Clarke must be congratulated upon having hit upon a happy way of commemorating Donders' great achievements by publishing this book in the Dutch language.

Opuscula Selecta Neerlandicorum de Arte Medica. Fasciculus II. PETRI CAMPERI de Oculorum Fabrica et Morbis. Nach der Lateinischen Handschrift übersetzt. Amsterdam : F. van Rossen, 1913. English Price, 8s. 4d.

"In connection with the golden jubilee of *Nederlandsch Tijdschrift voor Geneeskunde* in 1907, the editors of this journal republished a choice selection of medical works by older and more recent Dutch authors. This publication, which, in addition to the original text, comprised a translation into one of the modern languages, appeared under the title *Opuscula selecta Neerlandicorum de arte medica*, and the first fasciculus expressed the intention of the editors to continue later on the new edition of authoritative Dutch works."

The foregoing is a translation of the opening paragraph of the preface of the volume now under consideration, the second of the series, which, unlike its predecessor, is entirely concerned with the work of one author. It is a transcription and translation (into German) on parallel pages of the manuscript (hitherto unpublished) of a text-book on eye diseases by the world-renowned Petrus Camper (1722-1789).

The history of the volume is interesting, as set out in the preface. The manuscript, composed of 336 pages, fell, at an auction sale, into the hands of

a medical student, S. Diamant, who is at present in active practice. By Herr Diamant it was sent to Prof. Straub, of Amsterdam. Straub soon found that it was not the original manuscript of Camper, but the original was discovered shortly afterwards in the Amsterdam University Library. Perusal of the manuscript showed that Camper, in the middle of the eighteenth century, had delivered an extraordinarily able (*tüchtig*) course of lectures, so much so, indeed, that had they been published even so late as the first half of the nineteenth century they would have been much used as a text-book.

The manuscript has been translated from the Latin into German by Dr. W. P. C. Zeeman, who, in the preface, calls special attention to certain points in the work of Camper.

The volume of 411 pages is a handsome one as to print and paper, and contains a portrait of the author, who holds in his right hand a kind of hook, which might perhaps be an eyelid retractor. Reproductions of a number of original sketches and drawings are scattered through the pages. We must, however, allow those who are interested in old books to examine this one for themselves. ERNEST THOMSON.

Surgery of the Eye. By ERVIN TÖRÖK and GERALD H. GROUT. London: Baillière, Tindall & Cox., 8, Henrietta Street, W.C. Pp. x and 507. 1913. Price, 18s. net.

In this well-got-up book the authors have aimed at producing a guide which shall include all operations in common use to-day, described in such a way that it shall be valuable both to the student and the practitioner interested in ophthalmology. For this reason they give, in a preliminary section (Part 1) an account of the procedures necessary for the preparation of patients, both for anæsthesia and operation, and the methods of treatment after any operative measures, which will be of great value to all practitioners. This section includes also the preparation of the surroundings and of the instruments.

In the second section the various conditions which may require operation, are severally discussed and the best forms of procedure given in detail so clearly that, at least, in the majority of instances any student will be able to follow the procedure, and, if necessary, practise it for himself without further guidance.

It is not to be expected that the operations selected for description should exactly coincide with those in common use here, but the lines of selection are generally sound, although a book which aims at including all operations in common use might perhaps name such procedures as Smith's operation for cataract, Herbert's for glaucoma, the St. Mark's Hospital operation (modified from van Millingen) for cicatricial entropion, and Frost's procedure of implanting a glass sphere in the capsule of Tenon.

In describing operations on the globe, the authors adopt the terms "American" and "European" position to indicate that in some cases the operator stands behind the head and in some in front of the patient. It is, of course, convenient to have a term which expresses this in a single word, but it may be doubted whether the term adopted is quite acceptable, inasmuch as the large majority of English operators, who presumably are European, adopt the position behind the head.

It is not very clear who first adopted the posterior position; many of the older writers make no mention of their stance, and it has to be guessed from inferences, but Guthrie, in 1834, gives an account of his method which involves standing behind the patient.

Mackenzie states that he stood in front, but that "a distinguished surgeon in London," whom he does not name, always stood behind. Soelberg Wells

assumes the position behind to be the general one, so that it is clear that even from early times the "American" position was natural to English operators.

In the section on cataract but the slightest notice is taken of prolapse of the capsule, an insidious accident which may give rise to serious disaster; and the method of opening the capsule by a Y-shaped incision seems to us dangerous, as likely to favour this mishap.

The authors very rightly draw attention to the danger of infection of instruments from touching the eyelashes, and it seems strange that they continue to recommend the wire specula rather than a pattern such as Lang's, which shields the instruments from the cilia.

There are, so far as we have noticed, very few misprints, but the authors throughout adopt the spelling "Burrow" for Burow, probably having been misled in this point by Terrien.

No references are given to any orginal papers, except the general references in the introduction to the text-books of Czermak, Terrien, and Blaskowics.

HAROLD GRIMSDALE.

CORRESPONDENCE.

While THE OPHTHALMOSCOPE will at all times welcome correspondence from its readers, the Editor does not hold himself responsible for any views expressed in this column.]

THE NEW ANTIGLAUCOMATOUS OPERATIONS.

To the Editor of THE OPHTHALMOSCOPE.

DEAR SIR,—When reading in *La Clinique Ophtalmologique* Dr. Dor's article upon the "New Antiglaucomatous operations," it appeared to me as presenting the best *résumé* of any article upon the subject which had appeared up to the time of its publication, and therefore worthy of being translated and published in the January number of *Ophthalmology* for the benefit of English-speaking readers. Notwithstanding the criticism of the reviewer of the article in the June number of THE OPHTHALMOSCOPE, page 366—(3), it does not appear, upon re-reading the article, that the ideas of Dr. Dor have been misinterpreted, unless it may be that a slight change had, of necessity, to be made in the quotation referring to Herbert's operation in which appear the words "*fil d'argent.*" This is a misquotation—as the words are not in Herbert's description of his operation in the *Transactions* of the Ophthalmological Society of the United Kingdom Vol. XXIII, 1903, to which reference is made.

As it was ostensibly a quotation from Herbert's paper, it was deemed advisable for the benefit of the readers to substitue the original description as given by him in English, which enhanced the value of the paragraph rather than made it "suffer in the translator's hands."

Whether the credit for the rectangular flap is to be attributed to Harman or to Herbert I will not undertake at this time to decide, nor does it fall within the province of the translation to criticise the opinion of the author as to the value or permanency of trephining as practised by Argyll Robertson, Blanco, or Fergus.

I am,
Very sincerely yours,
L. WEBSTER-FOX.

1636, SPRUCE STREET,
PHILADELPHIA,
June 13*th*, 1913.



SIR JONATHAN HUTCHINSON.

To the Editor of THE OPHTHALMOSCOPE.

DEAR SIR,

Having read Dr. Webster-Fox's letter I must confess to having shown a lack of discretion in obtruding a personal opinion of his translation of Dor's article in the review referred to, but I am bound to say that a re-reading of the translation along with the original does not lead me to change that opinion. I should like to say that my remarks had no reference to Dr. Webster-Fox's correction of Dor's misquotation of Herbert. I notice, however, that the revised version of the quotation is also inaccurate.

With regard to the last paragraph of the letter, Dor, so far as I can see, did not express any opinion as to the "value or permanency of trephining as practised by Argyll Robertson, Blanco, or Fergus," nor did I, but I wished to point out that it was inaccurate to describe Herbert's rectangular flap operation as if it originated with Harman, and to speak of Argyll Robertson and Blanco as having trephined the anterior chamber, and that it was unfair to Fergus and these others to describe them as "undecided precursors who have entertained the idea without rendering it practicable." No one would blame the translator for not calling attention to these mistakes, but surely it is permissible to do so in a review.

I am, yours sincerely,

11, SANDYFORD PLACE,
GLASGOW, W.,
15th July, 1913.

ARTHUR J. BALLANTYNE.

THE EXTRACTION OF CATARACT.

To the Editor of THE OPHTHALMOSCOPE.

SIR,

It may interest your readers to know that during the five years when he held the office of ophthalmic surgeon at the Middlesex Hospital, from 1876 to 1881, my father frequently lacerated the anterior capsule before extraction of cataract. He used a sharp needle and endeavoured to cut out a piece from the centre of the capsule. Mr. Treacher Collins and Sir John Bland Sutton, were, during a part of their time, dressers in the ophthalmic department, and they will, I feel sure, remember this proceeding. As my father did not publish his method, it is evident at a later period Mr. E. F. Drake-Brockman considered, quite naturally, that he had initiated this operation.

Faithfully yours,

21, HARLEY STREET,
15th July, 1913.

ANDERSON CRITCHETT.

NOTES AND ECHOES.

Deaths.

JONATHAN HUTCHINSON.

"A man of hope and forward-looking mind."

(1828—1913.)

IN common with the whole medical world, we deeply deplore the loss of Sir Jonathan Hutchinson, whose death occurred on June 23rd, 1913, and was briefly chronicled in our last issue. He passed away in his 85th year.

The full obituaries published in the general medical journals of this distinguished surgeon, render it unnecessary for us to do anything except to touch lightly upon the ophthalmic aspect of his many-sided, nay, scientifically ubiquitous, life. In the early sixties he was appointed assistant surgeon to the Royal London Ophthalmic Hospital, and from 1862 onwards, he lectured at the London Hospital on the principles and practice of surgery. In the

following year, when he became full surgeon to the London Hospital, he lectured upon medical ophthalmology in the Medical College attached to the hospital. In 1868 he became full surgeon to the Royal London Ophthalmic Hospital. His time of active service at the London Hospital ended in 1883, and he retired from the active staff of the Royal London Ophthalmic Hospital in 1878, several years before the end of his term, and he was appointed consulting surgeon to both institutions.

Sir Jonathan Hutchinson was vice-president of the Ophthalmological Society of the United Kingdom in 1880-1881. He occupied the presidential chair from 1883 to 1886, and on retiring from that position, was again elected vice-president of the Society, a post which he held from 1886 to 1889. In 1884 he delivered the Bowman Lecture of the Society, taking as his subject, "The Relation of certain Diseases of the Eye to Gout." The last communication he made to the Society dealt with the subject of "School Ophthalmia" (1894), and like so many of Hutchinson's communications, it gave rise to a lively and profitable discussion.

In many other directions Sir Jonathan Hutchinson contributed to the literature of ophthalmology. His works dealt largely with the relationship between syphilis and affections of the eyes. It is interesting to recall the fact that his first contribution, written at the age of twenty-four years (1852), was on the subject of infantile iritis, which he assigned to inherited syphilis. His immortal discovery of the dependence of interstitial keratitis upon inherited syphilis, and the diagnostic importance of the teeth, particularly of the upper permanent incisors, was published in several directions. His conclusions on malformed teeth as an indication of inherited syphilis were communicated to the Pathological Society (1857-1859). A series of extremely important papers dealing fully with inherited syphilis in relation to diseases of the eye was published at about this time in the *Ophthalmic Hospital Reports*. In 1863 he published his classic *Clinical Memoir on certain Diseases of the Eye and Ear consequent on Inherited Syphilis*, which he dedicated to William Lawrence, F.R.S., and to his surgical colleagues of the Royal London Ophthalmic Hospital. This famous book was a much extended reprint of the papers previously published in the *Ophthalmic Hospital Reports*. The principal points insisted on were that chronic interstitial keratitis was essentially an heredito-syphilitic disease, and that dental peculiarities, of a certain kind, were a trustworthy indication of inherited taint.

The following appreciation of a most remarkable man is from the pen of one specially qualified to speak, Mr. Edward Nettleship, who was for many years in close professional and personal touch with Sir Jonathan Hutchinson:

Although only a fortnight has passed since Sir Jonathan Hutchinson died, I find it difficult to say anything about him that has not already been said, and said in more fitting words than I can command, by others. But perhaps the best tribute one can hope to pay in such a case is by writing as simply as may be what comes to the mind without thinking of novelty either in substance or form.

I first knew Hutchinson in my late student days, when he was already in the foremost rank of the clinical teachers in the kingdom and some years after he had published, in 1863, his great memoir upon the later differential phenomena of congenital syphilis which was the result of several years' labour at the Moorfields and various other hospitals. I remember my first sight of him quite well. In the late summer or autumn of 1868 I entered for the surgical practice at the London Hospital and at my first visit found him giving one of his informal clinical demonstrations, largely by question and answer, in the Receiving Room, the subject being a patient with rodent ulcer. I was fortunate enough to

be made one of his in-patient dressers, and when that work was over he made me one of his assistants, junior to Mr. Waren Tay, both at Moorfields and the Blackfriars Skin Hospital, and was also privileged to help him in various ways in his private work. He was constantly at work, never in a hurry, and seemingly never tired, but resourceful and endowed with such a variety of gifts and such a capacity for storing and remembering his experiences that he found his recreation more in passing from one mental task to another than in the entire change that most people find necessary on a holiday. A voracious, rapid, varied and retentive reader, he was also, like so many great surgeons and physicians, a naturalist, and carried on field work in almost every branch when at his house at Haslemere from the sixties onwards ; but I think that he needed fresh air and physical excercise for their own sake less than many men do, and certainly when I knew him best in London, he could sit with comfort for hours with closed windows, even in summer.

Few, whether students in the ordinary sense or men of fuller experience, could see much of Hutchinson without feeling the attraction of his great power and balanced enthusiasm. It was perhaps the quantity, fulness and comprehensiveness of his information, coupled with his abiding sense that it was his duty to teach what he was continuously learning, that gave to his personality an almost fearsome charm. If his fertile imagination sometimes led him in later life to see similarities or relationships that were not apparent to others, the same gift cautiously used in earlier years, had often led him to suggest luminous comparisons or generalisations in regard to conditions that seemed quite dissimilar. Hutchinson could not be called an eloquent or very attractive speaker, and more often than not preferred to read his communications to the societies ; but he was able to make a clearly expressed, agreeable and telling speech when occasion arose. He wrote rapidly in a clear, bold, even hand, the letters well-formed and seldom slurred ; his ideas too flowed steadily in ordered sequence, so that he would either write or dictate an article or a paper with scarcely an erasure or hitch.

Like all great teachers, Hutchinson remained a student and seeker after knowledge to the end of his days. Like all great medical practitioners he was much more than a doctor. Genial, always accessible, very hospitable in a quiet way, he knew and understood most sides of human nature and was tolerant of most things, even such as appealed least to his sympathy and understanding. His ancestors for several generations were members of the Society of Friends and he as well as his numerous brothers and sisters were brought up, not only as strict Quakers, but total abstainers from alcohol. He himself was, I believe, but little bound by the tenets of any sect after the middle period of his life, although the habits of a long life time were based and moulded largely on the traditions and routine in which he had been trained before he left his parental roof.

July 8th, 1913. E. NETTLESHIP.

Francis Gotch, F.R.S., Waynflete Professor of Physiology in the University of Oxford and Fellow of Magdalene College, Oxford, died on July 15th, 1913, at the age of 60 years. His work upon the retinal functions is familiar to every ophthalmic surgeon. He served upon the Departmental Committee of the Board of Trade upon tests for vision in the Mercantile Marine.

We regret profoundly to announce the death of Ernest Motais, professor of clinical ophthalmology in the medical school of Angers, France, at the age of 67 years. Motais's name is familiar, not alone for his anatomical researches, but also by reason of the operation for ptosis which goes by his name. When he attended a meeting of the Oxford Ophthalmological Congress some years

ago, he made many friends amongst his British *confrères*, who had the privilege of seeing him perform his own operation. Motais was the founder and the editor of *L'Ophtalmologie Provinciale*. Death occurred on June 30th, 1913, after a very short illness.

The death is announced, at the age of 73 years, of Dr. George H. Powers, once professor of ophthalmology in the University of California, San Francisco.

Dr. David Coggin, of Salem, Mass., for many years attached to the Eye and Ear Department of the Salem Hospital, has succumbed at the age of 70 years.

Dr. R. P. White, of Fort Wayne, Ind., well-known as the oculist to the Pennsylvania Railroad, is dead.

* * * *

"The Prescriber."

The Prescriber, a monthly journal dealing with therapeutics and treatment, published at 137, George Street, Edinburgh, devotes its June issue to the subject of ophthalmic therapeutics. In addition to a couple of brief original articles, it contains a good many abstracts from recent literature dealing with the subject.

* * * *

The Paris Hospitals.

THE following list represents the distribution for the year 1913-1914 of the ophthalmic surgeons and assistants attached to the chief Paris Hospitals:—

Hôtel Dieu.—de Lapersonne; Coutela; Cerise; Chenet; Velter; Monbrun; Bollack; Fauconnier; Royole; Hervouet; G. Jacquemin; Nazim; and Mlles. Brailowsky and Friedmann.

Hôpital Saint-Antoine.—Dupuy-Dutemps; Joseph; Sebald; Pierrot.

Hôpital Cochin Annexe.—Cantonnet; Deschamps; Lignac.

Hôpital Beaujon.—Terrien; Selter; Gauchon; Hiblot.

Hôpital Lariboisière.—V. Morax; Landrieu; F. Rousseau; Wiart; Bergès; de Carvalho; Vigouroux: Mouriès; Bortnowiki.

Hôpital Laennec.—Rochon-Duvigneaud; Faure-Beaulieu; Ducamp; P. Giraud; Salinières; Jouisse.

Hôpital des Enfants-Malades.—Poulard; Offret; Dantrelle; Cousin; Mallet; Beau; Charlet; and Mlle. Badilquès.

* * * *

"The Ophthalmic Record."

DR. THOMAS H. SHASTED has been appointed editorial secretary of *The Ophthalmic Record* (Chicago), in place of Dr. Woodruffe, resigned.

* * * *

Ehrlich as "Hoflieferant."

IN the July issue of THE OPHTHALMOSCOPE (p. 452) we published a notice taken from *l'Actualité Médicale*, of Paris, concerning a decoration recently bestowed upon the illustrious discoverer of "606" The paragraph in question had already appeared in the pages of a certain English medical journal, which shall be nameless. Objection has been taken to the paragraph, which has been construed as reflecting upon Professor Ehrlich. The honorary general secretary of the Seventeenth International Congress of Medicine, Dr. W. P. Herringham, has voiced the objection in an entirely courteous letter to the medical press. We must emphatically dissociate ourselves from any intention of giving offence, and under the circumstances, we regret having given publicity to the paragraph.

THE

OPHTHALMOSCOPE.

A MONTHLY REVIEW OF CURRENT OPHTHALMOLOGY.

VOL. XI.—No. 9.] *SEPTEMBER 1, 1913.* [TWO SHILLINGS.

CONTENTS.

Original Communications.— PAGE

1. Robert W. Doyne, M.A., F.R.C.S.—On the Present Position of Ophthalmology ... 508
2. R. A. Reeve, M.D.—The Present Position of Ophthalmology in Canada ... 513
3. C. O. Hawthorne, M.D. — The Relation of Ophthalmology to General Medicine ... 513
4. Emile de Grósz, M.D.—The Present Position of Ophthalmology in Hungary ... 517
5. F. R. Cross, M.B., F.R.C.S.—Discussion on the Present Position of Ophthalmology ... 518
6. Sydney Stephenson, D.O.—On the Present Position of Ophthalmology in Great Britain ... 520
7. Lieut.-Col. R. H. Elliot, I.M.S.—Trephining in Glaucoma, acute and chronic: Miscellanea ... 523
8. C. G. Russ Wood, F.R.C.S.—On Pseudoneuritis... 530

Pathological and Clinical Memoranda.—

1. E. Treacher Collins, F.R.C.S.—A Pathological Report upon a Case of Doyne's Choroiditis ("Honeycomb" or "Family" Choroiditis) ... 537
2. A. F. MacCallan, M.D., F.R.C.S.—An Operation for Ectropion of the Lower Lid ... 538
3. G. Lindsay Johnson, F.R.C.S.—Notes on the New Operative Treatment of Glaucoma ... 539

Novelties.—

A Hand Perimeter ... 540

Current Literature.—

I. The Noguchi and the Wassermann Reactions ... 541
II. Infra-Nuclear Paralysis ... 542
III. Fluorescence of the Crystalline Lens ... 544
IV. Eclipse-Blindness ... 545
V. Word-Blindness ... 546
VI. Arcus Juvenilis and Arcus Senilis ... 547
VII. Parinaud's Conjunctivitis ... 548
VIII. Cyclic Affections of the Third Nerve ... 549
IX. Buphthalmos with Good Sight ... 550
X. Congenital Anterior Staphyloma ... 551
XI. Disease of the Pituitary Body ... 552
XII. Cataract ... 555
XIII. Colour Blindness ... 560
XIV. Acne Rosacea ... 560
XV. Remedies (eighth notice) ... 561

Book Notices ... 566

Correspondence... 569

Notes and Echoes ... 570

The Ophthalmoscope Diary... 574

ORIGINAL COMMUNICATIONS.

ON THE PRESENT POSITION OF OPHTHALMOLOGY.*

BY

ROBERT W. DOYNE, M.A., F.R.C.S.

MASTER OF THE OXFORD OPHTHALMOLOGICAL CONGRESS.

IN bringing before you this subject for discussion, I fear I shall not be able to enter into the details of it as thoroughly as I could wish, but I am compelled to limit myself to a mere sketch, leaving it to be amplified by others who will speak on the subject. When I first came in touch with the subject some thirty-seven years ago, the knowledge concerning it, and the practice connected with it, were widely different from what they are to-day, although the actual practice bears a strong resemblance, but differs in degrees. This was carried on, as it is to-day, by duly qualified medical men and others who had not complied with the Medical Act, chiefly jewellers and opticians. Practice was divided, speaking generally, into two portions, which were held to be more or less distinct—the treatment of manifest disease, on the one hand, and the fitting of spectacles, on the other. The two branches were to some extent treated as being quite distinct. The former was mainly dealt with by the orthodox medical practitioner, the latter chiefly by jewellers and opticians, who kept a supply of glasses to suit all sights, the onus of selection being left to the customer, as, in effect, the patient became. The teaching for the medical man was of a most perfunctory kind; indeed, facilities can hardly be said to exist; while the unqualified optician picked up what information he could from actual experience. In most general hospitals there were only the most elementary facilities, if such they may be called, for the practice and study of the subject. Dark rooms and test types were, on the whole, the exception. At this time the ophthalmoscope was just coming into limited use, and the indirect method was demonstrated to the curious by men who themselves were often sadly in need of practical experience.

The total amount of knowledge that existed as to the condition of the fundus was decidedly limited, and was of very little value in the diagnosis of general medical troubles. Indeed, I doubt if I go too far in saying that it was more useless than valuable, for, in my own experience, I have certainly come across cases in which the ophthalmoscopic examination had been responsible for allowing patients to spend their lives as invalids for no other reason than that they had opaque nerve fibres. The minds of many of the most careful physicians were misled by conditions which were recognised as hyperæmia of the disc, blurred margins, pallor, etc. By this I do not mean to cast any slur upon the trustworthiness of the examination of the disc, but only wish to point out that unusual conditions were accepted as definite evidence of disease when none such existed. It may be truly said, of course, that apparent appearances of disease exist at the present time and lead treatment astray.

After the period to which I allude, special departments and hospitals began to grow all over the country, and at the present time England may be considered as well equipped for the diagnosis and treatment of eye disease. Various devices for the investigation of disease have been developed, but there has been no development greater than that in the treatment of con-

*The opening address in a discussion held at the Oxford Ophthalmological Congress on July 18th, 1913.

ditions of refractive error, and in this branch the profession has to compete with the rivalry of the optician. In the early times of which I spoke just now, this was very little understood. Indeed, in many quarters, there was a strong feeling against glasses in any form. I can well remember in my student days an extremely hypermetropic charge nurse, who could only manage to do her work by wearing strong *plus* glasses. She was reproved by one of the staff for wearing them, and they were actually confiscated. She was obliged to get another pair of glasses to wear "on the sly," when it was necessary.

This state of affairs has completely changed, and nowadays the ametropic patient is provided with glasses of all sorts and kinds, whether he is suffering from the effects of errors or not. To such an extreme degree are these views held by some, that it amounts to considering that the incidence of tuberculosis or appendicitis can be prevented by the provision of glasses. Of course, there can be no question that in many cases the wearing of glasses is necessary, and that much suffering is relieved by wearing the proper correction for the refractive error. In this direction opticians have advanced to a very considerable degree, but cases are quite common in which glasses are altered every few months, or even oftener, with the excuse that the astigmatism or other refractive error has been cured; nor, in my own experience, has this practice been entirely limited to opticians. This fitting of glasses for therapeutic purposes has been claimed as a matter for the medical practitioner, and there is no doubt that great inroads have been made upon this special work by the unqualified man. This has for some time been a burning question in professional circles. Its merits have been much discussed, and it is a difficult matter to decide, but the aspects of the case must be fairly considered. There is no doubt that glasses are quite often correctly estimated by the skilled optician. It is also true that the medical man, unless he has especially studied the subject, cannot correctly fit glasses merely by reason of his qualification. From time to time measures to prevent the optician from correcting errors of refraction are discussed. On the other hand, it is true that the medical profession takes up a "dog in the manger" attitude and they wish to make it a case of "we can't and you shan't." It cannot be denied that years before the medical profession actively took up the question, jewellers and opticians had carried on the practice of fitting spectacles, nor that there would be at least an appearance of hardship upon a capable body of men, who have developed a profession, apart from the question whether it be entirely for the benefit of the general public or not. Of course the *crux* of the question is whether this development is for the good of the public. However hardly it bears upon the medical profession, they can scarcely demand the monopoly on this ground alone, and the question requires consideration from a very broad point of view.

The proper elucidation of the question on the part of the medical profession seemed to me the production of the better man. This, of course, would not satisfy all requirements of the question, because the public are easily led by advertisements and the unqualified man relies upon advertisement, while doctors are unable to do so. However, it appeared to be a dignified and scientific way of dealing with the question, and for this purpose I brought before the University of Oxford the desirability of providing a diploma in ophthalmology for those who were qualified to take it. Examinations for the diploma have since been held. They have been stiff, and those who have passed them may certainly be acknowledged as men who have a thorough knowledge of their special subject. There have been difficulties

against which the University has had to struggle, as, for instance, the unpopularity of the scheme, speaking generally, with London men, many of whom have done their best to spoil it. This attitude is unworthy of the profession, and I will explain in greater detail why this is so.

I think it cannot be questioned that the greater majority of surgeons who are practising ophthalmology and holding appointments, have the very sketchiest knowledge of the scientific basis of their speciality. I do not suppose that 5 per cent. could claim to be in any sense pathologists, nor is there perhaps a greater number of bacteriologists, although on the subject of ophthalmiæ the text-books are being re-written, and the microscope is in this respect as important as the ophthalmoscope is for intra-ocular disease. Of course, many who have not the scientific groundwork, which I advocate as desirable, are very good clinical men, and become successful practitioners ; but I expect it will not be denied that, with a deeper basis, they would become even better men. Nowadays, although it is becoming less the case than in the past, the evolution of an ophthalmic surgeon is largely a matter of chance. A vacancy occurs, and it his turn, and so he fills the post more or less successfully. As regards the question of refraction, as I said just now, there have been great developments, but it has developed too much, I think, into a money-making scheme on empirical lines, rather than on those of scientific treatment. I feel I cannot ridicule too strongly the claims of men who deal with refraction by changing glasses every two or three months, and claim in the end to have cured astigmatism or prevented tuberculosis. In fact, the great mistake in dealing with errors of refraction is to treat it as a commercial process. It is quite a usual thing for a patient, who consults a fresh oculist for any reason whatever, to be given new glasses on the grounds that the old ones were unsuitable. Herein is a matter of great difference between qualified surgeons and opticians, for whereas the latter claim, although not always successfully, to correct the mathematical error existing, the qualified man will attempt rather to give glasses as modified by the general conditions of physique or health. A patient between 40 or 50 seeks glasses, generally not because he wants to see better, but because he wants to see as well as he did ten years previously for reading books and papers. He does not want a complicated glass, whereby an error of half a diopter of astigmatism, according to rule, is corrected. Very frequently corrections of this kind have a disturbing rather than a calming effect, and are not nearly so well tolerated as a spherical glass, which leaves uncorrected a small error, to which the patient has been accustomed all his life, and which may be found in the vast majority of people. Yet, such persons can be, and very often are, frightened into wearing a constant correction, as well as a special one for near work, glasses to which they eventually become accustomed and find a difficulty in doing without. Consequently, they are placed under a disability in many respects, which undoubtedly results from the permanent wearing of glasses. I do not wish for a moment to detract from the enormous value that does result from the wearing of glasses in high degrees of error or dissimilarity. There can be no doubt that the whole course of some patients' lives in the matter of actual pain and discomfort is favourably altered. I refer more particularly to detailed mathematical corrections rather than to ordinary reading glasses.

However, I am rather wandering away from the subject in hand. I do not deny that the correction of errors of refraction offers grounds for wide differences of opinion, which may be quite honestly held, and which are not a mere question of money-making. What I particularly desire to emphasize as unworthy of the honest practitioner is that he should imply and arrogate to

himself great merit in fitting glasses, when the prescription he gives varies only in about one quarter or one half a diopter of refraction from the old one. But I do not wish to encourage or to uphold a slovenly way of doing work, for even if simple spheres of a reading strength are given, the surgeon ought to investigate to the fullest extent any deviation from ametropia, even although he does not correct it.

Nowadays the work of the ophthalmic surgeon has become an item in the routine entailed by diagnosis, and he must be prepared to bear his share in this. An allusion here to his relations to his fellow practitioners may not be out of place. I remember well, when I was a youngster at the outset of my career as an ophthalmic surgeon, that I met in consultation one of the leading surgeons of the day. At the end of the case he agreed with me, and also with my line of treatment, but said that they would expect us to do something, and suggested changing my prescription of a mixture by putting half the ingredients into a pill and leaving the remainder in the mixture. I recollect the hot flush of indignation I felt, which I had not the moral courage to express in words. Of course, when the patient recovered, all the credit was given to the intervention of the surgeon. Therefore, I especially caution you younger men against allowing yourselves the influence of the *suggestio falsi* or the *suppressio veri*, which is so easy to obtain unfairly. It is an effect produced by mere gesture, look, or tone, and is, indeed, one that a patient is too often ready to grant and to bring about himself. The temptation, therefore, may be very great for the surgeon to receive what is offered him, and I fear it is too often encouraged, both by the surgeon and the patient. But, and I am again addressing the younger men, you should remember that it gives rise to a great deal of bad feeling, which exists in this age of competition, and is a poisonous weapon which in the same way may be used against you from the same source. I could narrate a great many specific instances in my own experience, but I am not out to-day to give vent to or to create bitterness. There is only one thing I would say, perhaps in bitter recollection of the past, but which I only intend as a warning, namely, that, when I have in the spirit of truest honesty and fairness sent a patient on a roving commission to get another opinion from a surgeon of his own selection, in a case where there was some doubt as to the course of treatment, I have never, except in a very few cases, seen the patient again. Certainly, what is borne in upon me is that the policy of "grab," especially in London, is far too much followed. Of course, there are cases in which the patient desires to change his medical attendant, and the wish for some new thing is often uppermost with the patient, so there must be due allowance for discount in this sort of general remark I am making. And I must not forget to recall the conspicuously brilliant exceptions to this rule, among whom I may particularly mention the late Mr. W. I. Hancock, whose lamented death deprived the profession of a brilliant surgeon.

I have mentioned the action of Oxford as a means of raising the standard of ophthalmology, and I have alluded to the manner in which this has, at present, been in a large measure defeated by the attitude of other men, but also I should suggest that this has been added to by the opposition of Oxford itself and the apathy of its supporters. I fancy it will be hardly credited that no provision whatever was made by the University, except for one year, for the course of instruction on which it insisted. The responsibility and expense of the adequacy of the course in ophthalmology were left on the shoulders of the Reader in Ophthalmology, who has actually no special statutory responsibility whatsoever in connection with the duties required for this course. I do not hesitate to say that Oxford had special opportunities,

which will never occur again, for taking a leading position in the world of ophthalmology. The Oxford Ophthalmological Congress had been evolved out of the annual postgraduate course in ophthalmology, and I think you will agree with me that it has been supported with considerable enthusiasm. The criticism may be offered, that London would be a better meeting place for the Congress. My reply is that London is so satisfied with itself and so split up into opposing camps that no good thing can come out of it, until it has recognised that its pre-eminence is mainly due to its geographical position and not merely to the scientific merit of its units. At the time of which I spoke of as Oxford's chance, I hoped that Oxford might be accepted as common ground, on which opposing factions might meet, and, having the prestige of an ancient name, might be acceptable as being near London and offering great facilities for the purpose. At this time the Ophthalmological Society of Great Britain has been almost destroyed by the powerful influence of a small *clique*, and the self-satisfaction thereof, and it had been manœuvred out of its library.

This part of my Address is no doubt highly contentious and will be regarded as absolutely inaccurate by some, but I am content to leave the decision to the innermost thoughts of the thinking men, who may even be among those whom I regard as the culprits.

This Congress, as I suggested last year, has serious times before it. It must not be forgotten that at its inception every precaution possible was taken not to interfere with any existing society or association, and the programme of its work was carefully arranged to that end. The new Congress of the Ophthalmological Society must, to a great extent, cover the same ground. Consequently, there must necessarily be a good deal of competition, which will interfere with the success of both Congresses, and eventually one or both of them must suffer. I do not complain of this action of the Ophthalmological Society, for I had several courteous communications with the organisers on the subject. The new Ophthalmological Congress seems to me to have been born moribund, but I cannot prophesy to what pitch succeeding meetings of the Congress will arrive, nor, on the other hand, can I look forward with complete confidence to the future Oxford Congresses. The effort (which has been almost wholly borne this year by our honorary secretary, Mr. Sydney Stephenson) is enormously great, and cannot continue to be undertaken, with strangely little outside help, by the same individuals. I commend this subject to you who have valued the meetings for your very earnest consideration. I myself believe that concerted action is likely to be of more advantage to British ophthalmology, which, after all, is the main question. The fate of the Ophthalmological Society of the United Kingdom must ever be borne in mind. Any national attempt must not again be thwarted by overwhelming importance being arrogated by a very large and important section of the ophthalmic world to the detriment of other important sections, which may not be able to muster the same numerical superiority to support their views.

THE PRESENT POSITION OF OPHTHALMOLOGY IN CANADA.*

BY

R. A. REEVE, M.D.,

TORONTO, CANADA.

FOR a good many years ophthalmology has had a recognised place in the curriculum of several of the leading Universities in Canada; and didactic and clinical instruction has been regularly given in this branch (as also in oto-laryngology). For a number of years, examinations have been compulsory, and the results have been counted in summing up the total marks. At least, in Toronto and McGill, practical instruction has been given in clinical classes in the fourth and fifth years of the course. All the graduates, therefore, have some practical knowledge of ophthalmology, and they have been led to realize the importance of its bearing upon their future work as general practitioners.

Education in medicine cannot be regarded as at all adequate which does not include within its scope a fair training in ophthalmology (and oto-laryngology).

The proper study of the eye has been hindered for years by the false view that this meant becoming a specialist. This current idea has put a premium, too, upon the unfounded assumption that optometry, so-called, was not a part of the practice of medicine. That the eye is an organ of the body is a truism which we can never afford to ignore. Herein the wisdom of the men who founded and kept alive the Ophthalmological Society of the United Kingdom cannot be gainsaid, in which for many years the internist, the neurologist, and the ophthalmic surgeon worked side by side and manifestly to the advantage of each. In view of the facilities for instruction in the special branches in the medical schools of our country, shortly to be augmented at various new university centres, there is no valid reason for the incorporation into a profession in Canada of those who merely deal with the eye as an optical instrument, and that under real handicaps which must abide. Opticians, it is true, were here before us, and they will continue to be, because the people will have them. We willingly acknowledge that they have improved, as other standards have risen, but they should remain opticians, not doctors of optics.

THE RELATION OF OPHTHALMOLOGY TO GENERAL MEDICINE.*

BY

C. O. HAWTHORNE, M.D.,

PHYSICIAN TO THE CENTRAL LONDON OPHTHALMIC HOSPITAL, LONDON, ENGLAND.

MY qualification to take part in this discussion is but a partial and restricted one, as I approach the question, provided, not with the equipment of the ophthalmic surgeon, but merely with the more moderate interest of the physician. Indeed, it has occurred to me that in the circumstances it may be well for me to bespeak the consideration of the Congress by reminding

* A Contribution to the discussion at the Oxford Ophthalmological Congress, July 18th, 1913.

members that, according to the Book of Ecclesiasticus, it is our duty to "Give place to the physician," for the good and sufficient, though possibly surprising, reason, that, according to the writer, "the Lord created him." Whether members are or are not disposed to pay heed to this exhortation I, of course, cannot say. In either event, I propose to submit that it falls within the four corners of to-day's discussion to enquire whether the present position of ophthalmology in relation to general medicine is or is not a satisfactory one; and if not satisfactory, to consider how the existing state of matters may be remedied.

As related to this question there may be stated three propositions, on each of which we shall, I think, find ourselves in substantial agreement. The first of these is that many of the pathological changes which occur in the fundus oculi, and to a less extent, perhaps, in other parts of the eyeball, are mainly important, not because they are signs of local disorder, but because they are evidences either of some general constitutional disturbance or of more or less widespread visceral disease. Secondly, we shall agree that these changes are all the more important seeing that not infrequently they are the first available clinical evidences of the diseases to which they respectively belong. And thirdly, even when such changes are not early events, their development during the progress of an illness of obscure or uncertain nature may either indicate the direction in which a complete diagnosis is to be sought, or may afford valuable confirmation of a conclusion suggested by other facts.

To put the position still more briefly, we shall agree that in many general and visceral diseases examination of the fundus oculi may either facilitate an early diagnosis, or provide the interpretation of obscure symptoms, or confirm evidences obtained by other methods of investigation. This is the contribution which ophthalmology in one of its departments is capable of offering to general medicine, and my submission now is that in this respect the present position of ophthalmology is a highly unsatisfactory one; and it is unsatisfactory because the contribution I have just defined either is not paid at all, or is paid only in part. To recite to an Ophthalmological Congress proofs of the accuracy of this statement, can hardly be necessary. I am content to say that if not a daily experience in medical practice, it is at least a frequent experience, to find that even in complicated and difficult cases no thought has been given to the possibility that an examination of the fundus oculi might well be able to yield important diagnostic results. And the explanation of this attitude, I suggest, is the view—unfortunately widely adopted—which regards the pathological disturbances of the eyeball as shut up in a special department of practice, separate, isolated, and detached from the general scope and application of medical knowledge. It is not unfair to say that in at least some departments of ophthalmology there is given up to a party what is meant for mankind.

Now if we agree that certain forms of structural change within the eyeball are of great importance in the diagnosis of many general and visceral diseases; that in not a few individual instances this source of information is not laid under tribute; and that the cause of this defect or lacuna is the restriction of the methods of ophthalmological examination within a comparatively narrow circle—we must surely agree to proceed to the inevitable conclusion that if the position of ophthalmology in this respect is to become satisfactory, such restriction or barrier must be broken down. As opposed to it, there must be announced and illustated the doctrine that, in every case, the routine clinical examination of the patient demands an inspection of the fundus and other parts of the eyeball, just as much as it demands the use of the stethoscope and the application of chemical tests to the urine.

But if this doctrine is to take root and flourish in the profession it is not sufficient to preach it to dull and crabbed middle age; rather it must be implanted in the receptive minds of the rising generation, whose habits of thought and practice are not yet fixed. And it must be enforced by example as well as by precept. The student, during his period of training, must see the physician in the wards and the assistant physician in the out-patient department making an ophthalmoscopic examination as much a matter of routine practice as are auscultation of the cardiac sounds and estimation of the tendon-jerks. Alike by the practice and the precepts of his teachers, the student must be protected from the unhappy delusion that to make ophthalmoscopic examination effective it is necessary to invoke the apparatus of a dark room, the application of mydriatic drugs, and the assistance of a colleague engaged in the fascinating and engrossing practice of ophthalmic surgery. The ophthalmoscope in clinical medicine ought to be, in short, not a rare and unusual experience, but a repeated and routine procedure.

My first suggestion, therefore, is, that to render satisfactory the position of ophthalmology in relation to general medicine, it is essential that all medical examinations include the use of the ophthalmoscope, and that the training of the medical student be conducted in harmony with this sound and necessary doctrine. To examine only diseased hearts, is, everyone recognises, no fit preparation for clinical cardiology; to examine only diseased eyes, is, similarly, no fit preparation for clinical ophthalmology.

The second consideration which I wish to advance, is almost a necessary consequence of the proposal I have just made. It is that in ophthalmology there is a considerable department where the interest and importance are not surgical but medical, and that in this department the methods of the physician, in reference both to diagnosis and treatment, are an essential condition. An ocular palsy, a hemianopsia, are just as much examples of nervous diseases as are, say, cases of wrist drop, or of hemianæsthesia, and each demands with equal voice a complete clinical investigation of the state of the nervous system; retinal hæmorrhages, again, establish the same claim for enquiry as do attacks of epistaxis or of purpura; an embolus in the retinal artery is a clinical parallel to an embolus in the middle cerebral, or indeed, in any other artery; and retinitis is as frequently part and parcel of a general constitutional state as are pleuritis and pericarditis. Any arrangement therefore which removes these local ocular conditions from the clinical groups to which they naturally belong is artificial and unreal: it puts cases in which such conditions occur out of their natural relations and true perspective.

Such an arrangement has also, I think, certain unfortunate practical consequences. In the first place it opposes what may be called wholeness of knowledge. To take a rough example, physicians are apt to grow up with the belief that retinal changes in kidney disease and in diabetes are almost invariably exceptional and postponed events, while to the ophthalmic surgeon such changes seem the common and early expression of the diseases which produce them. In each instance knowledge is partial and incomplete because it is collected in a field of observation artificially restricted and confined. If it is reasonable to break up kidney diseases into two groups—one unaccompanied by retinal changes and appropriately cared for by the physician, the other including retinal changes and requiring, therefore, the ministry of the ophthalmic surgeon—it is equally reasonable to say that while disseminate sclerosis without nystagmus is for general medicine, the same disease with nystagmus claims the attention of ophthalmic surgery, or that whereas in enteric fever unaccompanied by rose spots, the physician may suffice, cases in which there is a skin eruption demand the direction of a dermatologist.

In the second place, cases such as those with which I am now concerned put, in the ophthalmic clinic, an unfair burden on the ophthalmic surgeon. Doubtless there are exceptional individuals who, as Lord Bacon, may take all knowledge for their province, but, to come down to more frequent levels, it is as unreasonable to expect the ordinary ophthalmic surgeon to be in a position to appreciate the finer clinical disturbances of the nervous system, or the records of the sphygmomanometer and the sphygmograph, as it would be to expect the ordinary physician to be an expert in the art of refraction or in the performance of delicate intra-ocular surgical operations.

Thirdly, it may be gently questioned whether the retention, in the ophthalmic clinic, of cases of nervous, renal, vascular, and constitutional disease, does, as a fact and in practice, make for efficiency of treatment. To name, in a case of ocular palsy, the paralysed nerve or muscle, and to order a series of doses of potassium iodide, is neither scientific investigation nor rational therapeutics; nor does a weekly or fortnightly inspection of the fundus oculi, even when supplemented by the prescription of a stock mixture, seem to be an adequate scheme of treatment for a case of chronic interstitial nephritis. Activities of this order are certainly not medicine: I would fain hope that neither are they ophthalmology. All this is not to say that a practitioner who cultivates ophthalmic surgery ought to be debarred from treating cases of constitutional and visceral disease. On the contrary, he enjoys, as does every member of the profession, the right to treat what cases he will, provided only that he qualifies himself for the duty (and here he himself must be the judge) and accepts full responsibility for his directions. If any man likes to practise both general medicine and ophthalmic surgery there is no one to say him nay. But let it be clearly recognised that, when treating cases of nephritis, glycosuria, chlorosis, tabes dorsalis, disseminate sclerosis, facial paralysis, exophthalmic goitre, myxœdema, cardiac disease, &c., he is certainly not engaged in the service of ophthalmic surgery. Quite possibly he may be a most excellent physician, and all that can be asked from him is that, by using the necessary methods and apparatus, he shall cultivate assiduously the special opportunities he enjoys, and that the liberality of his activities shall not be concealed under a restrictive title.

In the last place, I wish to suggest that cases of intra-ocular disturbance, dependent on general disease, offer an attractive opportunity for clinical investigation, and this opportunity under existing arrangements is, I submit, largely neglected. These cases lie, as it were, on the borderland between ophthalmology and general medicine, and it is on the borderlands and frontiers of knowledge that enquiry and investigation are particularly fruitful. At present this chance for the increase of knowledge falls, so to speak, between two stools. The surgeon naturally concentrates his attention on the local changes and is but little engaged with the more obscure evidences of the general clinical state on which these changes depend, while the physician, if he sees such cases at all, sees them only when some gross evidence of constitutional disturbance has appeared, and when, even if he is in a position to appreciate the intra-ocular disease, this has become relatively unimportant. For fruitful and serviceable observation there must be continuity of opportunity and of interest, and it is the absence of this at the present day which helps to make unsatisfactory the present position of medical ophthalmology.

In summary, my two proposals are:

(1) That the routine investigation of all cases in the medical department of practice ought to include an examination of the fundus and other parts of the eyeball; and (2) that all cases of intra-ocular change dependent on

general or visceral disease, and incapable of relief by surgical treatment, ought to be continuously observed and treated by the methods of the physician, which, in practice, would mean either that such cases should be referred from the ophthalmic to the medical clinic, or that, in connection with the ophthalmic clinic, a special department for continuous medical observation and treatment should be established.

I submit these suggestions to the Congress with great respect. At the same time, I desire to record an emphatic opinion that only by the adoption of some such proposals can there be effectively secured the full measure of the tribute of service which ophthalmology is capable of rendering to scientific medicine and to the progress of the healing art.

THE PRESENT POSITION OF OPHTHALMOLOGY IN HUNGARY.*

BY

EMILE DE GRÓSZ, M.D.,

BUDAPEST, HUNGARY.

IN Hungary ophthalmology has had an eventful and significant past. It was first taught separately at our University about the end of the XVIIIth century, the first lecturer on the subject being Joseph Plenck. A little later, before the century had run its course, a physician of the court of Louis XVI of France, named William Le Febure, Baron de St. Idelfont, came and settled in Hungary, and, probably as a private professor, delivered public lectures on eye diseases in our capital city.

In 1801 the first eye-hospital was founded in Hungary—at Budapest—with two rooms and six beds ; and in 1816 an independent chair of ophthalmology was created. Beer, of Vienna, not being made ordinary professor until 1818, was up to that time employed as professor extraordinary ; the oldest chair of ophthalmology being that at Budapest, which is at the present day filled—unworthily—by myself.

In 1867 the clinic was given twenty-four beds, the number being, in 1884, raised to fifty-three ; while a new clinical hospital was built in 1908 with eighty-one beds. A description of this edifice was published about that time in THE OPHTHALMOSCOPE through the courtesy of the editor of that periodical.

The rooms of the hospital bear the names of the representative men of ophthalmological science ; among them Bowman and Mackenzie, in order to keep permanently in the minds of the students the unfading glory of those two great English *savants* among others who have also added lustre to our science.

The number of cases treated has considerably increased during the last few years. In 1912 there were 17,500 new patients registered of whom 1,300 were received into the clinic, 45,000 treatments were given and 1,500 important operations performed in the period named.

The number of students enrolled was 350. Four assistants and four salaried practitioners helped to deal with this great traffic.

The permanent auxiliary staff of the clinic comprises two lady-clerks, one laboratory assistant, one head nurse, fourteen nurses, eight maid-servants, two cleaners, one mechanic, two stokers, one porter, and three men-servants.

In the syllabus of our University, ophthalmology was in 1806 placed in the

---

* Contribution to the discussion at the Oxford Ophthalmological Congress on July 18th, 1913.

third year of the course of medicine and in the second of the course of surgery. The regulation of 1875-76 laid it down that ophthalmology should be taught during a semester at the rate of ten hours a week, and that it should form one of the subjects in the second examination for the doctor's degree. At length, in the provisions of the regulation of 1901, the instruction is to last for two whole semesters, always at the rate of ten hours a week, the students being interrogated on ophthalmology in the course of the third examination.

Since 1905 the instruction has presented a practical as well as a theoretical character. Every day from 10 to 11 a.m. the students are present at the prescribed courses, which follow the presentation of the patients until noon. The courses form a systematic and complete statement of ophthalmology in all its branches, and the number of patients presented amounts to about a thousand a year. Moreover, in groups of ten, a different group each week, the students are present in turn in the morning (8 to 9 a.m.) at the operations and in the afternoon (5 to 6 p.m.) they visit the patients. They also draw up reports of the clinical observations. The groups are not more numerous, in order that each student may be able to follow the details of the operations and the findings at the visits.

Besides the professional courses, three private *docents* hold free lectures at the clinic: on the pathology of the eye, the diagnosis of affections of the eyes, and ocular surgery. Finally, a valuable library consisting of some 4,500 volumes and 28 journals, besides a well equipped laboratory, are at the disposal of all who wish to make personal researches.

Ophthalmology has now a second chair at Budapest University with a new clinic containing 72 beds; while at our other University (Kolozsvár) a hospital with 70 beds is attached to the chair of ophthalmology.

The two prospective Universities of Pozsony and Debreczen—for the erection of which Government sanction was given last year—will each have a chair of ophthalmology with a hospital of 70 beds.

In the teaching of ophthalmology at Budapest, besides two ordinary professors, three extraordinary and three private *docents* take part, who are consulting surgeons at the different hospitals.

The number of hospital beds at the service of eye patients has increased by about 400 within the last ten years. There are to-day, in the three clinics now existing, 220 beds; in the four State ophthalmological hospitals 370 beds; in the ophthalmological department of the 15 general hospitals 750 beds; and in the three existing trachoma hospitals, 60 beds: in all 1,400 beds are at disposal for eye cases.

For protection against trachoma, there is a Government Commissioner, and a Referant in the Ministry of the Interior; this work costing the State 150,000 crowns annually, besides the expenses for hospital treatment.

Such is the position of ophthalmology in Hungary at the present day.

DISCUSSION ON THE PRESENT POSITION OF OPHTHALMOLOGY.*

CONTRIBUTED BY

F. R. CROSS, M.B., F.R.C.S.,

BRISTOL, ENGLAND.

Mr. F. R. CROSS thought that the great development of specialities in medicine had been well met as to ophthalmic work, by the appointment in all

* A contribution to the discussion at the Oxford Ophthalmological Congress on July 18th, 1913.

the larger hospitals of the country of eye departments, as well as by the better equipment of the special hospitals. Of recent years there had been a large increase in the number of ophthalmic surgeons up and down the country, the larger residential centres being now usually provided with one.

He thought it might be convenient in country towns not large enough to support a pure ophthalmic surgeon, if a department were made at the local hospital, in which nose and ear cases were attended to by a specialist who also had charge of the patients suffering from diseases of the eye—such a provision would be a great convenience to the neighbourhood, as well as to the hospital staff.

The correction of refractive errors by the use of glasses will be partially undertaken by the opticians, who should, however, have some special training, with a knowledge of optics and so forth. They often give glasses with good judgment. In children the advice of an ophthalmic surgeon is essential, as investigation under eye drugs is usually necessary.

There is a close association between swellings of the orbit and diseases of the surrounding sinuses of the nose, and the ophthalmic surgeon and rhinologist might well be associated in one person; but in large centres a division of work is much more satisfactory, and, as a rule, it is not difficult to decide to which department a given case properly belongs.

He quite agreed with many of the remarks made in the excellent speech of Dr. C. O. Hawthorne. Every case of disease of the eye, or any inflammation of any portion of the eyeball, should be considered on the broadest lines of medical diagnosis: it was often a symptom in a general disease, and a full investigation should be made in regard to the patient's health.

He demurred strongly to the suggestion that oculists only considered the case from the narrow local standpoint of the eyeball, or that they, as a class, did not avail themselves of consultation with their medical colleagues. He believed that the opposite held good, and that, although well informed specialists are quite capable themselves of making a general diagnosis, on what may be called the clinical aspect of the case, still they appreciate the necessity of consulting with a patient's doctor or with a physician specially selected, as to faulty conditions of secrection, disease of the organs, blood pressure, habits of life, etc., or with the neurologist as to symptoms that accompany abnormal conditions of movements of the eyeball, or in defective functions of the optic nerves.

When the eye symptoms are secondary to more general severe ill health, the patient very properly remains under the care of his physician; but when the essential complaint is of faulty vision, or when the eye is the organ primarily at fault, the patient and his friends will look to the oculist to control the case.

The chief assistance, however, comes from the scientific investigations of the pathologist and the bacteriologist. He would venture to say another word, and would suggest that the rising generation of young physicians will show their value as consultants, and their early claim to obtaining hospital appointments, not only by a sound up-to-date clinical knowledge, but rather by their capacity for undertaking original laboratory and bacteriological research. Much of the help now given in the pathological laboratories by lay clerks, might with advantage be undertaken by recently qualified medical men.

ON THE PRESENT POSITION OF OPHTHALMOLOGY IN GREAT BRITAIN.*

BY

SYDNEY STEPHENSON, D.O. (Oxon).

LONDON, ENGLAND.

HON. SECRETARY OF THE OXFORD OPHTHALMOLOGICAL CONGRESS.

I SHALL limit my remarks to two alone of the problems Mr. R. W. Doyne has attempted to solve, namely: (1) The optician question, and (2) The special societies.

1. The Optician Question.

Few medical men appear to be as conversant as would seem desirable with the state of this question in England to-day.

Two bodies, both having their headquarters in London, concern themselves with the education and qualification of opticians, *viz.*: The British Optical Association and the Company of Spectacle Makers.

The former body, formed in the year 1895, issues, after examination, two qualifications, a lower one, now known as the *Associateship*, and a higher one, the *Fellowship*. It fosters the production of the skilled optician, who does not mix up his business with that of a jeweller, chemist, or anything except optics and sight-testing. Its rules and practice are evidentally modelled upon those which prevail in the medical and dental professions. Thus, the British Optical Association aims at raising its diplomates to a professional grade; inculcates ethical principles; and sets its face strongly against anything approaching blatant advertisement on the part of its members. It enforces discipline by withdrawing its diploma from holders, and its power to do this has been upheld by a recent legal decision, according to which these certificates belong absolutely to the Association. The treatment of distempered eyes, otherwise than by glasses, or the employment of atropine or other cycloplegic, is met by warning the delinquent or even by recalling his diploma. The action of the Association has led to the disappearance of the objectionable sight-testing stalls from the White City and from several provincial exhibitions. The non-provocative attitude of the Association has led to the giving up of the aggressive tone once so commonly employed towards the medical profession by a certain type of optician. It attempts to suppress what has been called "the multiple optician," of which London still, I am sorry to say, shelters one or two especially flagrant offenders. The aim of the British Optical Association, in short, is to render opticians better qualified for their work, and to enforce a code of ethics upon its members, who now number upwards of eight hundred.

The Worshipful Company of Spectacle Makers, on the other hand, is an ancient (1629) City of London Livery Company, which has of late years 1898) added to its other function of giving dinners that of licensing opticians. Its qualification deals with sight testing, and is known by the letters F.S.M.C. The number who hold this certificate is about one thousand.

To a certain extent, the two bodies overlap, but the Spectacle Makers, as compared with the British Optical Association, is relatively an inert concern, from which as little is to be hoped as it is to be feared. Nowadays, it lays itself out to manufacture the so-called "chemist-optician."

Both these bodies have promoted bills to secure state recognition of their certificates or diplomas. But that of the British Optical Association was

* Contribution to the discussion at the Oxford Ophthalmological Congress on July 18th, 1913.

never presented, while that of the Spectacle Makers' Company, although introduced into the House of Lords (April 5th, 1906), never reached a second reading. From what I can gather, it is very unlikely that any further attempt will be made in that direction for a good many years to come. It must be preceded by an understanding between the two bodies mainly concerned, and, furthermore, it is likely to be seriously made only after some sort of arrangement has been concluded with the medical profession.

It can scarcely be gainsaid that the ophthalmic surgeon and the skilled optician are in active competition with regard to refraction cases. It has been said, with truth, that anybody suffering from obvious external disease of the eye, or from acute pain, is seldom to be seen in an optician's shop. He is much more likely to seek medical help. But there is a class common to the two. An important part of the modern ophthalmic surgeon's practice is made up of refraction cases, driven to him by aching eyes, headache, and so forth. It is over this class of case that the ophthalmologist and the optician find themselves in open and active rivalry.

Those conversant with the facts will be the last to deny that some of these skilled opticians do their refraction work remarkably well. They are well trained, and, for that matter, their methods are much the same as our own. They often take wonderful pains with their clients. The equipment of their testing-rooms would in many instances put the modest outfit of some ophthalmic surgeons to the blush. Their weak point is that they are precluded from employing cycloplegia for the estimation of small errors of refraction. Not only is the use of atropine forbidden by the bodies whence they derive their certificates, but they are themselves well aware of the risks they may incur at common law by employing that or similar agents.

It has been epigrammatically said that "the first duty of an ophthalmic surgeon is to prevent ophthalmic surgery," and the rivalry between the two classes, surgeons and opticians, is only too likely, it seems to me, to increase rather than to diminish in the future. The competition is bound to become accentuated when the public awakens to the technical competency of many of these men and realises what an influence eye reflexes may on occasion exert upon the health and well-being of the community. Even now signs are not lacking that knowledge is spreading in those two directions.

It would be futile to attempt to ignore the existence of this class of optician, the justification for whose existence depends entirely upon the fact that their help is sought, in the first instance at any rate, by nine persons out of ten whose sight is failing. Parliament would not listen for a moment to any attempt to insist that such individuals should be dragooned into seeking advice from the medical man. Neither are there enough medical men to undertake the work. Personally, I am persuaded that the qualified optician in this country has "come to stay."

The remedy, as it seems to me, is first, to regulate the proper practice of what is often termed nowadays "optometry"; and, secondly, to educate the ophthalmic surgeon in such a way that he is, without question, the more competent man to deal with refraction cases. There appear to be a couple of methods in which the latter end may be accomplished:—(1) By making ophthalmology a compulsory subject in the ordinary medical examinations, as is already done by six out of twenty-one licensing boards; (2) by instituting a special diploma on the subject, and thereby following the example already set by the Universities of Oxford, Liverpool, and Colorado. The medical man's wider general education, together with his professional training, would be tangible assets with which the optician could scarcely hope to compete successfully.

By these means refraction cases would in the future divide themselves into two groups, namely, the poorer members of the community, who would seek help from the optician or the hospital, and the more prosperous, who would gravitate towards the trained ophthalmic surgeon. With this sub-division of labour, the ophthalmologist might well rest content; the optician would find his proper sphere of usefulness; and, last, but by no means least, the public, irrespective of social class or financial standing, would not be victimised by the slip-shod and too often dishonest worker, who in the past has often enough posed as an "optician" or "eye-sight tester."

2. The Special Societies.

At the moment we are in a somewhat chaotic state as regards the ophthalmological societies or sections of this country. In my view, the present confusion makes neither for efficiency nor economy.

Now in Great Britain there are the following societies which specially concern themselves with matters ophthalmological:—(1) The Ophthalmological Society of the United Kingdom (492 members); (2) The Oxford Ophthalmological Congress (247 members); (3) The Midland Ophthalmological Society (34 members); and (4) The Scottish Ophthalmological Club (48 members). The three last-named were formed at a period long after the foundation of the Ophthalmological Society of the United Kingdom. In my opinion, every one of them, unless it be the Oxford Congress, indicates the failure of the older society in some particular direction or directions.

Then, in addition to the societies proper, we have the following special sections:—(1) The Ophthalmological Section of the Royal Society of Medicine, and (2) The Ophthalmological Section of the British Medical Association.

The value of properly organised societies cannot be ever-estimated, more especially perhaps to the younger members of the profession. Indeed, not to belong to a special society is nowadays really somewhat of a reflection; it always gives the uncharitable-minded an opportunity to assume ineligibility as the cause. Contrariwise, to belong to a special society is in itself somewhat of a testimonial to a man's fitness to practise the speciality he has chosen. A society, when wisely used, brings men of the same line into close personal touch with one another, and hence tends to remove many a misunderstanding born of ignorance and fostered by isolation. The mere association of the junior with the senior tends to make each take a larger outlook. The impetus given by the society to study is great. In brief, it rouses our enthusiasms, strengthens our friendships, and, looked at merely as a means of instruction, is valuable to every one of us.

A first necessity for any speciality, therefore, is a strong, well-managed, and energetic society. Can it be truthfully said that we have such in this country at the present time? Every open-minded observer must, I fear, return a negative to this question.

The needs of the metropolis, both as regards the showing of cases and the reading of papers, are met quite satisfactorily by the Ophthalmological Section of the Royal Society of Medicine, constituted as recently as the 26th of last July (1912). But with that exception I cannot but believe that the interests of ophthalmology would be best consulted by sinking all individual differences between other societies and sections and by forming a *British Ophthalmological Society*, which like the corresponding societies of America, Germany, and France, would meet once in each year. Personally, I should like to see these meetings organised upon a peripatetic basis, although most will agree that if

one place alone be selected, London has greater advantages in that respect than any other city in the United Kingdom, and next to London, Oxford's outstanding advantages will be apparent to many of us. Local needs might readily be met by forming as many sections of the parent society as necessary —say one each for the north, south, east, and west of England, one for the midland counties, while Scotland and Ireland would each naturally form a division of its own. The local branches would not be hampered by any cast-iron set of rules, but would be left free to make their own arrangements as to membership, dates, places, and times of meeting, and so forth. In short, their autonomy should be complete, subject only to loyalty to the parent association.

The present Ophthalmological Society would strike one as the nucleus around which the existing societies might cluster, and the necessary preliminaries to any such scheme as I have ventured to outline would be the amalgamation for a common end of our own Congress, the Midland Ophthalmological Society, and the Scottish Ophthalmological Club.

I feel convinced that it is only by some scheme of the sort that British ophthalmology will ever be represented by a society really worthy of the achievements, past and present, of the ophthalmologists of these islands.

TREPHINING IN GLAUCOMA, ACUTE AND CHRONIC: MISCELLANEA.*

BY

LIEUT.-COL. R. H. ELLIOT, I.M.S.,

MADRAS, INDIA.

(1) *Homatropine as an adjuvant in the diagnosis of glaucoma.* (2) *The influence of various subconjunctival injections on the intra-ocular tension in glaucoma.* (3) *The causes of the variations in the difficulty met with in "splitting" the cornea during the trephine operation.* (4) *The best size of trephine to employ.* (5) *The best shape to give to the sclerostomy wound.* (6) *The nature, significance, and importance of the so-called post-operative iritis, met with after trephining.* (7) *Some causes of failure after trephining.*

Introduction.

I wish to open this address with the statement of my conviction that trephining is not merely suitable, but is *the operation of choice* for cases of acute as well as of chronic glaucoma.

It is first necessary to clear away some possible sources of misunderstanding as to what is meant by the term "acute glaucoma." Some would reserve the name for "the form of the disease, which *begins* with acute symptoms" believing, as they do, that the onset of these symptoms marks, in some cases at least, the very beginning of the disease. Hence, there appears from the operative point of view to be a tendency to place "acute primary attacks of glaucoma," in a category apart, and to draw a sharp distinction between them and the acute or subacute exacerbations of cases of chronic glaucoma. Despite its apparent suddenness, the first attack of high tension may be merely an exacerbation of an extremely mild glaucomatous state. The histories given

* Address delivered at the Oxford Ophthalmological Congress, on July 17th, 1913.

prove that this is so in many instances. I do not mean to challenge the opinions of those who are confident that they have met with cases in which they are satisfied that the eyes were not glaucomatous before the acute attack began, but it is quite obvious that in every such eye the physical factors which predispose the organ to an attack of high tension must at least be present, whilst the proof that the eye was normal is always difficult, and often impossible. It may be urged that in the exacerbations of chronic cases, iris adhesions introduce an element of complication. The same cannot be said of a class of case frequently met with in India, in which violently acute attacks of secondary glaucoma complicate the course of an intumescent cataract. The only discernible difference between these cases and those of acute primary glaucoma, lies in the rapidity of the onset of those physical conditions which invite a glaucomatous attack. It is quite certain that in the violence of their symptons, they sometimes yield pride of place to nothing less acute than a glaucoma fulminans. In India we do not meet with cases of acute primary glaucoma ; this is accounted for by the reluctance of the people to resort very early to medical relief, and by the fact that the diagnosis is too often not made at this stage, owing to the paucity of trained medical men, but we have trephined a number of cases of acute or sub-acute exacerbations of chronic glaucoma, and of acute glaucoma secondary to cataract, with the most satisfactory results. It is true that I do not now advocate the use of the trephine in the great majority of cases of glaucoma secondary to cataract, simply because this condition is most frequently met with in intumescent cataracts in which the cortical substance is fluid or semi-fluid, and hence tends to flow towards, and thus block up the trephine hole. This, however, is a complication apart from the conditions we are now discussing, and if it can be excluded, the results of trephining may unhesitatingly be classed as not merely satisfactory, but as brilliant ; all the more so since they are permanent. No further argument is needed to show that the operation of trephining is applicable to the treatment of very acute glaucoma. The only serious reply to this contention, with which I have met, is that iridectomy gives excellent results in these cases, and that therefore no fresh operative procedure *need be tried.* I do not think that this argument is a sound one. I admit the brilliant results of iridectomy,but I submit that *trephining is an easier,a safer,and a more securely permanent remedy* for the condition. I do not think that any surgeon, be his skill and experience what they may, can undertake any known operative procedure on a patient with acute glaucoma, without the feeling that he would be foolish indeed to boast until after he has laid his armour by. The issues are momentous, and the results, even when he has given of his best, are in the lap of the gods. When I hear a surgeon speak of an iridectomy for acute glaucoma as an easy proceeding, I wonder what he means. I have had the opportunity in Madras of teaching the operative surgery of the eye *on the living patient* to a large number of medical men and ladies, and I know no operation which it is harder for the beginner to acquire than the performance of a clean iridectomy, even in uncomplicated cases. The surgeon who has learnt this is a graduate in the art of operating. To my mind, trephining is an easier operation from the surgeon's point of view, and a safer one from the patient's, than the old broad iridectomy. Then, as to permanence ; if trephining has been successfully performed, the future of the patient is assured. I do not think that I shall be so fortunate as to carry you all with me when I state my belief that the same thing cannot be said so certainly of the results of an iridectomy. I believe that when an iridectomy is successful, it is so in most cases by producing a filtering cicatrix. Doubtless, cases do occur in which the results appear to be permanent, although no

evidence of filtration exists. I would ask you whether these are not the cases in which an acute glaucomatous condition has suddenly supervened, and I would suggest to you that the physical conditions, provocative of a glaucomatous attack, are present, and that the iridectomy has merely "seen the patient through" a crisis; a serious lesson has been learnt, and your after-care puts him on his guard, and shields him from those influences which may convert a potential into an actual glaucoma. I do not press these views, still less do I attempt to dogmatise, but I do put them forward for your earnest consideration. I believe this aspect of the case to be worthy of very serious attention. Even if surgical opinion finally rejects such an interpretation, nothing but good can come from an examination of the subject.

From almost every part of the known world, surgeons have written to me of their satisfaction with trephining in chronic cases, or have published like opinions in the medical press. To those who have trusted me so far, I would appeal that they should at least give the trephine a fair trial in their acute cases. I speak not as an enthusiast who desires to establish a monopoly for a procedure in which he is interested, but with a firm, settled, and gradually acquired conviction that trephining is the easiest, the safest, and the most reliable method of performing a sclerostomy, a conviction which many others who have tried it in Madras and elsewhere firmly share.

It is not uncommon for surgeons to try one form of operation and in the event of a failure to fall back on another. One of the many charms of trephining is that it in no way interferes with the subsequent performance of any other procedure which may be deemed advisable in the event of a return of tension. The same cannot be said of an iridectomy performed in the usual way, for the keratome wound leaves a cicatrix at or near the limbus which mats the conjunctiva to the deeper parts and makes the dissection of the conjunctival flap on to the cornea (in other words, the "splitting" of the cornea) much more difficult than it would otherwise be. This trouble is very easily avoided by dissecting a conjunctival flap right up to the limbus, before introducing the keratome, in the course of the iridectomy operation. The ordinary steps of the iridectomy are in no way interfered with, and if it is found necessary to trephine at a later date, there is no difficulty in carrying the dissection of the flap on to the cornea.

(1) On the use of Homatropine as an Adjuvant in the Diagnosis of Glaucoma.

The diagnosis of glaucoma must not be made lightly. Every feature of the case must be taken into account. The sight, the visual field, the tension, the history, and the ophthalmoscopic appearances are all of importance. Each must be weighed, and in doubtful cases our judgment must be based on a consideration of all the evidence available. In India we meet with many cases in which, owing to want of dilatation of the pupil, to haziness of the media, to corneal nebulæ, to cataract, or some other cause, it is not possible to obtain a clear view of the disc without dilating the pupil. We tried the hydrophthalmoscope in Madras, only to reject it as an interesting toy which has little practical application. Our rule now is to dilate the pupil with homatropine in every case of doubt, nor have we ever had cause to regret our temerity. This line of action was not ventured on until after we had most carefully considered all the bearings of the case. It is true the homatropine has been known to produce an attack of glaucoma in predisposed eyes; but so far as our information goes, this accident has never yet occurred until after several hours of continuous mydriasis. Moreover, it has always been possible in these cases to control the rise of tension by the use of eserine. Homa-

tropine mydriasis can, in our experience, always be converted into myosis within a period of thirty minutes. Its use has often enabled us to clear up a doubtful diagnosis, whilst an experience of a large number of cases has justified us in the belief that it is a perfectly safe proceeding, so long as we are careful to instil a myotic as soon as we have completed the examination for which the mydriatic was used.

(2) The influence of various subconjunctival injections on the intra-ocular tension in glaucoma.

Dr. Herbert Thomas, of Auckland, California, has advocated the treatment of glaucoma by means of subconjunctival injections of solutions of pure crystallised sodium citrate. He found the reduction of tension unfailing; complications were absent, and relief lasted from days to weeks (*Journal of Ophthalmology and Oto-laryngology*, July, 1911). Dr. Martin H. Fischer, who worked with Thomas, supports him in the above findings (THE OPHTHALMOSCOPE, Vol. 10, page 715). We tried the method in Madras, closely following these writers' directions, and controlling the results obtained by selecting one eye for the injections, whilst eserine solution was used for its fellow. The cases chosen were all marked instances of double glaucoma. Our results were most disappointing, and we reluctantly abandoned the treatment without being able to explain the discrepancy between the two sets of observations. One very distinct disadvantage in the use of the citrates was found to be the troublesome adhesions they excited between the conjunctiva and the deeper parts. We will return to this subject again later on.

(3) The causes of the variations in the difficulty met with in "splitting" the cornea during the trephine operation.

Any surgeon who has done a number of trephinings must have noticed that the difficulty met with in carrying out this manœuvre varies very greatly. In many cases it is very easy to get an area 2 mm. or more in breadth for our purpose, whilst in others we have to make a long and careful dissection in order to obtain the necessary minimum of 1 mm. This ever-recurring variation led us to make a careful study in search of its cause or causes. *A priori*, one would expect to find more difficulty in cases where long-standing perilimbal congestion has been present, and experience justifies this surmise. An allied condition is that in which subconjunctival injections have been made in the quadrant subsequently selected for the trephining. Where normal saline has been thus used, the raising of the corneal portion of the flap is distinctly more difficult than in an ordinary case, whilst the previous exhibition of a sodium citrate solution or of a preparation of the mercurial salts makes trephining in this area an impossibility, unless we are content to forego the splitting of the cornea. The plain moral of these observations is, that if we decide to use any such preliminary treatment, we must select for the purpose a quadrant of the eye remote from that in which we intend to trephine.

Apart, however, from any of the considerations hitherto dealt with, there are physiological conditions which have a very distinct influence on the amount of difficulty met with in "splitting" the cornea. We had from the first observed the extraordinary variation in the amount of subconjunctival tissue met with in the eyes of different patients. It is a broad general rule that older patients have less subconjunctival tissue than younger ones; but inside this generalisation we soon found that further wide variations occured, and the idea that there was a relationship between the amount of tissue present, and the difficulties met with in "splitting" the cornea began to take definite

form. Before committing ourselves, however, to such a view, we steadily made a number of observations, without endeavouring to reach any conclusion, until after the mass of figures at our disposal was considerable. We avoided all preconceptions, and simply accumulated statistics, the principal features of which were (1) a note of the amount of subconjunctival tissue present and (2) a record of the ease or difficulty met with in "splitting" the cornea. We classified the amount of subconjunctival tissue present under three heads, (1) abundant, (2) moderate, (3) scanty; whilst the difficulty of "splitting" the cornea likewise fell into three heads, (1) difficult, (2) moderate, (3) easy. The results were kindly worked out for me by Lieut. Craggs on 238 consecutive cases. To summarise the leading points:—"splitting" of the cornea proved difficult in 31.7 per cent. of cases with abundant tissue, in 15·2 per cent. of the moderate cases, and in 11·6 per cent. of the scanty ones; whilst it was noted as easy in 29·2 per cent. of the abundant cases, in 43·4 per cent. of the moderate ones, and in 58 per cent. of the scanty ones. This confirmed the conclusions we had previously reached in a tentative fashion from our general impressions derived from a large number of cases in which exact statistics had not been taken. The figures would probably have been much more convincing but for the obvious difficulty in a large number of cases of defining the boundary lines between ease and difficulty and between varying amounts of connective tissue. We are all of us (in Madras) quite satisfied as to the soundness of the conclusion that the less the connective tissue present beneath the conjunctiva, the easier it is to "split" the cornea and *vice versa.*

At the same time, one desires to avoid giving any support to the views of those who maintain that "splitting" of the cornea is a very difficult procedure; it is true that it calls for care and skill, but that is all that need be said of it. To prove my point, I may quote some figures from our statistics in Madras. In 201 consecutive trephinings (between November, 1911, and March, 1912) I damaged my flap on four occasions only (*i.e.*, in 1·99 per cent.), and in not one of these cases was there any evidence that the tiny button-hole made had any influence on the satisfactory course of the case. During the same period ten other surgeons, learning trephining in Madras, button-holed seven times in 124 consecutive operations (*i.e.*, in 5·6 per cent.) and on only one such occasion was it found necessary to shift the area for the application of the trephine.

(4) What is the Best Sized Trephine to use?

Extraordinary as the admission may seem, I do not think that this question can be yet considered as settled. Indeed, I would go farther, and express the opinion that the subject is one on which expert opinion will remain long, if not indefinitely, undecided. Nor need we within certain limits consider the point a vital one; and yet I shall put forward for your consideration to-day some facts, which, to my mind at least, shepherd us toward a trustworthy solution of the vexed question.

In the early days of trephining, we were uncertain how large an aperture would be needed to maintain the necessary freedom of filtration, and the critics of the method suggested that large apertures would be required to allow for the filling up of the trephine hole, which they prophesied would inevitably take place. It is not worth while discussing the reasons then given for these views, since time and experience have furnished a full and sufficient contradiction of them. We have been able to follow cases in Madras for long periods, some of them from over two to as much as 3½ years, in which full and free filtration has been established and maintained by the aid of a trephine of 1·0 mm. or of 1·5 mm., in diameter.

We however abandoned all smaller trephines for one of 2 mm. in diameter, under the stress of a very important factor, *viz.*, the occurence of uveal tissue complications. It is to be particularly remembered, that at this stage, though we were practising "splitting" of the cornea, we were not using the manœuvre in every case, nor were we carrying the "splitting" so far as we do now. The natural result was, that we not infrequently entered the anterior chamber, in close proximity to the iris base, or when pathological adhesions were present, to the line of irido-corneal attachment. Iris tied down in this way to the very edge of the wound, is obviously a standing menace to the maintenance of efficient filtration; it may easily get washed into the wound and directly block it, or it may become the seat of proliferative changes which lead to a later sealing up of the trephine hole. It was therefore felt that the aperture in the sclera must be made of sufficient size to admit of the iris forceps and scissors being freely used therein, so that when this troublesome complication of iris-prolapse did occur, it could be easily and thoroughly dealt with.

To-day the position has very considerably altered. The anterior position of our trephine hole enables us to avoid the undesirable neighbourhood of the ciliary body and of adherent iris base; so that we now only have to reckon with free iris tissue, whose point of tethering is at some distance from the hole. Again, the new manœuvre, elsewhere described, for fixing the globe during the iridectomy, avoids all drag on the iris, and so in skilful hands, practically eliminates the main cause of impaction of iris tissue. Under these changed operative conditions, iris complications have now almost vanished from our experience in any but late cases, and we have, therefore, naturally turned once more to consider whether we may not now again reduce the size of our trephine hole. Able writers have expressed themselves satisfied with the results obtained with a 2 mm. trephine hole, and some have even expressed an intention to increase the diameter of their blades. Surgeons will, therefore, naturally ask what we expect to gain by reducing the size of our sclerostomy. Is it really important to do so? I think it is. In the first place, it is unsurgical to make a bigger wound than is required, and experience has shown that an aperture of 1·0 to 1·5 mm. in diameter suffices to maintain permanent filtration. Some of our critics have suggested that the prolonged hypotension, met with after trephining, may constitute a menace to the safety of the eye by interfering with its normal nutrition. This indictment has been unsupported by any evidence, and has been negatived by our Madras experience. Again, I have been consulted by surgeons, who have asked my advice as to the performance of a trephining in long-standing cases of glaucoma, in which the probable state of the vessels made them fear the occurrence of an intra-ocular hæmorrhage. Their contention was that the prolonged hypotension would be pregnant with the possibility of the occurrence of late bleeding. They argued that after an iridectomy, normal intra-ocular tension would be restored at an early date and that consequently the diseased vessels would sooner receive a normal external support. I have no hesitation in answering this from clinical experience. Be the method we adopt what it may, we cannot get away from the risk of intra-ocular hæmorrhage at the moment when we relax the tension of the globe by dividing its investing tunic. Priestley Smith long ago gave us the valuable advice to perform a sclerotomy in certain cases before opening the eye for an iridectomy. Many of us have proved the value of this manœuvre by frequent use. The *modus operandi* is evident; the congestion of the intra-ocular vessels is relieved before the supporting pressure from without is wholly withdrawn, and the danger of a rupture of the vessel walls is thereby minimised. Schnaudigel has suggested that the trephining should be

slowly performed, so as to allow the aqueous to make its escape gradually. This suggestion is entirely in accordance with what has long been our practice in Madras. Despite every precaution, however, intra-ocular hæmorrhage will still be met with from time to time; but if it does occur, it manifests itself at once whilst the patient is still on the operation table; the rapid hardening of the eye and the bulging of intra-ocular contents at the trephine hole leave us in no doubt as to what has happened. In my whole experience of now nearly 900 trephinings I cannot recall a single instance of late hæmorrhage. This in itself would negative my correspondents' suggestions of the dangers latent in the maintainance of a prolonged hypotension. On the other hand, I would remind you that when hæmorrhage occurs in an eye which has been widely opened by the incision necessary for an iridectomy or a Lagrange operation, there is nothing to prevent, and everyto invite, the extrusion of the contents of the globe through the wound. Every surgeon of large experience has seen the vitreous well up into the opening he has made, sometimes to be permanently impacted there, more seldom but more disastrously to be followed by a copious hæmorrhage. The trephine wound has materially altered this. It is so small that only a bead can present through it, and unless the operator wilfully ruptures that bead by rough or prolonged manipulation, he can always send his patient back to bed with the vitreous still intact and the hæmorrhage locked up under pressure. On the second or third day, he will often find that the tension has fallen. The obvious presumption is that absorption of the effused blood has taken place. It is conceivable that some will admit the validity of the arguments we have used as proof of the value of the trephine wound over the keratome incision, but will nevertheless cavil at the suggestion that a further reduction of our sclerostomy from 2 mm. to 1 mm. or 1·5 mm. in diameter can be of any value. I am not inclined to agree with such, for I hold that the smaller the opening made, the less is the interference with the support of the deeper structures. A still more important consideration, however, awaits us in this connection, *viz.*, the determination of the breadth of the zone available for the implantation of the trephine, *i.e.*, the zone between the irido-corneal angle, on the one hand, and the limbus or the base of our conjunctivo-corneal flap, on the other. Very important issues hang on the correct determination of this measurement. Not least among these is the question of the soundness or otherwise of the sliding flap, recently advocated by some American surgeons. Careful drawings to scale made by other workers have been examined to control the results we have obtained in Madras by the measurement of sections of normal eyes. These observations have appeared to confirm our estimate that the breadth of the zone we are considering is rarely as much as 2 mm., and usually only about 1·7 mm. If this calculation is borne out by other observers, it is obvious that very important conclusions must follow, especially when we recall the fact that in glaucomatous cases we often meet with adhesions between the iris base and the cornea, adhesions which encroach on the area we are now discussing. It is true that we can add from 1 mm. to 2 mm. to the available breadth of the area by "splitting" the cornea, but against this we must allow for the possibility of a loss of 1 mm., or even more in certain cases, owing to irido-corneal adhesions. In favourable circumstances, then, we would have 3·2 mm. to come and go on, and could, therefore, afford to use a 2 mm. trephine with a good margin for safety; but if we happen to be dealing with adherent iris, or with an eye in which the zone between the limbus and the angle is naturally narrow, and still more if "splitting" of the cornea beyond 1 mm. proves difficult, it is clear that the

posterior border of our trephine will be in dangerous proximity to fixed uveal tissue, even if we do not actually impinge on, or wound, the same. The more we can safely reduce our trephine diameter, the further do we remove our wound from the area of danger. Every fraction of a mm. appears to me to be worth fighting for. One point more—the class of case in which there are no adhesions and plenty of room physiologically (owing both to the conformation of the eye and to the ease with which the cornea "splits"), is the very class, above all others, in which we do not require a large trephine hole. On the other hand, although in those cases which are likely to prove difficult one can infer the presence of adhesions in advance, it is not possible accurately to gauge the breadth of the adherent area before we apply the trephine. Under such conditions it is obviously better, *ceteris paribus*, to err on the side of making a small sclerostomy rather than a large one. All the indications, therefore, appear to point in the direction of a reduction in the diameter of our trephine blades, and I would suggest a 1·5 mm. blade as likely to prove the best, whilst confessing a doubt whether one of 1·0 mm. may not in the long run prove the most favourable selection.

(*To be Concluded.*)

ON PSEUDONEURITIS.*

BY

C. G. Russ Wood, F.R.C.S.,

SURGEON TO THE SHREWSBURY EYE, EAR, AND THROAT HOSPITAL,
OPHTHALMIC SURGEON TO THE SALOP INFIRMARY, ETC.

It is remarkable that in spite of the very large mass of ophthalmic literature which has accumulated during the last fifty years, the subject of Pseudoneuritis has received so little attention. In this country only slight interest has been displayed in the anomaly, but on the Continent more account has been taken of the subject, if one may judge by the published work. It is to be regretted that the text-books are virtually silent on the matter, because it is important that mimicry of optic neuritis should be fully recognised. Yet cases are occasionally seen about which the most expert in the use of the ophthalmoscope find it impossible to give a decided opinion, the most careful consideration of concomitant symptoms serving to obscure rather than illuminate the diagnosis. In such the only method of differentiating the spurious from the true is repeated examination by objective and subjective methods spread over a considerable period.

de Wecker[1] in 1870 appears to have been one of the earliest to draw attention to the condition, and, under congenital anomalies of the optic nerve, he utters a warning against confusing the condition with optic neuritis. Galezowsky[2] in 1869, quoted the case of a heavy drinker and smoker, who complained of defective vision. The left fundus was normal, the right showed signs of neuritis, and six months later, the ophthalmoscopic appearances were unaltered. Dobrowolski[4] described a case in which appearances became much less marked after lenses were worn; but it is doubtful if this was a true case of pseudoneuritis. Gunn[5] reported, in 1895, a case with R.V. 6/6 Hm. + 2D. L.V. 6/24 Hm. + 2D. = 6/18, left convergent strabismus. There was hypermetropia of 5D., and the O.D. was swollen and seen with a +8D.sph., the

* A communication read at the June, 1913, meeting of the Midland Ophthalmological Society.

condition of the papilla in each eye closely resembling an acute optic neuritis. The patient had been under observation for five months and no change noted. In the following year the same author, in discussing another reported case, said that he had watched a patient with this condition for four or five years, during which period the swelling had remained unchanged. He further stated that correction of the refraction had had no influence on the ophthalmoscopic appearances. Holmes Spicer[6] reported a case of a boy with 6/6 in each eye and no refractive error. The patient was first seen in 1893, with +3D. swelling of both discs, the outlines of which were blurred and indistinct. The vessels appeared normal. There was headache and ocular pain, but no vomiting. The patient was examined at intervals during the following three years, and still complained of headache, ocular pain, but no vomiting, the vision remaining unimpaired. Latterly, he had been compaining of occasional attacks of red-coloured vision which came on when he was reading. Visual fields, colour vision, and light sense normal. The edges of the disc were quite indistinct, the appearance suggesting an optic neuritis in the subsidence stage. E. W. Brewerton[7] reported a case in 1906, which had been under observation for sixteen months, during which no change had occurred. The vision was 6/6 each eye; refraction emmetropic. The swelling of the disc was about 1 mm.; no vomiting or headache The author, in August, 1912, in answer to an enquiry from the writer, regarding the after-history of this case, kindly reported, "The optic discs have never changed in the slightest degree, and the vision has remained normal." In the discussion on this case, A. W. Ormond stated he had seen a case of optic neuritis in both eyes, in one of which there was fair vision; the patient had been under Gustavus Hartridge ten years before with the same condition, which presumably had never subsided. He died in two or three months' time. In answer to an enquiry from the writer, Mr. Ormond has courteously furnished the following additional details.—When first seen, the patient had a large abscess under the scalp in the occipital region with signs of intra-cranial pressure and delirium, also paresis and anæsthesia of the right arm. *Post-mortem* an abscess was found in the left occipital lobe, between the falx cerebri and tentorium, with some purulent meningitis.

Nottbeck[3], who has written an exhaustive article on this subject, to which I am indebted for many of the Continental references, quotes the following five cases:—(1.) A boy, aged 14, had always seen well, but recently had taken up work as a tailor, and found difficulty with his sewing. R.V. 6/18 +5 D.+ 2.50 cyl. ax. vert. L.V. 6/6 + 2. D. The right disc about + 3 D. higher than the retina, especially so on the inner side. The left disc + 2 D. higher than the retina. Visual fields, light, and colour sense normal. The patient was seen at intervals for seven years, and at the end of this period the condition was unchanged, no atrophy having supervened. (2.) Child aged 15. R.V. 6/60 H. + 3 D. L.V. 6/6 + 1 D. Periostitis of right orbit, which settled down in a few weeks. When first seen, both fundi, especially the right, shewed what appeared to be marked neuritis with hyperæmic papillæ but no swelling of O.D. No hæmorrhages or white spots in retinæ. At the end of nearly four years, the ophthalmoscopic appearances were unchanged. This patient had suffered from ear disease (probably chronic suppurative otitis media), inflammation of lungs, enteritis, and an affection of the heart, before the periostitis appeared. There was a suspicion of albumen in the urine. (3) Girl, aged 12. R.V. 6/6 + 1 D. L. V. 6/6 + 1 D. Both papillæ + 2·50 higher than retina. Visual fields, light, and colour sense normal. The edges of the discs were blurred and reddened, there was also retinal streaking, especially on the

temporal side; vessels very tortuous. Observed for three years, during which time condition remained unchanged. (4) Girl, aged 7. R. V. + 6/6 + 2·25 D. L. V. 6/18 + 3.75 + 1·50 cyl. ax. vert. Both disc-edges blurred and grey-red in colour; swelling + 1 D. There was a white patch above the O. D. in left eye (? opaque nerve fibres). Condition unchanged at the end of four years. (5) Girl, aged 17. R. V. 6/60 + 6 D. L. V. 6/18 + 1 D. Both disc edges blurred, with slight swelling. Right convergent strabismus. Condition unchanged at the end of five years.

Nottbeck also quotes thirteen other cases, all of which had blurred edges to the discs with radiate retinal streaking in several. They were not, however, observed over long periods. He further quotes a case of Axenfeld's, which was under observation for thirteen months. The man, aged 30, was insane, and when first seen, had what appeared to be marked optic neuritis in the left eye; the right fundus was normal. As the condition did not change, pseudoneuritis was suspected, but on examination of the eye after death, an old perineuritis was found, with increase of the connective tissue of the papilla.

Harlan[8] reported a case of a man, aged 30, V. 20/16 — 3·40 in each eye, swelling of both O.D. of + 3 D. to + 4 D. marked striation of edges, papillæ of a dirty-grey colour, veins slightly enlarged and contorted, no other general symptoms: four months later appearances unaltered. Also a girl, aged 15, with headaches V.= 6/5, H. +1.50, fields normal, occasional vertical diplopia, lasting a few seconds, some dizziness. O.D. swollen 1.50 D.; margins indistinct and striated. With glasses, the headaches disappeared, but the fundus condition remained unchanged at the end of two months. In the discussion on this case Riseley said he had observed a patient with V.=6/6 in each eye, H. +1 D. + 1 D. cyl. ax. vert. with a +2 D. to +3 D. swelling of the disc. This condition remained unchanged at the end of twelve months.

Bristowe[9] described general blurring of the disc margins with marked striate radiations, some swelling of the edges and tortuosity of the vessels, in cases of hypermetropia (23·2 per cent.). The condition bore no relation to the hypermetropia present. He does not describe any definite swelling of the disc—and ascribes the appearances to the fact that hypermetropia is a condition of imperfect development. Sydney Stephenson[10] found some grade of blurring of the disc edges, without swelling, in 22·8 per cent. of cases examined, and although the majority were hypermetropic, yet some were myopes. The vision of all these patients was good.

It will be seen from these reported cases that there are various types of this puzzling condition, and if any knowledge is to be arrived at, it will be helpful if they can be divided up into classes. Clinically, two broad divisions can be made, namely, those discs which show signs of swelling and those which do not, and of these the former class may be grouped under the general heading of "pseudopapillœdema" and the latter under that of "pseudoneuritis." Salzer[11] divides the various forms of the condition into four classes, pseudoneuritis rubra, P. striata, P. hyperplastica, and P. prominens; but it seems to the writer that the previously suggested classification is simpler and quite sufficient for the purpose, because many of the types insensibly pass into each other, and it forms a good basis for classification. Considering the condition as a whole, it should be remarked there are never any of the concomitant signs of true neuritis, such as hæmorrhages or macular exudates, to be observed. In a large proportion the vision is normal, and if it falls below this standard, there is frequently an obvious cause to account for the amblyopia, such as a convergent strabismus, or the history of defective vision of long standing. Many of the patients complain of headache, which rather complicates the diagnosis, but in such cases the correction of refractive errors is usually

followed by relief. The retinal vessels, although very frequently twisted or contorted, are never engorged, and no marked difference between the size of the veins and arteries can be made out to the extent seen in true neuritis. Then, again, constitutional symptoms are absent.

Pseudoneuritis is by far the more common condition, and it presents varying appearances. Estimates of its frequency vary largely. Stephenson[10] and Bristowe[9] agree very closely, as they found the condition present in about 23 per cent. of their patients. On the other hand, Nottbeck[3] gives 0·214 per cent. as his average. The most probable explanation of this marked discrepancy is that the former two observers included very slight cases in their numbers, and, moreover, Stephenson's patients were all children, in whom it is much more common. Nottbeck, on the contrary, only included in his list marked examples of the condition, and these are certainly not frequently observed.

The most common form of pseudoneuritis is the striate variety, with slight blurring of the disc edges; this is frequently seen in hypermetropic patients and the appearance is probably caused by the retina in the small hypermetropic eye not being fully stretched out, thus causing minute radiating folds around the disc. In this connection it is interesting to note that Lindsay Johnson[12] has figured in his Atlas of the Mammalian Eye a radiate striation of the retina in various monkeys, a wild boar, and a skunk, which resembles pseudoneuritis to some extent. The same author also figures the fundus of a Nubian, which simulates these appearances closely. Salzer[11] found marked striation around the disc of a negro and a lemur. When it is remembered that this condition is found chiefly in less developed hypermetropic eyes, probably in most negroes and certain mammals, it suggests that this may be a reversion to another type of fundus. The other examples of pseudoneuritis present a greyish-red appearance of the disc, marked woolliness of its edge, tortuosity of the vessels, and some connective tissue adjacent to them at their origin. This type is not confined to hypermetropia, but is found in association with other refractive errors, or in emmetropia. Together with the striate variety, this is found at all ages, and is undoubtedly congenital. With few exceptions, the vision of these patients is good. The ophthalmoscopic appearances suggest that a portion of the embryonic "scaffold" tissue has escaped obliteration during development, a view further supported by the afore-mentioned connective tissue remains on the disc following the course of some of the larger vessels.

"Pseudopapillœdema" is much the more uncommon variety; it corresponds to the pseudoneuritis hyperplastica and prominens of Salzer. Elevation of the disc of the nasal side is frequently seen, and calls for no comment here, since it rarely gives rise to difficulty in diagnosis. When the whole papilla is enlarged and elevated, errors in diagnosis are possible, especially if, combined with striation radiating from the disc, the margin is undifferentiated and encroaches on the retinal area. In these fundi the vessels are always contorted, and sometimes the veins appear to be distinctly swollen.

The following case of "pseudopapillœdema" (*see* figure) has been under the writer's observation for eleven years.—Phoebe R. aged 34, had an operation for squint on the left eye when a child, and when first seen, R.V. 6/24 — .50 D— 2.D. cyl. ax. 60°. L.V. 2/60 lens no improvement. There was + 3 D. of swelling of the upper halves of both discs, the vessels were undilated, the enlargement slightly extending on to the retina; the level of the lower part of the disc was the same as the surrounding retina, which did not show any hæmorrhages or white exudates. The right field for white was contracted about 20° on the temporal and 10° on the nasal side; the left field was concentrically contracted about 30° but much more so in the

inferior nasal quadrant. For colours the contraction in the right field was in like proportion to that for white; in the left it is much greater. The condition is unaltered at the present time.

Optic neuritis was diagnosed, and she was put on various forms of treatment, but with no result. She complains frequently of occipital headache, which is relieved only by a seton in the neck.

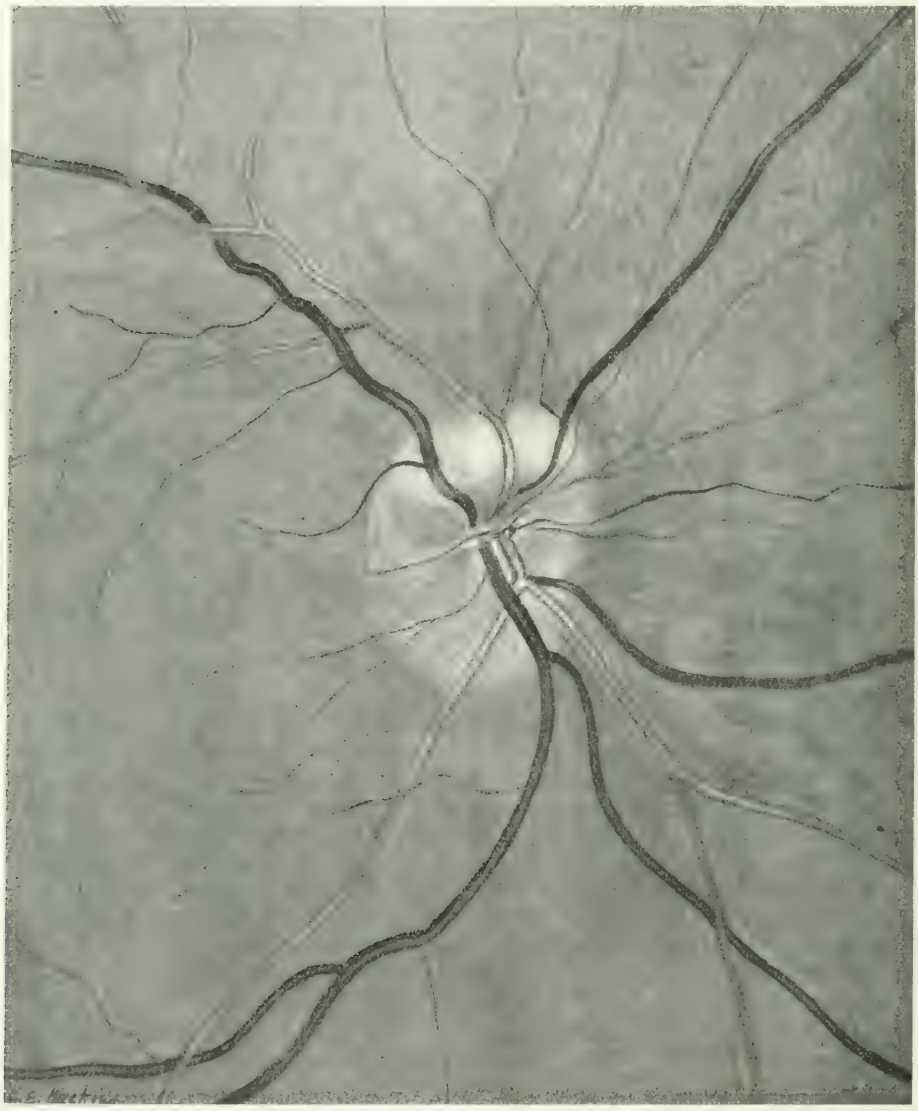

It is not easy to account for these mimicked inflammations of the optic disc. But, as shown, the striated appearance of pseudoneuritis is common in negroes and certain mammals, and so may be an atavastic tendency in these eyes, as suggested by Salzer.[11] The woolly edges occasionally associated with the above are unrepresented, as far as I know, in any vertebrate fundus. It is possible that the appearance may be due in a partial medullation of the nerve fibres. Stephenson[13] regards these cases as representing "a

congenital non-differentiation of the optic disc, a view supported by the frequent co-existence of shreds of connective tissue about the vessels on the papilla and also by the state of the retinal vessels." Salzer[11] says the streaked form of pseudoneuritis is more frequently seen in insane patients, a view which is interesting in connection with its appearance in lower mammalian types. It is unfortunate that up to the present time no anatomical examination has been reported of an eye in which the condition was observed during life. These cases have been described as "hypermetropic discs," on account of their supposed frequency in that refractive condition, but, as has been shown, with the exception of the striated variety, they are not confined to hypermetropia, and, moreover, do not vary in intensity in proportion to the refraction, correction of which has no effect on the ophthalmoscopic appearances (Stephenson). Indeed, many of the marked examples of pseudoneuritis occur in very low grades of hypermetropia or with no refractive error at all.

The only two anatomical examinations of pseudopapillœdema which I can find recorded are by Axenfeld[14] and Ormond,[15] but these showed the condition to be a true neuritis and not a mimesis. Upon this evidence, it seems probable that the cases of pseudopapillœdema are really enlargements of the optic nerve head due to a primary œdema which has persisted for many years, a view supported by certain symptoms which observers have noted in some of the cases recorded. For instance, Holmes Spicer's[6] patient complained of transient attacks of erythropsia and Nottbeck's[3] second patient also had suffered from what was probably chronic suppurative otitis media, as well as from enteritis, inflammation of the lungs, heart disease, and periostitis of the orbit. The writer's case detailed above has contraction of the visual fields, especially in the left eye. Furthermore, it is well known clinically that many cases of optic neuritis have normal vision. The absence of hæmorrhages, which has always been noted in these patients, may be accounted for on the supposition that absorption may have taken place before the ophthalmoscopic examination. If this assumption be correct, then the condition assumes a graver aspect, because we can scarcely look upon a chronic inflammatory state of such a delicate organ without misgiving. Such an hypothesis is quite feasible, because we have analogies in other parts of the body where an acute œdema may become chronic, and the part remain enlarged for many years. In a certain proportion of the reported cases of pseudopapillœdema, it has been noted that convergent strabismus was present; it is not easy to see, however, why this should be a causal factor, and the connection is probably fortuitous. In true papillœdema the disc is greatly swollen, as a result of œdematous liquid collecting between the nerve fibres in cystic spaces, and it is quite possible that this fluid may remain permanently, and never become absorbed. Such an explanation was advanced by Adams Frost and G. Hartridge, at a discussion on Holmes Spicer's[6] case, and "persistent optic neuritis" was suggested as a better name for the condition by Hartridge. In connection with this suggestion, it is possible that the good vision often associated with this state of persistent neuritis may be due to an abnormal development of cilio-retinal vessels which have escaped pressure in the lamina cribrosa; and that they are not uncommon was shown by Lang and Barrett,[16] who found cilio-retinal vessels at 17 per cent. in a series of cases examined ophthalmoscopically. They are present normally, in greater or lesser degree, in many mammals. In addition, also, the large complex space between the optic nerve and its pial sheath, with branches extending between the primary nerve bundles towards the centre of the nerve, as described by Nettleship[17] in the hog-deer and zebra, may be represented in these

" persistent " cases and be a factor in the chronicity of the swelling of the disc. An analogous condition of persistence, as suggested by Salzer[11], may be cited in the continuous pallor of the disc which is sometimes seen after severe hæmorrhage, when the vision, at first seriously affected, in course of time returns to normal, the pallor remaining unchanged. The case of hemi-papillœdema mentioned previously may be a true congenital condition, and is probably the reverse of the physiological cup ; the nerve-fibres being closely packed together in the upper part of the disc causing this area to be elevated. Collins and Mayou[18] suggest this hypothesis for pseudoneuritis generally.

The importance of pseudoneuritis is emphasized when the possibility of true neuritis being mistaken for it is considered. The previously quoted case of Axenfeld, is instructive ; also Stephenson[13] records another in a boy, who eventually died from a cerebral glioma. A. Natason, jnr.,[19] reported a case in a worker in a rubber factory, who exhibited signs of choked discs, without hæmorrages in the retina. The vision and other functions were normal. The patient was under treatment for ten months, and no alterations in the fundi were noted during this period. Drugs were discontinued, and the woman went to live in the country ; when seen one year later, however, the swelling had disappeared and the discs were merely slightly discoloured. There was no contraction of the field.

In conclusion, reviewing the causation of pseudoneuritis, we may say that the variety which shows no appreciable swelling is not uncommon, especially in children, and is almost certainly congenital ; whereas pseudo- or persistent papillœdema, with swelling of the optic disc, is, on the evidence available at present, not congenital, and most probably represents a persistent condition of œdema of the optic papilla, which for some reason does not interfere with the functions of the optic nerve.

REFERENCES.

1. **de Wecker et Jaeger.**—" Traité des Maladies du Fond de l'Œil et Atlas d'Ophtalmoskopie." (Nottbeck.)
2. **Galezoswky.**—" Traité Iconographique d'Ophtalmolopie," Pl. XI, Fig. 4. Paris, 1879. (Nottbeck.)
3. **Nottbeck.**—" Ein Beitrag zur Kenntniss der kongenitalen Pseudo-neuritis optica." v. Graefe's *Archiv*, Bd. XLIV.
4. **Dobrowolski.**—" Diffuse Netzhautentzündung bei hochgradiger Hypermetropie." *Klin. Monatsbl. f. Augenheilk.*, 1881. (Nottbeck.)
5. **Gunn, Marcus.**—*Transactions of the Ophthalmological Society U. K.*, Vol. XV, p. 136.
6. **Spicer, Holmes.**—*Transactions of the Ophthalmological Society U. K.*, Vol. XVI, p. 134.
7. **Brewerton, E. W.**—*Transactions of the Ophthalmological Society U. K.*, Vol. XXVI, p. 122.
8. **Harlan, C. G.**—*Transactions of the American Ophthalmological Society*, Vol. III, p. 731.
9. **Bristowe, H. C.**—" Ophthalmoscopic appearances of Hypermetropia." *Ophthalmic Review*, 1891.
10. **Stephenson, Sydney.**—*Reports of the Society for the Study of Disease in Children*, 1903.
11. **Salzer.**—*Münchener med. Wochenschrift*, 1911.
12. **Johnson, Lindsay.**—" Comparative Anatomy of the Mammalian Eye." *Philosophical Transactions of the Royal Society*, 1901.
13. **Stephenson, Sydney.** – " Eye-strain in Everyday Practice," 1913.
14. von Graefe's *Archiv f. Ophthalmologie*, Bd. XLIV, 1897. (Nottbeck.)
15. A personal communication kindly made to the writer.
16. **Lang and Barrett.**—*Royal London Ophthalmic Hospital Reports*, Vol. XII.
17. **Nettleship.**—*Transactions of the Ophthalmological Society U. K.*, Vol. XXV, p. 352.
18. **Collins and Mayou.**—" Pathology and Bacteriology," 1911, p. 2.
19. **Natanson, A., Junr.**—*Klin. Mon. für Augen.*, 1909, Bd. VII.

PATHOLOGICAL AND CLINICAL MEMORANDA.

A PATHOLOGICAL REPORT UPON A CASE OF DOYNE'S CHOROIDITIS ("HONEYCOMB" OR "FAMILY" CHOROIDITIS.)*

BY

E. TREACHER COLLINS, F.R.C.S.,

SURGEON TO THE ROYAL LONDON OPHTHALMIC HOSPITAL.

IN sections through the posterior part of the eyeball in the region of the macula and optic disc are seen the following changes.—Situated between the retina and choroid is a new formation of a hyaline substance. It commences on each side of the optic disc close, to its margin, and extends inwards from it about a distance of two discs' breadth, and outwards a distance of six discs' breadth. Its external surface has a regular contour following the natural curve of the choroid. Its inner, or retinal surface, presents several rounded nodular elevations with depressions between them. The thickness of the hyaline substance varies therefore considerably in different parts. It shows in places very definite lamination and for the most part is entirely free from cells, although here and there a cell with a flattened nucleus is seen embedded in it.



The choroid external to the hyaline tissue shows marked thinning, and in places complete absence, of its internal capillary layer. The vessels of the outer layer appear, however, abnormally large, but their walls are not thickened. In the choroid on the outer side of the optic disc there is a small area of round cell exudation, but apart from this, there are no signs of inflammatory disturbance. Where the hyaline substance is present, the elastic lamina of the choroid or membrane of Bruch cannot be satisfactorily differentiated. At the periphery of the hyaline substance, on each side, the pigment epithelium can be seen extending for a short distance over its inner surface as a single layer of cells. Large parts of the inner surface of the hyaline substance are, however, devoid of any lining of pigment epithelium, whilst here and there irregular collections of pigment epithelial cells are met

* Microscopic sections shown at the Oxford Ophthalmological Congress, July, 1913.

with. The outer surface of the retina has become much disorganised by the formation of the hyaline tissue. The rod and cone layer has become entirely destroyed where it is situated, also to a very large extent the outer nuclear layer. In places the rounded ends of the nodules of hyaline substance are in contact with the inner nuclear layer. In some localities the granular layers are thickened, the fibres crossing them being stretched out with spaces between them. The inner layers of the retina show but little change.

Remarks.

The hyaline substance in these sections presents the same histological appearances and staining reactions, as the nodules of hyaline commonly met with in a similar situation in many degenerative conditions of the choroid. Such nodules are often termed "*Drusen*." The hyaline continuous substance in this specimen is peculiar in forming such a long layer. In other conditions it is usually in the form of isolated nodules. The ophthalmoscopic changes, known as "Tay's Choroiditis," are generally regarded as being due to such nodules. Many different views have been put forward to account for the formation of these hyaline nodules. They have the same characteristics as the elastic lamina of the choroid, and it seems probable that they are, like it, the product of the pigment epithelial cells. Some of the hyaline tissue in this specimen looks very like a number of super-imposed layers of the elastic lamina. Further, it seems likely that the primary change was in the pigment epithelium, and that the changes in the choroid and retina around are secondary to the pressure caused by the formation of the hyaline substance.

AN OPERATION FOR ECTROPION OF THE LOWER LID.*

BY

A. F. MacCallan, M.D.Camb., F.R.C.S.Eng.,

DIRECTOR OF THE EGYPTIAN GOVERNMENT OPHTHALMIC HOSPITALS.

Ectropion of the lower lid is not unfrequently seen in Egypt in trachomatous patients. In these cases the tarsal "cartilage" is displaced, so that its normal vertical axis comes to lie horizontally immediately underneath the conjunctiva. Between the attachment of the cartilage to the orbito-tarsal fascia and the globe the conjunctiva is usually found to be prominent, cicatrized, and thickened. The fornix has almost disappeared in most cases.

The operation consists in the removal of the tarsus and in the formation of a fornix. The details follow :

The lid spatula is placed below the eyelid to be operated on, the border of the lid is seized by the assistant with forceps and still further everted on the spatula.

(1) A horizontal incision is then made through the conjunctiva throughout the width of the eyelid about 5 or 6 millimetres from the margin of the lid, that is, in the situation in which it is desired to make the new fornix : an incision is made at each extremity of the first incision to unite it with the inner and outer canthi, stopping short 1 or 2 millimetres from the lid margin.

(2) The conjunctiva is then dissected from the subjacent fascia and "cartilage" as far as the margin of the eyelid.

*Demonstrated at the Oxford Ophthamological Congress, July 17th, 1913.

(3) The "cartilage" is then removed with scissors, together with as much redundant conjunctiva as is considered advisable.

(4) A threaded needle is entered from the skin surface five millimetres below the lashes, passed through the tissue of the lid and through the anterior edge of the conjunctiva. It is then passed forwards through the posterior edge of the conjunctiva, coming out of the skin near to the point of entrance of the needle. Three such sutures are inserted and tied loosely.

The result of this operation for the condition described is remarkably good. The stitches may be removed on the fourth or fifth day. It is, of course, important that the skin should be carefully sterilised with tincture of iodine, and that non-absorbent material, such as silk-worm gut, should be used for the sutures.

NOTES ON THE NEW OPERATIVE TREATMENT OF GLAUCOMA.

BY

G. LINDSAY JOHNSON, F.R.C.S.

JOHANNESBURG, SOUTH AFRICA.

DURING the past two years I have invariably performed the following operation whenever the tension is increased after an iridectomy had been performed.

The *technique* is extremely simple, and anyone accustomed to ophthalmic surgery can perform the operation without difficulty. After cocainizing and disinfecting the eyeball, I fix the eye with a speculum and toothed forceps. I insert a small bent keratome through the conjunctiva and sclerotic, 3 mm. external to the sclero-corneal junction, and then after lowering the handle, push the point forwards past the angle, splitting the cornea until the point just passes through the back of it, and can be seen projecting for about 2 or 3 mm. into the aqueous in front of the iris. On withdrawal of the knife only a very small amount of aqueous escapes; often none at all. In this way an opening is made from the outside into the aqueous chamber, extending from about 6 mm. wide at the base to 3 mm. where it enters the chamber.



I then insert the solid blade of the punch as far forward as is deemed necessary, but always extending past the angle into the cornea, and punch a piece out, exactly 2 mm. in width and from 2 mm. to 5 mm. long. Should the hole appear too narrow, a second piece can be punched out on one side of the first, so as to extend the width to 3 mm. or even to 4 mm. But this is rarely necessary.

The wound is then washed with a stream of warm boiled saline solution, and smeared over with a mixture of equal parts of pure liquid paraffin and vaseline, previously boiled. A compress of cyanide gauze placed over the lids completes the treatment.

In my opinion, this instrument performs its work quite as effectively as Smith's trephine or Bardsley's sclerotome, and allows of far greater latitude on the part of the operator, since one can make a clean cut of any size one pleases. Besides, it has the great advantage of extreme simplicity, combined with the least possible risk of injuring the neighbouring parts.

I append a drawing of the instrument, which was made for me, over two years ago, by Walb, of Heidelberg. It costs about 35 marks.

NOVELTIES.

A HAND PERIMETER.

MESSRS. C. W. DIXEY & SON, of 3, New Bond Street and 20, Welbeck Street, W., have produced a portable hand perimeter, similar in design to pre-existing instruments, but with certain modifications suggested by Dr. R. Beatson Hird, of Birmingham. The handle is detachable, and the whole may



be carried in an ordinary handbag; the fixation point is a white spot 10 mm. in diameter, which can easily be seen by presbyopes. Weight is reduced by making the metal parts of aluminium, and vulcanite is employed where the instrument comes in contact with the face The workmanship is excellent, and the cost moderate (21/- with a book of 100 charts).

CURRENT LITERATURE.

NOTE.—Communications of which the titles only are given either contain nothing new or else do not lend themselves to abstract.

I.—THE NOGUCHI AND THE WASSERMANN REACTIONS.

(1) **Cohen, M.—Noguchi's cutaneous luetic reaction and its application in ophthalmology.** *Archives of Ophthalmology*, January, 1911.

(2) **Mouradian,—On the practical value of the Wassermann reaction in ophthalmology.** (De la valeur pratique de la réaction de Wassermann en ophtalmologie.) *Ann. d'Oculistique*, janvier, 1912.

(3) **Abadie, Charles.—Some reflections on the Wassermann reaction.** (Quelques réflexions sur la réaction de Wassermann.) *La Clinique Ophtalmologique*, 10 mai, 1912.

(4) **Danis, M.—Wassermann's reaction in affections of the eye.** (Résultats de la réaction de Wassermann dans les affections oculaires.) *Bull. de la Société Belge d'Ophtal.*, No. 34, 1913.

(1) "Luetin" is an extract of pure cultures of dead spirochaetæ pallidæ. **Cohen** has injected this intra-dermatically into 50 non-syphilitic individuals, with 94 per cent. negative results. The 6 per cent. positive results were mild and atypical. The test would therefore seem to be of considerable negative value. He then injected "luetin" into 60 ophthalmological cases, and the results were compared with those of the Wassermann test and with the clinical evidence. The cases included chiefly interstitial keratitis and also kerato-iritis, acute iritis, optic neuritis, orbital tumour, retinal detachment, etc. In 76 per cent. of these cases, the skin test accorded with either the clinical evidence or the Wassermann reaction, or with both these. Cohen therefore thinks that a positive luetin reaction furnishes strong presumptive evidence of syphilis. The luetin test was positive in ten cases regarded clinically as syphilitic, in which, presumably because of previous antisyphilitic treatment, the Wassermann reaction was negative. Thus far the test has been absolutely harmless in 170 cases which were inoculated in five months. The positive reaction shows itself by a papule appearing usually within 6 to 24 hours, but occasionally as late as eight days, surrounded by a bluish-red halo. The papule is from 5 mm. to 20 mm. in diameter, and develops in the majority of cases a central area of suppuration, bacteriologically negative. On rupture of this pustule, a hypertrophic condition of the skin supervenes, which persists. The tests were controlled by simultaneous injections of uninoculated culture media in the other arm.

ROSA FORD.

(2) **Mouradian**, of Paris, has analysed the statistics of 1,214 ophthalmic cases, including 245 under his own observation at the Lariboisière Hospital, in which the Wassermann reaction has been investigated, and has formed the opinion that owing to the accuracy with which the ætiology of syphilitic eye diseases has been clinically determined, the reaction is not of so much value in ophthalmology as in internal medicine. Interstitial keratitis appears to him to be the only ocular disease in which the specific origin has been confirmed by the sero-reaction, while the fact that negative reactions have been obtained in a large number of cases of choroiditis and retinitis does not prove that syphilis is rare as a cause of these diseases. In the 245 cases examined by himself, the author found the percentage of positive reactions when the diagnosis of syphilis was "positive," "probable," and "doubtful" to be respec-

tively 70, 45, and 23. He therefore considers that a negative reaction is of no practical significance, but a positive reaction should be regarded as of great importance, although not sufficient to justify the renewal, or continuance, of treatment in the absence of any other manifestations of the disease.

R. J. COULTER.

(3) The "reflections" of **Abadie**, of Paris, resolve themselves into a caution against relying too absolutely and to the exclusion of other means of diagnosis on the reaction of Wassermann, or as he prefers to call it, the "complement reaction," in settling the question whether syphilis does or does not exist in a given case. The reaction should be regarded rather as a valuable auxiliary than as something which takes the place of all the elements of diagnosis which are furnished by clinical observation. It has many times happened in his practice, says Abadie, to prescribe mercurial injections for patients from the country who must return forthwith. To their great loss, however, the medical attendant has refused to use the treatment, on the ground that there were no syphilitic antecedents. He asks, therefore, if there is not reason to fear that in the presence of a negative Wassermann, this reluctance to the application of mercurial treatment, and especially of salvarsan, will tend to increase.

ERNEST THOMSON.

(4) **Danis**, of Brussels, publishes the results of the sero-diagnosis of syphilis in 106 patients under the control of Gallemaerts, of the same city. It may be noted that among 27 cases of interstitial keratitis, 21, or 79 per cent., yielded a positive reaction. For purposes of comparison, Danis quotes the following figures:

Wolff ...	...	14	cases	10	reactions +	4	reactions —	71 per cent.
Fleischer	...	8	,,	7	,,	1	,,	88 ,,
Hessberg	...	44	,,	36	,,	8	,,	82 ,,
Fleischer	...	40	,,	46	,,	4	,,	93 ,,
Glantz...	...	64	,,	59	,,	5	,,	92 ,,
Schumacher	...	28	,,	23	,,	5	,,	92 ,,
Cohen ...	...	38	,,	24	,,	14	,,	63 ,,
Silbersiepe	...	100	,,	15	,,	151	,,	85 ,,
Zade ...	..	19	,,	18	,,	1	,,	95 ,,
Franke	...	20	,,	19	,,	1	,,	95 ,,
Leber ...	...	82	,,	61	,,	21	,,	74 ,,
Mouradian	...	33	,,	22	,,	11	,,	66 ,,
Total	...	500	,,	410	,,	90	,,	82 ,,

SYDNEY STEPHENSON.

II.—INFRA-NUCLEAR PARALYSIS.

Brandenburg, Fritz.—The typical partial infra-nuclear paralysis of the third cranial nerve in abscesses and tumours of the temporal lobes. (Ueber die typisch-partiellen Stammlähmungen del Okulomotorius bei Abszessen und Geschwülsten im Schläfenlappen.) Deutschmann's *Beiträge zur Augenheilkunde*, Heft xxxi, 1912.

Brandenburg reminds us that the familiar statement that a partial paralysis of the third nerve is always due to a nuclear lesion is inaccurate.

Exceptions have been reported from time to time, but the question was first fully discussed by Körner in 1894. His conclusions were: (1) That abscesses of the temporal lobe originating in the ear often paralyse the third nerve of the same side. (2) That the paralysis is almost always partial, those fibres which innervate the levator palpebræ superioris and the sphincter iridis being first affected; that is to say, that in the first place mydriasis or ptosis, or both, make their appearance, and the other ocular muscles are involved later, if at all. (3) That this typical form of paralysis is not of nuclear origin, but arises from a trunk lesion. Paralysis due to a nuclear lesion has not the typical form. In it the involvement of the muscles does not follow any regular sequence. Another point to bear in mind is that the nuclear region belongs to the posterior fossa of the skull and is protected by the firm tentorium from pressure exercised by the temporal lobe, while the trunk of the third nerve, for about 2·5 mm. of its length, lies against the median wall of the middle fossa and is subject to direct pressure from the affected lobe. Damage by such pressure is particularly apt to occur where the nerve lies against the edge of the dorsum sellæ. The fourth, sixth, and fifth nerve in the same situation are better protected by soft parts, and are therefore not so liable to be involved. Since cerebral abscesses of otitic origin almost invariably arise in the neighbourhood of the tegmen tympani, they may be expected to exercise pressure in a fairly regular manner on the structures in the neighbourhood, and therefore to produce quite typical symptoms. In the case of tumours of the temporal lobes the conditions are different. Tumours are less uniform in their situation and in their manner of growth, and the topical diagnosis is apt to be confused by the presence of distant symptoms due to interference with the corpora quadrigemina, etc., and with structures on the other side.

The practical value of such a law as that propounded by Körner, should it become established, is obvious, and Brandenburg's review of forty-five cases of temporal abscess from the literature seems to show that its value as an aid to diagnosis has not been exaggerated Eleven of these cases had ptosis, twelve had mydriasis, thirteen had ptosis and mydriasis, three had paralysis of the levator, sphincter, and internal rectus, one had paralysis of the levator, sphincter, and internal and superior recti, five had complete third nerve paralysis. Thus, in thirty-six of the cases there was paralysis involving only the levator or the sphincter or both. In cases where more than two muscles were paralysed, the levator and sphincter were always involved, and one or other of them was always first affected. This quite bears out Körner's description of the typical paralysis. It is, of course, to be understood that all cases were excluded in which the abscess was complicated with meningitis, which introduces confusion by the production of crossed symptoms.

Coming to the question of tumours in the temporal lobe, the available cases include ten published by Albert Knapp in 1905, and ten others from the literature. Knapp found in his cases that the third nerve was very often implicated; indeed, in those cases observed until death, third nerve affections were never absent. He concluded that a late, transitory, partial, recurring third nerve paralysis, especially an ipsolateral ptosis or mydriasis with disturbance of the pupillary reactions, is most often found in tumours of the temporal lobes. Brandenburg's investigation of the other ten cases supports this view.

It is admitted that it is unusual for pressure exerted on a nerve trunk to affect certain fibres in preference to others, but examples are found in conditions involving pressure on the recurrent laryngeal nerve, and in the special failure of the papillomacular bundle in retrobulbar neuritis, as well as

in the isolated peroneus paralysis due to injury of the sciatic nerve trunk. We are forced to assume a lower degree of resistance on the part of the selected fibres. No very satisfactory explanation for this difference of resisting power has been offered, but it is suggested that it might be explained on Edinger's theory, that the fibres which are in most constant action are the ones most liable to suffer. A. J. BALLANTYNE.

III.—FLUORESCENCE OF THE CRYSTALLINE LENS.

(1) Vogt, A. Analytical researches on the fluorescence of the human lens and of the lens of the ox. (Analytische Untersuchungen über die Fluorescenz der menschlichen Linse und der Linse des Rindes.) *Klin. Monatsbl. f. Augenheilkunde*, Februar, 1913.

(2) v. Sepibus, J.—Experimental researches upon the fluorescence of the human lens. (Experimentelle Untersuchungen über die Fluorescenz der menschlichen Linse.) *Zeitschrift für Augenheilkunde*, Mai, 1913.

(1) **Vogt**, of Aarau, states that the fluorescence of the lens is not always of the same whitish-blue colour, but varies according to a number of conditions. He has conducted a series of experiments on the fluorescence of the human lens at different ages, both *in vivo* and after extraction, and of the lenses of the calf, ox, and cow.

The following are some of the results arrived at :—

(1) When the fluorescence of these lenses is excited by exposure to ultra-violet light, the fluorescent light is of a whitish-blue colour, which contains all the spectral colours from violet to red. This colour is modified to a yellowish-green when it has to pass through a yellow coloured lens substance, the blue and violet components of the fluorescent light being thereby reduced in intensity. The degree of this influence depends on the intensity of the yellow colour of the lens, the thickness of the yellow substance, the intensity of the fluorescence, and the intensity of the ultra-violet light used.

(2) Violet light produces fluorescence only in yellow coloured lenses. Colourless lenses, like those of the calf, do not fluoresce in violet light, while the human lens always has a yellow colour, even in early life, and therefore fluoresces in violet light. The fluorescent light excited by violet is of green to yellow-green colour. Spectroscopically, it contains no ultra-violet rays.

(3) The fluorescence excited by blue light is weaker than that from the ultra-violet. It requires a more intensely yellow colour in the lens than that from the violet. Spectroscopically, it contains neither violet nor ultra-violet.

(4) The yellow colour of the lens can be observed entoptically on illumination of the eye by ultra-violet light.

(5) The fluorescence of the lens provides an objective proof of the presence of the lens in cases where the presence of pupillary exudate makes the familiar tests of no avail. A. J. BALLANTYNE.

(2) **v. Sepibus**, of Aarau, has carried out a research upon the nature of fluorescence in the human lens. Fluorescence is the change of light rays from one wave length to another, and Stokes' law states that the change is generally from a shorter to a longer wave length. Brucke, Helmholtz, and Schulek have interested themselves in the subject of the fluorescent qualities of the lens. The latter pointed out that the lens of healthy individuals filters off all harmful ultra-violet rays, and so protects the retina from the deleterious

action of such rays. In children the retained rays show themselves by fluoresence of the lens, but in the aged there is no fluorescence; the ultra-violet rays are converted into heat rays. The author notes in the literature of the subject some differences in the opinions expressed as to the exact colour seen in the fluorescent lens. Helmholtz says it takes the same tint as a solution of quinine. Schanz and Stockhausen note a lavender-green fluorescence. The cause of these discrepancies is due to the fact that each writer upon the subject had adopted a different method to induce fluorescence. v. Sepibus used a Schott uviol glass plate, 6 mm. thick, which absorbs all light except ultra-violet, violet, blue, and a little red. Hs also tried Lehman's U.V. filter, which contains blue uviol glass, nitro-sodium, methylanilin, and a solution of copper sulphate. This filter practically allows only ultra-violet rays to pass. A Finsen apparatus was used as a source of light in which the arc is produced between iron-containing carbons—a light exceedingly rich in ultraviolet rays.

The author found that with the U.V filter (ultra-violet) the fluorescence of the human lens was very slight, although discernible; it had a blue tinge. The visible part of the spectrum which passes the filter causes a yellowish-green fluorescence. Using the uviol glass filter, he obtained a greenish-yellow fluorescence, which was more markedly observed in old than in young lenses. The swollen lens seen in traumatic cataract did not fluoresce in this light. The aphakic eye did not exhibit the fluorescence.

T. HARRISON BUTLER.

IV.—ECLIPSE-BLINDNESS.

(1) **Cords, R.—Eclipse blindness. (Sonnenblendung.** *Zeitschrift für Augenheilkunde*, Juni, 1912.

(2) **Vinsonneau. — Scotoma by solar eclipse and macular lesion. (Scotome par éclipse solaire et lésion maculaire.)** *Archives d'Ophtalmologie*, septembre, 1912.

(3) **Valois et Lemoine.—Visual disorders following direct observation of the last solar eclipse. (Troubles visuels consecutifs à l'observation directe de la dernière éclipse soleil.)** *Revue Générale d'Ophtalmologie*, 30 septembre, 1912.

(1) The recent eclipse on April 17th, 1912, has furnished **Cords**, of Berlin, with sufficient cases to write a paper on the subject of eclipse-blindness. He has taken the trouble to have a coloured plate made which represents the appearance seen in six of the eyes he examined. Only two other ophthalmologists have made drawings of the conditions seen on the macula after exposure to strong sunlight, *viz.*, Ruete and Dufour-Gonin; there is also a drawing of an atypical case by Zirm. Some of Cord's drawings are very similar to some representing the normal macula which appeared in the first edition of Axenfeld's Text-Book, but then it is exceedingly difficult to get a good reproduction of a drawing of the macula by the ordinary process.

The cases fall into three groups:—

(1) After-image effects, which vanish at the latest by the next day.

(2) Typical alterations in vision (positive central scotoma):—(a) with changes at the macula; (b) without macula changes.

(3) Atypical cases.

The mild cases with after-image effects see yellow and blue spots, and have symptoms analagous to the erythropsia which appears after exposure to dazzling lights.

The cases with more severe symptoms had definite deterioration of central vision associated with a central scotoma, which was generally positive. The macular changes were varied, as shown in the plate, but in the majority the macula was surrounded by a dark-red ring. In two cases the deep-red macula was surrounded by a large oval bright halo. Other maculæ were simply a darker red than usual. In general, the visual acuity was only slightly reduced, because the paracentral area of the retina was used for reading, but in some cases it was only 6/36. Generally, Jaeger I was read, but with much effort, because the letters looked at became indistinct.

The prognosis must be exceedingly guarded. The only favourable cases are those in which ophthalmic changes are absent. In some cases the positive scotoma vanishes but central vision does not return, and other patients are worried for months with the dark spot and with scintillating scotomata. In one case this latter symptom lasted forty-five years.

According to most authorities, fundus changes are the exception or are very slight. A white round patch in the centre of the fovea is often seen, but vanishes after a few days. Dufour regards it as an optogram of the sun's image on the retina.

More severe cases have been described in which the vision was reduced to eccentric finger counting. Well-marked optic neuritis has been described, and others have noted macular hæmorrhages. These cases must be regarded with some scepticism, as must those in which retinochoroiditis, embolism of the central artery, and retrobulbar neuritis have been ascribed to the action of the sun's rays. The paper includes a bibliography of the disease.

T. HARRISON BUTLER.

(2) **Vinsonneau**, of Angers, describes a case of scotoma helieclipticum, the interesting points of which were :—impairment of the right pupillary reaction to light and accommodation, the presence of slight retinal clouding around the papilla, and a whitish disc, surrounded by a reddish zone, at the macular region ("solar optigram"). The patient was a man with normal eyes, who had gazed at the 1912 eclipse for periods of five minutes at a time over a space of one and three-quarter hours. He had used the right eye alone unprotected by a glass, but partially shielded by looking through the right hand closed like a trumpet. Symptoms began in six hours, and the following morning there was a positive scotoma in the right eye, with reduction of vision to two-tenths. After some months, the vision had improved only to four-tenths, and the whitish disc at the macula persisted, although the surrounding zone of red and the peripapillary clouding had disappeared. BERNARD CRIDLAND.

(3) **Valois** and **Lemoine**, of Nevers, have tabulated in a useful way the symptoms and course of eighteen cases of disturbance of vision following the solar eclipse of 1912. ERNEST THOMSON.

V.—WORD-BLINDNESS.

Hinshelwood, James.—The treament of word-blindness, acquired and congenital. *British Medical Journal*, October 19, 1912.

The article by **Hinshelwood**, of Glasgow, impresses upon us all once more the duty we owe to the congenitally word-blind child. The old idea was that nothing could be done for cases of word-blindness, but we now

know, both in acquired and congenital cases, that much can be done in the treatment if conducted on proper lines. The treatment consists, of course, in the method of education, or re-education, as the case may be. It was the success which attended the re-education of those rendered word-blind by disease that encouraged one to persevere in the education of the congenitally word-blind child. The child must not be educated in class (not even, according to Hinshelwood, in special class), on account of the discouragement produced by the ridicule of other children. There are two methods of teaching these cases, namely, the "look and say" method and the spelling aloud method. Hinshelwood considers that where the auditory memory is good, perseverance in the spelling method will ultimately lead to the child being able to read without spelling. Where the auditory memory is defective, the attempt to teach the child to spell is only increasing the difficulties of the task. We are then attempting to educate two defective memory centres instead of concentrating attention upon one. In such cases Hinshelwood approves of the "look and say" method, by which the child is taught to recognise printed words as a whole. In any case the lessons should be short and frequent rather than long and single each day. Whether we are dealing with the acquired or the congenital variety the brain becomes exhausted in a comparatively short time, because the effort of concentration required is much greater than in normal education. ERNEST THOMSON.

VI.—ARCUS JUVENILIS AND ARCUS SENILIS.

Attias, G.—Arcus juvenilis and arcus senilis. (Arcus juvenilis und arcus senilis corneæ.) *Zeitschrift für Augenheilkunde*, Dezember, 1912

Attias, of Munich, draws attention to the essential differences between an arcus in a young and an old individual.

In tabular form they are as follows:—

ARCUS SENILIS.	ARCUS JUVENILIS.
The opacities are generally bilateral.	The opacities may be unilateral.
The opacities are mostly symmetrical and equally large in each eye.	The opacities are generally asymmetrical and unequal in both eyes.
When the arcus does not form a closed ring, but consists of two segments. then, as a rule, the upper one is the larger.	A closed ring is rarely seen; if two arcs are present, the lower one is usually the larger. The two arcs also lie obliquely.
A single arc is almost always above the cornea.	The exactly opposite is the case. The arc is generally single and below.
The margin is ill-defined towards the cornea.	The margin is sharp on both sides.
Simple focal illumination makes the arcus appear to lie deeply in the cornea.	The same method makes it appear superficial.

Some badly reproduced photographs should demonstrate the appearance generally seen. T. HARRISON BUTLER.

VII.—PARINAUD'S CONJUNCTIVITIS.

Verhoeff, F. H.—Parinaud's conjunctivitis: a mycotic disease due to a hitherto undescribed filamentous organism. *Archives of Ophthalmology*, July, 1913.

There is a modern tendency to regard Parinaud's conjunctivitis as due to infection with the bacilli of bovine tuberculosis.

Verhoeff, of Boston, U.S.A., describes in the present communication, however, a peculiar filamentous organism (classed provisionally as a leptothrix), which his investigations lead him to regard as the cause of the affection. His experiences are based upon the examination of twelve cases, which presented nothing unusual from the clinical point of view. The characteristic histological feature was the occurrence of focal areas infiltrated with discrete endothelial phagocytes in varous stages of necrosis. They lay, as a rule, just beneath the epithelium, were usually about 0·3 mm. to 0·5 mm. in diameter. In some instances many sections had to be stained before they could be recognised. The areas in question included a few lymphoid and plasma cells, but practically no pus cells, and by special methods of staining, a small amount of fibrin could usually be made out in them. The tissues surrounding the areas of necrosis were densely infiltrated with plasma cells, but lymphocytes, eosinophiles, and mast cells, on the other hand, occurred only in small numbers. The changes described by Verhoeff were well brought out in specimens hardened in ten per cent formol and stained with haematoxylin-eosin.

Verhoeff has found in the areas of cell necrosis described above, when stained with thionin-blue, numerous bluish masses, which when examined in strong daylight with an oil immersion lens, were seen to be composed of collections of minute filamentous micro-organisms. They were recognised in sections of ten of the twelve cases investigated, and in one case, where they could not be found in sections, they were demonstrated in scrapings from the tissue. In the twelfth case, where results were negative, the material was insufficient for the purpose.

Technique.—Zenker gave better results than formol fixation. The hardened tissue was put in absolute alcohol overnight, and was then placed on a cover-slip, kept moistened with absolute alcohol, and its cut surface was scraped with a knife. The scrapings were allowed to dry on the cover-slip, which was then stained either with carbol-thionin or by Wright's modification of Leishman's stain. A still better plan is to employ Gram's stain as modified by Verhoeff himself. The essential difference between it and the ordinary Gram's stain lies in the preliminary treatment of the sections with xylol-balsam, and subsequent incomplete removal of the balsam by treatment with xylol, chloroform, alcohol (95 per cent.), and water.

The leptothrix described by Verhoeff was (except in one case) found in the close neighbourhood of the areas of cell necrosis, where it occurred in irregular masses, measuring from 10μ to 60μ in diameter. The filaments were simply intertwined about each other, without any more definite arrangement. At almost regular intervals along the delicate individual filament were round dots, which stained deeply when the modified Gram method is employed. Some of the longer filaments appeared either to become attenuated towards their ends or to stain less intensely. No branching of the filaments could be made out.

Now that the morphology and staining reactions of Verhoeff's leptothrix are known, its cultivation on artificial media should speedily be accomplished, and the experimental production of the disease, especially upon monkeys, should be undertaken. SYDNEY STEPHENSON.

VIII.—CYCLIC AFFECTIONS OF THE THIRD NERVE.

(1) **Salus, Robert.—Paralysis of the third cranial nerve with abnormal cyclic innervation of the internal branches.** (Okulomotoriuslähmung mit abnormer zyklischer Innervation der inneren Aeste.) *Klin. Monatsbl. f. Augenheilkunde*, Juli, 1912.

(2) **Greeves, R. A.—Case of partial oculomotor paralysis, with synchronous clonic contractions of muscles supplied by the third cranial nerve.** *Proceedings of the Royal Society of Medicine*, December, 1912.

(1) In the case reported by **Salus**, of Prague, the symptoms of a total third nerve paralysis were present. At intervals of about one and a half minutes, there was sudden elevation of the upper lid and contraction of the pupil. After ten to thirty seconds, the lid and pupil returned to their former condition. If the eyes were turned into any position other than that of rest, the intervals between the cycles were shortened. During the spasms, the refraction of the eye was increased by 3 D. The other eye, which was quite normal, took no part in the phenomena described.

The case belongs to the class which Axenfeld has distinguished as "Congenital cyclic affections of the oculomotor nerve," for which Salus would prefer to substitute the name contained in the title to his paper. We are here dealing with a paralysis of the pupillary sphincter and ciliary muscle, but only a paralysis to normal physiological stimuli (light, convergence, etc.), while there are other influences, mostly voluntary impulses to the extrinsic muscles, which are capable of producing a "reaction" of the pupil. This indicates an analogy with the familiar cases of "associated movements"—for example, of the upper eyelid in a case of ptosis, when the eye is adducted. Until recently it was generally assumed that in such cases the lesion must be a nuclear one. Some researches of Lipschitz, however, point to another possible explanation, which is developed by Salus. The idea underlying this explanation is that when regeneration occurs after a nerve lesion, the new axis cylinders growing from the central end of the nerve may wander into tracts to which they do not belong, and thus lead to an abnormal distribution. Salus assumes that at the point where the fibres of the third nerve are emerging from the base of the brain, the fibres which are to supply the intrinsic muscles are situated in the median aspect of the nerve. If now a lesion occurs at this point which causes a total paralysis of the third nerve, it may happen that, when regeneration occurs, the external fibres going to the extrinsic muscles are forced, by the presence of a cicatrix, for example, to traverse the peripheral tract proper to the fibres of the intrinsic muscles. It would thus come about that, although the intrinsic muscles are paralysed as regards physiological stimuli, they would contract on the transmission of stimuli intended for the extrinsic muscles. Something of this sort is assumed to have occurred in the case under discussion, the aberrant fibres having become related to the levator palpebræ and the internal muscles. The explanation of the rhythm and automatism of the abnormal movements seems to be that impulses are constantly passing out to the periphery, but that the presence of an interference with the conductivity of the centrifugal paths leads to a summation and rhythmic discharge of these stimuli.

A. J. BALLANTYNE.

(2) The case reported by **Greeves**, of London, is as follows:

A healthy girl, aged 8 years; eight other children all healthy. Drooping

of the left eyelid noticed since an attack of measles a year ago; until then the left eye appeared the same as the right. The left eye does not close fully during sleep. Right eye vision = 6/6, pupil reactions normal, consensual light reaction present. Left eye vision 6/6, with + 2 D. = 6/24. Partial ptosis. The eye cannot be moved inwards beyond the middle line; upward and downward movements absent; outward movement good; slight downward and outward movement preserved. The following series of movements occur rhythmically and synchronously: (1) the drooping lid is raised, after a few preliminary tremulous movements; (2) the eye is moved inwards to the middle line; (3) the pupil contracts fully; (4) a spasm of the ciliary muscle occurs, the refraction of the eye becoming about 3·5 diopters more myopic. The lid then drops, the eye moves out, the pupil dilates, and accommodation is relaxed. The cycle of movements is then repeated. This cycle has been timed, and the time has been found to vary on each occasion. But the contraction stage of the cycle has always been found to last exactly as long as the time taken by the rest of the cycle—for instance, on one occasion the pupil remained contracted for twenty seconds, and took twenty seconds to dilate and contract again, there being no appreciable stage of dilatation, and the whole cycle lasting forty seconds. On some other occasions the cycle has occupied a longer and on others a shorter time than this. The pupil does not react to light. The left eye is independent of the right, except in that the consensual reflex in the right eye is present, and that concomitant movements are, as far as possible, preserved. Light and attempts at accommodation do not affect the movements.

The author then gives an analysis in brief of similar cases in the literature. ERNEST THOMSON.

IX.—BUPHTHALMOS WITH GOOD SIGHT.

(1) **Warlomont.—A case of hydrophthalmus with the preservation of good sight. (Un cas d'hydrophtalmie avec conservation d'une bonne vision.)** *Bull. de la Société Belge d'Ophtal.*, No. 34, 1913.

(2) **Collins, E. Treacher.—A case of buphthalmos with full vision and without any cupping of the optic disc.** *Trans. Oph. Society U.K.*, Vol. XXXIII, 1913, p. 194.

(1) **Warlomont**, of Brussels, exhibited a patient, 20 years of age, who enjoyed good sight despite hydrophthalmus. The condition was pretty typical. Iridodonesis was present. There was neither glaucomatous excavation of the optic disc nor raised intra-ocular tension. The transverse diameter of each cornea measured 12 mm. The radius of curvature was 6·9 mm. Slight simple myopic astigmia. The visual acuity was superior to unity in both eyes. SYDNEY STEPHENSON.

(2) **Collins**, of London, reports the case of a man, aged 17 years, who presented the typical appearances of buphthalmos. The anterior chamber was very deep. The right cornea measured 14·75 mm. and the left 14 mm. in diameter. Fields for a 10 mm. white square normal. No cupping of the optic discs. Vision was 6/6 and Jaeger No. 1 with correction (R.E. compound myopic astigmia and L.E. simple myopia). SYDNEY STEPHENSON.

X.—CONGENITAL ANTERIOR STAPHYLOMA.

Collins, E. Treacher, and Hudson, A. C.—A case of congenital anterior staphyloma. *Trans. Oph. Society U.K.*, Vol. XXXIII, 1913, p. 159.

The eyeball described in this important communication by **E. Treacher Collins** and **A. C. Hudson,** of London, was removed from a male child at the age of eleven weeks. It was noticed to be abnormal as soon as the baby opened his eyes on the third day after birth. The affected eye presented corneal opacity, iris in contact with the posterior surface of the cornea, and an intercalary staphyloma above the cornea. The baby suffered from no tokens of constitutional illness. No associated congenital defects are mentioned in the report. There was no germane family history.

Measurements of the eyeball after removal were: antero-posterior, 23·5 mm.; vertical, 18·5 mm.; horizontal, 18 mm. The apparent cornea measured 9 mm. in its vertical by about 11 mm. in its horizontal diameter. When the eye was divided in a vertical meridian, it seemed that the anterior chamber was absent, the iris being applied to the back of the cornea. The condition of the lens could not be made out. The vitreous appeared to be somewhat degenerate. The optic disc was not obviously "cupped."

Sketched in very cursorily, the microscopical appearances were as under:—

The anterior part of the eye was covered with stratified epithelium. The cornea (vertical diameter, 9 mm.) was made up of a central attenuated portion and of a thicker peripheral portion. For the most part, the substantia propria of the cornea was composed of a regularly laminated structure, which resembled the normal tissue except for some hypernucleation and localised irregularity in the structure of the superficial layers, together with the existence of a few scattered polymorphonuclear leucocytes. Traces of Bowman's membrane could be recognized, but Descemet's membrane was altogether absent. Blood vessels of new formation were not present. The posterior surface of the cornea was lined, above by an iris tissue consisting of a double layer of pigmented epithelium, reinforced by a dilator musculature and a sphincter muscle, and below by tissue having the aspect of stretched and atrophic ciliary epithelium, with rudimentary ciliary processes, rather than of iris pigment. A curious column of distorted lens passed through the pupil constituted in this way. It expanded into a large antero-posteriorly flattened head (apparently undergoing partial disintegration), which lay in close contact with the central thinned portion of the cornea. A hyaline capsule, continuous with that enclosing the main body of the lens, passed through the pupillary aperture on to the expanded anterior head of the lens, completely investing the last-named except for a small area. The capsule was lined on its deep surface by lens epithelium. That portion of the lens which lay behind the iris took the form of a flattened disc-like base, from which arose the columnar process passing through the pupil and coming into contact with the central portion of the cornea. It was supported by a much-elongated zonula, directly continuous with the epithelium of the ciliary region. The ciliary body was atrophic. There was no pathological "cupping" of the optic disc. Finally, it is to be particularly noted that there was an entire absence of intra-ocular inflammatory exudation, and that the uveal tract was free from cellular infiltration.

Collins and Hudson adduce many reasons against regarding the condition as due to a perforation of the cornea, as from ulceration *in utero*.—1. The abnormality takes the form of a central defect in the cornea, surrounded by

tissues showing no evidence whatever of past inflammation. 2. What slight signs of inflammation there are in the cornea are confined to the anterior layers, and may plausibly be attributed to the staphyloma that was present. 3. There is no evidence of any incarceration of the tissues of the iris in the scar of an ulceration. 4. On this hypothesis, the iris should lie in front of the lens, whereas, in point of fact, it lies behind it. 5. There is an absence of inflammatory exudation, and the uveal tract is free from any cell infiltration.

The authors are agreed that the abnormality was of developmental origin, and had exerted its influence before the differentiation of Descemet's membrane and the formation of the anterior chamber and the pars plana of the ciliary body.

So far all has been plain sailing, inasmuch as the authors are agreed. But now each writes a separate account giving his own explanation of the microscopical appearances and of the fundamental abnormality that has resulted in the development of an anterior staphyloma. We feel we cannot do better than to refer readers to these highly technical and ingenious explanations, between the rival merits of which we feel altogether unable to decide.

SYDNEY STEPHENSON.

XI.—DISEASE OF THE PITUITARY BODY.

(1) Risley, S. D.—A case of bitemporal hemianopsia with acromegaly and other symptoms apparently due to disease in the pituitary region: Diagnosis confirmed by autopsy. *Trans. Amer. Ophth. Society*, Vol. XIII, Part i, 1912, p. 137.

(2) Lawford, J. B.—Case of disease in the pituitary region. *Proceedings of the Royal Society of Medicine*, March, 1913.

(3) Eason, H. L.—Notes of three cases of disease of the pituitary body. *Proceedings of the Royal Society of Medicine*, May, 1913.

(4) Holmes, Gordon.—Pituitary tumour with symptoms of dystrophia adiposogenitalis. *Ibidem.*

(5) Holmes, Gordon.—A pituitary tumour with early acromegaly. *Ibidem.*

(6) Harman, N. Bishop.—Two cases of bitemporal hemianopsia, with other evidence of pituitary tumour. *Ibidem.*

(7) Thompson, Theodore.—Case of pituitary disease. *Ibidem.*

(8) Turney, H. G.—Pituitary and (?) adrenal syndrome. *Ibidem.*

(9) Poynton, F. J.—Precocious development in a boy aged eight. *Ibidem.*

(10) Stewart, T. Grainger and Parsons, Herbert.—A case of pituitary tumour. *Ibidem.*

(11) Wilson, S. A. Kinnier.—A typical case of acromegaly with signs of regression. *Ibidem.*

(12) Stewart, T. Grainger and Brewerton, Elmore.—Case of pituitary tumour; symptoms of failure of posterior lobe function. *Ibidem.*

(13) Stewart, T. Grainger and Rutson, James R.—Case of pituitary tumour (Lorain type); small adult body with retarded sexual development, but no adiposity; failure of function of anterior lobe. *Ibidem.*

(14) Wilcox, W. H.—Case of acromegaly. *Ibidem.*

(15) Doyne, R. W.—Acromegaly; pituitary tumour showing the failure of the fields for colour before the failure of the white field. *Ibidem.*

(16) Collier, James.—A case of cerebellar ataxia with symptoms of a (? preceding) hypophyseal lesion. *Ibidem.*

(17) Batten, F. E.—Case of hypopituitarism—dystrophia adiposo-genitalis. *Ibidem.*

(18) Williams, E. Cecil.—Case of hyperactivity of anterior lobe combined with deficient action of posterior lobe. *Ibidem.*

(19) Hill, Emory.—Hypophysis disease (from the ophthalmological standpoint), with a report of two cases. *Archives of Ophthalmology*, July, 1913.

(1) The case by **Risley,** of Philadelphia, is briefly as follows:

A woman, of 65 years, who herself believed that she was in good health, had increased rapidly in weight, especially about her torso, and her hands and feet had become large, particularly the latter. The skull presented the appearances of acromegaly. She was exceedingly drowsy; she had lost the sense of smell; and she was tormented with itching sensations all over her body. When examined on October 10th, 1910, there was complete bitemporal hemianopsia, with Wernicke's sign in both eyes. In the left eye there was no perception of colours. The nasal half of each disc was grey and paler than the temporal. Examination with the *x*-rays (Dr. William M. Sweet) disclosed "an unusual enlargement of the bony structures of the sphenoid bone." In March, 1912, patient died from pneumonia. At the base of the brain was a tumour, which measured 5 cm. in length, 5 cm. in width, and 3·6 cm. in thickness. It was oval in shape, and rested on the frontal lobes anterior to the optic chiasm, compressing the optic nerves. It was found to be a highly-vascular spindle-cell sarcoma, and had entirely replaced the pituitary body. The posterior ethmoidal cells contained a large amount of thin, yellowish, purulent material.

SYDNEY STEPHENSON.

(2) **Lawford,** of London, brought before the Royal Society of Medicine for opinion the case of a man, aged 46 years, who while presenting incomplete bilateral temporal hemianopsia, optic atrophy, and symptoms suggestive of pituitary disease, such as loss of sexual power, drowsiness, and headache, yet showed no definite evidence of acromegaly. There was no history of syphilis, the patient had five healthy children, no deaths and no miscarriages, and Wassermann was negative.

The discussion does not seem to have thrown any light on the case, which thus offered considerable difficulty. ERNEST THOMSON.

(3) to (18) To reduce to the form of a readable abstract the individual articles and the contributions to the discussion on disease of the pituitary body, which occupied two meetings of the combined sections of Neurology and Ophthalmology of the Royal Society of Medicine, would be a well-nigh impossible task, which we shall not attempt. The subject fills ninety-four pages of the *Proceedings* and may well be left to the reader to peruse in the original. It is well to say, however, that in addition to the articles named in

the list of references, the discussion was taken part in by Professor Schäfer, who spoke of the structure and functions of the pituitary body; by J. H. Fisher, who also related a number of cases; by H. G. Turney; by A. E. Garrod; by William Hill, who discussed the operative treatment; by C. I. Graham on the same subject; by Langdon Brown, and by Richardson Cross. There are numerous illustrations, photographs of patients, charts of the visual fields, radiograms, blood-pressure tracings, and illustrations of operative routes.

(19) This important communication by **Emory Hill,** of Chicago, begins by considering the anatomy and physiology of the hypophysis. The anterior lobe of that complex body is essential to life, and its ablation results in death from cachexia. Its under-secretion leads to a lowering of the body temperature. Injection of its extract gives rise to some pressor effect upon the circulation. It is concerned with skeletal growth. As regards the posterior lobe of the pituitary body, it is normally concerned with effective carbohydrate metabolism (Cushing). Its over-activity results in a rise in blood pressure, diuresis, uterine contraction, dilatation of the pupils, increased carbohydrate assimilation, and a galactagogue action. Chronic over-secretion produces emaciation. Under-secretion causes an increased carbohydrate tolerance.

The effects of under-secretion of the entire gland include adiposity, nutritional changes in the skin, disturbance of carbohydrate metabolism, body temperature, growth and renal secretion, with sexual inactivity or atrophy.

The symptom-complex in a given case may be extremely involved, when we consider the many alterations possible as a result of hyper- and hypo-secretion of each of the lobes, to say nothing of the coincidence of overgrowth of one lobe with pressure-atrophy of the other. Included under the general term "Dyspituitarism" two large groups of cases may be identified in which the predominating factors are hyperpituitarism and hypopituitarism. Hyperpituitarism includes gigantism and acromegaly, overgrowth of the bony framework, when it begins in childhood, and of the acral parts, characteristic of acromegaly, when it is delayed until over puberty. Hypopituitarism is illustrated by the Fröhlich syndrome (generalized adiposity, delayed development of the genital organs, dry skin, and polyuria). When the disease begins in adult life, it is marked by such symptoms as amenorrhœa, testicular atrophy, loss of sexual power and desire, together with the assumption of the feminine contour of body by males. The first group is marked by excessive multiplication of the eosinophile cells of the parts anterior, and the second by a chromophobe struma.

The second part of the paper is devoted to an elaborate description of a couple of cases. The first of cyst of the hypophysis causing the clinical symptoms of hypopituitarism, with primary optic atrophy and atypical distortion of the visual fields, alleviation by operation. The second case is one of dyspituitarism (Cushing), probably due to pressure by a neighbouring growth, and associated with abducens paralysis, primary optic atrophy and blindness of one eye, with temporal hemianopsia of the other.

The third part of Hill's communication includes a review of the literature dealing with the eye symptoms that may be produced by enlargement of the hypophysis. The frequent absence of such pressure signs as exopthalmos raises the question whether their presence or absence may not be of service in distinguishing the acromegalic cases from those in which hypofunction of the gland exists. The literature, however, indicates no such distinction. Uhthoff's statistics show that palsies of the ocular muscles, which might be expected as a sign of osseous distortion in acromegaly, are more frequent in the opposite type. Cushing found a larger proportion of exophthalmos in hyperpituitarism, but

the preponderance was not great enough to be important. The author quotes the figures given respectively by Uhthoff, Cushing and Bartels. Amblyopia, amaurosis, and temporal hemianopsia were the striking symptoms on which the diagnosis of pituitary tumours in the pre-ophthalmoscopic days, as emphasized by Uhthoff. They represented, in fact, late appearances which were the sole diagnostic signs of hypophysis disease known to the older ophthalmoscopists. Primary optic atrophy is much more frequent than neuritis and secondary atrophy. Neuritis or choked disc may be superimposed upon a primary atrophy when excessive intracranial pressure is a late and rapid development.

Hill's analysis of the changes that may occur in the visual fields in disease of the pituitary body is most instructive. Scotomata receive scanty attention in the literature; so much so, indeed, that their presence has actually been held to exclude disease of that body. Uhthoff found such changes three times only in 328 cases; v. Frankl-Hochwart once in 31 cases; and Bartels in 13 per cent. of 22 cases. de Schweinitz and Holloway, on the contrary, have laid stress upon the relative frequency and importance of scotomata. The latter may be absolute or relative, and may represent the beginning of larger defects eventually destined to become true hemianopsias. Homonymous hemianopsia occurs in a fair proportion of cases. It is readily explained by one-sided pressure behind the chiasma, as from a growth in the vicinity of the hypophysis. According to Uhthoff, temporal hemianopsia occurs in 38 per cent. and according to Bartels, in 46 per cent. of the cases. But Hill believes that undue stress has been placed upon temporal hemianopsia as a diagnostic point, and that disease of the hypophysis may be revealed long before such a picture is forthcoming. The important fact seems to be that temporal hemianopsia is not essential to the diagnosis of pituitary disease, and that the other eye symptoms are of greater consequence. Cushing regards the evolution of temporal hemianopsia as following a fairly definite course. As Hill points out, defects short of hemianopsia and colour defects must be looked upon with suspicion. J. Herbert Fisher (1911) has suggested, (as did R. W. Doyne before him, 1895) that colour loss is an index to the progress of the disorder. Cushing's observation of colour interlacing is noted, and, finally, it is pointed out that daily variation in the condition of the fields is often observed in diseases of the pituitary body.

In conclusion, the reviewer would say that Emory Hill's communication deserves to be read in the original by those interested in the complex subject of pituitary disease. SYDNEY STEPHENSON.

XII.—CATARACT.

(1) **Vital-Bérard.—Some points in the operation of cataract extraction. (Quelques particularités dans l'opération de la cataracte.)** *L'Ophtalmologie Provinciale*, janvier, 1912.

(2) **Frenkel, H.—Cataract, dacryocystitis, and epithelioma of the cheek on the same side in a woman of 76. (Cataracte, dacryocystite et epithelioma de la joue de même côté chez une femme de 76 ans.)** *L'Ophtalmologie Provinciale*, janvier, 1912.

(3) **Lagrange.—Diabetic cataract. (La cataracte diabetique.)** *L'Ophtalmologie Provinciale*, juin, 1912.

(4) Chevalier.—The question of operative treatment of slow-growing cataracts. (De l'intervention opératoire dans les cataractes à évolution très lente.) *L'Ophtalmologie Provinciale*, juin, 1912.

(5) Smith, Henry.—Details of vision of 132 cases of intra-capsular extraction of cataract. *Indian Medical Gazette*, Vol. XLVII, p. 342, September, 1912.

(6) Nesfield, V. B.—The extraction of cataract in its capsule, by division of the suspensory ligament. *Indian Medical Gazette*, Vol. XLVII, p. 382, October, 1912.

(7) Parsons, J. Herbert.—The treatment of unilateral cataract. *Lancet*, November 9th, 1912.

(8) Sattler, Robert.—The relative value of recent improvements of cataract extraction. *Trans. Amer. Ophth. Society*, Vol. XIII, Part I, 1912, p. 52.

(9) Weill, G.—Operation for senile cataract with the keratome. (Ueber Operation des Altersstaares mit der Lanze.) *Klin. Monatsbl. f. Augenheilkunde*, Januar, 1913.

(10) Hudson, A. C.—Cataract extraction with peripheral iridectomy. *Royal London Ophthalmic Hospital Reports*, July, 1913, p. 84.

(1) **Vital-Bérard**, of Angoulême, mentions several useful points in the operation of cataract extraction. He confesses himself a believer in preliminary iridectomy; he thinks it is safer, especially in the case of nervous patients, while the disadvantages, *viz.:* adhesions of the angle of the coloboma, and the difficulty in making a conjunctival flap at the second operation, are outweighed by the advantages. He instils 15 per cent. argyrol into the eye to be operated on thrice daily for three days before the operation. It acts as an antiseptic, and informs him of the patency of the lacrymal apparatus. He does not believe in douching the conjunctival sac, as he thinks that such procedure might destroy the germicidal power of the conjunctiva. After the first instillation of 3 per cent. cocaine, he puts in 1 c.c. of warm 2 per cent. hermophenyl solution. He uses 0·04 per cent. biniodide oil for sterilising the lashes. The lids and surrounding parts are cleaned with alcohol. Before commencing the operation, he injects a solution of cocaine and adrenalin subconjunctivally. He holds that the use of a speculum is dangerous; an assistant keeps the upper lip raised, the fixation forceps keeps the lower lid down. He recommends Terson's capsule forceps. After the operation, he instils a few drops of methylene blue into the eye; it is antiseptic, analgesic, and tends to promote keratinisation. He applies a wet dressing to both eyes and changes it on the following day. He gets the patient up as soon as possible. He states that he has seen benefit from the employment of Darier's paraspecific treatment. P. A. HARRY.

(2) **Frenkel**, of Toulon, relates the case of a woman with cataract. Her family history was good. The vision of the right eye commenced to fail about a year before; on admission, she could count fingers at a few inches. The right lacrymal sac was markedly distended. On the right cheek there was an ulcer, one-third inch in diameter, on a thickened indurated base; there were no enlarged glands. The first operation was removal of the lacrymal sac; this was done under novocain and adrenalin anæsthesia (1 per cent novocain and 1/1000 adrenalin), in the proportion of 8 to 2; 2 c.c. were injected. Seventeen days afterwards, the right lens was extracted by the combined operation. Good vision resulted. Nearly a month later the

epithelioma of the cheek was removed, also under local anæsthesia. He gives drawings of the incisions made. The wound was closed by sliding in a flap from the outer side. He believes in removing the outer dressings as soon as possible, and in using an ointment of yellow oxide. P. A. HARRY.

(3) In the course of a clinical lecture **Lagrange,** of Bordeaux, discusses the diagnosis, pathology, and prognosis of diabetic cataract.

The case under review was that of a cabinet maker, aged 35 years. Duration of the disease two years. Family history negative. While under treatment, he noticed a slight mist and photopsia. Many times day and night bright sparks would flash suddenly and rapidly before his eyes. His visual acuity diminished rapidly.

With regard to diagnosis, Lagrange recalls the four stages of cataract. With the plane mirror or on oblique illumination, the first signs of cataract are radiating opacities. Later, one notices an increase in myopia and diminished depth of the anterior chamber, followed in the third stage by an absence of iris shadow. In the final stage of hypermaturity, the nucleus separates from the liquid cortex and produces the condition known as the Morgagnian cataract. The importance of the pupillary reflexes and light projection are recalled, and the author shows how the light sense can be measured by Graefe's method. In diabetic cataracts the opacity is diffuse and not striated and radiating as in the senile type, there is also an absence of the silvery lustre of the latter. Other points in the diagnosis of this form of cataract are the age of the patient, the rapidity of growth of the cataract, and the presence of sugar in the urine. With regard to the pathology, the lens changes are said to be due to cytolysins that poison the lens when its protective epithelium is altered. The secretion of the ciliary region is altered; both these influences are emphasized in diabetes.

The prognosis is good in the well-nourished but bad in the asthenic cases.

P. A. HARRY.

(4) In cases of immature and almost stationary cataracts "expectant" treatment is usually recommended. In this article, however, **Chevalier** mentions several procedures that might be adopted in order to hasten maturity. He describes the two commonest varieties of immature cataract. The procedures recommended are :—

1. *Iridectomy.*—Several observers have noted the occurrence of lental opacities after iridectomy. Secretory disturbances are produced in the ciliary region, causing an alteration in the nutrition of the lens, or toxic substances may be formed that will produce the change in the lens. The author mentions the work done by Koch, Kolinski, and Hess.

2. *Combined flap extraction at a variable time after Foerster's operation.*—Gibson, Graefe, and Mannhardt made an opening into the capsule before extracting; this procedure was revived in 1883 by Foerster. He performed a preliminary iridectomy, allowed the aqueous to escape, and massaged the cornea with a rubber curette. After an interval of several days or weeks, he proceeded to the second step, which was a needling of the capsule with Bowman's needle. Eight or twelve days afterwards extraction was performed.

3. *Extraction of the partially ripe lens a month after the preliminary iridectomy.*—This is the procedure that Chevalier recommends. He does not advise the reopening of the wound two or three days afterwards to remove lens matter. A large opening should be made in the capsule. He concludes with a reference to Rohmer's method of discission followed by external massage, and MacKeown's of injecting water into the lens substance.

P. A. HARRY.

(5) This is a record of 132 visual results obtained by intra-capsular

extraction, the tests being made by Colonel Smith himself, or by his wife, medically qualified. It includes thirteen cases already published in the *Indian Medical Gazette* of July, 1910. The task was undertaken mainly in response to a paper published by Eason in the *Lancet* of July 29th, 1911. The eyes were all selected as normal apart from cataract, and the visual examination was made from ten to twenty-one days after operation. Only spherical lenses were used in testing, but a diaphragm was always placed behind the lens. The patients being mostly illiterate, "bull's eyes" had to be used generally for distant vision in place of the ordinary types.

Placing aside two extremely stupid patients, the results work out thus: 6/12 two cases, 6/9 three cases, 6/6 twenty-six, 6/5 twenty-two; 6/4·5 sixty-one, and 6/4 sixteen cases. Thus, 125 out of 130 eyes had visual acuteness ranging from 6/6 to 6/4; more than half the cases had 6/4·5 or better. Further, Colonel Smith emphasizes the statement that still greater improvement in sight is to be expected later in these cases, contrasting with the deterioration frequently found after operation where the capsule is left behind. He quotes figures (already published by Captain Lister) of sixty-one intra-capsular extractions in which vitreous had been lost, examined from one to five years after operation. In ten of these sixty-one cases the visual acuteness was higher than in any of Colonel Smith's list (six cases 6/3·5, four cases 6/3).

These records evidently indicate good results, but the actual figures are not convincing. Without questioning in the very slightest degree Colonel Smith's good faith, there is obviously something unusual in tests which ascribe to so many middle-aged or old people vision distinctly above normal. These figures are the more remarkable since Maynard, like the reviewer and, he believes, Elliot also, failed to find any definite superiority in the visual results of intra- as compared with extra-capsular extraction, at the time of discharge from hospital.

Smith adds a few general remarks, among which may be noted his preference for leaving the operated eye uninspected for ten days, or even longer, after intra-capsular extraction. H. HERBERT.

(6) This is a third paper by **Captain Nesfield** on intra-capsular extraction after division of the suspensory ligament below the lens by a bent silver wire cutter. The wire is as stout as a darning needle. Its sharp-pointed bevelled extremity is an eighth of an inch long, bent at a right angle, and the angle is "flattened by filing" to facilitate introduction. The instrument is kept carefully polished, as any roughness of the wire tends to tear the lens capsule.

From January 1st to July 27th, 1912, Captain Nesfield performed 503 extractions by this method. He considers it much easier to learn than Smith's method of operating, and it reduces to a minimum the amount of pressure required in expulsion of the lens. It enables the incision to be placed at the scleral margin, so that a conjunctival flap may be employed. It has enabled Nesfield also to dispense with a complete iridectomy. He makes only a small basal iridectomy, after rupturing the suspensory ligament, but before expelling the lens. With this procedure he has had no prolapse of iris in his last 200 operations. As regards escape of vitreous his latest list runs thus:

61	cases and then a	slight escape
21	ditto	ditto
105	ditto	ditto
83	ditto	ditto

There were two instances of sepsis in the series, leading to complete loss of sight in one case, and partial loss in the other. It is to be noted that for a quarter to half an hour before operating one in 4,000 perchloride of mercury is "dropped frequently" into the eye.

In expelling the lens, pressure is made below at the sclero-corneal margin, and counter-pressure with a spatula above the wound. Soft lenses are made to rotate, so that the lower margin comes forward and presents first, the pressure being applied almost directly backwards, and the point of the expressor (hook) being then "drawn a little downward."

He keeps the eyelids closed afterwards by a silk stitch passed through the sling at their margins. Apparently the stitch is passed (loosely) at the beginning of the operation. In addition, both eyes are bandaged up, the operated eye being protected from pressure by a celluloid shield under the bandages.

(7) The clinical lecture on unilateral cataract by **Parsons,** of London, proceeds on lines which will commend themselves to the majority of ophthalmic surgeons. There is one point in it which the reviewer considers of such importance, from his own experience, that he desires to give it special prominence. In speaking of methods of operation in juvenile cataract the author says :—

"Some surgeons advocate a very free needling of the capsule, followed in a few days by evacuation of the swollen lens matter through a linear incision. My experience, especially as a pathologist, has taught me that the few cases of needling which go wrong do so as the result of the curette evacuation. It is excessively rare for an ordinary needling to become infected or otherwise give rise to anxiety. I therefore advocate repeated needlings in these cases, using every precaution to avoid the necessity of evacuating the contents of the anterior chamber through excessive swelling of the lens matter and consequent increased intra-ocular tension. The only objection to this method is that it takes a longer time than the bolder line of action, but time is usually of little importance in young children compared with increased safety."

With every word of this, the reviewer agrees so heartily that he desires to take this opportunity of emphasising a point which is perhaps not fully realised, the increased danger of the curette operation as compared with carefully graded needling. If there is one class of case in our operative work more than another in which the famous remedy "tincture of time" is to be recommended, it is this class. In the opinion of the reviewer, a year is not too long to spend, if necessary, in an ordinary case where both eyes have to be operated. S. E.

(8) This appears to represent an argument *pro* and *con* dealing with Smith's intracapsular extraction of cataract by **Sattler**, of Cincinnati, but owing to the tortuous English in which it is couched, the reviewer would not care to commit himself to an opinion one way or the other. SYDNEY STEPHENSON.

(9) The use of the keratome in extraction of senile cataract has been generally abandoned, owing to the difficulty in getting a large enough incision or to the objection to enlarging the wound by means of scissors. **Weill,** of Strassburg, however, being of the opinion that the keratome incision results in a neater wound with more rapid healing than that produced by the linear knife, has reintroduced the former instrument into his practice. An ordinary bent keratome with a base of 11 millimetres is used. It is inserted a little to one side of the mid-point, is passed far into the anterior chamber, and in its withdrawal it is made to extend the wound in the other direction. The extraction of the lens is perhaps a little slower, but not more difficult than through the usual incision, and the results as regards healing are quite satisfactory. A. J. BALLANTYNE.

(10) Prolapse of the iris has been estimated to occur in from 3-4 per cent. (de Wecker) to 13·86 per cent. (Marshall) of the cases after the performance of the so-called "simple" extraction of cataract. On the other hand, the

"combined" method is liable to be complicated by incarceration of the lens capsule between the lips of the wound, one of the most serious accidents that can follow cataract extraction. We are thus between Scylla and Charybdis. **Hudson**, of London, would extricate us from the perilous position by causing us to adopt a plan originally recommended by Bell Taylor (1871), of making a peripheral iridectomy, and modified by H. Beckles Chandler (1890). SYDNEY STEPHENSON.

XIII.—COLOUR-BLINDNESS.

(1) **Edridge-Green, F. W.—Accidents which have occurred through colour-blindness.** *Lancet*, September 23rd, 1911.

(2) **Digby, Kenelm, H.—The Admiralty test for colour-blindness.** *Lancet*, April 27th, 1912.

(3) **Edridge-Green, F. W.—A case of colour-blindness.** *Lancet*, June 22nd, 1912.

(1) **Edridge-Green**, of London, has written this article because of the continued repetition of the mis-statement that no accident has ever been shown to have occurred through colour-blindness. The author quotes a series of accounts of accidents on sea and land which have been due to colour-blindness, and most interesting details of cases, where accident has only been prevented by the prompt action of some other officer—the captain of the ship—in giving an order to the steersman, countermanding the order given by the colour-blind officer. ERNEST THOMSON.

(2) **Digby**, of Bowdon, Cheshire, in a letter to the Editor of the *Lancet* says "Judging from several months' experience of examining men for railway work by various tests, including Holmgren's wools (matching) and the Edridge-Green lantern (naming), it seems to me that the lantern has several definite advantages. It is *conclusive*. A man who will hesitate with the wools and perhaps only blunder the first time, will repeatedly miscall the signal red, white, and green, in the lantern. . . . . The lantern is *practical* and represents the conditions that a railwayman or sailor has to meet in his work. Ten minutes with the lantern is, indeed, a more searching test than a night on the foot-plate, for by means of various glasses the appearance of signal lights in different conditions of the atmosphere can be shown. . . . . ."

ERNEST THOMSON.

(3) **Edridge-Green**, of London, reports in full the case of a man who could pass the Board of Trade test with Holmgren's wools, and who nevertheless failed with the lantern, with the spectrometer, with Stilling's test, with the bead test, with the author's pocket test, and with his classification test. He passed on Lord Rayleigh's colour mixing apparatus and on Nagel's test. "Can we wonder," says Edridge-Green, "that there are accidents at sea . . ?"

ERNEST THOMSON.

XIV.—ACNE ROSACEA.

(1) **Holloway, T. B.—The ocular manifestations associated with acne rosacea, with the report of a case of so-called rosacea keratitis.** *Archives of Ophthalmology*, July, 1910.

(2) **Caralt.—Acne rosacea and keratitis.** (Acne rosaceo y queratitis.) *Archivos de Oftalmologia Hispano-Americanos*, Abril, 1913.

(1) In **Holloway's** case, the acne first appeared at the age of 26, during pregnancy; it recurred at the next pregnancy, and any remaining lesions during the intervals were aggravated at the menstrual epochs. The staphylococcus pyogenes aureus was present in both the eye secretions and in the pus evacuated from a stye which formed. A very marked lymphangiectasis developed.

ROSA FORD.

(2) Acne rosacea, as is well known, says **Caralt**, has nothing to do with acne proper; the lesion of the latter is essentially the comedo; that of the former is a permanent dilatation of the subepithelial capillaries and veins, which thus become visible on the surface as fine violet lines. The two diseases have to a large extent the same seats of election, because their causes are to a large extent the same. The ocular lesions of acne rosacea are similar to, or clinically identical with, the conjunctivis called "scrofulous" or phlyctenular, and these two are interesting as being the only forms of conjunctivitis which are not contagious.

In all cases the corneal or sclerotic efflorescence is preceded by a hyperæmia of the region in which the efflorescence is about to appear. Caralt has observed that the hyperemia is evident some days or hours before the corneal affection, the vessels becoming engorged over a triangular area near the canthus generally, and raising the conjunctiva over them. He is satisfied that the disease is not a local one, but a manifestation of some change in the vaso-motor centres by which the local blood-vessels receive an abnormal stimulus. The prime cause of this is to be sought in some auto-intoxication from the alimentary canal or from some of the glands of internal secretion.

HAROLD GRIMSDALE.

XV.—REMEDIES.

(*Eighth Notice.*)

(1) **Baudry, S.—The treatment of suppurative kératitis.** (Sur différents cas de kératite suppurative et de leur traitement.) *L'Ophtalmologie Provinciale*, février, 1912.

(2) **Beauvieux.—Tuberculin and ocular tuberculosis.** (Tuberculine et tuberculose oculaire.) *L'Ophtalmologie Provinciale*, août, 1912.

(3) **Desvaux, E.—A case of amblyopia cured by meat and white wine.** (Un cas d'amblyopie guéri par le régime de la viande et du vin blanc.) *L'Ophtalmologie Provinciale*, septembre, 1912.

(4) **Lagrange.—Ocular tuberculosis and its treatment.** (La tuberculose oculaire et son traitement.) *L'Ophtalmologie Provinciale*, septembre, 1912.

(5) **Mackay, George.—Discussion on the use of tuberculin in diseases of the eye.** (Annual Meeting of the British Medical Association, Liverpool, 1912.) *British Medical Journal*, October 19th, 1912.

(6) **Ritchie, L. C. Peel—Discussion on the use of tuberculin in diseases of the eye.** (Annual Meeting of the British Medical Association, Liverpool, 1912.) *British Medical Journal*, October 19th, 1912.

(7) Dor, Louis.—**Discussion on the use of tuberculin in diseases of the eye.** (Annual Meeting of the British Medical Association, Liverpool, 1912.) *British Medical Journal*, October 19th, 1912.

(8) Rohmer.—**Autoserotherapy in ophthalmology.** (De l'Autoserothérapie en Ophtalmologie.) *L'Ophtalmologie Provinciale*, novembre, 1912.

(9) Wölfflin, Ernst.—**How can one prevent the red coloration of eserine solutions? Wie kan man das rotwerden von Eserinlösungen vermeiden?**) *Klin. Monatsbl. f. Augenheilk.*, März, 1913.

(10) Stevenson, Edgar.—**Some points in modern eye surgery.** *Liverpool Medico-Chirurgical Journal*, July, 1913.

(11) Paton, Leslie.—**Rodent ulcer treated with CO_2 snow.** *Trans. Oph. Society U.K.* Vol. XXXIII, 1913, p. 56.

(12) Lawson, Arnold.—**A case of chronic glaucoma of thirteen years' standing, treated without operation.** *Trans. Oph. Society U.K.*, Vol. XXXIII, 1913, p. 195.

(1) In a clinical lecture on this subject, **Baudry**, of Lille, showed five cases. He described the anatomical divisions of ulcers. In the superficial form Bowman's membrane is not affected, and the ulcer heals under treatment without loss of transparency. In a further stage, necrosis of Bowman's membrane takes place, and the superficial layers of the true cornea become involved. Bowman's membrane is not re-formed. In a still more serious case, toxines dialyse through the remaining layers of the cornea and Descemet's membrane into the anterior chamber, and cause an exudate to be poured out by the iris and ciliary body. Corneal abscesses may be superficial or deep; they develop in the true corneal tissue, and may rupture through Bowman's membrane or into the anterior chamber. The diffusion of toxines produces a hypopyon in all these cases. Infection of the hypopyon, owing to rupture of Descemet's membrane, may lead to panophthalmitis.

The author described the course of an untreated case of serpiginous ulcer of the cornea; he emphasised the importance of a microscopic examination of the pus. Where the diplo-bacillus of subacute conjunctivitis is found, a solution of zinc sulphate is enough to cure the condition. In the presence of pneumococcal infection, stronger drugs must be used—cyanide of mercury, potassium permanganate, silver nitrate, protargol, etc.; tincture of iodine is preferred to the galvano-cautery. In the presence of lacrymal disease, there should be no hesitation in excising the sac, as a preventive of future trouble. The *technique* of corneal section is given, also advice upon the treatment of corneal opacities. P. A. HARRY.

(2) In a paper read before the French Ophthalmological Society, May, 1912, **Beauvieux** reports three cases of ocular tuberculosis localized to the anterior segment of the eye:

1. Tuberculosis of the iris with iridocyclitis in a man of 23.
2. Iridocyclitis in a girl suffering from hæmorrhagic entero-colitis, tuberculous in origin.
3. Unilateral external ophthalmoplegia in a man aged 33, due to basal meningitis.

He believes in commencing with small doses of tuberculin, and he injects intra-muscularly 1/1,000 milligramme of the dry substance. He uses tuberculin C.L. from the Pasteur Institute. Every second day the dose is increased by

1/1,000 milligramme, until 1/100 milligramme is reached, when the succeeding doses are 2/100, 3/100, etc., up to 1/10, then 2/10, 3/10 to the final dose of 1 milligramme. He is of opinion that non-progressive doses are unsatisfactory and even injurious. By his method of treatment it takes about two months to complete a series. He has had no serious results, either local or general. Three cases of tuberculosis of the posterior segment of the eye, successfully treated by the same method, are also mentioned. He lays it down, as a rule, that any young person, non-syphilitic, with a negative Wassermann, with a tuberculous family history, and presenting a positive cuti-reaction, should be treated with tuberculin, if suffering from any chronic condition of the retina and choroid. The author suggests that the patient should be under careful observation during the entire course of treatment. P. A. HARRY.

(3) **Desvaux**, of Angers, records the case of a man, aged forty-two, with hysterical amblyopia. In July, 1902, while at work, he noticed a blank patch in his line of vision, affecting only the right eye. His doctor, whom he saw immediately, treated him on general lines, and gave him some copper sulphate drops for his eye. There was no improvement after two months, so he consulted an eye specialist, who diagnosed toxic amblyopia, and prescribed milk, potassium iodide, and a mercurial inunction for the temple. The left eye now commenced to show a scotoma. Both eyes were treated for fifteen days without success. He saw another specialist, who made the same diagnosis, and advised similar remedies in larger doses. After trying for another month he saw Galezowsky at Paris, where amblyopia, with commencing atrophy was diagnosed, and injections of strychnine were made into his temple. Five months of this treatment produced no result; anti-syphilitic treatment was then tried without result. In July, 1903, central vision was absent; only peripheral perception of objects remained. The patient became discouraged, and decided to stop all treatment. In September, to his surprise, after breakfast, on looking up quickly, he was able to perceive a calendar on the wall four metres away. The right eye showed this improvement. He rested for a couple of hours, but was no better afterwards. On the following day the same improvement was noticed; it was found to occur between eleven and two o'clock. In the course of another month the time of improvement increased from eleven to two. Each month showed an increase of two hours. Both eyes participated in the improvement, which the patient declared to be due to beefsteak and white wine. He invariably became worse if he drank any red wine. P. A. HARRY.

(4) In a clinical lecture on the above subject **Lagrange**, of Bordeaux, lays stress on the difficulties of diagnosis, and the importance of the laboratory in verifying the diagnosis. He mentions three cases of conjunctival tuberculosis which would not have been diagnosed but for the help of the laboratory, one a case of conjunctival tuberculosis simulating spring catarrh, another recurrent chalazion, tuberculous in nature; the third a case of obstinate conjunctivitis with a nodule, which examination proved to be tuberculous.

The cornea, too, may be the seat of tuberculous disease, either diffuse or nodular; small tubercles may develop in the anterior chamber, like whitish grains. Varieties of episcleritis that used to be classed as syphilitic or gouty are now known to be tuberculous

The attraction of the tubercle bacillus towards the uveal tract is very marked. The bacilli escape from some softening lesion elsewhere and are caught in the sponge-like structure of the uveal tract; a granuloma may result or a diffuse inflammation Parinaud was the first to differentiate between the vascular gumma at the pupillary border of the iris, and the dirty-white tuberculoma at the periphery of the iris, which is non-vascular and breaks

down before long. Lagrange relates a case of disseminated choroiditis due to tubercle and a case of tuberculoma of the ciliary region diagnosed as sarcoma. Pigmentary choroiditis and the macular choroiditis of myopes he also believes to be tuberculous. Notes are recorded of two cases that were shown, and the technic of tuberculin therapy is mentioned. If the temperature is normal, heart normal, and if there is no inflammatory tuberculous lesion, 1/1000 milligramme of tuberculin (Calmette) is injected and the dose increased every second day by 1/1000 to 1/100, then by 1/100 to 1/10, then by tenths to 1 milligramme. P. A. HARRY.

(5) **Mackay**, of Edinburgh, in opening the discussion on the use of tuberculin at the 1912 meeting of the British Medical Association, first discusses the various diagnostic methods and some of the therapeutic methods, and then gives his personal experiences. Some cases of eye diseases of tuberculous origin are illustrated in two fine coloured plates. In speaking of treatment in general, Mackay refers to the view that human and bovine forms of tuberculin are antagonistic to one another, and that in the case of human infection the bovine vaccine should be used, and *vice versâ*. In his experience, this is not the case. With regard to the dosage, he says that while it is claimed that a proper interval between the doses is best secured by a careful study of the opsonic index, sufficient experience seems now to have been obtained to justify the view that if the initial doses of vaccine are small, the increase is gradually made, and the inoculations are not too frequent, the clinical condition of the patient and the absence of local reaction may be taken as a guide without continuous repetition of the opsonic index. The safest preparation is, in his view, Koch's new tuberculin (T.R.), human or bovine. This produces the least violent reaction. Where a more powerful effect is desired, the bacillary emulsion may be employed. No hard and fast rule can be laid down for the scheme of dosage. The personal reaction of each patient must be studied. "It must be borne in mind that the treatment does not consist in flooding the patient with a massive dose of bactericidal material ready prepared, but in stimulating his own tissues to produce the opsonic material necessary for his protection, and many factors in his condition may modify his capacity in that respect." We may leave Mackay's case-histories for study in the original. ERNEST THOMSON.

(6) The second introductory article on the subject of the tuberculin treatment of eye diseases at the 1912 meeting of the British Medical Association is by **Ritchie**, of Edinburgh, and is so concisely written that it amounts almost to an abstract in itself. After stating the various methods of blood examination and giving the opinion that the differentiation of the various types of tubercle bacillus is of high practical importance, Ritchie briefly outlines the method of treatment adopted. The general principles are to keep the patient constantly under the influence of a comparatively small dose of tuberculin, fairly uniform in amount, but tending as time goes on to increase slightly; never to diminish the dose; to make no attempt to "accustom" the patient to the largest doses of tuberculin, but to aim at a gradual immunisation; to avoid hypersusceptibility by giving the earlier doses at short intervals; while later, as the condition tends to come under control, to increase the intervals, as also the doses. The best dosage is that which causes no obvious reaction and has the most prolonged effect. Two schematic tables of dosage are given, the one for the chronic and the other for the acute type of case. ERNEST THOMSON.

(7) The third introductory article on the subject of the tuberculin treatment of eye diseases at the 1912 meeting of the British Medical Association is by **Louis Dor**, of Lyons, and is, as usual with this author's writings, and even

though a little hampered by being written in English, very crisp and pointed. Dor begins treatment with exceptionally small doses, as low as one hundred thousandth of a milligram, and every third day injects a higher dose. As long as there is no reaction, he increases the dose. As soon as there is a local or general reaction, he injects the same dose. As the reviewer understands the author, this dose is injected until there is no reaction, and then the dose is increased once more. The patient takes his own rectal temperature morning and evening. Two or three months of treatment are generally necessary, and after a period of rest, it is frequently well to begin again. After trying many tuberculins, Dor considers that B.E. is the best. In using tuberculin, Dor does so in conjunction with all the other appropriate treatment, local and general.

ERNEST THOMSON.

(8) **Rohmer,** of Nancy, emphasises the difference between serotherapy for general infections and for ocular conditions. Except in the case of diphtheritic conjunctivitis, general serotherapy has been of little or no use in ophthalmology. It has been found that the injection of Roux's serum will do as much good as, or more good than, the specific serum, even in cases where the diagnosis of diphtheria is out of the question. Deutschmann's serum has given good results, in ocular infections due to different organisms, but only in his own hands.

With regard to local serotherapy he discusses the different methods of using the serum, *e.g.*, as subconjunctival injections, injections into the anterior chamber, or in the form of drops. The same remarks apply to local paraspecific serotherapy. He then describes his own method of auto-serotherapy; he got the idea from an article of Gilbert, who treated a tuberculous patient by injections of pleuritic fluid. In a case of abscess of the cornea, Rohmer for the first time, in December 15th, 1911, instituted this treatment: he injected subconjunctivally 1 c.c. of serum taken from a vesicle on the patient's arm; the vesicle was produced by a blister about two inches square. In one patient, a case of tuberculous keratitis, Rohmer injected subconjunctivally some fluid taken from the pleural cavity; the result was exceptionally good.

He claims good results for autoserotherapy in cases of corneal suppuration, with or without hypopyon, parenchymatous keratitis, iritis, sympathetic ophthalmia, and spring catarrh. In its action the injection of the serum may be allied to a vaccine; it may also be regarded as a local stimulant.

P. A. HARRY.

(9) **Wölfflin**, of Basel, finds that the red colour acquired by eserine solutions is due to the action of an alkali. His experiments show that the alkali is derived from the glass of the vessels in which they are kept, and to a much smaller degree from the water with which the solutions are made. Heat, light, and contact with the air, all act as additional stimuli. It was found possible to keep the solutions colourless only by using the purest distilled water and by storing the solutions away from light and air in metal vessels or in those made of quartz or other alkali-free glass.

A. J. BALLANTYNE.

(10) **Stevenson**, of Liverpool, has an omnibus article (a very candid production) dealing largely with the therapeutics of the eye. It is much cheaper, he tells us, to prescribe "ethyl morphin hydrochloride" than to specify "dionin.' He uses subconjunctival injections a good deal, preferably of the oxycyanide of mercury, and believes that they mark a distinct advance in ocular therapeutics. Several striking cases give point and support to this view, but for details readers must be referred to the original communication. Stevenson retains his faith in silver nitrate, with which he considers none of the substitute preparations is worthy to be named in the same paragraph. To argyrol he nevertheless awards the possession of soothing and

agglutinative powers, while he denies to it any bactericidal virtues. He is a believer in large doses of aspirin or sodium salicylate, the former in traumatic inflammations of the eye, and the latter in sympathetic ophthalmitis. He notes that massive doses of sodium salicylate do not give rise to the unpleasant symptoms seen after the adminstration of very much smaller doses. Stevenson, by the way, has never seen mercury do the least good in sympathetic disease. Salvarsan is characterised as "quite useless" in interstitial keratitis, an opinion that will scarcely be shared by those with most experience of the drug. The author speaks enthusiastically about staphylococcus vaccine (Parke, Davis, & Co.), and he believes that it exerts powers of control over diseases other than those caused by the staphylococcus. With regard to tuberculin, "the bad cases don't seem to improve with it, and the slight ones get better no quicker than they do with ordinary treatment." Cold applications are to be applied with the utmost circumspection, since they may even cause necrosis of the cornea. SYDNEY STEPHENSON.

(11) **Paton,** of London, has employed carbonic dioxide snow in several cases of rodent ulcer about the eyelids, and has had satisfactory results from the application. The main characteristic of cases treated in this way appears to be the plasticity of the resulting scar. SYDNEY STEPHENSON.

(12) *Apropos* a case of bilateral glaucoma kept in check for thirteen years without surgical intervention, **Lawson,** of London, makes some general remarks dealing with the non-operative management of the malady.—The management and dosage of eserine naturally claim first attention. In order to avoid conjunctival irritation, Lawson urges that the preparation should be freshly made, and that it should be discarded the moment it shows the least pink discoloration. The smallest dose of eserine that will suffice to keep the intra-ocular tension within normal limits should, broadly speaking, be the dose employed. It is important to apply the medicament at night time. The influence upon the progress of glaucoma of such factors as irritability and worry, arterio-sclerosis and high arterial pressure, is discussed, and much importance is attached to them by the author. The question is asked: Is immediate operation the proper treatment in all cases where one is satisfied that the disease is established? While all admit the desirability of operation when it is proved by objective signs that organic changes are taking place, not a few experienced surgeons insist upon operation as soon as it is certain that the intraocular tension is habitually raised. Lawson gives reasons for believing that this attitude is mistaken. For his own part, he always prefers to try the effect of palliative treatment, provided the case be secured early enough. "The well-worn statement that eserine is of little service in glaucoma simplex arises from the fact that too much reliance has been placed on the use of this drug by itself, and that it has not been sufficiently urged in our text books that the physical and mental conditions of the patient are of the utmost importance, and must receive their proper attention, if we are to control the disease for any length of time without recourse to operation."

SYDNEY STEPHENSON.

BOOK NOTICES.

The Royal London Ophthalmic Hospital Reports. Edited by J. HERBERT PARSONS. Volume XIX, Part I, July, 1913. London: J. and A. Churchill, 7, Great Marlborough Street. Price, 7s. 6d.

This number of the familiar "Moorfields Hospital Reports" is prefaced

by a well-written account of the life of Thomas Young, that great English physicist. His remarkable work dealing with the phenomena of light and colour receives full recognition at the hands of the writer of this sympathetic but anonymous article. Messrs. Nettleship, Hudson, Lawford, Coats, Moxon, and Parsons contribute articles to this volume of the *Reports*.

Accidents from Defective Sight. By E. NETTLESHIP, F.R.S. London: Adlard and Son, Bartholomew Close, E.C. 1913. Price, 2s.

In this small *brochure* Nettleship collects all the accidents which have been proved to be caused by colour blindness and defective form vision, and also instances many occasions upon which accidents have only been avoided, in some cases at the very last moment, by the timely intervention of an individual with normal vision. In the introduction he lays great stress upon the deplorable fact that only rarely have the officials responsible for an accident been examined to determine whether they were colour blind or had other defects of vision. "Naturally, therefore," he says, "no accidents are discovered to have had visual defects for their cause. Continuing to reason in a circle, the conclusion is that defects of sight do not cause accidents!" It is perhaps consoling to learn that the United States authorities were just as careless about these matters as our own were, for on page 24 we read that the Secretary of the Navy wished to reinstate an officer who had resigned because he had nearly caused a collision owing to his Daltonism! The pamphlet is of absorbing interest to those who have taken an interest in these questions, and fully confirms all that Edridge-Green, T. H. Bickerton, C. Devereux Marshall, and many others, have for the past twenty years stated to be the case. Coming from a member of the recent Departmental Committee upon Sight Tests for Seamen, the evidence brought forward has a greatly enhanced value. We hope that its contents will be carefully read by the directors of those railways who still adhere to tests which have repeatedly been proved to be utterly futile. Only recently we were asked to examine two platelayers, working upon the Great Western Railway, who, after passing the colour tests for several years, were suddenly found to be colour blind, and therefore could not obtain promotion. Examination showed that neither of them could pass even Holmgren's wool test, and both failed hopelessly with the Edridge-Green lantern. This is only an isolated instance. We knew of an engine driver on the North-Western Railway who until recently was, and in all probability now is, driving an engine on the main line. He is dangerously colour blind, and yet he always passed the tests used by the company! Such instances could be multiplied by any ophthalmic surgeon who has given attention to the matter. When will the Board of Trade intervene, and insist that the railway test for colour vision shall be efficient?

T. HARRISON BUTLER.

The Ophthalmic Year Book (illustrated), Volume IX. Edited by EDWARD JACKSON, M.D. 8vo, 518 pp. Denver: Herrick Book and Stationery Company. 1913. Price, $5.00.

A hearty welcome to the ninth volume of that invaluable work of reference, the *Ophthalmic Year Book*, which contains a digest of the literature of our specialty for the years 1911 and 1912. Owing to various circumstances, some of which reflect but scant credit upon the discrimination of the medical profession, this volume appears upwards of eighteen months after its immediate forerunner,

and is now published with assistance from the Knapp Testimonial Fund of the Section on Ophthalmology of the American Medical Association. It is by far the largest of the series. Its arrangement resembles that of the preceding volumes. The editor, Dr. Edward Jackson, has been assisted by a large number of collaborators in the preparation of this volume. They include Drs. Schneideman, Zentmayer, Crisp, Wendell Reber, Wood, Gradle, Aufmwasser, and Wiener. Colonel R. H. Elliot and the Editor also contribute sections. The *Ophthalmic Year Book* represents the work of a number of devoted men, and we do not hesitate to urge those of our readers who are not already subscribers at once to become so. They will be amply repaid.

SYDNEY STEPHENSON.

Diseases and Injuries of the Eye. (The Edinburgh Medical Series.) By WILLIAM GEORGE SYM, Ophthalmic Surgeon, Edinburgh Royal Infirmary; Lecturer on Diseases of the Eye in the University of Edinburgh. Crown 8vo, cloth. Containing 25 full-page illustrations, 16 of them in colour, and 87 figures in the text. London: A. & C. Black. 1913. Price 7s. 6d. net.

Among the many text-books of ophthalmology for students and general practitioners which have appeared in recent years, Sym's *Diseases and Injuries of the Eye* must assuredly occupy an honourable place. It is a credit to the author and to the Edinburgh Medical School.

Written in a frank and racy, although undeniably dogmatic, manner; original in thought and expression; up-to-date; illustrated profusely with the right kind of illustrations; well printed and well bound: this book of some 500 pages is, to put the matter bluntly, as good value as the student is likely to find.

It is difficult to know what points to emphasize where there is so much that is good. Perhaps the most outstanding is the selection of what should be included in a book of this kind. The author has exercised a great and a wise restraint in omitting much that must be of interest to himself as a specialist, although unimportant for the general practitioner. Again, while very dogmatic, as is necessary for the student, he has stepped aside to notice debatable points of consequence, and, in general, has succeeded in placing before the student a sound and at the same time a safe line to take in any given case. Thus, such difficult subjects as wounds and injuries and medico-legal questions are excellently handled; sympathetic ophthalmia is dealt with in a masterly manner and is right up-to-date. The chapter on glaucoma, such a difficult one to write, could hardly be bettered.

Operative treatment is, for the most part, and probably rightly, only outlined. Some operations, notably the cataract operation, receive fuller description.

At the end of the book there are useful short chapters on diagnosis, on eye symptoms in diseases of other parts, on nursing (by Sister Douglas), on therapeutic agents, and on the requirements of the public services. In a thin pocket in the back cover is a sheet of distant- and near-vision test-types.

The illustrations demand special notice. There are twenty-five plates and eighty-seven figures in the text. Sixteen out of the twenty-five plates are coloured, but as most of these contain anything from three to twelve drawings, it happens that there are no fewer than ninety-two coloured drawings, Further, the great majority of these drawings, more particularly those representing external appearances of the eye, have that quality of convincing realism which is often conspicuously absent from much more pretentious and specialized volumes than this one. The name of the artist does not transpire,

so that one cannot know where to place the credit. One coloured plate alone is open to serious objection, that, namely, which illustrates the Holmgren wool test, and in this case the text beneath the plate more or less disarms criticism.

What has just been said in appreciation of this book does not preclude the reviewer from saying that he does not agree with the author regarding his (intentional) method of mixing the British and the metric systems when dealing with refraction and accommodation, regarding the employment (or non-employment, to be more accurate) of atropine in refraction, nor with his views on several other points. Nor need it prevent him from making the suggestion that certain paragraphs here and there are hardly up to the author's own standard, and require revision. It also is the personal belief of the reviewer that the author's statements of the incidence of sympathetic disease on pages 389 and 396 are too strong, and, further, that the statements on this subject to be found in the last paragraph of the former page are illogical and to all intents and purposes mutually contradictory.

Printer's errors are almost absent. One important misuse of type may be mentioned: on page 56 the employment of the sign of multiplication in place of the letter x will certainly prove confusing.

There are one or two slips such as "convexity" for (presumably) "convergence" (page 43), "repairing" for "ripening" (p. 189), and (the reviewer supposes) "perforation" for "ulceration" (page 105, heading 3). On page 227 a double line space might be introduced after the first paragraph with advantage to the sense. On page 231 the author is likely to be misunderstood by the student struggling with the difficulties of optic disc "cupping." On pages 13 and 14 the conventional symbol for seconds is repeatedly employed instead of that for minutes, in reference to the visual angle.

We think that the extent to which this book will be taken up by students of ophthalmology, before and after graduation, will prove gratifying to the author.

ERNEST THOMSON.

CORRESPONDENCE.

[While THE OPHTHALMOSCOPE will at all times welcome correspondence from its readers, the Editor does not hold himself responsible for any views expressed in this column.]

THE EXTRACTION OF CATARACT.

To the Editor of THE OPHTHALMOSCOPE.

DEAR SIR,

In your issue of June of the current year, Lieut.-Colonel Drake-Brockman does me the honour to notice a paper of mine which appeared in the April, 1912, number, on the Madras Ophthalmic Clinic.

He claims that he was the originator of the "Madras method" of opening the lens capsule with a needle before making the incision for cataract extraction. It is only fair to Colonel Elliot for me to say that on first demonstrating it to me he (Colonel Elliot) disclaimed originality for the procedure, and informed me that he was indebted to Colonel Drake-Brockman for the idea. I might perhaps have mentioned this in my paper, but it did not occur to me. However, honour where honour is due.

In quoting me further.—" Colonel Elliot advocated the routine use of the measure as long ago as April 1903," Colonel Drake-Brockman has inadvertently taken this paragraph from its context, as he will see if he will again refer to the article. This remark refers to another procedure altogether, namely, that of irrigation of the anterior chamber.

I am, yours faithfully,

135, Macquarie Street, Sydney.
July 10th, 1913.

E. TEMPLE SMITH.

NOTES AND ECHOES.

Deaths.

WE regret to announce the death, upon August 5th last, of Henry Grey-Edwards, of Bangor, at the age of 57 years. Mr. Grey-Edwards was a graduate of Dublin University both in Arts and Medicine. He held the post of ophthalmic surgeon to the Carnarvon and Anglesey Infirmary, as well as to the North Wales Blind Society. He was a member of the Oxford Ophthalmological Congress, and had been a member of the Ophthalmological Society of the United Kingdom. Mr. Grey-Edwards had contributed articles to THE OPHTHALMOSCOPE dealing with the efficacy of subconjunctival injections (1907) and the use of staphylococcic vaccine in the treatment hypopyon-ulcer of the cornea (1908).

Alphonse Desmarres, son of the celebrated Louis Auguste Desmarres, died on August 4th in Brittany, where he had lived in retirement for many years, before which he had followed in his father's footsteps. He was a *chevalier de la Legion d'Honneur.*

The death is announced, at the age of 68 years, of Dr. Leopold Hessberg, director of the eye clinic at Essen a. Ruhr. Deceased was appointed director when the clinic was opened in the year 1909.

The following deaths are announced from America:

Dr. Morris Drossner, of Jersey City, at the age of 70 years.

Dr. John L. Short, of Rollo, Mo., at the age of 59 years.

Dr. R. Parks White, of Fort Wayne, Ind.

* * *

Appointments.

H. WORK DODD, appointed consulting ophthalmic surgeon to the Royal Free Hospital, London, has been succeeded as ophthalmic surgeon by M. L. Hepburn.

H. Willoughby Lyle has been appointed lecturer on practical ophthalmology at King's College Hospital Medical School, London.

J. S. Hosford has been appointed ophthalmic surgeon to the London Temperance Hospital.

H. Haward Bywater, D.Ch.O. (Liverpool), has been appointed assistant surgeon to the Liverpool Eye and Ear Infirmary, as well as assistant surgeon to the Eye, Ear, and Throat Department of the Wigan Royal Infirmary.

T. Milnes Bride has been appointed ophthalmic surgeon to the Northern Hospital for Incurables, Manchester.

Henry Hanna has been appointed visiting ophthalmic surgeon to the Belfast Union Hospital in succession to J. A. Craig, appointed lecturer on ophthalmology in Queen's University, Belfast, *vice* Cecil E. Shaw, deceased.

E. A. Dorrell has been re-appointed clinical assistant to the Eye Department of the Royal Free Hospital, London.

Dr. Aubaret, *agrégé* in the Faculty of Bordeaux, has been appointed professor of clinical ophthalmology at Marseilles, France, in succession to the late Dr. Guende.

The following have been recognised as *privat-dozenten* of ophthalmology: Dr. Adolf Jess, at Giessen, and Dr. G. Colucci, at Rome.

Dr. Arnold has been appointed *chef de clinique ophtalmologique* in the Faculty of Lille, France.

* * * *

Bowman Lecture, 1914.

THE Bowman Lecture of the Ophthalmological Society for 1914 will be delivered by Professor W. Uhthoff, of Breslau.

* * * *

The Oxford Diploma in Ophthalmology.

AT the recent examination (July) for the Diploma in Ophthalmology of the University of Oxford, the following seven candidates are announced to have satisfied the examiners:—

Ford, Harriet R. D.; Horgan, David; Karanjia, K. N.; Kerans, George C. L.; Oliver, George H.; Paton, David Duncan; and Reid, Alexander C.

* * * *

Colour Vision Tests.

IN the House of Commons, on June 18th last, Mr. Cathcart Wason asked the Parliamentary Secretary to the Board of Trade what percentage of men had failed with the colour vision tests introduced on April 1st, and how this percentage compared with that of former years; and how many men had passed with the wool test and failed with the lantern test and *vice versâ*.

Mr. J. M. Robertson replied: The total number of men examined in colour vision from April 1st to May 31st was 1689, and of these 105, or 6·22 per cent., failed. Of the 105 failures, 55 failed in both the wool test and the lantern test, and 50 in the lantern test only. None failed in the wool test only. I regret that it is not possible to give corresponding figures for previous years, since the statistics available for previous years relate to examinations and not to individuals. I may mention, however, that in 1912, out of 7,326 examinations in colour vision, 163, or 2·22 per cent., resulted in failure. The figures for the two periods are not comparable, both because of the difference of basis, and because the Board of Trade have reason to believe that the number of candidates examined in the last two months includes an abnormal proportion of persons who have never been examined before, among whom naturally the percentage of rejections is disproportionately high.

* * *

Professor F. Lagrange.

THE French Académie des Sciences has recently awarded a prize of 1,500 francs to Professor Lagrange for his *mémoire* entitled "The Treatment of Chronic Glaucoma."

* * *

The Twelfth International Congress of Ophthalmology.

READERS are reminded that the Twelfth International Congress of Ophthalmology is to be held at St. Petersburg from the 10th to the 15th August, 1914, under the presidency of Professor L. G. Bellarminof. It is intended to hold four morning sessions for discussions, and one afternoon will be reserved for demonstrations. The last Congress, held at Naples in 1909 under the presidency of Professor Arnaldo Angelucci, selected two subjects for discussion at St. Petersburg, namely, (1) The Ætiology of Trachoma, and (2) The Nutrition of the Eye. The committee invite suggestions as to other subjects for discussion, and intimate that members who wish to make communications to the Congress must send their MSS., together with the enrolment fee, to the Central Bureau at St. Petersburg Ophthalmic Hospital, Mochowaja 38, addressed to the General Secretary, Dr. Th. Germann, not later than the 1st of February, 1914. The communications must be typewritten in one of the official languages of the Congress, *viz.*, English, French, German, Italian, Spanish, or Russian, and should not exceed five pages in length.

The subscription is 25 francs for each member of the Congress and 10 francs for each individual of a members' family who may desire to attend also. Notification will be made later as to reduced railway fares and other privileges to which members may be entitled.

The correspondents for Great Britain are Mr. Walter H. Jessop, 73, Harley Street, London, W.; Dr. George Mackay, 20, Drumsheugh Gardens, Edinburgh.

* * * *

Central London Ophthalmic Hospital.

On July 15th the new buildings of the Central London Ophthalmic Hospital in Judd Street were opened by the Duchess of Albany. The buildings consist of five floors and a basement, and provide for forty beds, in addition to an out-patient department, two operating theatres, bacteriological and pathological departments, an *x*-ray room, and a museum. There is also a common room for students, a library, quarters for the resident staff and clinical assistants, and on the top floor quarters for the nursing staff. So far as building expenditure is concerned, the institution is free of debt, but funds are still required for equipment, and at present it is not intended to utilize more than twenty-five beds.—*British Medical Journal*, July 19th, 1913.

* * * *

Hospital to be closed.

It is announced that the Halifax (Yorkshire) Eye, Ear, and Throat Hospital, which was established in the year 1886, will be closed at the end of the current year. The hospital, which possesses four beds, has been supported by its founder, Dr. John Oakley, until recently. He and his son, Dr. G. G. Oakley, had acted as surgeons, nurses, dispensers, and apparently in every other capacity, and they intended to resign at the end of the year. As a further reason for closing the Hospital (which has doubtless done good work in its time) it was pointed out that a special department had been started at the Halifax Royal Infirmary, an institution with 150 beds.

* * * *

Tobacco amblyopia.

We gather from an editorial article in the June number of our contemporary *American Medicine* that tobacco amblyopia occurs only in hyperopes and in hyperopic astigmia, a piece of novel information placed to the credit of de Lapersonne and Terson. When the refraction of such patients is corrected with suitable glasses, cure of the amblyopia is said to be speedier and more satisfactory.

* * * *

Norfolk and Norwich Eye Infirmary.

On July 16th last the new In-Patient Department of the Norfolk and Norwich Eye Infirmary was opened by the Duke and Duchess of Norfolk. The old premises, inconveniently situated in the slums of the City of Norwich, had long been condemned by the Medical Staff, and after some five years of negotiation with the Norfolk and Norwich Hospital a working arrangement was come to between the two Institutions, and what was once a detached dwelling house opposite the Norfolk and Norwich Hospital has been adapted —as well as possible—to serve the purpose of the In-Patient Department and Administrative Block. In the fairly extensive grounds attached to the house, a new Out-Patient Department has yet to be built.

To meet these changes the Duke of Norfolk some years ago gave £1000, and at the opening ceremony the Lord Mayor of Norwich (A. Samuel, Esq.), announced he would give £500 towards building the out-patient department. More is required if the Institution is to be freed from debt.

The history of the Institution is not uninteresting. Founded on July 11th, 1822, through the efforts of three medical men, it was, and is still, the only Hospital dealing solely with affections of the eye in the whole of the East of England. Nevertheless, until six years ago, it was staffed by general practitioners. It was one of the earliest hospitals to consider the question of treatment by the Hon. Medical Staff of a Charitable Institution of school children found defective by State Medical Inspection, and the Medical Staff by resolutely refusing either to treat such children or to agree to the appointment of a Clinical Assistant, have upheld the expressed principles of the British Medical Association, *i.e.*, that the Education Authorities should deal in this matter directly with medical men. The Infirmary also has what is somewhat unusual in this country, namely, a medical staff not entirely honorary. The Consulting Surgeon (one); Full Surgeons (two); Assistant Surgeon (1); Anæsthetist (one), are all honorary, while the Bacteriologist (one) is a salaried officer.

THE OPHTHALMOSCOPE DIARY.

	1913.	
American Academy of Ophthalmology and Oto-Laryngology.	October 27th to October 29th.	Chattanooga, Tenn., U.S.A.
	1914.	
Oxford Ophthalmological Congress	July.	Oxford.
British Medical Association: Section of Ophthalmology.	July 15th to July 17th.	Aberdeen.
International Congress of Ophthalmology.	August 10th to August 15th.	St. Petersburg.

THE

OPHTHALMOSCOPE.

A MONTHLY REVIEW OF CURRENT OPHTHALMOLOGY.

VOL. XI.—No. 10. OCTOBER 1, 1913. TWO SHILLINGS.

CONTENTS.

Original Communications.—

1. Emile de Grósz.—The methods of Cataract Extraction practised in the Royal Hungarian University Eye Hospital, No. I, Budapest ... 576
2. Lieut.-Col. R. H. Elliot, I.M.S.—Trephining in Glaucoma, acute and chronic: Miscellanea... 580
3. G. F. C. Wallis, M.D.—Elliot's Trephining for Glaucoma and its Technique ... 588
4. G. F. C. Wallis, M.D.—The Restoration of the Anterior Chamber after Elliot's Operation ... 594
5. T. Harrison Butler, M.D.—A case of Optic Neuritis with Retinitis and Consecutive Atrophy associated with Pregnancy ... 597

Clinical Memorandum.—

W. H. Brailey.—A Method of Operating upon After-Cataract, etc. ... 600

Current Literature.—

I. Anatomy and Physiology ... 601
II. Ophthalmology and General Medicine (second notice) ... 604
III. The Measurement of Ocular Protrusions ... 612
IV. Immunity ... 613
V. Pathology (fourth notice) ... 614
VI. Malformation of the Cornea as a Stigma of Heredo-Syphilis ... 617
VII. Rupture of the Optic Disc ... 618
VIII. Phlyctenulosis ... 619
IX. Pseudo-Glioma ... 620
X. Lymphorrhagia of the Fundus Oculi ... 620
XI. Membranous Conjunctivitis... 622
XII. Local Anæsthesia ... 624
XIII. Fracture of the Skull and Lesions of the Optic Nerve ... 625
XIV. Teeth and Eyes ... 626
XV. Anti-Glaucomatous Sclerectomy ... 627
XVI. Hydatid Cyst of the Orbit ... 628
XVII. Ætiology of Iritis ... 630
XVIII. Miscellaneous ... 632

Book Notices ... 634

The Ophthalmoscope Diary... 638

ORIGINAL COMMUNICATIONS.

THE METHODS OF CATARACT EXTRACTION PRACTISED IN THE ROYAL HUNGARIAN UNIVERSITY EYE HOSPITAL, No. 1, BUDAPEST.*

BY

PROFESSOR EMILE DE GRÓSZ,

BUDAPEST, HUNGARY.

I ESTEEM it a great honour to be permitted to address you on this occasion. Up to the last moment I felt somewhat reluctant and undecided whether I — whose labours are conducted so far from England—ought to raise my voice in this distinguished assembly. But the Secretary of the Society, Mr. Sydney Stephenson, encouraged me with so much emphasis that my scruples were at length overcome, and I would now only request you to accord your kind indulgence to my humble remarks.

For a long time I hesitated with regard to the subject on which I should speak. Should I refer to the researches made in the clinical laboratories? Should I speak on the ætiology of trachoma and its treatment? or should I set forth my own point of view with regard to operation for glaucoma or strabismus, or should I discuss the localisation and extraction of foreign bodies from the interior of the eye with the different magnets?

I decided, however, against all these themes, feeling that a part of them was unsuitable for treatment within the limits of a brief address, while the other part was down on the programme of the International Medical Congress to be held in London from the 6th to 12th proximo. Therefore, I have come to the conclusion to set before you the method that I follow in operating for cataract. This operation that we oculists most frequently have to perform is the very one by which we make our reputation, while, on the other hand, when unsuccessful, it affects us quite as badly as it does our patient. Even to-day cataract cannot be cured except by operation. Though the researches of Joseph Imre (one of my assistants) seem to confirm the theory of Römer, namely, that the formation of senile cataract is brought about through the influence of toxins, yet organo-therapy founded on this basis has failed to meet the case.

I have experienced about every phase of the *technique* to the present day. I come of a line of oculists, my father and grandfather having been oculists before me. When a mere youth, I used to witness the reclination of the lens; when an assistant, I took part in operations made in the beds of the old clinic; in unfavourable circumstances, I have served in public hospitals; and to-day I have the honour to be at the head of a large modern clinic. I have passed through both the antiseptic and the aseptic periods. In hundreds of cases I have applied the simple extraction method, and, finally, I have adhered to the procedure combined with iridectomy. I will not weary you with historical, literary, or statistical data, as I believe you are better acquainted with such things than I am, but will merely confine myself to setting before you the method that I follow. This procedure is neither strict adherence to past traditions, nor blind imitation, nor desire for innovation, but the result of my personal experiences, extending over the last quarter of a century. I have had ample opportunity to collect experiences, for although I cannot—like

* A communication made to the Oxford Ophthalmological Congress on July 17th, 1913.

our Indian colleague Smith—claim 24,000 cataract operations to my account, yet at the clinic under my control 400 to 500 cataract operations take place annually, so that my observations have comprised some 10,000 operations altogether.

As to the indication for the operations, it is my firm conviction that it is in the patient's interest to wait until the cataract is mature. I know very well that, trusting to the help afforded by irrigation of the anterior chamber and other cleansing methods, many oculists do not wait for the maturing of the cataract ; but I have often been convinced that for a speedy cure and for perfect and permanent sharp-sight, it is advantageous to wait for maturity. If there is a mature cataract in the one eye and the disease has not yet commenced on the other, postponement of the operation may, I think, be allowed : for the simple reason that the sight of the eye to be operated on would, in such circumstances, be of little use to the patient. Such postponement must, however, be for a limited period only. To sum up, although the prognosis of the operation in over-mature cataract may be good, it is not so favourable as in the case of mature ones ; I do not, therefore, recommend postponement for more than a few years. It is important to note the general condition of the patient ; although a cough, difficulty in breathing, or sugar in urine are not nowadays matters of so much importance as they were considered to be in the past. Even with 7 per cent. or 8 per cent. of sugar in the water, the convalescence may be undisturbed.

Age does not matter ; operations on patients of an age of 96 years are included in my series. But we attach considerable importance to the condition of the auxiliary and protecting organs of the eye. Especially since the researches of Elschnig, the control of the bacterial contents of the conjunctiva is very important. The researches made at Freiburg by my assistant, Joseph Imre, and those conducted at Budapest by my assistant, Leo Liebermann, as revealing the fact that the pneumococci play the greatest *rôle* in bringing about post-operative inflammation, are an excellent guide. Therefore, with the aid of the platinum loop, we take a little secretion from under the caruncula of the patient, and lay it on the plate. If the preparation contains no pneumococci, and the bacterial content be generally poor, the operation takes place. If the result be positive, we flush the conjunctiva sac daily with 1:10,000 mercury oxycyanide, in order to render the pathogenic bacteria innocuous. Should this fail, we drop in 10 per cent. argyrol three times a day. Should this also fail to destroy the pneumococci, we treat the conjunctiva with 2 per cent. silver nitrate. If the eye be actively secreting, the treatment last-named is followed from the beginning. Lately, blepharitis has been treated, on the advice of my assistant, Leo Liebermann, with 10 per cent. noviform ointment. In the event of dacryocystitis chronica, formerly we removed the lacrymal sac, and were but very seldom satisfied with the treatment by probes and the flushing with 10 per cent. protargol. Lately, in order to prevent abscess of the lacrymal sac and to ensure free passage, Dr. Louis Polyák cuts the naso-lacrymal duct endonasally, and opens the lacrymal sac from the nose. His cases are very encouraging. West, the American colleague, also has worked out a similar method in Berlin.

When we have by this method prepared the auxiliary organs of the eye, we must take care that the patient's digestion and bowels are regular and after having him instructed how to look up and downwards, take him to the preparation room on the second day after his reception at the clinic. There the nurses wash the eyelids and lashes and adjacent parts with neutral soap. Twenty minutes before the operation, the patient is given one drop of 5 per cent.

cocaine hydrochloride followed by one drop at intervals of five minutes, the last drop immediately preceding the operation. We then give one drop of 1:1000 adrenalin (Parke) and finally wash out the conjunctival sac with 3 per cent. sterile boric acid from the little jug which I show you. No antiseptic is used just before operation. The active concentration irritates the conjunctiva; the weaker is ineffectual. It is impossible to render the conjunctiva quite free from germs, so care must be taken not to decrease the resistance of the tissues, as well as not to increase the formation of the secretion.

We use an operation table of the Hirschberg type, the patient walking to his bed after the operation is over. In our clinic the operator stands on the right of the patient; in consequence operations on the right eye are made by the left, left-eye operations by the right hand, thus we are ambidextrous. The eye, before operation, is fixed and a cloth with a hole is placed over it in such a manner that the eye is left exposed, while the operator's fingers do not come in contact with the patient's skin or eyebrows. The instruments are sterilised as follows.—For every single operation they are prepared in a metal box. Each box, containing a registering thermometer, is wrapped in paper and put into a Luer steriliser for half an hour at a temperature of 150° Celsius. The boxes are not opened until the operation is about to begin. After use, the instruments are boiled and cleansed in potash-soap spirit, carefully wiped dry, and replaced in their boxes. A great number of boxes and instruments are, of course, necessary, but the care taken of them compensates for the expense thereby incurred.

The bandages are sterilised in steam. In the Lautenschläger autoclave the steam rises to 110° Celsius under an atmospheric pressure of 0·50. If there is not sufficient natural light, I think a hand electric lamp (the Hirschberg-photophor or the Hess-Hammer lamp) will, as artificial light, best meet the case. It is held by an assistant, so that its rays obliquely fall upon the field.

Our instruments are: the Graefe knife, the Liebreich forceps, the Wecker pince-ciseaux, the Shulek capsule-forceps, the Daviel spoon, the Graefe spoon, the Jäger sharp tenaculum, and an iris-spatula. For opening the eye-lids the Snowden speculum and to fix the eye the Weber forceps are used. We obtain our knives from Weiss & Son, the Wecker pince-ciseaux from Luer, while the remainder are manufactured by Tahy, instrument maker, of Budapest.

The instrument boxes I have already referred to.

We lay great stress on exactness in *technique*. On the upper part of the cornea we make an incision in the limbus as far as the upper third of the cornea with a flap of the conjunctiva. We take hold of the iris at the side of the pupil and sever it at a single cut. A large piece of the capsule of the lens must be drawn out with the Schulek forceps, and, finally, we press out the lens with the Daviel spoon. The great advantage of the capsule forceps is that a large opening is made in the anterior capsule directly in the pupillary area. The remnants must be removed by pushing up with the Daviel spoon into the Graefe spoon, the latter being supported by the posterior flap of the wound. After removing the congealed blood, we apply boric lint and two pledgets of wadding to the eye, fixing them with strips of sticking-plaster (our own speciality). The Arlt bandage is also used on the first day. Both eyes are bound up, the bandages being changed twenty-four hours later, after which the unoperated eye is allowed to go unbound. If the patient is restless, the bandage is removed from the unoperated eye after twelve hours; and should the patient's operated eye prove painful, it is bathed with 3 per cent. warm boric lotion.

It will afford great relief to the patient if the retained tears be removed. Six hours after the operation, he is allowed to sit up in bed, and should his back ache, he is allowed, twelve hours afterwards, to sit in an arm-chair. We never keep patients in bed longer than twenty-four hours.

We protect the eye against re-opening of the wound by means of the Fuchs' lattice appliance, which we apply on the second day after the operation. Bandages are used at first, but after four days, the lattice alone. After a week, the patient wears spectacles of medium grey. We do not darken the room, but merely exclude the direct rays of the sun. The pupil is kept dilated with 1 per cent. atropin. The patient usually remains at the clinic for two weeks, after which we make an examination of the sight to ascertain results. Having once left, some of our patients do not return, and at the expiration of four to six weeks we furnish them with suitable spectacles. The astigmatism of the wound is about 2D., but sometimes more. This is probably augmented by the wound being larger and by mild after-treatment. The Gullstrand glasses are therefore very valuable, as they prevent the distortion caused by the necessary cylindrical glasses. I must mention here that, after an undisturbed and peaceful recovery, the patient can—with exceptions—wear the glasses without danger within two weeks. If there is an after-cataract, I operate for that only after some months, and as carefully as possible, according to the Kuhnt method. The smallest breach suffices to make the sight complete.

As to the complications, the average number of our prolapses of the vitreous amounts to merely 3-5 per cent. When the vitreous appears before the delivery of the cataract, we remove it with the Graefe spoon. The reopening of the wound very often occurs, 5-8 per cent. This cannot be avoided, for the reason that many of the patients are ignorant peasant people lacking in will-power or self-restraint. With regard to post-operative inflammations, they are becoming fewer and fewer, thanks to modern efforts.

Any candid oculist must admit that the absolute prevention of post-operative inflammations has never yet been accomplished. We can no more operate for cataract without some amount of loss, than surgeons and gynæcologists can operate without some deaths. It does not depend entirely on our ability and knowledge, but on a great many different factors that influence success. The restless attitude of the patient, the condition of the conjunctiva, and even latent constitutional disease—all these may militate against our success. But with careful and conscientious preparation and after-treatment, supported by exact *technique*, we have succeeded in reducing the losses and post-operative inflammations to a minimum ; and the complications are so rare that there is but little prospect of their ever becoming rarer than they are at present.

In Hungary my colleagues especially operate in the manner I have described. Besides the three University Ophthalmological Clinics (two at Budapest and one at Kolozsvár), we have to-day seven State Ophthalmological Hospitals and fifteen ophthamological departments at the general hospitals, with altogether about 1,400 beds at the service of eye-patients.

As Government Commissioner for Trachoma Affairs, it is my earnest endeavour to get the number of eye-hospitals and ophthalmological departments increased ; being firmly convinced that these form the strongest point in the campaign against eye disease and blindness. In our country the State alone can provide for such requirement ; not so as in England where a powerful and wealthy Society stands ever ready to run to the aid of suffering humanity.

We are poor, our means are poor ; we are also few in number, the population of our land being less than twenty millions. Yet we know that at the Gate of

the Orient, a great historical *rôle* is incumbent upon us. For a thousand years we served the cause of civilization with the sword; to-day we serve it with the pen and the book. We ask the goodwill of the great, the magnanimous, the cultured British nation in the arduous, withal honourable, task we have to perform.

TREPHINING IN GLAUCOMA, ACUTE AND CHRONIC: MISCELLANEA.*

(*Concluded.*)

BY

LIEUT.-COL. R. H. ELLIOT, I.M.S.,

MADRAS, INDIA.

(1) *Homatropine as an adjuvant in the diagnosis of glaucoma.* (2) *The influence of various sub-conjunctival injections on the intra-ocular tension in glaucoma.* (3) *The causes of the variations in the difficulty met with in splitting the cornea during the trephine operation.* (4) *The best size of trephine to employ.* (5) *The best shape to give to the sclerostomy wound.* (6) *The nature, significance, and importance of the so-called post-operative iritis, met with after trephining.* (7) *Some causes of failure after trephining.*

(5) In performing a sclerostomy, what is the best shape to give to the opening in the sclera?

In the course of a review of my recently published book on sclero-corneal trephining, a writer in the *Ophthalmic Review* (June, 1913) suggests that cases of trephining and of the modifications of Lagrange's operation ought to be called "sclerostomies" and not "sclerectomies." As our object is to establish an opening in the scleral or sclero-corneal tunic, his suggestion is obviously sound, and I propose to adopt it in the future. I think it will meet with wide acceptation. I have endeavoured to look at the question of the best shape for a sclerostomy from the view-points of those who have advocated other operative measures; and yet the conclusion that a circular wound is ideal, becomes more and more a rooted conviction in my mind. I have brought the matter up to-day in the hope that the opposite side may represent its views, and in order to pave the way for this, I shall merely state the case in favour of the trephine, as it appeals to me:—

i.—The ultimate size of the scleral wound should be reduced to the minimum consistent with the establishment of permanent and efficient filtration. By using a trephine, we can effect our purpose with an aperture which in no diameter exceeds 1 mm. or 1·5 mm. It will hardly be contended that the breadth of a sclerectomy wound can be reduced appreciably below this limit, whilst by any other method the length of the wound must be several, if not many, times as much as this. Moreover, for any definite length of incision made, a circular wound obviously gives the maximum possible of surface area.

ii.—It is inadvisable temporarily to make a larger wound in the sclera than that of which we intend to avail ourselves for the purposes of permanent filtration. If we do so, we thereby unduly weaken the ocular tunics, and so deprive the contents of the eye of their wonted support at the critical stage

---

An address delivered at the Oxford Ophthalmological Congress on July 17th, 1913.

of the operation. The circular trephine hole alone fulfils this condition, and does so in an ideal manner.

iii.—The shape of the wound should be such that the filtering channel obtained is not likely to be encroached upon during the process of healing. It is obvious that the ends of an elliptical wound will tend to become shortened by the union of adjacent raw surfaces, whilst the equidistance of all parts of the circular trephine wound will tend to keep the wound of its original size, provided always that no inflammatory action is started. In the latter case, *any* wound will fill up and close.

iv.—In the interests of scientific accuracy of method, we should be able to determine in advance the exact size of the sclerostomy we intend to perform, and to give mathematical effect to such a determination when the time comes to translate it into operative action. This can certainly be done with the trephine. One of the leading instrument makers has recently provided sets of blades of various sizes, which all fit into a single handle, and are packed in a compact case, so that an operator has the means at hand of varying his size of instrument at will.

v.—The investing coat of the eye, on the support of which so much depends, should be in no way unduly or unnecessarily weakened. The trephine leaves a clean-cut, straight-walled canal of the desired size, of uniform calibre throughout, and running perpendicular to both surfaces of the ocular tunics. Can the same be said of the channel made by any other method of performing sclerostomy?

(6) The Post-operative Iritis met with in Trephined Eyes.

What is its real nature? What is its significance? How far is it to be considered as important?

I cannot help thinking that there is a good deal of misunderstanding in connection with this complication. Several quite diverse conditions seem to have been included under one heading, with the result that differences of opinion, often more apparent than real, have sprung up. In order to invite criticism, I shall state the case from my point of view. Three conditions at least appear to be confused by some recent writers on this subject, *viz.*, (1) the commonly occurring post-operative complication, usually called "quiet iritis," with which every surgeon who has done much trephining is familiar; (2) an exacerbation, or may be merely a continuance of an acute or sub-acute condition which existed prior to the operation; and (3) a true septic condition of the wound, due to an accidental contamination at or after the operation.

Unless these three conditions are clearly defined in a surgeon's mind, and definitely separated in his case-sheet analyses, he will be apt to do grave injustice to the operation of trephining and surgical science will suffer unjustly thereby. I therefore propose to discuss each head in turn.

i.—**A quiet iritis** is unpleasantly frequent after trephining, but is it really a result of the operation? Is the *technique* of the procedure to blame? I think not, and I shall give my reasons for venturing such an opinion:—this complication is not marked by the incidence of any of the usual signs of an invasion of iritis; pre-existing pain is relieved by the operation, signs of congestion diminish, vision improves, and the patient appears to be making excellent progress; so much so that unless we are forewarned and thereby forearmed, we discover the complication only when it is too late. Since we have adopted in Madras the vigorous antisepsis of the conjunctiva, our practical acquaintance with post-operative sepsis has become very small; but it was not ever thus, and in those early days one saw a truly lamentable amount of post-operative sepsis, due doubtless to the

frequency with which the conjunctiva harbours septic organisms in the East. Looking back on my all-too-extensive past experience of this complication, I can say without the least hesitation, that the type of iritis we are now discussing, has nothing in common with a septic uveitis due to accidental contamination of the wound at the time of operation. It is true that surgeons recognise a "quiet iritis" occurring under quite other circumstances, and somewhat closely resembling that we have under discussion, but I think that most people agree in attributing it to constitutional causes, and in considering that its type is quite distinct from that of the great majority of post-operative infections.

The natural question asked will obviously be "If this is not a post-operative inflammation, what is it?" I wish to put forward the suggestion that it is the manifestation of a condition existing before the operation, but unable to find expression until the altered physical conditions empowered it to do so. To begin with, the act of trephining alters the relations of the parts which border on, or project into, the aqueous chamber. The chamber is for a time at least practically empty, with the consequence that the iris lies in direct contact with the lens capsule, the posterior chamber being temporarily reduced to a potential cavity; at the same moment the long-continued dilatation of the pupil has given place to a state of more or less marked contraction; so that here we have to hand the very conditions which render the formation of posterior synechiæ most easy. Then, again, there can be little doubt that the nature of the fluid secreted under the new conditions may be such as to render the deposition from it of fibrin more liable to occur, without in the least premising any access of inflammatory action.

I have been asked why this quiet iritis is so much more often met with after trephining than it was after the old iridectomy. I would first reply by another question. Is it really the case that it is more frequent? It is far from an infrequent experience to see the iris tied down after an iridectomy for glaucoma. It must not be forgotten that after a well-performed iridectomy, the chamber will be completely closed in a few hours, and probably often after only a few minutes. Remember, too, that a wide coloboma makes the effects of posterior synechiæ both less obvious, and less injurious to the results, since it leaves a wide area for visual purposes, even should some amount of adhesion take place between the iris and the deeper parts. I suggest that surgeons should carefully watch their cases for the occurrence of this *so-called* quiet iritis (I fear I am myself to blame for thus christening it), with a view to establishing its relative frequency under the old and under the new operations. I need hardly point out that if such statistics are to be of any value, the possibility of the occurrence of this quiet complication must never be lost sight of in the iridectomy cases, no matter how well they seem to be doing. It is an old adage that we only see what we look for, and I think that most surgeons will agree with me that many deductions from statistics would require profound modification were the notes taken daily on a schedule which reminded the over-worked observer of the possible, and still more of the probable, complications he has to be on the look-out for. I am making no reflection on the work of any one, but merely entering a plea that the importance of the subject demands a thorough and unprejudiced enquiry into the facts. I would go a step farther and ask, what is the real importance of the subject? To my mind, it lies solely in the fact that it may weigh with timid surgeons, and deter them from trephining. I have shown most conclusively, over an experience of many hundreds of consecutive cases, that a solution of atropine may be safely used on the second or third day, and that if this is done, we need no longer

fear post-operative occlusion of the pupil. Others have confirmed this statement, whilst a few have gone farther still, and instilled atropine drops at the close of the operation. I do not think it is necessary to do this so early. Of one thing I am quite sure, *viz.*, that the use of a strong mydriatic is positively harmful, if, on the second or third day, we find iris tissue plugging the wound and causing a rise of tension thereby. Eserine and not atropine is then called for, if reliance is to be placed on drugs at all. One cannot help feeling that if the use of atropine aggravates the blocking of the wound, when it is present, it may bring it about when the tendency to the accident is in the ascendant, or even in existence. Whatever the individual surgeon's final decision may be as to the exact date at which atropine should be instilled after trephining, there can, I think, be no disputing the fact that the condition which gives rise to synechiæ in this quiet way after the operation of trephining, and which, for want of a better term, we at present call a "quiet iritis," can be controlled and rendered harmless, if the surgeon is on the alert, to recognise the risk, and promptly to treat the condition by maintaining full mydriasis, whenever the use of atropine instillations reveals a tendency to the formation of posterior synechiæ in a recently trephined patient.

A very different view must be taken of the two other conditions we have still to consider. We will take them in turn :—(ii). **A continuation of, or even exacerbation of, an acute or sub-acute condition which existed prior to the operation**, may severely try the nerve and resources of the surgeon. The condition is to be treated on ordinary lines, and with that side of the question we are not now concerned. A much more important thought is suggested by such cases. Everyone who has dealt with large numbers of glaucoma cases and has pondered over their almost endless variety, has probably come to the certain conclusion that whilst the term glaucoma is a very convenient label for a huge mass of cases which all have the common feature of a rise of intra-ocular tension, the causes which bring about this rise in tension are many and various.

The stormy course of the affection, once the rise in tension has become established, serves to monopolise the surgeon's attention, distracting it from this very important aspect of the case. If I may be permitted a simile, it would be that of a man standing by the bank of a narrow cataractous river which is fed by a number of broad slowly moving streams. The tossing, turbid, rushing torrent impresses his imagination far more than do its quiet tributaries; and he leaves with the lasting impression of tumultuous waters predominant in his mind, to the exclusion of the very streams on which the torrent depends. I think that this is the position, even now, of many who are engaged in the treatment of glaucomatous patients. We are apt to forget the ætiological side of our cases in the absorbing interest of the momentous factor of increased tension. Priestley Smith has set us an inspiring example, and others have followed in his footsteps, but we are still groping in twilight. I think that one important element in the situation is that of intra-ocular sepsis. I use the term in its largest possible meaning, and I have been led to make this observation from a clinical study of the very class of cases we are now considering. Two explanations may be offered of the continuance or increase of intra-ocular congestion after operation for glaucoma. It may be due to (1) the continuance of a septic action which was in existence before we operated, or (2) an accidental infection at the time of operation. The subject is a difficult one and requires careful study, but will, I believe, well repay the pains spent on it. To begin with, the usual course of a case of congestive glaucoma, after successful

trephining, is that the signs of congestion rapidly subside, and the eye returns quickly to its condition of health. This is obviously what should happen if the main trouble is a condition of intra-ocular congestion brought about by a rise in the tension of the eye, for by lowering that tension, we have removed the cause of the congestion. When this happy result is not attained, we are justified in concluding that another factor has complicated the problem, and that factor often is, in my opinion, some form of sepsis. The really important point, to which we now come, is the source of this sepsis. Has it been introduced by the surgeon, or was it there before he stepped in at all? Is he to blame for it, or is it merely a complication he must expect to meet with, despite the most careful *technique*? Speaking from a clinical standpoint, I have no hesitation in affirming that the latter answer to each of these two questions is the correct one in a number of instances. The first point I would make is that the congestion present remains practically unchanged after operation, or, at most, undergoes the slight aggravation which may be expected after mechanical interference. Now this is not consistent with the theory of introduced sepsis, which we all know begins to manifest itself about the third day, and rapidly increases in intensity during the few succeeding days. When a more marked aggravation of the signs present manifests itself, the solution of the problem becomes more difficult, but even then we meet with not a few cases in which it is difficult to decide whether such aggravation is due to the amount of interference at the time of trephining or whether a farther explanation is called for. The second point is the frequency with which we find adhesions between the iris and the cornea in late cases of glaucoma, in which there has been no operative interference whatever. Of evidently the same nature is the peri-limbal matting, which, when it exists, makes "splitting" of the cornea difficult. Again these cases tail off imperceptibly into those of the so-called "quiet iritis" discussed under the preceding heading, for one meets with an eye in which the marked pre-operative congestion markedly subsides, and all appears to be going well, and yet close synechiæ may form, and sight be impaired or lost if by any chance the surgeon is caught napping. My third and last point is based on a class of cases with which you are more familiar in Europe than we are in India. A patient, often with a gouty history, develops evidence of raised tension. He is advised to diet himself, to take more exercise, and to take more care of himself in a variety of ways, with the result that he very speedily improves in his general health, and at the same time the signs of increased tension disappear, to the great relief both of doctor and of patient. I think that many of you will be able to remember such cases. The plain meaning of them would appear to be that the threatening of glaucoma was due to a toxic condition, which has been removed, or at least ameliorated, by the constitutional treatment employed. I do not pretend to assign the threat of raised tension definitely to bacteria or to circulating toxins, but prefer to leave the matter open. One cannot review the above evidence without a deepening conviction that toxicity, possibly in many forms, is playing no unimportant part in the pathogenesis of some, at least, of the conditions which we now, for convenience sake, are content to group together under the term "glaucoma" I do not doubt that there are many who have thought with me in these matters, even if some of them have not formulated their ideas so definitely as I have just done. I would ask any such, or any whose ideas are in sympathy with mine, to look back for a moment over the work of the past few years, with its triumphs in bacterial diagnosis, in serum reactions, and in vaccine

therapy. What does the future hold for the surgeon interested in glaucoma? Is it possible that a new era is dawning, an era in which the newer medicine, the medicine that has sprung Minerva-like from the microscope and the laboratory, will stand shoulder to shoulder with the newer glaucoma surgery, the surgery that, be its technical variations what they may, finds expression in the magic of the word "sclerostomy?" May we not look forward with confidence to the day when this dual alliance will still further rob glaucoma of its terrors, believing, as we must, that medicine so applied will not merely make surgical interference more secure, but that it will go farther still and save a number of glaucoma cases from the need to resort at all to the knife or the trephine?

(iii) **A Septic Condition of the Eye, due to Contamination at the time of Operation,** requires little comment here. In nearly 900 consecutive cases trephined in Madras since the first operation of that nature on August 2nd, 1909, we have not had a single case of suppuration of the globe, nor have we had any cases of serious irido-cyclitis, which could without hesitation be put down to septic contamination in the theatre. I do not say that we can absolutely exclude an element of sepsis in some of the cases in which an irido-cyclitis existing before the operation, continued thereafter, sometimes in an aggravated form. That would be an irrational claim, and no one could make good such a position. Be the method of operating what it may, we shall get such cases, and in the present state of our knowledge, we cannot with certainty differentiate between them and those discussed under the previous heading. India is a land where sepsis is rife, and we have seen a wonderful change come over our practice, since we have employed rigid conjunctival antisepsis. If there is one proposition which I would venture to put forward with less hesitation than any other, it would be that contamination of an operation wound *depends very little indeed on the particular method employed*, and practically entirely on the preparatory *technique*, especially on conjunctival asepsis or the reverse. I make these remarks because others have attributed their failures to what they consider is the scanty protection afforded by the thin conjunctival flap. Under cover of this explanation, there have been included cases of quiet iritis, cases of varying degrees of irido-cyclitis, and even losses of the eye due to panophthalmitis. I venture to think that the data on which such conclusions have been founded have often been insufficient for the purpose. I would remind you, firstly, that the layer of anterior epithelium suffices, so long as it is intact, to guard the cornea against the inroads of so virulent an organism as the gonococcus, and, in the second place, that the great majority of our wounds in Madras are healed, and the chamber thereby sealed, on the first dressing. Finally, our Madras experience of nearly 900 cases, already quoted, shows that the conjunctiva, when properly dealt with, affords sufficient protection to the important structures it covers. With quiet iritis I have already dealt sufficiently.

(7) Some Causes of Failure after Trephining.

(i) **Dislocation of the Lens or Vitreous Body towards the trephine hole.**—It sometimes will happen that on the day following the operation, tension is found to be still high, and a bead is observed bulging into the aperture in the sclera. An immediate diagnosis is called for, since so much depends on the correct treatment of the condition, which may be that of presenting lens or vitreous, on the one hand, or of prolapsed iris, on the the other. As the treatment of these two sets of conditions is very different, it is essential we should make no mistake at this stage. Fortunately, the differentiation is usually quite easy. All that is necessary is to use a lens and throw a strong beam of

light on the edge of the cornea from below (when the trephining has been made above), and at the same time, to observe the bulging bead. If this consists of iris tissue, it remains opaque, whilst if the offending mass consists of transparent tissue (lens or vitreous body) the bead is illuminated and an opalescent appearance is at once obtained. The diagnosis can be advanced one stage farther, with at least some degree of probability of correctness, if we have observed whether there was evidence of intra-ocular hæmorrhage at the time of operation, and if we note the relative depth of different parts of the anterior chamber, when the bulging is under examination. We shall take these two points in turn.—(1) When at the close of the operation, the tension of the eye suddenly rises, we may safely conclude that an intra-ocular hæmorrhage has occurred, and although dislocation of the lens is not to be forgotten, the great probability is in favour of vitreous rather than lens being thrust into the hole. The immediate indication is to close the eye, and return the patient, as quietly as possible, to bed. On the other hand, if the blockage is first noticed when the eye is inspected on the second or third day, we are more likely to be correct if we think of dislocation of the lens, rather than of presenting vitreous. (2) A careful inspection of the aqueous chamber under oblique illumination, will often reveal that its anterior division is shallower in the neighbourhood of the trephine hole than it is in the opposite quadrant. This is a most suggestive sign, and it will be safe to conclude that it indicates a displacement of the lens. What are we to do? We may settle the diagnosis by puncturing the protruding bead with a cataract needle, when the nature of the escaping contents will at once set all doubts at rest. Is this good surgery? I think that it is a grave mistake to be premature in taking such a step, although one may be driven to it. Later, I shall give my reasons. If the case is one of impaction of the ocular contents in the trephine hole under the pressure of an intra-ocular hæmorrhage, the obvious thing to do is to await the cessation of the bleeding and the subsequent absorption of the blood. This complication is met with only in long-standing and desperate cases, and premature interference will probably aggravate the mischief, whereas if we take the ordinary steps for the arrest of hæmorrhage (both general and local), we shall not infrequently find that the tension falls, and a less hopeless result is obtained than we had anticipated. If in the course of three or four days things do not mend, we can puncture the bead of bulging matter, knowing that, desperate as the remedy is, the condition is still more so, and demands drastic action. The escape of fluid vitreous may better the conditions and lead to a fall of tension, although one, of course, recognises that one is fighting with one's back against the wall. Stranger far to my mind is the observation I have elsewhere published, namely, that if the incision of the bead leads to the extrusion of lens matter, the tension is sometimes at once relieved, and yet widespread opacification of the lens does not always occur. A possible explanation of this has been suggested to me, which I offer in a purely tentative spirit.—It is suggested that a fine funnel of capsule and semi-fluid lens matter is thrust into the hole, and that when this is peripherally punctured, the semi-fluid contents escape, and the mouth of the funnel becomes sealed, immediately by twisting, and later by exudation. It is difficult to understand where the twist comes from, and possibly the mere collapse of the fine funnel of capsule is all we need postulate; but in any case the clinical observation above recorded stands in several very carefully noted cases. The opinions of other surgeons on this phenomenon will be gratefully received.

What is the pathological explanation of these cases of presentation of the lens or vitreous body? We have had the opportunity of examining two cases

in Madras which throw some light on the matter. I think it will be generally admitted that in a large number of instances, the first event of moment in the development of the glaucomatous state is an *increase in the volume of the vitreous body.* How that is brought about does not concern us now. The effect, however, is well-known, and consists of a push-forward of the diaphragm of the eye, *i.e.*, of the lens, suspensory ligament, ciliary body, and iris, with a corresponding shallowing of the anterior chamber. Such a condition, if long-continued and extreme, must obviously lead to an over-stretching of the suspensory ligament, and hence results in the lens possessing an undue freedom of movement so soon as the *vis a tergo* is removed or lessened. Anatomically, we have twice observed a dislocation of the lens in sections of frozen eyes removed after trephining, and in both cases it appeared that *the ligament was so unduly lax as to have permitted the lens to tilt and move bodily towards the trephine hole.* There was nothing to indicate that intra-ocular hæmorrhage had played a part in the phenomenon. In one case the lens was separated from the trephine hole by uveal tissue, whilst in the other it presented directly into the hole. With our present *technique*, it is obvious that presenting vitreous must press the suspensory ligament in front of it.

(ii) **Prolapse of Uveal Tissue into the Trephine Hole.**—There can be no doubt that the tissue commonly protruded is iridic, although the ciliary body may easily be involved in the misfortune, thus rendering the case much more serious from every point of view. If the ciliary body is pushed far forwards, or if the iris-base is adherent to the corneal periphery, then tethered uveal tissue lies in close propinquity to the aperture in the sclera and is much more likely to prolapse into the wound than it is when it lies free of abnormal attachments, and with a good space separating its base from the margin of the hole. Uveal tissue may be pushed into the trephine hole by a dislocated lens, as we have proved anatomically, but this is probably a very rare event, and it is, I think, safe to assume that in the vast majority of cases, the impacting tissue has been washed into the hole by escaping aqueous fluid, the accident being strictly comparable to that which is so dreaded a complication of the course of a cataract case in the first few days after operation. The lessons to be learnt from this are two-fold: (1) always to combine a small iridectomy with a trephining, and (2) never to hesitate to lay back the flap and excise prolapsed iris as soon as it has been diagnosed as the cause of a return of increase of tension. The importance of an anterior trephining, and of avoidance of any drag on the iris during the iridectomy, have already been strongly insisted on. The results of early excision of prolapsed iris are excellent, and the operation, although a delicate one, is not difficult.

(iii) **Blocking of the Trephine Hole by a Proliferation of Connective Tissue.**—Time does not permit of my discussing this matter at any length; but I desire to reiterate the conviction expressed in my book on "Sclero-corneal Trephining," and arrived at on clinical grounds, that such an accident does occur, and that the proliferating tissue may be derived from two distinct sources, *viz.*, (1) the episcleral tissue lying beneath the conjunctiva, in the neighbourhood of the trephine hole, and (2) uveal tissue lying on the deep surface of, or projecting into, the trephine hole. Whilst it is essentially in long-standing chronic or sub-acute congestive eyes that this blocking is likely to be met with, there can be no question that it is not by any means a common occurrence even in this unfavourable class of case. I have been able to examine macroscopically several eyes which seemed to confirm my view as to the dual ætiology of the obstruction. Unfortunately, our Indian method of

preserving these eyes has made the microscopic evidence unsatisfactory; but one very kindly cut for me by Mr. Sydney Stephenson and now on view in the Scientific Museum attached to the Congress, has, I venture to think, clearly shown that the blockage of a trephine hole by proliferative tissue is an indisputable actuality. I hope to return to this subject in the near future, armed with sufficient microscopical evidence derived from more suitably preserved specimens.

[THE END.]

ELLIOT'S TREPHINING FOR GLAUCOMA AND ITS TECHNIQUE.

BY

G. F. C. WALLIS, M.D.Edin.,

LATE SENIOR HOUSE SURGEON, ROYAL LONDON OPHTHALMIC HOSPITAL (MOORFIELDS) AND THE BRISTOL EYE HOSPITAL.

ELLIOT'S trephining operation for chronic glaucoma has now been in vogue for a sufficient time to enable one to judge the results. At Moorfields I had the opportunity of observing the results of trephinings done before my term of office, and also the more immediate effects of those done during that term. In the past year this procedure has almost entirely superseded Herbert's sclerotomy in chronic glaucoma.* The conclusion had gradually been established that the tension, after the latter operation, did not remain permanently normal in a majority of cases. The operation of iridectomy, for other than acute glaucoma, has been but rarely performed. Now, although the desired end has usually been obtained by means of an Elliot operation, in a proportion of cases disappointment has followed, the tension returning, after a time, to above the normal. This occurred in some after many months; in others after only a few weeks; and in one the next day.

This operation is considered by many ophthalmic surgeons to be a simple procedure, and therein probably lies the cause of failure. Excellent as the operation is, I have no hesitation in saying that it is a difficult one. True, it is perfectly simple to trephine a hole of sorts in the corneo-sclera, but to make one so that it remains patent for all time, is an entirely different matter. It has been my good fortune to assist each member of the staff at many Elliot operations. The conclusion that has been forced upon me, is that a constant good result can be obtained only by most rigidly carrying out the exact details of *technique*. Now, early personal experience showed how difficult it is to perform consecutive operations in exactly the same manner. I therefore determined to observe more carefully the procedures of the various members of the staff. With this object, I took fully detailed notes of the last sixty operations performed at Moorfields. They fully bore out the above contention, and also showed that the *technique* varied not a little with each surgeon.

In this article I propose to deal in detail with the *technique* that has appeared to me to give the best results.

---

* In not a few cases an Elliot's trephining has been resorted to in acute glaucoma with satisfactory results. This operation has usually been done when the pupil has been dilated and inactive to a myotic, or when a general anæsthetic has been contra-indicated.

i. The site.—All are agreed that the place of election for the flap is immediately above the cornea.

ii. The conjunctival flap.—This must be as large as can conveniently be made. It extends to within 4 mm. of the fornix, and should be shaped as in the diagram—the outer limits must not pass closer to the cornea than the top level of that structure. Not infrequently one sees small narrow flaps made in which the incisions are carried up to the cornea. This is a great mistake. Objections have been raised to the difficulties of making so large a flap, of the after-suturing, and to the risk of opening Tenon's capsule. This latter is

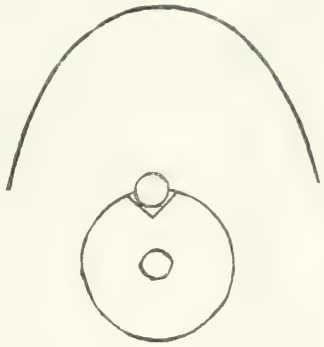

Diagram to show shape of flap, position of trephine, and shape of iridectomy.

unlikely to occur, but no particular harm would result if it did happen. To the two former I shall refer later. Elliot has noted that the edges of the conjunctival flap frequently heal down to the scleral tissue: this has been the condition in every case that I have observed. At a later date, unless a stitch has been used, this scar is apt to be very broad, partly from the retraction of the flap, and also because the escaping aqueous and lid pressure tend to push the flap downwards. As the result of this, and of the adhesions at the side, the filtration is limited to the size of the flap. If the incision has not been carried up to the cornea, it is possible for aqueous to pass into the subconjunctival tissue beyond the flap. This however is more potential than actual, for it seldom occurs because with a large flap a sufficient filtration is able to take place under the flap without passing beyond its limit. Although a wider diffusion is infrequent—two cases—yet, it is desirable to have every possible advantage. A large flap is a much greater security against infection; in one case purulent conjunctivitis developed the day succeeding the trephining, but owing to the large flap, no untoward result followed. It is for these reasons that the flap should be large and that it should not be brought down to the cornea except in the middle.

For the slight "splitting" of the cornea which is necessary to complete the flap, some surgeons prefer sharp-pointed scissors and others Desmarres' knife. Scissors offer the very great advantage that it is impossible to incise the cornea too deeply, but in spite of this, Desmarres' knife, used with caution, is, I think, preferable. With this latter instrument the incision being completed in three, or at the most four, strokes, the resulting surface is smooth. The smoothness is of importance, as there is less likelihood of the two surfaces healing together at a later date. With scissors many snips or tears are necessary, the time taken is longer, and the surface is rough. Furthermore, it is less easy to incise the cornea sufficiently, and there is much more risk of button-holing the flap. Toothless Moorfields stitch forceps should be used for handling the

conjunctival flap throughout the operation; the fine serrations give a quite sufficient hold, and the risk of tears is much less than with fixation forceps, and is indeed practically *nil*.

In order to obtain the large flap, the exposed upper limit of the conjunctiva is picked up with stitch forceps and gently slid towards the cornea. It is then held in this position, by the end of the tenotomy scissors, whilst a fresh hold is taken with the stitch forceps. By this means as much conjunctiva can be obtained for the flap as is desired. The conjunctiva is then snipped on the upper side of the forceps, a blade of the tenotomy scissors is run underneath in the same manner as when doing an excision, and the incision completed in the desired shape. The flap should then be dissected off with the sharp pointed scissors (these cut subconjunctival tissue better than tenotomy scissors) until the "corona" is well defined. In defining the "corona" the flap should be held lightly over the cornea, for if taut the "glans" like appearance is masked. The cornea is now "split" with the knife; it is most important not to attempt this before the "glans" is evident, as otherwise the knife will slide about on the loose subconjunctival tissue. That part of the knife where the curve joins the straight edge is used, for it permits more even sweeps and is sharper. Three strokes, or at the most four, are amply sufficient if each incision exactly coincides with the former, thus ensuring a smooth surface By holding the blade at about 35° to the sclera there is small risk of incising too deeply. A microscopical section through an incision so made, in an eye before enucleation, showed that it was entirely within the parenchyma, being parallel to the epithelial layer, and at a depth equal in thickness to that layer.

Accidents.—Button-holing of the flap is a rare accident, most liable to occur if there be continuous oozing obscuring the parts. It usually happens when the corneal part of the flap is being completed. If the flap has been made in the manner described, there is usually plenty of room to do the trephining a little away from the centre; should, however, it be impossible to avoid making the trephine opening too near the edge of the flap, it is advisable to stitch the flap up and make another to one side. Oozing frequently happens, in spite of full blanching with adrenalin before the commencement. Adrenalin applied after the tissues have been opened up is of little service and reliance is then to be placed in gentle but firm pressure. Failing this, the flap should be turned back into its proper place and left there for two or three minutes, which seldom fails to arrest the hæmorrhage. A bloodless area is an essential for a perfect operation.

iii. **The trephining.**—A most important point to decide upon is the calibre of the blade. For routine work the choice lies between a 1·5 mm. and 2 mm. diameter; in exceptional cases a 2·5 mm. or even a 3 mm., but never a 1 mm. The whole success of this operation depends on obtaining a good, clear, sharply-cut hole in the corneo-sclera. The use of a 1·5 mm. or a 2 mm. depends somewhat on the personal factor. I always find it easier to obtain the clear and complete trephine opening with the smaller of the two, but the 2 mm. has several important advantages. With this latter, the *plaque* is much more easily removed with scissors if trephining is incomplete. There may arise the necessity for manipulation within the anterior chamber—adhesion of the base of the iris, the *plaque* having entered the anterior chamber, or a pillar of the iris coloboma having become entangled—for all of these conditions the 2 mm. is incomparably more advantageous; probably then, this is the better size to use. In a few cases failure is possibly due to the opening being too small, and then a 2·5 mm. or even 3 mm. may be used for the re-trephining. The instrument must be as sharp as possible. If re-sharpened more than twice, the edged portion becomes conical, and then,

although keen, it will not cut well. Spare blades should be examined on a piece of wax, as those supplied are not always of standard calibre. Lang's concave handle is the most comfortable to use.

The site of the trephining.—The ideal position appears to be half corneal and half scleral. It is easily possible to open the anterior chamber, although the trephine is placed entirely upon the sclera. In this position, however, the trephine opening is situated opposite the base of the iris, which then does not readily prolapse. In one or two cases as many as three trephinings have been done in the one eye, each with a large iridectomy, and after each the tension has returned to above the normal. Eventually, black bulging spots presented at the sites of the trephine openings. These were cases of scleral trephinings, but which were well within the anterior chamber. I am inclined to think that the ciliary body must have come forward and blocked the opening. For these reasons the trephine should not be too peripheral. If the cornea be "split" far enough, as can readily be done, the trephine gap can be made entirely in the cornea. Some cases that have relapsed early were trephined in this position, and their sclerosed appearance suggests that when so placed, the cornea is more liable to heal down firmly, and so to stop permanent filtration.

Whilst the trephine is being used, the eye should not be fixed, but the operator should hold the flap lightly and almost at right angles to the cornea. In this way the eye is steadied without pressure on the globe, and the anterior chamber is not obscured from view. Some surgeons have the flap held out of the way of the trephine by the assistant pressing it against the cornea with an iris spatula. This, however, prevents the anterior chamber from being seen, and tends to expel the aqueous too soon.

The selected site is marked by a turn of the trephine, and then swabbed dry to see that it has been properly placed. This is *the only examination that is really necessary.* The trephine is then replaced and held sloping a little anteriorly to the vertical to the tangent of the cornea. Half revolutions are slowly made with moderate pressure *until the trephine is felt to be in the anterior chamber.* More than one examination cannot help and may do much harm. For if there be no opening into the chamber in any part when the inspection is made nothing is gained, as the trephine must be again resorted to. But should a portion of the circle have been cut through, the aqueous is lost, and the rest of the process must be completed with scissors. Repeated examinations cause rough and jagged edges, and frequently flaking of the *plaque.* When the trephine enters the anterior chamber, there is a sensation of "suction" (as described by Elliot) which, having been once felt, is quite characteristic. It is apparently due to the enlarging calibre of the trephine, as it sinks into the anterior chamber, being gripped by the sclera. The assistant may also see the trephine entering the chamber and give the warning, but the sensation of "suction" is by far the best guide. The trephine must then be eased out slowly and gently, when the aqueous escapes, carrying with it the iris and *plaque*, the latter being attached by a minute hinge to the sclera, which is snipped through. On the first occasion that one feels the trephine in the anterior chamber, one is strongly tempted to jerk it out for fear of damage. Should this be done, a negative pressure will be created, and the *plaque* may be sucked back into the chamber. There is no risk of damage to the iris or other structures, for as long as the anterior chamber is present, these give before the trephine. The trephining may be very slow, as the result of the trephine being re-sharpened and conical, from insufficient pressure upon the instrument, or from a thick sclera. It is surprising how the latter apparently varies in thickness, but in any case, I cannot emphasise too strongly the importance of avoiding repeated examinations.

In the event of imperfect trephining, if the trephine has been held slightly forward, as before stated, the portion still attached will be the posterior third. When the *plaque* is snipped out, the gap will be nicely over the anterior chamber. For this purpose de Wecker's scissors are not strong enough, and also the *plaque* is apt to flake or be cut very obliquely when they are used. The points of the small scissors are the best, but, however, successfully used, the gap is never so smooth or large as when accomplished by the trephine; a 2 mm. disc removed in this way is eventually equal to a 1·5 mm. gap. After a glaucoma iridectomy, a subsequent trephining must be made well away from the coloboma, for otherwise there is no protection to the lens or zonule.

Accident.—The *plaque* entering into the anterior chamber is the most disconcerting trouble that can arise during the operation. As stated above, it appears to be due to a negative pressure created by too rapidly removing the trephine. It has occurred on some seven occasions in one hundred and thirty-seven operations; with one exception, the disc was always attached by a minute hinge of tissue. In this single exception the efforts at removal may have ruptured such a tag. Even although the *plaque* be attached, it is often very difficult or impossible to remove. This appears to be most readily accomplished by passing the single-toothed end of the straight iris forceps into the anterior chamber, and thus hooking it out. Sometimes the introduction of an iris repositor, in addition, to aid in steadying the disc, is of assistance. If the *plaque* be completely severed, irrigation (suggested by Elliot) may be of use to wash it up towards the gap, but I have not seen it successful in removing it. In two patients the *plaque* has been left in the chamber without causing uveal inflammation, as has been described by some writers. Attempts at removal almost certainly involve entanglement of the iris or a risk of damage to the lens, so that it may be more advisable to leave it.

iv. **The Iris.**—The routine with some operators is to leave the iris intact; others snip the prolapsed portion, which then, as a rule returns within the anterior chamber; and, again, others do an iridectomy. My experience is that this latter procedure is essential for success; some of the failures being due to the absence, or improper performance, of an iridectomy. The anterior chamber is seldom restored in less than three or four days, and may be much longer. Should an iridectomy not have been performed, it means that a congested iris is kept in contact with the gap throughout this time; the likelihood of adhesion is considerable. When this happens, the case goes from bad to worse, for, as well as the trephine hole failing to act, the filtration angle over a large additional area is blocked by the up-drawn iris. An iridectomy should be performed in every case, and the ideal is one shaped like an equilateral triangle just sufficiently large to contain the trephine gap. If it be made in this way—it is, however, difficult to accomplish every time—it is impossible for the pillars to adhere, as does sometimes happen with a slit-like coloboma. For cosmetic purposes it is undesirable to make a complete coloboma, although it is then so much easier to ensure it clearing the trephine gap. Nor should the sphincter alone be left, for then this part of the iris always adheres to the lens capsule.

If the trephining has been made as I have described, the iris bulges freely in uncomplicated cases, (the iris may not prolapse for one of four reasons—the presence of iritic adhesions, when the gap is close to a previous iridectomy, imperfect or too peripheral trephining), but the difficulty lies in controlling the size and shape of the iridectomy. This is best overcome by picking up with iris forceps the most posterior portion of the prolapse, and excising it with de Wecker's scissors. The blades are held in the coronal plane, which ensures a wide based coloboma, whilst cutting as close to the forceps as possible,

limits the vertical dimension. As soon as the iridectomy is completed, the cornea should be centripetally stroked with the spatula; if the pillars of the coloboma do not return readily by this procedure, the stroking should be done centrifugally. It may be necessary to do this fairly vigorously before success is obtained; it is, however, undesirable to introduce any instrument into the chamber if it can be avoided. Whilst the iridectomy is being performed, the flap is held lightly over the cornea by the assistant. The eye should not be fixed. One is sometimes misled into thinking that too little iris has been removed; a further excision should not be attempted until this is verified by replacing the iris, for the appearance is deceptive. de Wecker's scissors must not be used in the sagittal plane, for besides the risk of cutting the flap, a slit-like coloboma results, the pillars of which are not outside the trephine gap. Some surgeons prefer to snip off the top of the prolapse without seizing it with forceps, but much variability in the shape and size of the coloboma results. Others snip the prolapse, especially if large, as a preliminary to the iridectomy. It, however, necessitates introducing forceps into the anterior chamber, and makes it more difficult to perform a good iridectomy. I have repeatedly noticed that, in the lighter coloured irides, should a portion remain at the bottom of the gap, *e.g.* with a slit-like coloboma, the iris tissue becomes very pale, giving the appearance as though a thin film of sclera had been left. Of course, attempts at removal, such as I have sometimes made, are apt to lead to the iris becoming entangled. The appearance is possibly due to oedema, the result of the lowered intra-ocular pressure.

Where the base of the iris is adherent to the cornea, an endeavour should be made to separate the two by means of a spatula. This procedure is, however, not very successful, and is attended with some danger to the lens.

Accident.—A loss of vitreous may happen after the iridectomy. This has occurred on some three occasions in cases where there has been no reason to suspect a ruptured zonule. In spite of the tag of vitreous presumably remaining in the gap, a subsequent rise in tension did not take place. Elliot suggests that the vitreous tag may become retracted.

v. **The suture.**—The operation is now complete excepting for the replacement of the flap. The practice with some surgeons is not to suture the flap, partly because it is held to be unnecessary, and partly also because there is some difficulty when the flap is of large size. I regard it as essential for the following reasons.—(1) The flap does occasionally slip down, and then requires to be replaced the next day. In spite of cocaine, patients always complain very much of pain when late suturing is done. Further, without a stitch, although the flap may not slip right down, it often does so sufficiently far as to overhang the cornea. (2) The delay in recovery. (3) The risk of infection. In one case the eye would have been lost inevitably if no suture had been used, for a purulent conjunctivitis developed within twenty-four hours. (4) The band of scar tissue outlining the flap is much less broad when a stitch is inserted.

The flap should have the needle and silk suture passed through the apex. Whilst the assistant lifts the speculum the upper edge of the bulbar conjunctiva is pulled down and the suture completed by a double hitch without the second tie. One suture is ample, which by the third day becomes untied and is then lifted off.

I wish to express my indebtedness to Mr. George Coats for reading over these notes as well as for valued suggestions.

THE RESTORATION OF THE ANTERIOR CHAMBER AFTER ELLIOT'S OPERATION.

BY

G. F. C. WALLIS, M.D.Edin.,

LATE SENIOR HOUSE SURGEON, ROYAL LONDON OPHTHALMIC HOSPITAL (MOORFIELDS) AND THE BRISTOL EYE HOSPITAL.

COLONEL ELLIOT, referring to the time when he first began to perform his operation, says: "We had all to learn. . . . We did not know if the eye would remain permanently too soft." Everyone now knows that this does not happen, yet the restoration of the anterior chamber is considered so much a matter of course that it seems almost querulous to enquire into it. However, during my term of office at Moorfields, Elliot's trephining was almost exclusively in vogue for chronic glaucoma, some 137 operations being performed. I was much struck by the great variation in rapidity with which the anterior chamber re-formed. To a certain extent the same fact had impressed itself upon me in regard to the old operation of iridectomy, but in that case the variation was less marked. In the latter procedure it is quite obvious why and how the anterior chamber re-forms; where, however, a permanent, and often large, hole is made into the chamber, one would not be surprised if, the glaucomatous condition being cured, it were never restored.

Now in a few cases the chamber has not commenced to appear before as long as three weeks, in others it is present at the examination on the next day—in one before the child left the theatre—but the usual time is about the third or fourth day after the operation; and the permanent result seems to be as good as, or better in those that appear very early. In those cases in which the chamber re-forms slowly, one may notice it gradually deepens until complete, the actual process lasting several days; or that it is absent at one, and fully restored at the next, examination. This latter phenomenon, however, is much more usual in those that appear early.

The degree of filtration which takes place bears little or no relation to the rapidity of formation, or to the depth of the anterior chamber. Thus, a marked filtration may be associated with a normal chamber or with its absence; on the other hand, there may be no chamber and very little filtration. The size of the trephine gap is not the sole factor, for the chamber may, and usually does, reform as quickly after a 2 mm. as after a 1·5 mm. trephine; in one patient a 2·5 mm. was used, and the chamber was normal upon examination the next day. A very imperfectly removed *plaque* may be, and was in one case, associated with a rapid return of the chamber. In this case, however, the reason is obvious. The condition of the pupil, whether contracted or dilated, and the presence or absence of an iridectomy, have no effect. In this series, with two exceptions, the edge of the flap has always been cicatrised to the sclera. From this one might anticipate that a small flap, especially if the incisions have been carried up to the cornea, in which the filtration is limited, would tend to cause the chamber to become normal quicker than with a large flap. But it is not so. In some I tried protection alone with a "Cartella" shield, thinking that the pressure of a bandage might be a factor, but without effect.

The explanation was found by accident.—A patient was admitted with bilateral chronic glaucoma, and in both eyes the anterior chambers were very shallow. In one there was an acute exacerbation for which a posterior sclerotomy was performed, and as the result, the anterior chamber became a shallow normal. Subsequently trephinings were done upon each eye under similar operative conditions. In the sclerotomised eye the anterior chamber

had reformed at the end of twenty-four hours, but took more than a fortnight in the other. Later observations confirmed the fact that in those cases where the chamber was normal in depth before the operation it was rapidly restored, whereas in those in which it was very shallow, the reverse was the case. In one buphthalmos case the chamber of the left eye had reformed before the child left the theatre, and in the right within six hours; in another buphthalmic baby in the two eyes within twenty-four hours, both patients having the usual very deep chambers before the operations. In cases where the chamber is very shallow, the iris, lens, and vitreous have come forward gradually and more or less permanently. Under these circumstances it is to be expected that the aqueous would take longer to collect than when these structures have occupied their normal situation up to the time of operation. It is possible that the secretory power of the ciliary body, in the more advanced glaucomatous states, is somewhat disorganised, and becomes insufficient after the tension is abruptly lowered. This might be a contributory factor, but the chief cause, as I have shown above, is the depth of the anterior chamber. That impaired secretion is not mainly so is further shown in two cases, in which both eyes were trephined under similar surgical circumstances; one eye of each was an absolute glaucoma, and the other almost normal; the chambers in the nearly healthy eyes were decidedly slower in re-forming. It may *therefore be advisable to do a preliminary posterior sclerotomy before carrying out a trephining* in those cases where the anterior chamber is extremely shallow.

Now, in those cases in which the anterior chamber regains its normal depth within a day or two, the pupil re-acts well, no posterior synechiæ form, and no pigment is deposited upon the lens capsule. Whereas, as Elliot points out, if the iris, which is passively congested by the lowered tension, remains long in contact with the lens capsule adhesions form. This iritis is of an extremely quiet type—as a rule—and unassociated with any pain or ciliary injection. So much is this the case, that, until a mydriatic is used, it may not be suspected, and there may then be a ring synechia. Sometimes, in addition, the pillars of the coloboma become more or less completely bound down to the capsule, and I have seen a slight condition of *iris bombé* result. Some few cases, however, develop acute iritis with strong posterior synechiæ, much ciliary injection, and pain. A hyphæma is very frequently present, and there may be keratitis punctata. The hæmorrhages absorb slowly or not at all, the trephine gap is apt to be blocked with lymph, and the tension is almost certain to become full. This type is probably due to constitutional cause or to hæmorrhagic glaucoma, and, as a rule, such cases do very badly.

As regards the use of mydriatics and myotics, it is well to instil a drop of $\frac{1}{4}$% atropine the next morning; this should be repeated sufficiently often to keep the pupil half-dilated. It is undesirable to keep the pupil very wide, for the iris is bunched up in the periphery and adhesions to the trephine gap might result.

Elliot gives 4·6 as the percentage of his failures.*

* In making up the Moorfields statistics for the purposes of this paper, I have excluded all but primary chronic glaucoma patients, and amongst these were not a few for whom the prognosis was very grave—cases that had failed to receive permanent benefit from previous operative measures (other than Elliot's), and absolute glaucomata; also, all operations are included, whether performed by the honorary staff, senior house-surgeons, or clinical assistants. Of 91 patients suffering from primary chronic glaucoma, upon whom Elliot's operation has been performed, those who have developed repeated plus tension within a year of the operation, give a *case* percentage of failures of 9·8. The *operation* percentage of failures, among these patients, is 15·3—this larger figure is due to the cases that have failed to be improved by more than one operation in the same eye, and from failure in the two eyes of the same patient when this occurred. I am indebted to the Medical Council of the Royal London Ophthalmic Hospital for permission to publish these figures.

I think that the manner in which the anterior chamber is restored has an important bearing on the permanent good result of this operation. The conjunctivo-corneal flap is attached for the first few days by coagulum only, and during this time the chamber is reforming. This restoration may be aided by a diminished and less forceful secretion of aqueous from the temporarily disorganised ciliary body, but the balance must be very delicate for some days—hence the necessity for keeping the patient in bed until the chamber is fully restored. In the course of time these adhesions, throughout the area of the flap, become loose fibrous tisssue—the conjunctiva can be rolled readily upon the sclera, and freely balloons with the filtration. But in all cases this loose tissue contracts with time and the ballooning lessens. Under certain conditions the flap may be firmly and permanently healed ; when the cornea has been incised too deeply in an otherwise faultless operation. This happened in three cases ; a month after operation the increased tension had returned, filtration had ceased, and the corneal portion of the flap had become white and sclerosed. This appearance was apparently due to healing of the flap. In another case, where the operation seemed to be surgically ideal, the tension at the end of four months had gradually returned to above the normal, and no conjunctival œdema could be ascertained with a probe. I reflected the same flap again, but with the utmost difficulty, as it was firmly adherent over the area extending for 5 mm. from the cornea up to and including the corneal part of the flap. The trephine opening was also completely blocked, although as far as could be ascertained there was no prolapse of iris, and the pillars of the iridectomy were well outside of the gap. Now whether the flap healed first and led to blocking of the trephine opening, or the reverse (I believe the former, for it was re-trephined at the same site, and with occasional massage, the tension three months later was below normal) is of little importance; my contention being that the flap is only hindered from healing so firmly as to prevent filtration, by the occurrence of a free and continuous passage of aqueous. If, therefore, the trephine gap became partially plugged, or the glaucomatous condition be so slight that the tension is but little, or only occasionally, increased, or the cornea be incised too deeply, there is then the chance that the corneo-conjunctival flap may progressively heal down to the sclera. Should this happen, a vicious circle would be established, the healing lessening the filtration, and the lessened filtration increasing the healing. Personally, I am suspicious of commencing failure if a case of trephining presents a normal tension at the end of a month, particularly if the tension remains normal, and no increased filtration occurs, after digital testing.

I put forward the suggestion that it may be advisable that *the cornea, in cases of trephining, should be periodically massaged*, in order to ensure a subnormal tension and free and continuous filtration. A considerable degree of *minus* tension does not cause harm to the organ or to vision, and massage was frequently resorted to after the old operation of iridectomy without ill effects.

I wish to express my thanks to Mr. George Coats for reading over these notes and for making valued suggestions.

A CASE OF OPTIC NEURITIS WITH RETINITIS AND CONSECUTIVE ATROPHY ASSOCIATED WITH PREGNANCY.*

BY

T. HARRISON BUTLER, M.D. Oxon,

ASSISTANT SURGEON TO THE BIRMINGHAM AND MIDLAND EYE HOSPITAL.

IT is a well recognised fact that optic neuritis and exudative retinitis may be associated with pregnancy and the puerperal state. Bonte,[1] records a case of a lady of 38 years, who towards the close of her ninth pregnancy, developed optic neuritis and became blind. Arnold Knapp,[2] reports three cases of optic neuritis occurring in pregnant women with other manifestations of toxæmia. Burrier, in an article which appeared in THE OPHTHALMOSCOPE, Vol. IX, page 639, on Eye Complaints in the course of the Albuminuria of Pregnancy, states that in the non-albuminuric woman who is pregnant one may find an optic neuritis coming on usually from the seventh to the ninth month.

My case differs from these in that the optic neuritis apparently developed after delivery.

Case.

A. S. age 24, the wife of a soldier, came to the Warneford Hospital, Leamington, on November 9th, 1911.

History.—Patient was confined on August 21st. The confinement was a normal one. The baby was born dead at full time. Fourteen days later she began to have violent headache and vomiting. The vomiting continued up to date of present visit. It is violent and occurs twice a day. She has had such violent vertigo that she could scarcely walk. There is no history of syphilis. A negative Wassermann reaction was subsequently obtained. There has been some polyuria, patient having to get up three or four times during the night to pass water.

Condition when first seen.—A Meibomian cyst in the right lower lid was incised and scraped out.

R.V. = 6/18 $\quad -0 \quad +0$

L.V. = 6/36 $\quad -1 \quad -1$

There is some irregular astigmatism and faint nebulæ, the result of strumous keratitis in childhood.

Fundus.—There is in both sides well-developed optic neuritis, each disc being choked to about 2 dioptres. There are well marked macular fans, and round each disc are large white *plaques* of a character unusual in albuminuric retinitis. The retinal vessels, as they leave the disc, are buried in billowy masses of exudate. There are no hæmorrhages. The arteries are tortuous and the veins congested. There is no evidence of arterio-sclerosis, but some of the arteries are accompanied by a band of white exudate.

General Condition.—The most careful examination by Dr. F. Clayton, Honorary Physician to the Hospital, failed to reveal any evidence whatever of kidney disease. The urine was found to be normal in amount and character. There was never any trace of albumin and no casts could be found. There was no sign of cardiac disease, and the blood-pressure was only 82. No clinical evidence of cerebral tumour.

Blood.—There is a moderate leucocytosis, but no signs of any serious anæmia. *Nose* examined by Mr. F. Sydenham, rhinologist to the Hospital, and found to be normal.

Fields of Vision.—Both show concentric contraction. The right most markedly (down to 50°). There is some interlacing of the red and blue fields on both sides.

*Patient shown at the Midland Ophthalmological Society in February, 1912.

Diagnosis.—It seemed certain that there was a rise of intracranial pressure causing the classical symptoms of headache, vomiting, optic neuritis, and vertigo, with dyschromatopsia. But there were no signs to confirm the suspicion that there might be a cerebral tumour. Syphilis was excluded by the absence of any signs or history, as well as by the negative Wassermann reaction.

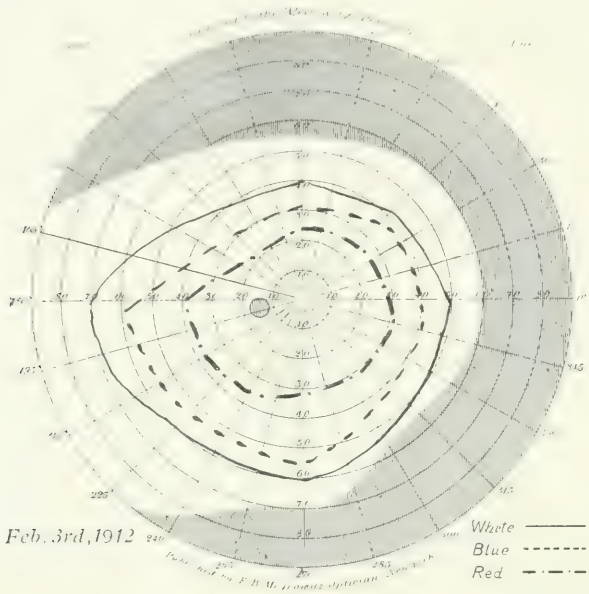

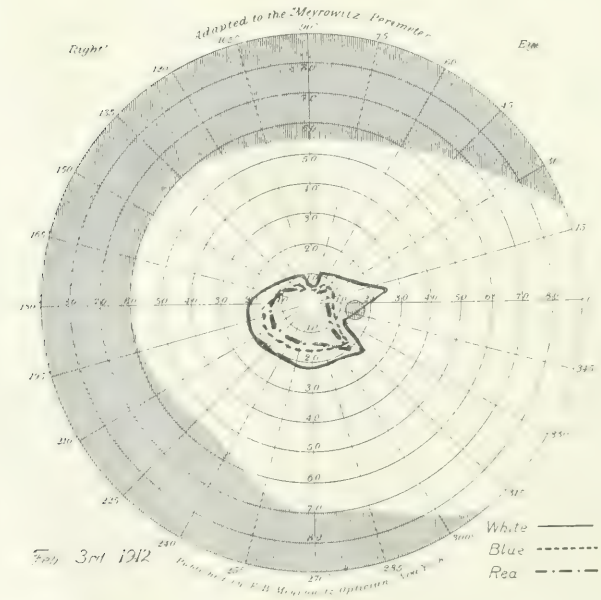

Later in the course of treatment, we excluded tuberculosis by three negative tuberculin injections. There was only left a toxæmia due to pregnancy causing a serous meningitis.

Progress of the Case.

Nov. 30th.—Has been kept in bed. Headache has disappeared, no vomiting. The optic neuritis is more intense.

December 7th.—Right disc now choked to + 3 D. and left to + 2·5 D. V.R. and L. = 6/24.

December 19th.—The discs are less swollen, about + 1 D. on each side. There are now no symptoms apart from the ocular condition.

December 21st.—Discharged from the Hospital.

January 25th.—There is now no swelling of the discs, but marked pallor is noticed. Much of the exudate has disappeared. There is much periarteritis. V.R. = fingers at 1 foot. V.L. = 6/36.

February 1st.—V.R. = fingers at 1 foot. V.L. = 6/24. The right disc is very pale and the cup is filled in. The sheaths of the vessels can no longer be seen, but the arteries are getting small. Less exudate. The left disc is like the right, but the atrophic signs are less evident; still some *plaques* of white left. The right field is contracted down to 20°, and a re-entering sector above almost reaches the fixation point.

February 21st.—Re-admitted and tested with tuberculine.

On February 24th received 0·001 c.cm. of old tuberculine.
" " 29th " 0·002 " " " "
" March 4th " 0·004 " " " "

No reaction was obtained. R.V. = 6/60. L.V. = 6/18.

A Wassermann test was made by Mr. Haslam, pathologist to the Hospital and proved negative.

Patient was placed upon iodide of potassium, which was rapidly increased to a dose of forty grains three times a day.

Massage of the right optic nerve was started with a Bier's cup. This was carried out daily for two months; but in spite of it, the sight of the right eye gradually sank to 3/60. The field became very small, and the disc dead-white in colour. The sight of the left eye gradually improved, and the field of vision expanded.

March 6th, 1913. R.V. = 3/60 L.V. = 6/9. The left field of vision is now almost normal in extent. Both discs are chalky-white and the arteries are small. There are only traces of the white *plaques* left, all the exudate has been absorbed. The appearance of the left disc is so bad that it is hard to credit the almost normal field and the visual acuity of 6/9. The patient is perfectly well.

Remarks.

The character and course of the disease leaves little or no doubt that the optic neuritis was caused by a toxæmia dependent upon the pregnant state. It will be noted that the pregnancy was abnormal, for the child was stillborn. The nose was carefully examined for me by Mr. F. Sydenham, who pronounced it to be normal. Syphilis and tuberculosis were excluded. There was no evidence of any renal disease, and the outcome excludes a cerebral tumour.

The appearances of both fundi were and are practically similar, and yet one eye had an acuity of 3/60, the other of 6/9. One field is contracted down to 15°, while the other has become almost normal in extent.

REFERENCES.

1. **Bonte.**—*La Clinique Ophtalmologique*, août, septembre, 1907 (see THE OPHTHALMOSCOPE, Vol. VI, p. 447).
2. **Knapp, A.**—*Trans. American Ophth. Soc.*, 1907.

CLINICAL MEMORANDUM.

A METHOD OF OPERATING UPON AFTER-CATARACT, ETC.*

BY
W. H. BRAILEY,
HOVE, SUSSEX.

THE essential point of the method of operation which I am about to demonstrate is the way of approach to the site where operative interference is required. This is from behind the iris, instead of, as usual, from in front.†

Indications.

The method is used in three classes of cases.—

First, obstruction in the pupillary area of the aphakic eye.

Secondly, operation on the iris in the lensless eye.

Thirdly, operations on post-lental structures, where the lens is intact.

Operation.

Ordinary aseptic precautions are taken, and the needle or knife is inserted through the conjunctiva about 2 mm. from the point where it is intended to puncture the sclerotic. This is usually just behind the ora serrata, either above or below the horizontal meridian of the eyeball, as is most convenient. The conjunctiva is now pushed sideways to the point determined on, and the instrument pressed steadily into the eye. Should it be necessary to tear an after-cataract, a needle is used, and the point directed forward until it appears in the pupil. The web is then pierced and torn in several directions, and any loose pieces are pushed away behind the iris.

Remarks.

The foregoing is an extremely satisfactory and easy operation to perform. It does not require any after-treatment. It can, therefore, be done in the consulting room, and the patient can go home immediately afterwards.

The needle point being some distance from its fulcrum, makes it easy to get sufficient movement without the web slipping off the point or sliding up the instrument. The point of the needle being in sight all the time, after it appears in the pupil, there is no possibility of doing any damage.

I have operated in this way some two hundred times, and have never had any trouble, either in the operation or from after-effects.

Should the membrane be tough, a Ziegler's knife may be used instead of the needle. This knife, which must be very sharp, may also be used to divide the iris. Atropine is first instilled, and the knife passed into the eye, as already described, and the iris divided. This is a more difficult operation, and not so satisfactory.

I have found this method to be of use occasionally where a central corneal opacity has developed after an otherwise successful cataract extraction, and I have not thought it wise to interfere with the cornea again.

I have punctured a detachment of the retina in this way, and been able to watch the needle, with the ophthalmoscope, passing across the vitreous and entering the detachment. It is possible to make a much more certain diagnosis of a condition, such as sarcoma of the choroid, than by any other method. Indeed, I do not consider it justifiable to excise an eye without confirming the diagnosis in this way.

I have never seen any ill effects follow any of these operations.

---

* Demonstrated at the Oxford Ophthalmological Congress on July 17th, 1913.

†The method of operation through the sclera advocated by Mr. W. H. Brailey is, of course, an old one. It was fully described by William Mackenzie in 1854 (*Practical Treatise*, p. 816), to go no farther back. At the same time Mr. Brailey's communication will doubtless go a long way towards rehabilitating it in public favour.—EDITOR.

CURRENT LITERATURE.

NOTE.—Communications of which the titles only are given either contain nothing new or else do not lend themselves to abstract.

I.—ANATOMY AND PHYSIOLOGY.

(1) **Franz, Victor.—Histogenetic theory of the vitreous.** (Histogenetische Theorie des Glaskörpers.) *Arch. f. vergleichende Ophth.*, Bd. III, Heft ii, Juli 30, 1912, S. 217.

(2) **Whitnall, S. E.—The relation of the naso-lacrimal canal to the maxillary antrum: formation of the lacrimal recess.** *Ophthalmic Review*, February, 1913.

(3) **Whitnall, S. E.—The shape of the orbit: its influence upon the eyeball (Stilling's theory).** *Ophthalmic Review*, February, 1913.

(4) **Mawas, J.—The structure of the ciliary portion of the retina. Its part in the secretion of the aqueous humour and in the causation of cataract.** (La structure de la rétine ciliaire. Son rôle dans la secretion de l'humeur aqueuse et la pathogénie des cataractes.) *Fondation Ophtalmologique Adolphe de Rothschild: Bulletin et Travaux*, 1911, p. 89.

(5) **Mawas, J.—On the secretory and nutritive functions of the pigment epithelium of the retina.** (Sur la fonction sécrétoire et le rôle nutritif de l'épithélium pigmentaire de la rétine.) *Fondation Ophtalmologique Adolphe de Rothschild: Bulletin et Travaux*, 1911, p. 115.

(6) **Mawas, J.—Contribution to the study of the relation which exists between heterochromia and cataract: the alterations of the posterior epithelium of the iris in cataractous eyes.** (Contribution à l'étude du rapport qui existe entre l'hétérochromie et la cataracte; les altérations de l'épithélium postérieur de l'iris des yeux cataractés.) *Fondation Ophtalmologique Adolphe de Rothschild: Bulletin et Travaux*, 1911, p. 119.

(7) **Mawas, J., and Magitot, A.—A study of the development of the vitreous and zonula in man.** (Etude sur le développement du corps vitré et de la zonule chez l'homme.) *Fondation Ophtalmologique Adolphe de Rothschild: Bulletin et Travaux*, 1911, p. 123.

(1) **Franz**, of Frankfurt, accepts the recent view of the ectodermal origin of the vitreous. His theory is that it is to be regarded embryologically as a greatly developed and structurally modified basal membrane derived from the retinal cells. If so, it necessarily follows that when the fœtal cleft remains open, a cleft of the vitreous must also result. He claims that this can be demonstrated in teleostean fishes in which the cleft remains open permanently to give passage to the falciform process. Again, if his theory be correct, it follows that after the cleft has closed, the original cavity of the secondary optic vesicle must be represented not by the vitreous cavity, but by the canal of Stilling. It is along this canal that the pecten of the bird's eye runs, but the author admits that no channel is traceable beyond its free end.

An obvious objection to this theory is that a basal membrane should be a cellular structure, whereas the vitreous contains corpuscles of various kinds. Some of these may be foreign cells of mesodermal origin, but it seems to have been demonstrated that others are ectodermal and derived from the retina. The objection seems to be a weighty one, but is brushed aside somewhat airily by the author, who says that "these cells have certainly very little to do with the formation of the typical vitreous, and are not integral constituents of that body." The statement lacks proof, but even admitting its truth, one is not accustomed to see epithelial cells wander into the basement membrane.

Franz believes that the mammalian canal of Stilling, the pecten of the bird, and the processus falciformis of the fish are not, as is often stated, homologous. The canal of Stilling is a remnant of the cavity of the secondary optic vesicle; the pecten a neuroglial proliferation into this cavity; and the processus falciformis the turned-in edges of a persisting fœtal cleft, with the mesoderm between them. As regards the pecten, it might be suggested that since it contains numerous vessels, the mesoderm as well as the neuroglia must share in its formation. GEORGE COATS.

(2) **Whitnall**, of Oxford, has examined a number of maxillæ and finds that a well marked recess occurs at the upper, inner, and fore corner of the antrum, and in some cases almost separated off from it by a constricted neck, of which the boundaries are formed by ridges caused by the naso-lacrimal duct internally, the infra-orbital canal externally, the anterior superior dental canal below, and the roof of the antrum above. He quotes Swerschewsky as stating that the recess often contains granulations which may influence diseases of the canal. A. H. PAYAN DAWNAY.

(3) Stilling suggested that myopia with low brow aperture might be due to pressure of the superior oblique muscle on the eyeball causing antero-posterior elongation. **Whitnall,** of Oxford, has taken measurements of three kinds in a series of skulls, (1) the height of orbit at margin, (2) the intra-orbital height at the most roomy part, and (3) the inter oblique distance between the fossa trochlearis and the fossa of the origin of the inferior oblique. He finds that whereas in (1) and (2) the difference of extremes of variation is 8 mm., in (3) it is only 2 mm. This goes to show that the size of the orbit cannot affect the shape of the eyeball through any action of the superior oblique. A. H. PAYAN DAWNAY.

(4) The object of this paper by **Mawas,** of Paris, is to prove from the histological characters of the cells, that the epithelium of the ciliary body is glandular. The problem is most easily studied, of course, in the unpigmented layer, where Mawas finds certain details of structure which are also found in glandular cells, and which are said to indicate considerable secretory activity. These are a double staining of the chromatin of the nucleus with hæmalum and safranin, variation in the chromatin content of the nucleus, and the presence of vacuoles, and granules with a linear arrangement, in the cytoplasm. The granules are best demonstrated in the fresh cells, but may also be studied in sections after the use of suitable fixatives. He compares the cells with those of the kidney, which also secrete slowly and continuously. The pigmented layer has a similar structure, and is also glandular.

It is perhaps a little risky to make far-reaching physiological deductions from details of structure alone, and not everyone would agree with the author when he says there are no lymphatic channels *or spaces* in the eye, or when he forbids us to speak of ocular lymph.

In a second part of his paper Mawas considers the part played by the epithelium in the pathogenesis of cataract. In the senile form of that

affection he found an over-development of the connective tissue of the ciliary body, sclerosis of the vessels, indistinctness of the cell outlines, and proliferation of the epithelium, with vacuolisation and disappearance of granules in the protoplasm. Probably, he would have found most of these changes if he had examined non-cataractous senile eyes. In naphthalin cataract the vessels of the ciliary body were engorged and surrounded by fibrinous exudations. The protoplasm of the epithelium was vacuolated, and in places completely disorganised, and its normal striation was lost. In a case of spontaneous cataract in the rabbit, degeneration of the epithelium reached an even higher degree, the unpigmented layer having disappeared completely in places.

Mawas's idea is that lesions of the epithelium allow abnormal constituents to get into the aqueous, which bring about changes in the capsule and epithelium of the lens, leading to its opacification. All which is very probable, but perhaps not very novel. GEORGE COATS.

(5) In this paper, **Mawas**, of Paris, repeats, regarding the pigment epithelium of the choroid, what he has already said of the same layer on the ciliary body—that the presence of secretory granules, and of variations in the chromatin content of the nucleus, prove the cells to have an active glandular function. The secretory granules are especially prominent in animals which have no retinal vessels, and the author believes, therefore, that the epithelium has an important part to play in the nourishment of the retina, and considers that it forms a defensive organ, protecting by its vital properties the visual cells on its inner surface. He does not state exactly his objection to the common view, which attributes this nutritive function to the chorio-capillaris.

He argues that neither the pigment-elaborating nor the purple-forming functions of the epithelium can be essential to vision, since pigment is absent in albinos, and visual purple is absent at the fovea. On the other hand, when the pigment epithelium is absent, as in coloboma, or altered, as in certain cases of retinitis (should it not be "choroiditis"?), there is always much disturbance of vision. The argument seems somewhat strained, for in the case of coloboma, at least, a good many other things are absent as well as the epithelium. GEORGE COATS.

(6) **Mawas**, of Paris, supplements the foregoing papers with an account of the changes in the pigment epithelium of the iris in cases of cataract. In the naphthalin form of that affection, he found the protoplasm homogeneous or vacuolated, and the nucleus shrunken. In a case of spontaneous cataract in a rabbit, the cells, especially of the posterior layer, were enlarged, their pigmentation was uneven, and their protoplasm was vacuolated. The stroma generally was normal, but the ciliary processes which were found on the iris in the rabbit were congested. He thinks these lesions may account for cases of heterochromia with cataract, but he does not tell us that there was any heterochromia in the cases which actually showed the lesions in question. It is surely quite certain also that in cases of heterochromia with cataract the appearances are the result of loss of the stroma pigment, not of changes in the epithelium. GEORGE COATS.

(7) **Mawas and Magitot**, of Paris, give a useful *résumé* of the different explanations of the origin of the vitreous. The mesodermal hypothesis, first stated by Schöler and supported by Kölliker, long held sway, but in more recent times, the idea of an ectodermal origin from the cells of the secondary optic vesicle has obtained an increasing amount of support, and has received the sanction of Kölliker himself. The explanations of Kessler, who hypothecated an exudation from the mesodermal vessels, and of Lenhossék, who derived the vitreous from the cells of the lens vesicle, have not received general support.

The authors of the present paper profess themselves adherents of the ectodermal school. Their account of the development of the vitreous is as follows.—Three stages are to be distinguished: (1) The primordial, (2) the transient, and (3) the definitive vitreous:

(1) The primordial vitreous is derived as a delicately fibrillar tissue from the supporting cells of the retina. The cells of the lens vesicle also contribute some filamentary prolongations. At the beginning of the fourth week the hyaloid vascular system makes its appearance, and some mesoblastic cells enter the vesicle through the fœtal cleft; mesoblastic cells also enter from in front. These cells are concerned only with the formation of vessels; they take no part in the formation of the vitreous proper. Vitreous corpuscles are distinguishable from the first; they are derived from the retina, and contain droplets of secretion from which a part at least of the vitreous fluid originates; these cells belong to the neuroglial system of the retina.

(2) The transient or hyaloid vitreous is also mesodermal and is formed by neuroglial cells which surround the hyaloid artery and its branches; a similar neuroglial sheath surrounds the central vessels within the nerve; it is composed of two sorts of cells, elements with hair-like prolongations, which become the vitreous fibres, and elements, which leave the vessels and become mobile. The neuroglial sheath itself disappears with the hyaloid vessels. The whole system reaches its highest development about the third month.

(3) The vitreous in its final form (*corps vitré definitif*) is an expansion of the primordial vitreous, which has been masked for a time by the hyaloid system. The ciliary epithelium also takes on activity and forms the major part of the anterior fibres of the vitreous, and also the zonula, which first appears at the beginning of the third month. The zonula is therefore homologous with the vitreous fibrils. The hyaloid system is gradually compressed by these new elements, which aid in its final disappearance at the end of the seventh month. The authors deny the existence of a hyaloid membrane or a limitans interna of the retina; we presume they do not deny the existence of the structures which have been described under these names, but mean only that in a literal, developmental sense, the limitans interna does not form the inner boundary of the retina, so that the globe is in reality filled with a retinal tissue. GEORGE COATS.

II.—OPHTHALMOLOGY AND GENERAL MEDICINE.

(*Second Notice.*)

(1) Dreisch.—A case of leontiasis faciei and exophthalmos. (Ein Fall von Leontiasis faciei und Exophthalmus.) *Centralbl. f. prak. Augenheilk.*, Mai, 1911.

(2) Coppez, H.—The ocular complications of African recurrent fever. (Les complications oculaires de la fièvre récurrente d'Afrique.) *La Clinique Pratique Médico-Chirurgicale*, octobre, 1911.

(3) Grunert.—On the ætiology of ophthalmoplegia interna. (Zur Ætiology der Ophthalmoplegia.) *Bericht der Ophthalmologischen Gesellschaft*, Heidelberg, 1911.

(3A) Ormond, A. W.—A case of transient miosis associated with headache. *Trans. Ophth. Soc. U.K.*, Vol. XXX, p. 162.

(4) Noceti.—A contribution to the study of tumours of the pons. (Contribucion al estudio de los tumors del puente.) *Archivos de Oftalmologia Hispano-Americanos*, Enero, 1912.

(5) Gabriélidès.—Recklinghausen's disease with palpebral localisation (Maladie de Recklinghausen avec localisation palpébral.) *Ann. d'Oculistique*, février, 1912.

(6) Villard.—Optic neuritis during lactation. (Névrite optique dans le cours de l'allaitement.) *L'Ophtalmologie Provinciale*, avril, 1912.

(7) Rönne, Henning.—A case of tabetic optic atrophy with unilateral nasal hemianopsia. (Ein Fall von Sehnervenatrophie bei Tabes mit einseitiger nasaler Hemianopsie.) *Klin. Monatsbl. f. Augenheilk.*, April, 1912.

(8) Watzold.—The significance of scrofuloderma in ophthalmology. (Die Bedeutung des Scrofuloderma in der Augenheilkunde.) *Zeitschrift für Augenheilkunde*, April, 1912.

(9) Hoffmann, T.—Cataract in and with "atrophic myotonia." (Kataract bei und ueber "atrophischer Myotonie.") von Graefe's *Arch. f. Ophthalmologie*, 10 Mai, 1912.

(10) Knapps, George H.—Some ocular manifestations of syphilis and parasyphilis of the nervous system. *Archives of Ophthalmology*, May, 1912.

(11) Darling, C. G.—Retinal lipæmia in severe diabetes. *Archives of Ophthalmology*, July, 1912.

(12) Dupuy-Dutemps and Lutembacher.—On the ophthalmoscopic signs of erythæmia (Vaquez's disease). [Les signes ophthalmoscopiques de l'érythrémie (Maladie de Vaquez).] *Ann. d'Oculistique*, août, 1912.

(13) Coppez.—Ocular complications of the bony disease of Paget. (Complications oculaires de la maladie osseuse de Paget.) *Archives d'Ophtalmologie*, septembre, 1912.

(14) Hinshelwood, James.—Eye symptoms and the early diagnosis of diseases of the nervous system. *Lancet*, September 14th, 1912.

(15) Klinedinst J. F.—Recurrent third nerve paralysis with report of a case. *Ophthalmology*, October, 1912.

(16) Bourland.—Two cases of optic neutritis due to malaria. (Deux cas de névrite optique due à la malaria.) *Ann. d'Oculistique*, novembre, 1912.

(17) Stoewer, P.—Neuritis and iridocyclitis in diabetes insipidus. (Neuritis und Iridozyklitis bei Diabetes insipidus.) *Klin. Monatsbl. f. Augenheilkunde*, November, 1912.

(18) Frankal, H. and de Saint-Martin, R.—Ocular complications of aortic aneurism. Aneurism of the aorta and tabes. (Complications oculaires de l'anéurysme de l'aorte. Aneurysme de l'aorte et tabès.) *L'Ophtalmologie Provinciale*, décembre, 1912.

(19) Cramer, E.—Retrobulbar neuritis, with amaurosis of eight days' duration and severe cerebral symptoms, as a consequence of infective multiple neuritis. (Neuritis retrobulbaris mit achttägiger Amaurose und schwersten Gehirnerscheinungen als Folge von infectiöser multipler Neuritis.) *Klin. Monatsbl. f. Augenheilkunde*, Januar, 1913.

(20) White, W. Hale.—Case of secondary hæmorrhages in the retina in secondary anæmia. *Proceedings of the Royal Society of Medicine*, March, 1913.

(21) Péchin.—Spontaneous conjunctivo-palpebral ecchymosis in a case of severe anæmia. (Ecchymose spontanée conjonctivo-palpébrale dans un cas d'anémie grave.) *Revue Générale d'Ophtalmologie*, 30 avril, 1913.

(22) Dutoit, A.—The rôle of tuberculosis in orbital affections. (Le rôle de la tuberculose dans les affections orbitaires.) *La Clinique Ophtalmologique*, 10 mai, 1913.

(23) Barnes, Stanley.—On ocular paralysis. *Birmingham Medical Review*, May 15th, 1913.

(24) Marlow, Frank W.—Some points of contact between ophthalmology and general medicine. *New York State Journal of Medicine*, July, 1913.

(25) Ormond, A. W.—Two cases of permanent hemianopia following severe attacks of migraine. *Trans. Oph. Society U.K.*, Vol. XXXIII 1913, p. 138.

(1) **Dreisch**, of Ansbach, reports a curious case of leontiasis of one-half of the face. The patient, aged 47 years, gave the following history.—At 3 years of age the right eyelid hung down over the eyeball. At 6 years the temple became soft and furrowed. At 12 years a piece of the upper lid was excised, an operation which apparently resulted in the lid resuming its proper place. At 15 years a cartilaginous tumour was removed from the temporal region. At 17 years he was operated on several times in the Erlangen clinic without good result, and shortly after this, the eyeball came forward out of the orbit and could not be replaced. The present condition has lasted now for many years, causes the patient no trouble, and so he does not wish it removed. The right upper and lower lids and the surrounding parts are much enlarged, and hang down, together with the eyeball, as a loose sack over the right cheek. The skin is of doughy consistence. The right orbit is about 15 mm. wider than the left. The orbital margin is irregular and lumpy. The globe is at the level of the right nostril and about 1 cm. to the side of it. The cornea is preserved as regards form; it is quite opaque, insensitive, and vascular. There is no vision. The optic nerve can be felt as a thin cord, and on squeezing it, patient says he gets a sensation of weak light. It is impossible to replace the globe in the orbit.

A. LEVY.

(2) **Coppez**, of Brussels, after pointing out that the recurrent fever of Africa is not the same thing as the recurrent fever of Europe, proceeds to discuss the ocular complications of the former affection, of which little is really known. He describes the case of an officer who suffered from African fever, complicated with fine vitreous opacities, Descemetitis, and central scotoma. Under mercurial treatment (not usually believed to be indicated in recurrent fever), the eye made a complete recovery.

SYDNEY STEPHENSON.

(3) This extremely valuable paper by **Grunert,** of Bremen, led to an interesting discussion. The author, during the past three years, has treated twelve cases of uncomplicated ophthalmoplegia interna, complete paralysis of the pupil and ciliary muscle. Four cases were due to syphilis and seven were caused by empyema of the accessory sinuses (to be accurate, of the ethmoidal cells and the sphenoidal sinus) or by other abnormalities in the nose. In the twelfth case the patient, an old diabetic, had had syphilis, but treatment had no effect upon the paralysis. In addition, he suffered from ethmoidal suppuration. Surgical treatment of these nasal cases in most instances led to complete cure.

Discussion.

Igersheimer was surprised that Grunert had such a small proportion of syphilitic cases. He noted syphilis twelve times in fifteen cases. **Bartels** suggested that despite the negative Wassermann reaction, the nasal disease was really syphilitic in nature. **Hamburger** asked whether nasal disease was ever the cause of double ophthalmoplegia. **Levinsohn** spoke of a case of double congenital ophthalmoplegia interna. **Pischel** thought that a specialist who combined rhinology with ophthalmology could often clear up a case of doubtful origin. T. HARRISON BUTLER.

(3A) **Ormond**, of London, records the case of a boy of eight years, who was subject to attacks of headache associated with myosis of the right eye. General state good. During the attacks the pulse became irregular and was slow. Farquhar Buzzard, discussing the case, said that a small movable tumour in the third ventricle might account for the symptoms by occasionally obstructing the circulation of the "iter" and setting up temporary hydrocephalus. LESLIE BUCHANAN.

(4) In the first part of this paper **Noceti** gives a *résumé* of the knowledge on the subject, based largely on Uhthoff's statistics. He shows how it is hardly possible for the sixth nerve to remain long intact in the presence of a growing neoplasm of the pons; so that in about 82 per cent. of all cases this nerve is found affected. He explains, by means of clear diagrams, the anatomical conclusion to be drawn from the signs of Millard Gubler and of Weber, and shows how paresis of the facial is associated, sometimes with hemiplegia of the same, and sometimes of the opposite, side. In the latter half of the paper he gives an account of a case in which a small tuberculoma of the left eminentia teres was present during life. The symptoms were loss of movement of the left frontal muscles and of the left orbicularis palpebrarum. There was slight loss of power of the lower facial muscles and of sensation over the left side of the face. The eyes showed loss of conjugate movement to the left, and paralysis of the left rectus externus. There was no optic neuritis. After death, a tumour was found in the floor of the fourth ventricle on the left side, destroying the upper half of the median and lateral formatio reticularis, the central grey matter of the fourth ventricle, the dorsal longitudinal bundle, and the crossed root of the trigeminal; all the parts in the neighbourhood were compressed and deformed. HAROLD GRIMSDALE.

(5) **Gabriélidès**, of Constantinople, records a case of Recklinghausen's disease, or generalised pigmented molluscum, in which one of the tumours, the size of a hazel-nut, was situated in the outer part of the right upper eyelid and caused ptosis. This was removed, and on microscopic examination, proved to be a dermofibroma, without any trace of neurofibroma. Tumours from other parts of the skin, which were removed for pathological examination, proved to have a similar structure, but one from beneath the conjunctiva turned out to be an accessory lacrymal gland. R. J. COULTER.

(6) **Villard**, of Montpellier, relates two cases of optic neuritis during lactation. In both the neuritis was unilateral and its onset was associated with severe

headache and loss of sight. He points out that this type of optic neuritis occurs in women of thirty to forty years of age who have had several children. The condition commences some weeks or months after lactation has started. It may affect one or both eyes, and is nearly always preceded by general symptoms. Besides the reduction in visual acuity, there is a concentric contraction of the field of vision. The prognosis is fairly good, although it must be remembered that relapses are likely to occur in future lactations.

With regard to treatment, the primary cause must be removed: the child must be weaned; other means must also be tried, as bleeding, purgation, inunctions, and injections into the temple of strychnine sulphate.

The author concludes by calling attention briefly to the three possible theories that may account for the optic neuritis. P. A. HARRY.

(7) **Rönne's** patient showed progressive loss of vision in both eyes. In the left eye the field became reduced to a small area on the temporal side, while in the right the temporal half of the field was preserved with a sharp vertical line of demarcation. The author gives reasons for believing that he was not dealing with a syphilitic basal meningitis, but rather with a special localisation of the atrophic process at the chiasma. The case illustrates an important point in prognosis. Rönne has pointed out elsewhere that, since one set of fibres conducts both light and colour impulses, destruction of these fibres must affect both functions in an equal degree. In some cases, however, there is a disproportion in the loss of the fields for white light and for colours. His theory is that this indicates a greater loss of conductivity for one function than for the other, and that it is found only in fresh, rapidly progressive cases. This is a case in point:—with central vision of 6/36, and a moderately good field for white objects, there was total loss of colour vision. Further deterioration was rapid, and three weeks later, vision amounted barely to perception of hand movements. A. J. BALLANTYNE.

(8) **Watzold**, of Berlin, describes three cases of tuberculous swellings at the inner aspect of the eye connected with a tuberculous lacrymal sac. These conditions he considers very rare, because he can find few references to them in ophthalmic literature. He says "tuberculosis of the lacrymal sac is, judging by modern investigations, and according to my own observations, much commoner than was thought possible some time ago."

Our own experience may have been exceptional, but we should regard tuberculous disease of the lacrymal sac, especially in children, as too common to be worth recording, and when once a fistula forms, it is usual for the skin to become affected. Apart from lacrymal disease, tuberculous affections of the skin of the lids are, as the author states, very uncommon.

T. HARRISON BUTLER.

(9) **Hoffmann** (Heidelberg).—Out of eighty recorded cases of "atrophic myotonia," eight were suffering from cataract. The combination of the two diseases is the more striking as both seem to be running subject to heredity in the same families: some are affected with cataract without myotonia, others with myotonia without cataract, and others with a combination of the two. There is no record of cataract in Thomsen's disease (congenital myotonia without atrophy), or in muscular atrophy of dysatrophic, neuritic, or spinal origin. R. GRUBER.

(10) **G. H. Knapps** reports a case of double optic neuritis probably resulting from increased intracranial pressure in a case of cerebral gumma and another of inflammation of the optic nerve as a result of the extension of a basilar luetic meningitis. He reminds his readers that these ocular signs are often the precursors of more serious nervous affections, and urges thorough anti-syphilitic treatment at once. In those cases where the luetic origin is not

obvious, the Wassermann test and the cytologic examination of the cerebro-spinal fluid will in most cases settle the diagnosis. Even when the use of anti-syphilitic measures has removed all symptoms, Knapp urges that the patient be kept under observation and treatment continued until the Wassermann test has been found repeatedly negative. ROSA FORD.

(11) In **Darling's** case, the retina was quite normal except that the vessels looked "like waxy, light pink lines on a red background of normal colour." A blood film showed a large amount of fat in the blood. Six weeks later, the patient died. The case was one of a male of 48 years. Darling quotes seven other cases from the literature. In all of these, where the sex is stated, the patients were males, and in all but one, in which fat was not found in the blood, the appearance was a terminal one. Darling's case was older than that of the average of these other cases, *viz.*, twenty-two. ROSA FORD.

(12) **Dupuy-Dutemps and Lutembacher** describe the ophthalmoscopic appearances in a typical case of erythæmia, *i.e.*, primary absolute increase in the number of the red corpuscles without alteration in their size, due to disease in the marrow of the long bones. The disease is characterised by an intense purplish or blueish-red cyanosis, most marked on the face and extremities, caused by a fine network of dilated vessels, and accompanied by enlargement of the spleen and liver, and albuminuria. It causes attacks of pain, which come and go suddenly, and are most marked in the extremities when warm in bed, purpuric spots and ecchymoses, hæmorrhages from the nose, gums, stomach, intestines, and cerebral vessels, and thromboses. It comes on between the ages of 30 and 60 years, and death occurs in from one to five years. Ophthalmoscopically, the optic disc is of a deeper colour than normal, but has clear-cut edges, the arteries are normal, and the veins are dilated, the smallest ramifications being involved, as well as the large trunks, while their colour is deeper than normal, owing to their increased size, and in a lesser degree to the increased number of erythrocytes in the blood. Their appearances contrast with those seen in congenital cyanosis, in which disease the retinal veins are normal in calibre, but the arteries are of almost as deep a colour as the veins. R. J. COULTER.

(13) **Coppez,** of Brussels, draws attention to the condition of the macular region which he has observed in four cases of osteitis deformans.

The patients consulted him for impaired vision with metamorphopsia and scotomata. In all four cases there were present, lying close to the maculæ, pin-point yellowish-white spots, presumably degenerative. In one the degeneration had progressed to form an atrophic *plaque* covering the macular area in one eye, a similar appearance being found later in the fellow eye.

In two of the cases punctate hæmorrhages were associated, and in another diplopia from displacement of the pulley of the superior oblique. The optic nerve and retinal vessels showed no alterations. No ætiological factor was found, although slight albuminuria was present in one case. Coppez regards the change as a nutritional one to be expected in such a disease as osteitis deformans, and in such a delicate region as the macular. The condition has not been described before in connection with osteitis deformans.

BERNARD CRIDLAND.

(14) The clinical lecture to his students by **Hinshelwood,** of Glasgow, is one of a stimulating kind. It deals in a most succinct manner with the principal nervous diseases which present eye symptoms, and impresses on the student the necessity that he, as a general practitioner, should be on the alert for eye signs and symptoms, even in the absence of complaint of such by the patient. In this way he may arrive at a diagnosis of disease of the nervous system at a much earlier period than would be possible from consideration of

the other symptoms alone. In connection with the symptom of hyperæma of the discs the author remarks that this, with distension of the veins, is often an early sign of intracranial disease, and that it is a sign which hitherto has not had sufficient attention paid to it. It is met with not only in tumour and meningitis, but in various pathological conditions giving rise to increase of intracranial pressure—*e.g.*, in cerebral abscess and hydrocephalus.

ERNEST THOMSON.

(15) **Klinedinst's** patient, a girl of fifteen years, suffered from a fairly typical ophthalmoplegic migraine, which occurred every spring from the age of five. The mother and maternal grandmother suffered from migraine, and four sisters were subject to headaches, which in one case were migrainous. In all the cases the symptoms followed constipation. The author believes that the cause of these disturbances was a vasomotor disorder set up by autotoxæmia from intestinal putrefaction. A. J. BALLANTYNE.

(16) **Bourland**, of Oran, records two cases of optic neuritis caused by malaria. Both patients were men in the prime of life who had suffered from frequent attacks of malaria, but were otherwise free from disease. Both complained of attacks of dimness of vision coming on during the attacks of malaria and improving during the intervals. In both cases the discs were at first hyperæmic, with dilated veins, narrowed arteries, and indistinct edges. In the first case there were some retinal hæmorrhages, while in the second these were absent, but there was a characteristic deep-brown discoloration of the disc "in itself sufficient to establish the diagnosis of malaria." Both cases ended in optic atrophy, with temporal pallor, in spite of energetic treatment with quinine and other remedies.

The author considers that his cases show that malaria can cause lesions of the optic nerve which are serious, and not, as is generally considered, benign, and that so far from complaints of dimness of vision during attacks of malaria being ignored, the eyes of everyone suffering from paludism should be ophthalmoscopically examined during the attacks, so that lesions of the disc, which may occur without interference with vision, may be detected, and an attempt may be made to save the sight of affected eyes by early and appropriate treatment.

R. J. COULTER.

(17) **Stoewer**, of Witten, reports a case of diabetes insipidus in which there was optic neuritis of the retrobulbar type and iridocyclitis. Under treatment with injections of strychnine, both the eye symptoms and the diabetes showed apparent recovery, and this fact, together with the absence of evidence of any other constitutional disease, leads the author to conclude that the diabetes insipidus was the cause of the eye symptoms. A. J. BALLANTYNE.

(18) The authors report very fully the case of a man aged 44 years, a railway employee, who complained of ptosis, double vision, and heart trouble. The case affords a suitable illustration of Babinski's law. They state that the syphilitic origin of aortic aneurisms, first pointed out by Welsh in 1875, and confirmed in France by Vallin in 1879, then by Fournier, Laveran, Dujardin-Beaumetz, is not yet generally accepted, In 1901, Babinski introduced a new theory with regard to the relation between pupillary abnormalities and aortic aneurism, the substance of which was that pupillary abnormalities are not secondary to the aneurism, but that both conditions are due to the common cause, syphilis. He has also shown that the Argyll Robertson pupil, which is usually associated with cerebral syphilis, is not infrequently a symptom of aneurism, also that the inequality of the pupils accompanying aneurism, is not due to spasmodic mydriasis or paralytic myosis by compression of the thoracic sympathetic, but is due to the same cause as the aneurism, seeing that there is a loss of the light reflex. The case reported by the authors confirms this theory.

In this case there was no history of syphilis, but the man gave a positive Wassermann, and he had well-marked aortic valvular insufficiency, aortic aneurism, and definite tabetic symptoms. He also showed commencing optic atrophy with contracted fields, paralysis of the right sphincter, total left ophthalmoplegia and partial paralysis of accommodation. P. A. HARRY.

(19) **Cramer**, of Kottbus, describes the case of a man, 36 years of age, who came under his notice on account of loss of vision which had occurred suddenly eight days after the onset of a febrile gastric condition. Objectively, the eyes were normal, but vision was reduced to R. 3/35 and L. 1/40, and there was central scotoma in both. A diagnosis of acute retrobulbar neuritis was made, but no cause could be discovered. The case ran a very severe course. At its height, even light perception was lost. The cerebral symptoms included severe headache, vomiting, slowness of the pulse, somnolence, incontinence, etc. About a week later, there was definite improvement. Vision was returning, the pupils were reacting, and there was pallor of the temporal half of each disc. The fields of vision were of normal extent, but with large central scotomata. There was gradual but steady improvement in the vision, which reached R. 3/10 and L. 1/10. A relative central scotoma for white, blue, and red, remained in the right eye, and an absolute central scotoma in the left. The only other remaining symptom was a complete and permanent loss of the tendon-reflexes.

In discussing the differential diagnosis, consideration is given to the possibility of rapidly growing cerebral tumour, multiple sclerosis, disseminated encephalomyelitis, and serous meningitis. The final diagnosis of multiple neuritis, complicated with retrobulbar neuritis, was based chiefly on the central scotomata and the loss of the reflexes. A. J. BALLANTYNE.

(20) In a case of anæmia secondary to cancer of the cæcum, **Hale White**, of London, obtained the eye for *post-mortem* examination. During life minute hæmorrhages had been seen in each retina. Microscopically, minute subhyaloid hæmorrhages were found. Not all the hæmorrhages seen during life had been subhyaloid, since some were flame-shaped; but the only ones cut in section were subhyaloid. The article is accompanied by a sketch of the section shown. The author points out that retinal hæmorrhages are probably very rare in secondary anæmia, although much more often seen in pernicious anæmia. The best blood count observed during life was—red cells, 2,498,000; white cells, 14,000; hæmoglobin, 17 per cent.

ERNEST THOMSON.

(21) The interesting point in the case of severe simple anæmia in a child, nine years old, reported by **Péchin**, of Paris, is that a hæmorrhage took place in the lower lid, at its edge, and gave rise to the appearance of a small red tumour, like an inflamed chalazion, the real nature of which could not be diagnosed apart from the occurrence of hæmorrhages elsewhere.

ERNEST THOMSON.

(22) The article by **Dutoit**, of Montreaux, is of the nature of a review, with bibliography.

(24) **Marlow**, of Syracuse, in the course of a communication which covers a good deal of ground, draws attention to a symptom-complex described by Foster Kennedy as indicating a tumour or abscess in the frontal lobe of the brain: given a case in which the symptoms of a central lesion are present, if a retrobulbar neuritis develops in one eye, then it is certain that a lesion exists in the lower part of the frontal lobe on the same side.

SYDNEY STEPHENSON.

(25) **Ormond**, of London, draws attention to a somewhat curious class of case in which attacks of migraine are followed, usually in young or middle-

aged individuals, by permanent hemianopsia. Such a condition, it appears, was described by Dr. Thomas, of Boston, in 1907, and by Sir William Gowers in 1909. In explanation Ormond assumes an arterial spasm occurring during an attack of migraine and involving that branch of the posterior cerebral artery which supplies the visual centre. This results, he supposes, in permanent interference with the visual function of that side, and so leads to blindness on the opposite side.

In abstract, Ormond's cases are as follows :—

1. Female, aged 33 years, subject for upwards of ten years to severe migraine. An unusually prolonged attack, lasting for three or four days, was followed by inability to see anything on her right side. V. 6/6 (with correction). Fundi normal. Defect in field not absolute. Condition of visual fields stationary for five months, the date of last note.

2. Female, aged 32 years, had suffered from "bilious headaches" since she was about eighteen years of age. When three months pregnant, had headache, followed by sickness, on July 20th, July 27th, and August 3rd. On the morning of August 4th she awoke with a headache, and later in the day, after running to catch a tram, found she could see nothing on her left side. On examination, R.V. 6/5 and L.V. 6/6. Homonymous hemianopsia involving the left side of the visual field. Fundi normal. Wassermann was negative, and nothing was found wrong in patient's general medical state. The hemianopsia was as noted when patient was examined upwards of seven months afterwards.

SYDNEY STEPHENSON.

III.—THE MEASUREMENT OF OCULAR PROTRUSIONS.

Rollet and Durand.—The measurement of ocular protrusions (with sub-title "exophthalmos in optic atrophy.") (Mensuration des protrusions oculaires (l'exophtalmie dans l'atrophie optique.) *Revue Générale d'Ophtalmologie*, 31 mai, 1912.

Rollet and **Durand,** of Lyons, after discussing the history (dating from Cohn in 1865) of systematic exophthalmometry, and pointing out the interest of the subject, especially in view of recent American work on exophthalmos in nephritis, proceed, first, to a critical review of previous instruments for the measurement of ocular protrusion and, afterwards, to a description of the modified Hertel apparatus which they have designed and employed in two hundred measurements in various classes of case.

The main difficulty in exophthalmometry is, of course, the finding of a definite fixed point from which to take measurements. In this instrument the external border of the orbit is taken as the fixed point. Without entering into detail, it may be said that the principle employed is that of bringing a pointer, sliding on a scale, into correspondence with the image of the apex of the cornea seen by the observer in a 45° mirror. By this means the protusion of each cornea, in front of the orbital points to which the instrument is adjusted, can be read off.

The chief conclusions so far come to by Rollet and Durand are as follow (adults only studied) :—Measurements over 14 mm. represent exophthalmos, under 12 mm. enophthalmos. The study of ocular protrusion in errors of refraction has yielded no very conclusive results, especially in myopia. After tenotomy of the internal rectus, exophthalmos of 1mm. to 2 mm. occurred but rapidly disappeared, in one case in eight days. Protrusion has not been proved to exist in glaucoma. In optic atrophy there is no doubt about the common occurrence of exophthalmos, but the authors have not succeeded in finding the reason. Further, the protrusion is proportional to the amount of atrophy. In tabes the authors consider it certain that there is exophthalmos,

altogether apart from optic atrophy or from Graves' disease. Four cases of Graves' disease have been studied, and it is interesting to note that in one of these there was an appearance of exophthalmos, due to separation of the eyelids, when none existed in reality.

With regard to the exophthalmos of nephritis, Rollet and Durand say that, although reported so long ago as 1885 by Sattler, and again in 1894 by Culbertson, this condition has only within the last two years been studied by American authors, namely, by Barker and Hanes, Thayer, Gordinier, Bishop and Levison. These observers, without using exophthalmometers, found the symptom in about one-half of the cases, and consider it as of bad prognostic significance. Rollet and Durand have found it in 70 per cent., and consider this the most important result of a method which enables one to note, from the very beginning, a commencing exophthalmos which is possibly due to retro-bulbar œdema. Lastly, the instrument is applicable to the study of enophthalmos. Enophthalmos in the old is suggestive not only of age but of senility. Other cases of enophthalmos have not yet been studied.

ERNEST THOMSON.

IV.—IMMUNITY.

(1) **Grüter, von.—Further researches on the vaccine immunity of the eye. (Weitere Untersuchungen über die Vaccine-immunität des Auges.)** *Bericht der Ophthalmologischen Gesellschaft*, Heidelberg, 1911.

(2) **Schieck.—The use of the discoveries of researches upon immunity in ophthalmology. (Die Anwendung der Ergebnisse der Immunitätsforschung auf die Augenheilkunde.)** *Zeitschrift für Augenheilkunde*, Juli, 1912.

(1) **Grüter,** of Marburg, by vaccinating rabbits with ordinary vaccine has convinced himself that the consequent immunity obtained by ordinary active immunisation is shared by all parts of the eye, including the cornea. But simple scratching of the skin, although it does immunise the whole skin, yet fails to affect the cornea. If, however, the scratch is made upon the palpebral conjunctiva, not only does the skin become immune, but also, to a certain degree, the cornea. The same is true of passive immunisation. The injection intravenously or subcutaneously of 10-15 c.cm. of immune serum did not protect the cornea, but if 1 c.cm. of the same immune serum were injected subconjunctivally, the whole eye was generally immunised.

T. HARRISON BUTLER.

(2) **Schieck,** of Königsberg, in an interesting paper summarises the results which have so far been attained from the serum therapy of the eye. If we except the use of diphtheria antitoxine, the results have, he thinks, so far not been conspicuously successful. There is no doubt that in the antitoxine of diphtheria we have a most valuable antidote to the disease. Abrin antitoxine, too, acts with great certainty in neutralising abrin, but this fact has no great importance, because the value of abrin in trachomatous pannus has been much over-rated. Römer's serum has so far proved a failure in the treatment of serpent ulcer of the cornea, unless used in enormous doses. The reason probably lies in the fact that many strains of pneumococci are rich in "aggressines," and so are immune to the anti-bodies

in the serum. The cornea, too, is avascular, and it is difficult for the antibodies to reach the ulcer. Schieck doubts whether Deutschmann's serum has any specific properties, and criticises v. Hippel's results obtained with this product. The author points out that Römer's experiments with cataract patients, whom he fed on lens-substance, have led to no useful result, and could not be expected to do so. Römer has himself abandoned his researches along these lines. Attention is directed to Elschnig and Kümmell's views that sympathetic ophthalmia is a manifestation of anaphylaxis.

T. HARRISON BUTLER.

V.—PATHOLOGY.

(Fourth Notice.)

(1) Mawas, J.—Lipoid granules in the fixed cells of the cornea. (Granulations lipoïdes des cellules fixes de la cornée.) *Fondation Ophtalmologique Adolphe de Rothschild : Bulletins et Travaux*, 1911, p. 109 (Received March, 1913).

(2) Rochon-Duvigneaud and Duclos.—Flat sarcoma of the choroid. (Sarcome choroïdien en nappe.) *Fondation Ophtalmologique Adolphe de Rothschild : Bulletins et Travaux*, 1911, p. 69 (Received March, 1913).

(3) Kambe, Toshiro.—A case of expulsive hæmorrhage after cataract extraction, with formation of lacunæ in the optic nerve. (Ueber einen Fall von expulsiver Blutung nach Staroperation mit Lakunenbildung im Sehnerven.) *Klin. Monatsbl. f. Augenheilkunde*. Mai, 1912.

(4) Hess, C.—Remarks on some of the recent essays concerning the pathology of the lens. *Archives of Ophthalmology*, May, 1912.

(5) Rados, Andreas.—The pathological anatomy of the caruncula lacrymalis. (Zur pathologischen Anatomie der Caruncula lacrymalis.) *Klin. Monatsbl. f. Augenheilkunde*, September, 1912.

(6) Velhagen, C.—Cyst formation in the retina. (Ueber Zystenbildung in der Retina.) *Klin. Monatsbl. f. Augenheilkunde*, Dezember, 1912.

(7) Bayer, H.—A contribution to the pathology of vernal catarrh. (Zur Pathologie des Frühjahrskatarrh's.) *Bericht der acht und dreissigste Ophthalmologischen Gesellschaft*, Heidelberg, 1912.

(8) Stargardt, K.—On the pathological anatomy of optic atrophy in tabes and general paralysis. (Zur pathologischen Anatomie des Sehnervenschwundes bei Tabes und progressive Paralyse.) *Bericht der acht und dreissigste Ophthalmologischen Gesellschaft*, Heidelberg, 1912.

(9) Alt, Adolf.—Extraordinary alterations in the corneal epithelium of a glaucomatous eye. *American Journal of Ophthalmology*, February, 1913.

(10) Rochon-Duvigneaud and Mawas.—Lipoids and white plaques in albuminuric retinitis. (Lipoïdes et plaques blanches dans la rétinite albuminurique.) *Bull. de la Société d'Ophtalmologie de Paris*, mars, 1913.

(1) By means of staining with Sudan III, **Mawas**, of Paris, has demonstrated the presence of fine granules among the corneal lamellæ. These are found in the protoplasmic processes and fixed cells of the corneal corpuscles. They are not directly stained with osmic acid, and are therefore to be classed as lipoids. Chemically, they are probably cholesterin ethers. The finding of similar granules has been described by various authors in arcus senilis.

GEORGE COATS.

(2) The case of flat sarcoma here reported occurred in a woman, aged 49, in whom a tumour at the limbus had been removed two years previously. When seen, she had exophthalmos, œdema of the conjunctiva, pain, and glaucoma. On enucleation, a large perforating tumour was found, extending to the back of the orbit. She died three weeks after the operation.

Pathologically, the retina was detached and the fundus of the globe was lined with a layer of pigmented new growth, 2 mm. broad behind and becoming thinner in front. Microscopically, this proved to be a spindle-celled sarcoma, with a fasciculated arrangement of the cells. Pigmentation occurred in the form of isolated cells and pigmented strands. The sclera and nerve were freely invaded, but on the inner aspect the pigment epithelium was intact. The sarcomatous cells extended as far forward as the ciliary body and iris.

When tumours of this type occur in the anterior part of the eye, trans-illumination may aid in the diagnosis. When they arise at the posterior pole, the diagnosis is always difficult. The association of increased tension with detachment will be regarded as suspicious, and should usually lead to enucleation of the globe. GEORGE COATS.

(3) **Kambe's** patient, a man of 81 years, suffered from senile cataract. The only other visible abnormality was hyaline degeneration of the pupillary margin, which prevented full dilatation under atropine. Combined extraction was done. There was some escape of fluid vitreous. Severe intra-ocular hæmorrhage occurred a few minutes after application of the bandage. During the next day or two, there was partial absorption of the blood, but on the sixth day, there was repetition of the bleeding. After healing of the wound, a blind, shrinking, tender eyeball resulted, and enucleation was performed. The retina was found totally detached and rolled up behind the corneal cicatrix. Thickening of the walls and narrowing of the lumen were found in the uveal and retinal vessels. The nerve fibre layer of the retina broke off abruptly at the lamina cribrosa, and behind the lamina there was a number of lacunæ, some of them containing blood. The greater part of the blood extravasation was situated under the choroid.

The author's view as to the cause of the hæmorrhage in this case, is that the sudden fall of intra-ocular pressure from escape of vitreous caused the bursting of some pathologically altered vessel. The choroid is looked upon as the source of the hæmorrhage. As regards the spaces in the optic nerve, he conceives that the optic nerve fibres have given way owing to the pull on the retina, and since the fibres are medullated as far forward as the lamina, and therefore too thick to be drawn forward, rupture would take place at this point. Such lacunæ have been described in glaucoma and in myopia, and we are to suppose that in such cases also there has been some tension on the nerve fibres, causing them to rupture in the same way. A. J. BALLANTYNE.

(4) Not suitable for abstraction. **Hess**, of Munich, is merely defending himself against several critics. No new matter. ROSA FORD.

(5) **Rados**, of Budapest, had a patient presenting a tumour, the size of a hazel nut, situated on the caruncle and inner end of the upper eyelid. It was red, elastic, sessile, and covered with conjunctiva. Its growth had begun three years before the date of observation, and had been gradual. It was stated to

have shown a tendency more recently to bleed when rubbed. It was easily shelled out of its conjunctival covering, and it was found to consist of connective tissue composed of deeply staining white fibres and a striking number of elastic fibres. The cellular elements were mononuclear and polymorphonuclear leucocytes and fibroblasts. There were numerous thin-walled and dilated arteries and veins, and the lymph spaces also were very wide. He diagnosed the case as one of soft fibroma, and considers that it is the fourth case of the kind in the literature. A. J. BALLANTYNE.

(6) **Velhagen**, of Chemnitz, gives details of two cases of detachment of the retina followed by glaucoma, in which he found cysts on the outer surface of the detached retina. In the first case, there was a single cyst near the optic nerve entrance, and an interesting feature was that ten years before enucleation was demanded, a limited elevation of the retina had been observed ophthalmoscopically in the situation in which the cyst was afterwards found. In the other case no O.E. was possible. The bisected eyeball showed six cysts, ranging in diameter from three to seven millimetres. Microscopic examination in both cases showed the presence of numerous small cavities in the external nuclear layer of the retina, and the author believes that the cysts also originated in that layer, being set up by the occurrence of exudation or hæmorrhage into the pre-existing spaces of the tissue. Inflammation of the choroid and retina, adhesion between these layers, and shrinkage from degenerative changes in the retina, probably played a part in the pathogenesis of the condition. Apparently, such cysts occur only in eyes in which glaucoma supervenes on detachment of the retina, but, of course, they do not occur in every such case. A. J. BALLANTYNE.

(7) **Bayer**, of Freiburg i. B., has made a useful and interesting discovery regarding spring catarrh. Dimmer noted that the symptoms and signs disappeared if the affected eye were kept tightly bandaged up, but Axenfeld pointed out that this was not a constant effect. Bayer found that if the eye be covered with a dark glass instead of the bandage, no effect was produced. If, however, an ordinary white glass be fixed air-tight over the eye, all the signs of the disease rapidly vanish. It is not the absence of light or of ultra-violet rays which cures the disease, but the absence of air. A coloured plate shows two eyes affected with spring catarrh; one has been covered by an air-tight glass, while the other was left open. The difference is striking. Another plate shows the excessive increase of the eosinophil cells in the uncovered eye, and their entire absence and replacement by neutrophil cells in the covered eye. T. HARRISON BUTLER.

(8) **Stargardt**, of Kiel, urged that the optic atrophy seen in tabes and general paralysis had its origin in an inflammatory process in the chiasma and did not start in the ganglion cells of the retina. His most recent researches have only served to confirm this view. He advanced many cogent reasons in its support. T. HARRISON BUTLER.

(9) **Alt**, of St. Louis, describes the pathological appearances found in an eye which had been blind from glaucoma and was excised for an acute attack, but about which other clinical details were entirely wanting. Posteriorly, the well-known appearances of glaucoma were found, but interest centres upon the cornea. Before embedding, Alt was struck by the peculiar appearance of the cornea. A milky-looking thickening was noticeable on its surface, reaching from the corneo-scleral margin towards its centre, in the upper part of the eyeball. This Alt thought was a pannus. In the lower half the surface of the cornea looked quite irregular. On section, the pannus-like thickening of the upper half proved to be made up of dense connective tissue, containing a number of blood vessels near Bowman's

layer, on which this newly formed tissue rested. The tissue thus interposed between the epithelium and Bowman's membrane at the periphery had the thickness of half the cornea and grew thinner towards the centre of the cornea, where it ended somewhat abruptly. In the absence of any history it seemed quite impossible to explain from the sections this peculiar connective tissue growth. It was not like that in spring catarrh, nor was it similar to an atrophic pterygium. It appeared not unlikely, in the author's opinion, that it was a strangely thick and fibrous pannus, unless perhaps the connective tissue had grown into the cavity of a very large epithelial vesicle. The article is illustrated with two photomicrographs. ERNEST THOMSON.

(10) **Rochon-Duvigneaud and Mawas**, of Paris, review the actual state of our pathological knowledge concerning the white patches observed in cases of albuminuric retinitis. The white *plaques*, as seen with the ophthalmoscope, are not always of the same nature. They may be caused by four different pathological lesions, as follows:—(1) Foci of fibrinous infiltration, occurring sometimes in a reticulated form and sometimes grouped in larger or smaller masses. These homogeneous deposits may occupy the entire thickness of the retina, are usually localised in the external layers, which may be dissociated and distended, so as to form cavities, occasionally of considerable size. (2) Detachment of the limitans interna by exudations formed of *boules sarcodiques* devoid of fatty matters, including lipoids. (3) Collections of hypertrophied nerve-fibres. (4) Vesicular cells, massed or isolated, stuffed with lipoid granulations and containing accessorily grains of fuscin. The authors regard these cells as destined to play the same part as the granulous bodies found in degenerating nervous centres.

Mawas describes the staining reactions of a typical case, and remarks that from a histological and histo-chemical point of view, there is nothing in common between the two lesions characteristic of albuminous retinitis, namely, fibrinous deposits and granulous cells. Lipoid substances do not exist in the white retinal patches. For the most part they are to be found in the granulous cells, where they are present in the form of granules included in the cellular cytoplasm. SYDNEY STEPHENSON.

VI.—MALFORMATION OF THE CORNEA AS A STIGMA OF HEREDO-SYPHILIS.

(1) Eppenstein, A.—On the vertically-oval form of cornea. (Ueber senkrecht-ovale Hornhautform.) *Zeitschr. f. Augenheilkunde*, März, 1912.

(2) Antonelli.—The oval cornea and the blue sclerotic in hereditary syphilis. (La cornée ovalaire et la sclérotique bleue des héréditosyphilitiques.) *Archives d'Ophtalmologie*, août, 1913.

(1) **Eppenstein**, of Berlin, has measured the corneæ of fifty cases of interstitial keratitis and fifty normal eyes. In six of the normal cases and in seven of the abnormal, the cornea was found to be oval with the major axis vertical. This investigation does not confirm Fuchs' discovery, *viz.*, that this form of cornea is common in the subjects of inherited syphilis with interstitial keratitis. T. HARRISON BUTLER.

(2) **Antonelli,** of Paris, credits Patry (1906) with being the first to draw attention to the vertically-oval cornea as a stigma of heredo-syphilis, although wide attention was directed to the point by the communication made by Fuchs three years later (*see* THE OPHTHALMOSCOPE, 1911, p. 870). Rübel (*Klin. Monatsbl. f. Augenheilk.*, 1911, ii, p. 227) has recently published an account of two such cases in patients suffering from interstitial keratitis. In the present communication Antonelli gives notes of five analogous cases. He has found that the vertically-oval appearance of the cornea in these cases is usually due to a reduction of the horizontal diameter, thereby producing an exactly circular cornea, appearances notwithstanding. He explains the malformation, as well as the bluish tinge of the sclera often noted in these cases in the limbo-ciliary region, by a persistance of the fœtal condition.

SYDNEY STEPHENSON.

VII.—RUPTURE OF THE OPTIC DISC.

Gonin.—Partial ruptures of the optic papilla. (Ruptures partielles de la papille optique.) *Ann. d'Oculistique*, janvier, 1912.

Gonin, of Lausanne, records two cases of partial rupture of the optic disc.

The first patient was a skier who had a bad fall, during which he struck his face with the end of his ski. When seen two days later, there was a peripheral inferior rupture of the choroid, also a hæmorrhage at the lower-outer edge of the optic disc, with a deep glaucomatous excavation of the lower and outer third of the disc. There was slight œdema in the macular region, but no retinal ischæmia. The central vision was 2/10, and the field of vision extended only 10° above the fixation point. Five months later, the central vision was 1/3 but the defect in the field remained unaltered and the injured portion of the optic disc was covered by a mass, like a pad of cotton wool, which masked the excavation. The author considers that the patient when falling, shut his eyes, and that the associated elevation of the cornea exposed the lower part of the eyeball to a blow from the end of the ski at a point corresponding to the situation of the choroidal rupture and that the blow, acting from below, produced a forced rotation of the eye upwards and thus tore the lower fibres of the optic nerve.

In the second case the mechanism was similar. The patient, a student, fell on a drawing rule which inflicted a severe blow on the eye in a direction from below upwards, causing hyphæma with greatly diminished vision and a large absolute central scotoma. Six months later, the temporal sector of the disc was covered by a cicatricial mass, similar to that in the first case. As there was no visible alteration in the retinal tissue, the author considers that the central scotoma was caused by a rupture of the macular fibres of the optic nerve.

The author has been able to find only two similar cases recorded in ophthalmic literature, one by Lang (*British Medical Journal*, 1902, p. 1151) and the other by Caspar (*Archiv für Augenheilkunde*, Bd. XLI, S. 188).

R. J. COULTER.

VIII.—PHLYCTENULOSIS.

(1) **Rubert, J.**—The ætiology of phlyctenular inflammation of the eye. (Ueber die Aetiologie der phlyctänulären Augenentzundung.) *Klin. Monatsbl. f. Augenheilkunde*, September, 1912.

(2) **Davis, A. E., and Vaughan, Harry.**—Phlyctenular (eczematous) conjunctivitis, with special reference to ætiology and the value of tuberculin as a diagnostic agent; together with the report of forty cases. *Ophthalmic Record*, September, 1912.

(1) We are still, apparently, far from the discovery of the essential ætiology of the phlycten, in spite of the familiarity of the lesion and the amount of investigation that has been devoted to the subject. **Rubert,** of Kieff, after discussing the numerous theories which have been advanced, more especially with regard to the relationship between phlyctens and the scrofulous diathesis, sets out the results of a series of experimental investigations carried out by himself, keeping specially in view the findings of Rosenhauch and Weekers, namely, that phlyctenular inflammation can be called forth by the simultaneous action of tuberculotoxins in the body fluids and the toxins of other micro-organisms, such as staphylococcus aureus (Rosenhauch) or the tubercle bacillus (Weekers) in the conjunctival sac.

The animals used by Rubert were rabbits and guinea pigs. Some were already tuberculous; others, previously healthy, received a preliminary injection of old tuberculin. Anæmic, marasmic, and healthy animals were also employed. For instillation into the conjunctival sac, he used staphylococcus vaccine, staphylococcus toxins, and tuberculin, massage being sometimes applied after the instillation.

He found that it is possible to produce experimentally in this way lesions which, clinically and histologically, resemble the phlyctens of the human conjunctiva. In these experiments bacteria played no part; only toxins were employed, and since in the investigation of human phlyctens, both the implantation of these bodies in the anterior chamber and bacteriological examinations give negative results, there is reason to suppose that these also are produced. A. J. BALLANTYNE.

(2) In this systematic investigation by **Davis** and **Vaughan**, von Pirquet's test was used for diagnostic purposes, and bacillary emulsion (human type), for therapeutic injections. 70 per cent. of the cases gave a positive von Pirquet reaction. A focal reaction occurred in 7·5 per cent. (3 cases).

The therapeutic injections were only administered to those who gave a positive Pirquet reaction. The results were as follows:—

Cured	26 cases	=	65 per cent.
Improved	8 „	=	20 „
Unimproved ...	1 „		2·5 „
Unknown	5 „	=	12·5 „

Local remedies, such as boric lotion, yellow ointment, and, in two severe cases, argyol and atropin, were used. Regulation of diet was looked after in all cases, and the hygienic surroundings improved whenever possible. The cases with enlarged tonsils and adenoids were operated upon. The authors believe that tuberculosis is the underlying cause of the disease in all cases, and that the characteristic lesion (phlyctenule) occurs only in those who are subjects of tuberculosis, latent or otherwise, or are "candidates for tuberculosis." J. JAMESON EVANS.

IX.—PSEUDO-GLIOMA.

Krauss, Frederick. — Pseudo-glioma in children. *Ophthalmology*, April, 1913.

Krauss, of Philadelphia, records an example of pseudo-glioma in a boy aged eight. The history stated that there was some injury to the eye at the time of birth. Seven months before examination, there had been slight redness and photophobia, and since then, several similar attacks. A peculiar appearance had been noticed behind the pupil for four months. Examination showed that the eye was blind. The pupil was moderately dilated and fixed, the outer part of the anterior chamber shallow, and the outer margin of the pupil adherent by a few synechia. A greenish-yellow reflex shone from behind the lens on the temporal side. While the case was under observation, the yellowish-green reflex extended all round the pupil, and some vessels could be seen on its surface. The diagnosis was Pseudo-glioma. The tension, at first normal, fell to −2, then two months later suddenly rose to above normal.

The eye was enucleated. There was found to be a total detachment of the retina, which passed forwards, like a stalk, from the nerve entrance, spreading out to its attachment around the ora serrata. Exudate filled the space between the retina and choroid. There was a large subretinal hæmorrhage at the ora serrata on the nasal side, several smaller hæmorrhages, both recent and old, in the detached retina, and a mass of partly organised inflammatory exudate between the crumpled retina and the posterior surface of the lens. The blood-vessels of the retina were all degenerated. The iris, choroid, and sclera were practically normal. The large subretinal hæmorrhage at the ora serrata was taken to be the cause of the recent rise of tension.

The author discusses the various conditions which may raise a question as to the presence of glioma, *viz.*, retinitis proliferans, suppurative choroiditis, and certain forms of irido-cyclitis. He believes that in the case in question these conditions can all be excluded, and that it belongs to the special group, properly called "Pseudo-glioma," which originates primarily in the retina, and leads to retinal degeneration, hæmorrhages in and below the retina, detachment of the retina, and subretinal exudation. He agrees with those who hold that there is a distinct disease of the retina, occurring in children, which produces clinical symptoms closely simulating glioma of the retina, and is of retinal, not of choroidal, origin. It is justly called Pseudo-glioma, since even the most able diagnosticians cannot make a sure diagnosis without a pathological examination. In cases of suppurative choroiditis, on the other hand, the history should provide a sufficient safeguard against a wrong diagnosis.

A. J. Ballantyne.

X.—LYMPHORRHAGIA OF THE FUNDUS OCULI.

(1) **Gonin. — Retinal changes following a fracture of the skull. (Altérations rétiniennes consécutives à une fracture du crâne.)** *Ann. d'Oculistique*, février, 1912.

(2) **Gonin.—Lymphatic stasis and lymphorrhagia. (Stase lymphatique et lymphorrhagies.)** *Ann. d'Oculistique*, février, 1912.

(3) **Purtscher, V.—Angiopathia retinæ traumatica. Lymphorrhagia of the fundus. (Angiopathia Retinæ traumatica. Lymphorrhagien des Augengrundes.)** von Graefe's *Archiv f. Ophthalmologie*, 25 June, 1912.

(1) **Gonin**, of Lausanne, records the case of a workman, aged 17 years, who after a severe injury, causing fractures of the inferior maxilla and left frontal bone, complained of loss of sight in the right eye. On examination, the eyes were found to be normal externally apart from some palpebral and subconjunctival ecchymoses, but the vision of the right eye was reduced to 1/20 without notable contraction of the field of vision, while that of the left, which was astigmatic, was 2/3. Ophthalmoscopically, the left eye was normal, but in the right there were about ten milk-white spots, like those seen in albuminuric retinitis, but scattered without any apparent regularity not far from the retinal veins. These varied in size from 1/4 to 1/2 a disc-diameter, and were accompanied by some punctiform and striate hæmorrhages. There were also two large pre-retinal effusions, two disc-diameters in size, situated one below the macula and the other along the course of the principal ascending vein. Two months later, the vision of the right eye was still 1/10, owing to a small absolute scotoma situated to the right of the fixation point, but the only ophthalmoscopic lesion present was a small white spot in the macular region.

The author considers that these lesions were caused by the accident, and quotes similar cases recorded by Purtscher and Koerber. He refers to the views of the German authors that the white spots are caused by sudden and temporary increase of intra-cranial pressure, calling attention to the contrast and with the changes which occur when the rise in pressure is slow, and remarks on the fact that three of the four recorded cases were unilateral.

R. J. COULTER.

(2) **Gonin**, of Lausanne, records the case of a patient, aged 28 years, who in the morning two days before he consulted him found the sight of his right eye was almost completely gone. On examination, the pupillary reaction in the right eye was almost absent and its vision was reduced to P.L. eccentrically. Ophthalmoscopically, there was ischæmia of the papillo-macular region with numerous hæmorrhages, flame-shaped or in *plaques*, especially abundant at the edges of the disc but extending to the periphery in groups or isolated. The ischæmic zone was less regularly oval and less clearly bounded than in ordinary cases of obstruction of the central artery, while the hæmorrhages were less massive than in typical cases of thrombosis of the retinal vein. There was also a pre-retinal hæmorrhage in the inferior temporal region and more peripherally a detachment of the retina; greyer in colour than an ordinary one. The arteries were much narrowed and the veins swollen and surrounded by a white sleeve almost as broad as or in places even broader than the vein. This did not in any place obscure the column of blood, but at certain points ran into the retinal tissue and became mixed with the ischæmic and œdematous appearance of the fundus, while in places the hæmorrhages bordering the vein were involved in the sleeve. These appearances changed rapidly, and in a week the clear band along the veins had almost entirely disappeared, as had also the ischæmic appearance round the disc, the retinal tissue showed only a reddish-grey discoloration on which the hæmorrhages showed up as darker areas, and the retinal detachment had disappeared. In the course of the following few weeks, the retinal veins contracted, so as to be barely distinguishable from the already narrowed arteries, and the disc retained its atrophic tint. The author considers that the condition was due to simultaneous thrombosis of the retinal artery

and vein, but in cases in which he had previously diagnosed the condition, he has never seen the white bands along the veins, which were quite unlike those associated with changes in the walls of the vessels. From their sudden appearance and rapid disappearance he is led to form the opinion that they were due to swelling of the perivascular lymphatic spaces, but he is doubtful whether a simple increase in the quantity of fluid present would be sufficient to cause the ophthalmoscopic appearance of a white opacity or whether an abnormal multiplication of the lymph cells must be assumed in addition. He is also at a loss to account for the increased pressure necessary to cause such lymphatic stasis unless the whole condition was due to a hæmorrhage into the sheath of the optic nerve, a hypothesis which he does not care to put forward seriously, as it has been called upon to account for so many different conditions.

The author publishes the case, as he considers that it is of interest in connection with his paper on retinal changes following fracture of the skull in the same number of the *Annales d'Oculistique* (*see* above). R. J. COULTER.

(3) **Purtscher,** of Klagenfurt, thinks that the shining white spots which are often seen in the fundus, mostly round the optic disc and along the retinal veins, and which are generally situated in the innermost retinal layers, are products of stasis and due to increase of intracranial pressure. As a rule, they are caused by fracture of the skull or by extensive compression of the trunk. They are most likely due to mechanical causes—inclusive of embolism—and not to chemical or to toxic agents. R. GRUBER.

XI.—MEMBRANOUS CONJUNCTIVITIS.

(1) **Calhoun, J. G.—A peculiar case of membranous conjunctivitis.** *American Journal of Ophthalmology*, January, 1911.

(2) **Delord and Revel.—On a case of diphtheritic conjunctivitis. (Sur un cas de conjonctivite diphtérique.)** *La Clinique Ophtalmologique*, 10 juillet, 1912.

(3) **Hoor, Karl v.—Diphtheritic, diphtheric, and croupous conjunctivitis. (Conjunctivitis diphtheritica, diphtherica, und crouposa.)** *Klin. Monasbl. f. Augenheilk.*, März, 1913.

(1) In order to appreciate this rather extraordinary case by **Calhoun**, of St. Louis, it is necessary to quote the author's words freely. The patient was a girl of 17 years, who had been treated for trachoma, but in whom the trachomatous tissue had largely disappeared. When seen, the lower lid had been swollen for four days: no history of injury: she had been having daily treatment with 25 per cent. argyrol. "Examination showed a roughly quadrilateral area of thickened conjunctiva, occupying the middle third of the lower lid, some 4 mm. in breadth, beginning at the lid margin, and covered by a yellowish-grey exudative membrane. This could be wiped away with little difficulty, except near the lid margin, when it appeared to infiltrate rather deeply the conjunctiva, and here, with the lid in position, it presented in a peculiar rounded projection—sort of an eaves, overhanging the Meibomian duct openings, and having its front daintily scalloped in symmetrical little segments. The lid could be easily everted, and there was

not then—and I might here state, nor at any time subsequently—the deep infiltration with stiffening of the lid tissues, characteristic of diphtheritic conjunctivitis. Nor was there then or later, pain of any account, on manipulation, nor secretion at any time, other than of a scanty mucoid character." The *plaque* gradually moved down into the cul-de-sac, and climbed up on the bulbar conjunctiva, coming to a halt 4 mm. from the lower corneal limbus. As it did so the lid surface became free of exudate. After coming to a stand on the globe it reappeared on the lid. Then a patch which persisted but was non-progressive, appeared on the upper lid.

"A number of agents, short of the actual cautery, were employed, and it resisted them all with ease. The nearest approach to a successful combatant I was able to place in the field was a 1 to 500 formalin solution. But its effect was not so marked as the first of three injections of tuberculin which were given at intervals of two days. On the third morning after the first dose, the exudate was gone so cleanly that it seemed quite impossible for it to re-establish itself within six days. But it did. 3,000 units of diphtheritic anti-toxin later produced not the slightest effect." In the sixth week an irregular rise of temperature was noticed, but no cause other than the eye condition could be found. In the tenth week the cornea began to grow steamy. The epithelium gradually broke down. The iris was hyperæmie. "*Pari passu* with the corneal involvement, the bulbar and palpebral conjunctiva cleared up, and when the exfoliation of the corneal epithelium had reached its height, there was no particle of the membranous exudate to be seen. . . . The cornea required two weeks to heal completely, under treatment with atropin, xeroform, and light bandage, but even yet, three weeks later, the lower quadrant is somewhat nebulous, though gradually clearing. Vision is 15/38. The patient has regained her normal color and weight."

The author apparently has no views on the ætiology of this remarkable case. It is explained that tuberculin was tried because the girl was known to have been fondling a tuberculous child. The temporary improvement after the tuberculin is thought to be due "simply to a moderate anti-toxic effect on whatever micro-organism may have been present." Such micro-organism was never demonstrated. The xerosis bacillus was the only organism found. "On circumstantial evidence the xerosis bacillus might, in this case, fall under grave suspicion, and the question as to whether a possible variant of this saprophyte might not on occasion develop an affinity for living tissue, seems not an unreasonable one. Its unresponsive attitude toward the action of the diphtheritic anti-toxin, as above mentioned, does not, however, lend strength to the supposition of its kinship with the Klebs-Lœffler bacillus, other than morphologically and culturally." ERNEST THOMSON.

(2) **Delord,** of Nîmes, and **Surgeon-Major Revel** report a case of diphtheritic conjunctivitis which occurred under somewhat unusual and certainly misleading circumstances.—Some hospital nurses were undergoing training in the management of eye dressings, and, after the lecture, began to practise eversion of the upper lid on one of themselves, namely, the patient. As the result of this handling, a severe conjunctivitis developed, and, since one of those who had been handling this patient's lids had been in charge of a case of gonococcic ophthalmia in the hospital wards, it was very naturally assumed that the gonococcus was the organism concerned, and treatment was directed to that. After treatment had been begun, a bacteriological examination was made, and proved negative as regards the gonococcus. After a while, the second eye became affected, and now false membranes appeared. To shorten the story, the case turned out to be

diphtheritic and got quite well under serum treatment, but the only possible theory to account for this patient's infection was that she herself had been carrying the organism in the throat, nose, or conjunctiva since a date four months previously, when she had been nursing diphtheria in another hospital. A slight traumatism caused by the *maladroit* handling had allowed the bacillus of Löffler to gain entrance. ERNEST THOMSON.

(3) The paper of **v. Hoor**, of Budapest, opens with some remarks to emphasize the fact that the terms "Diphtheritic conjunctivitis" and "Croupous conjunctivitis" are based on clinical characteristics, while "Diphtheric conjunctivitis" or "Diphtheria of the conjunctiva" is a diagnosis that can only be made when the presence of the diphtheria bacillus has been proved. The case which he describes is that of a child which, shortly after birth, suffered from suppuration of the umbilicus. This cleared up in three months, but, a few days later, suppuration of the cervical glands appeared. The glands were incised, and took many months to heal, after which inflammation set in in both eyes. This took the form of a diphtheritic conjunctivitis in one eye and a croupous or pseudo-membranous conjunctivitis in the other. In both streptococci were found to be the infective agent. The infection was severe, and led to ulceration of both corneæ. During his handling of the case, the author punctured his own finger with a pair of forceps, and suffered thereafter from a severe general infection, with lymphangitis, fever, rigors, abscesses in the neck and leg, etc. The child's mother suffered during her pregnancy from symptoms which suggest a streptococcus infection, and it is assumed that the original infection of the infant took place through the placental circulation.

A. J. BALLANTYNE.

XII.—LOCAL ANÆSTHESIA.

(1) **Vail, Derrick T.—Enucleation of the eye under local anæsthesia. Indications and technique.** *Journal of Ophthalmology and Oto-Laryngology*, August, 1911.

(2) **Danis, Robert and Danis, Marcel.—Three operations upon the eye and face practised under regional anæsthesia. (Trois opérations sur l'œil et sur la face pratiquées sous anesthésie régionale.)** *La Clinique*, juillet, 1913.

(1) The history and evolution of the operation of enucleation are given by **Vail**, of Cincinatti. The operation is an old one. Ferrall, in 1841, discovered by accident that the eyeball could be shelled out of its socket by first severing the attachments of the recti muscles from the globe and finally dividing the optic nerve by means of curved scissors. Chloroform anæsthesia was discovered about this time. In 1851, Pritchard first advised enucleation of a blind and injured eye as a measure to prevent the loss of the remaining eye through sympathetic ophthalmia. In 1884 cocaine was introduced, and in the same year Cocks performed the operation under cocaine anæsthesia—most likely the simple dropping of a 4 per cent. solution in the eye. In 1888, Tosswill published a paper on "Enucleation of the eyeball with intra-orbital injections of cocaine."

In 1905 Elschnig's method of ciliary anæsthesia was described: "to inject a weak solution of cocaine in the region of the ciliary ganglion. He uses a hypodermic, the needle of which, one and three-fourths inches long, is entered near the temple edge of the orbit at the lower margin of the external rectus muscle, the point being inserted behind the eyeball. About seven or eight drops of the solution are forced into the loose tissue surrounding the ganglion. This, he states, seems to suffice in producing profound anæsthesia of the globe and tissues adjoining." He gives a hypodermic injection of one-sixth of morphine in the arm half-an-hour previous to the operation. Bruns and Robin (1909) recommend the following solution: 4 per cent. solution cocaine muriate, 10m.; 1/1000 solution of adrenaline chloride, 10m.; normal salt solution, 20m. This make a 1 per cent. solution of cocaine and 1-4000 solution of adrenalin: ten drops of this solution contain one-tenth of a grain of the cocaine salt.

Four cases are quoted from personal experience. Fifteen drops of this cocaine solution were used, one half of this amount subconjunctivally, and fifteen minutes later, the other half behind the orbit in the region of the optic nerve. The solution is first sterilised by boiling. HENRY L. G. LEASK.

(2) The brothers **Danis**, of Brussels, have successfully adopted regional anæsthesia by means of novocaine and suprarenine in three operations upon the annexes of the eye (spasmodic entropion, removal of lacrymal sac, entropion with epithelioma of the cheek). SYDNEY STEPHENSON.

XIII.—FRACTURE OF THE SKULL AND LESIONS OF THE OPTIC NERVE.

(1) **Le Roux, H.—Concerning lesions of the optic nerve following fracture of the optic canal. (A propos des lésions du nerf optique consécutives à la fracture du canal optique.)** *L'Ophtalmologie Provinciale*, juillet, 1912.

(2) **de Schweinitz, G. E. and Holloway, T. B.—Fracture of the skull with hæmorrhage into the optic nerve-sheaths and retinas: microscopical examination of the eyes.** *Trans. Amer. Ophth. Society*, Vol. XIII, Part 1, 1912, p. 120.

(1) **Le Roux**, of Caen, records two cases of injury to the head followed by loss of vision. One patient was struck by a stick and the other fell on his head. Both cases showed the same points, the ophthalmoscopic findings were alike, and the results were the same. The pupillary reaction to light by direct stimulation was absent, but the consensual reflex was present. Le Roux states that this is a most important symptom. Unilateral blindness following an injury and accompanied by loss of the pupil reflex to light, means an injury to the optic nerve, and permanent loss of sight. The normal aspect of the disc on the days following the accident has no bearing on the prognosis; atrophy appears later. Reference is made to von Hölder's statistical table of ninety-six fractures of the base, following shot wounds or falls on the head. Seventy-three cases presented a fracture of the orbital roof as well, while in 53 cases, the superior or internal wall of the optic canal was implicated, 42 cases showed a thickening within the sheath, in 25 there was complete unilateral blindness, and incomplete in four. P. A. HARRY.

(2) In brief, the case reported by **de Schweinitz** and **Holloway**, of Philadelphia, was as follows:

A man of 35 years was admitted unconscious, and when examined within half an hour, was found to have semi-dilated and unequal pupils, and numerous large hæmorrhages scattered over the fundus [illegible] the optic disc of each eye. Death in less than one hour after admission. A compound fracture extended from the posterior occipital protuberance, near the parietotemporal suture, to the base of the zygoma. Over this area there was a hæmorrhage into the scalp. The whole cranium was involved by a profuse subdural hæmorrhage. Ampulliform enlargement of the sheaths of both optic nerves. Closer examination showed that the sheaths of the nerves were distended by blood layer [illegible] mm. to 15 mm. thick. Arachnoid infiltrated by blood here and there.

Discussing the mechanism of hæmatoma of the sheath, the authors point out that among 126 fractures of the skull investigated by v. Hölder, 88 were concerned with the base, and in 54 of them there was a fracture through the wall of the optic canal. In 42 of these 54 instances there was hæmorrhage into the sheath of the optic nerve. The hæmorrhages in these cases were sometimes bilateral and sometimes unilateral. They were never found without associated fracture of the optic canal. But cases have been described where hæmorrhage into the intervaginal sheath of the nerve has taken place without fissure or fracture of the osseous optic canal (Talko, von Bergmann, Silcock, Panas, and Uhthoff). In the present case, too, no injury of any kind was demonstrable in the optic canal. de Schweinitz and Holloway conclude that hæmorrhages into the sheaths of the optic nerve may result from (1) fracture involving the optic foramen, and (2) the direct entrance of blood into the sheaths, the bony optic canal being intact. SYDNEY STEPHENSON.

XIV.—TEETH AND EYES.

Dor, Louis.—Hysterical amblyopia of dental origin. *La Clinique Ophtalmologique*, 10 avril, 1911.

"The title of this article will seem to some readers an incomprehensible sequence of words. It will be thought that if an amblyopia be hysterical it cannot be of dental origin, and that if it be of dental origin it cannot be hysterical. Yet everything depends upon one's idea of hysteria. If one understands by hysteria a malady which has no other cause than a physical or moral shock, or even only a suggestion, a malady of the mind (*conscience*), it is clear that an hysterical trouble cannot be of dental origin; but if one recognizes as hysteria a sudden anæsthesia which can disappear as promptly as it came, which developes in predisposed subjects, then this malady can be caused by any peripheral nervous irritation, and therefore hysterical amblyopia can be of dental origin, just as well as it can be of ovarian or any other origin."

Having thus cleared the ground, **Louis Dor**, of Lyons, reports the interesting case of a man of 26 years, whom he had known and treated for myopic astigmatism for fourteen years. On January 3rd, 1911 (nine years after Dor had last seen him), this patient reported that he had suddenly lost the sight of his left eye. He could not see a glowing electric lamp, and had only a little peripheral vision. When closely questioned, it transpired that since Dor had last seen the patient, there had been various nervous troubles.

On examination, it was found that the pupils were active, and that there was nothing amiss in the fundus. The diagnosis of hysterical

amblyopia was made, but the question remained as to the cause. It was found that the second upper left premolar was a crowned tooth (the French is *dent à pivot*) in very bad condition, and that the first molar was represented only by stumps, which were painful on digital pressure. The patient was advised to have these teeth extracted, and now volunteered the statement that four years previously he had had a patch of alopecia, which resisted all kinds of treatment, until one day he was advised to have a certain tooth removed because it was probably the cause of the alopecia. He had the teeth extracted, and fifteen days later the hairs began to grow again. The patient was surprised to learn that there might be a relation between his amblyopia and the teeth, but at once had the first molar extracted as advised by Dor. This tooth was found to have periodontitis, and there was some ostitis of the jaw. All this happened on the Tuesday; there was no improvement by the Friday, so the other tooth was extracted. From the evening of that day he commenced to see the light of an electric bulb. By Sunday he could read the title of a journal, and on the Wednesday following several lines of an article. Fourteen days after the first visit to Dor, this patient could read the finest print.

Dor is perfectly well aware that his interpretation will not be accepted by everybody. He is not, however, satisfied with the ordinary intrepretation that this is merely a case of cure by suggestion. If a dental lesion can cause a patch of alopecia in a patient, there does not seem any reason why it should not have a reflex inhibitory influence on the contractility of the retinal rods in predisposed subjects, and he thinks that the diagnosis may be put in this way:—"Nervous malady of the retina having the character of an hysterical amblyopia, and being caused by irritation of a dental nerve." Dor makes the strong point in favour of his explanation that had the cure really been only a matter of suggestion it ought to have taken place at once, and suddenly. As a matter of fact, there was no improvement after removal of the stumps and it was only after the crowned tooth had been removed that improvement gradually took place. Further, this patient was very much annoyed by his visual defect, and willing to do everything to get rid of it; so that there was no question of malingering.

Dor finishes his article with some remarks on the influence of crowned premolars in the upper jaw on the eye, with special reference to accommodative asthenopia. ERNEST THOMSON.

XV.—ANTI-GLAUCOMATOUS SCLERECTOMY.

(1) **Dupuy-Dutemps.—A modification in the technique of Elliot's trephining. (Une modification à la technique de la trépanation d'Elliot.)** *Ann. d'Oculistique*, juin, 1913.

(2) **Kalt.—A method of anti-glaucomatous sclerectomy. (Un procédé de sclérectomie anti-glaucomateuse.)** *Ann. d'Oculistique*, juin, 1913.

(1) **Dupuy-Dutemps**, of Paris, considers that the dissection of the conjunctival flap in Elliot's operation of sclero-corneal trephining is difficult, and that the flap itself, when turned down over the cornea, obscures the field of operation and renders it difficult to recognise the exact spot to which the trephine should be applied. He therefore proposes to dissect the flap upwards,

making his incision at the corneal margin, and to hold it in place after the disc of the sclera has been removed by two sutures, one at each end of the incision.* From a statement of the author's, that the trephining should involve not the transparent cornea but the limbus and sclerotic, it would seem that he has not fully realized the object of Elliot's *technique*. R. J. COULTER.

2) **Kalt**, of Paris, considers that the use of scissors for removing the scleral flap in Lagrange's operation is objectionable, as they are clumsy and liable to cause loss of vitreous, and recommends the following method of excising the flap with a Graefe knife as the operation of choice in chronic glaucoma.—1. The globe is fixed by a silk suture passed through the superior rectus and held over the brow by an assistant. This keeps the eye turned down and also prevents the wound from gaping by abolishing the antagonistic action of the superior and inferior recti. 2. A conjunctival flap, as broad as the cornea, is dissected from the insertion of the superior rectus, right up to the corneal margin first with a scissors and later with a fine bistoury and is thrown down over the cornea. The edge of a Graefe knife is then placed above, and by sawing movements the tissues are incised in a plane perpendicular to the antero-posterior diameter of the eyeball until the knife has largely penetrated into the anterior chamber. 3. The posterior lip of the wound is seized in a forceps with very fine teeth, and a semilunar slice of sclerotic is cut off with the Graefe knife from above, downwards behind the outer arm of the forceps. An iridectomy is then performed, unless one has been previously done, and the conjunctival flap is replaced and fixed by the thread previously passed through the superior rectus. The author claims to have obtained by this method very extensive losses of substance in the scleral tissue at the periphery of the anterior chamber. R. J. COULTER.

XVI.—HYDATID CYST OF THE ORBIT.

Gabriéledès.—Orbito-temporal hydatid cyst. (Kyste hydatique orbito-temporal.) *Ann. d'Oculistique*, juin, 1913.

Gabriéledès, of Constantinople, records two cases of orbital hydatid cyst, and discusses the diagnosis and treatment of the condition.

The first patient, a woman aged 65 years, gave a history of an attack of painless œdema of left upper eyelid, temple, and cheek, six months previously, which disappeared without treatment in a few days, and was followed after an interval by appreciable proptosis with some insignificant pain. For a month before her first visit, the eye was red and slightly painful, while the vision was misty. On examination, the following conditions were found: proptosis sufficient to cause slight lagophthalmos, strabismus down and in, diplopia, redness of the ocular conjunctiva, scanty secretion, slight spontaneous pain increased on pressure, normal tension and fundus, V. 2/3, no preauricular or cervical glandular enlargement, prominence of the left temple and the supero-external part of the upper lid, normal conjunctival cul-de sac and palpebral lacrymal gland, smooth round tumour in the orbit not connected with the eyeball, definite fluctuation in the temporal and palpebral region without elasticity, crepitation, or pulsation, painful enlargement of the liver,

* See THE OPHTHALMOSCOPE, August, 1913, p. 485.

no sign of tumour on radioscopic examination, eosinophilia 13 per cent., urine free from albumin and sugar. On the day after the examination and manipulation of the tumour of the temple, the eyelids and cheeks were swollen, red, and painful. Operation was recommended and refused. As the pain in the eye got worse, and the vision continued to deteriorate, the tumour was tapped through the upper lid and 15 cc. of clear fluid was drawn off, with immediate relief of the proptosis, strabismus, temporal prominence, and pain. Radical operation was still refused, and on the same evening there was a further attack of œdema over the affected region, with ecchymoses of the skin and conjunctiva, pain, and heat. The proptosis returned and a fortnight later, under cocain, an incision was made along the upper-outer margin of the orbit, and the tissues divided layer by layer until a blueish-white area appeared in the supero-internal part of the incision. This was punctured and a quantity of fluid, as clear as that removed at the tapping, was drawn off. An attempt was made to extract the cyst, but it tore and had to be removed piecemeal followed by two daughter cysts. Digital exploration showed that the cavity extended to the bottom of the orbit and that the bone in the upper-outer part was rough, bare, and eroded. The cavity was curetted and a small hole found in the bone, 2 c.m. from the orbital margin. The temporal part of the cyst was found to be too deep to be dissected out from the original incision, and as a fresh incision in the temporal region was considered to be too severe for the patient, it was punctured from the original incision and a drain was inserted. A drain was also inserted in the orbital cavity, and the wound was sutured, and a dressing applied. The sutures were removed on the fifth day, the orbital drain in a fortnight, and the temporal drain later ; all seemed going on well, the vision being clear, the strabismus cured, and only slight proptosis left, when a fistula developed in the region of the temporal drain and continued to discharge for three months, until a small piece of spongy bone came away through it. The fluid removed at the tapping contained four grammes of sodium cloride per litre, became cloudy on heating, and gave a strong cloud of albumin with nitric acid. Examination after prolonged centrifuging showed some erythrocytes and cellular *débris*, and a fragment of the germinative membrane of the cysts, but no hooks. Hooks and scolices were found in the scrapings removed from the cavity at the operation.

The second patient was a girl, aged 20, who stated that her illness had commenced ten years previously with severe pains. When seen, her left eye was pressed completely out of the orbit and transformed into a half dried mass hanging by the side of the nose. This was caused by a large tumour springing from the upper part of the orbit, which it completely filled. Examination of the blood showed eosinophilia 7 per cent. The cyst was punctured and a clear fluid removed containing albumin recognisable by nitric acid but not by heat. There were no hooks. Half an hour after the puncture of the tumour, the eyelids became red. This was followed by rigors, slight elevation of temperature, anorexia, and an erysipelatoid state which lasted several days. As soon as the patient had recovered from the attack, the tumour was removed. Scolices and hooks were found in its walls.

The localisation of the cyst in the first of these cases in the wall of the orbit, with extensions both in the orbit and the temporal region, was exceptional, and the author is inclined to explain it as due to injury to the bone from a fall on her left side a year previously. The transient œdema which occurred in the first case spontaneously and after manipulation and puncture of the cyst, and the severer symptoms which occurred in the second patient after puncture of the cyst, are regarded as due to anaphylaxis.

Similar symptoms have been previously recorded, and the author considers that their occurrence is of diagnostic importance. Eosinophilia is valuable as independent evidence of the presence of a hydatid, if its other causes can be excluded, or as corroborative evidence, if other conditions point to it. The presence of specific antibodies, as shown by Weinberg's application of the Bordet-Gengou deviation of the compliment, is of important diagnostic value. In the first patient, however, the presence of eosinophilia of 10 per cent., five months after the operation, led to the suspicion that the cyst had not been completely removed, or that there was another hydatid in the liver, and a Weinberg's test was done with a positive result. The value of this test, however, was completely discounted by the fact that such a reaction may remain positive for years after the complete removal of a hydatid, so that only negative results are reliable under such circumstances, but the author suggests that repeated estimations should be made of the amount of antibodies developed in the body and that variations in this should be regarded as evidence of the presence of a hydatid. Owing to the anaphylactic symptoms which may follow it, punctures of a hydated cyst should, if possible, be avoided, unless it can be followed by a radical operation either at once, or, if done for diagnostic purposes, as soon as the necessary examinations have been made. It is of value for distinguishing between solid and fluid tumours. If the tumour is fluid, a diagnosis may have to be made between a hydro-meningocele and a hydatid. In the former case, puncture is contra-indicated and the author recommends examination of the orbital tumour while performing a lumbar puncture and calls attention to the fact that the cerebro-spinal fluid does not contain hydatid specific anti-bodies except it is in direct communication with an orbital or encephalic cyst or one along the vertebral column. The examination of the liquid drawn by puncture rapidly distinguishes soft sarcomata, lipomata, dermoids, non-pulsatile angiomata, and other cysts, or suppuration, from each other and from hydatid cysts, but the distinction between the latter and hydro-meningoceles requires laboratory methods. This examination should be chemical and microscopical. Chemically, the tests for albumin do not provide a distinction, but the author found globulin absent in hydatid fluid, while it is present to the extent of 0.12 per litre in cerebro-spinal fluid. Chloride of sodium is present in abundance in hydatid fluid but, contrary to the usual statement, it is also present in cerebro-spinal fluid. Both hydatid fluid and cerebro-spinal fluid contain substances which reduce Fehling's solution. Microscopical examination—cerebro-spinal fluid contains no cellular elements except a few lymphocytes and endothelial cells, while one may find in hydatid fluid, when centrifugalised, hooks or scolices and pieces of the germinative or cuticular wall of the cyst.

The treatment for hydatid cyst of the orbit is operation as soon as possible under ether anæsthesia, which has been shown, by experiments on animals, to suppress the anaphylactic shock. R. J. COULTER.

XVII.—ÆTIOLOGY OF IRITIS.

(1) **Butler, T. Harrison.—The etiology of iritis.** *Brit. Med. Journal*, April 8th, 1911.

(2) **Yeld, Reginald A.—The etiology of iritis.** *Brit. Med. Journal*, May 13th, 1911.

(3) **Campbell, E. Kenneth.—Note of a case in which occurred six attacks of gonorrhœal iritis within four years.** *Lancet*, August 12th, 1912.

(1) **Butler,** of Leamington Spa, has an interesting communication upon the ætiology of iritis, a disease of which he has seen 100 examples amongst 5,710 eye patients (1·75 per cent.). Cases of traumatic iritis and iritis occurring as a complication of interstitial keratitis have been excluded from the list. "The net result of the enquiry," to quote the author's words, "is that in at least 30 per cent. of all cases it is almost impossible to determine the real origin of the disease. Twenty-five per cent. are due to syphilis, and only about five or six per cent. can truly be termed 'rheumatic.' An examination of the figures shows that in twenty-two syphilitic cases ten were monolateral and twelve bilateral, so that this question cannot be considered in coming to a diagnosis. Cases due to oral sepsis and to intestinal stasis are more frequently bilateral than syphilitic cases. One patient, put down as rheumatic iritis, had had an acute attack of rheumatic fever only five weeks before the iritis came on. Two cases were associated wth albuminuria. In one there was albuminuria, iritis, and a single retinal hæmorrhage, but no retinitis. The other was a case of albuminuria and general anasarca. No case due to gout has ever been seen by me. The investigation lends no colour to Kenneth Campbell's view that seventy per cent. of all cases are due to syphilis. Even allowing that *all* my doubtful cases were syphilitic, which is absurd, even then the figure only reaches sixty-three per cent.! I believe that Römer's estimate, twenty-five per cent., is the correct one. It is interesting to note that in Palestine iritis is almost unknown, although pyorrhœa is very prevalent. I only remember seeing two or three cases among several thousand seen at the British Ophthalmic Hospital." SYDNEY STEPHENSON.

(2) **Yeld,** of Hampstead, London, publishes (not for the first time) an analysis of 159 cases of iritis met with at St. Bartholomew's Hospital, London, between the years 1883 and 1900. The cases were divided into rough groups as follows:

				Per Cent.
Group I:	Syphilitic—(i) Certain	46	72	45.28
	(ii) Probable	26		
Group II:	"Rheumatic"		26	16.35
Group III:	Gonorrhœal—(i) Certain	13	24	15.09
	(ii) Probable	11		
Group IV:	Toxæmic		16	10.06
Group V:	Gouty		2	1.25
Group VI:	Osteo-arthritic		2	1.25
Group VII:	Obscure		17	10.6
	Total		159	

SYDNEY STEPHENSON.

(3) After mentioning the facts in his case, **Campbell,** of London, makes the following remarks which seem worth transcribing:—

"The gonococcus is *par excellence* a pus-producing organism. Gonorrhœal 'rheumatism' and gonorrhœal iritis are probably not due to the gonococcus, for pus is but very seldom found in connection with either of them. Invariably (so far as my own experience goes) when these complications arise, 'injections' have been used in the treatment of the original urethritis, and the explanation is simple. The urethral epithelium is a very delicate one,

consisting mainly of a single layer of cells. By the introduction of the nozzle of the syringe "Nature's first line of defence" is broken down, thus permitting of a mixed infection. The moral is that no case of gonorrhœa should ever be treated by 'injections,' for in trying to kill the gonococcus we really kill, or considerably lower, the vitality of the cells which are striving hard to phagocyte the invading organisms." ERNEST THOMSON.

XVIII.—MISCELLANEOUS.

(1) **Koster Gzn., W.—A modified sideroscope.** *Archives of Ophthalmology*, March, 1910.

(2) **Gabriélides.—Adenoma of the Meibomian glands. (Adénome des glandes de Meibomius.)** *Archives d'Ophtalmologie*, mars, 1910.

(3) **Barr, J. Stoddard, and Rowan, John.—Optic neuritis and suppurative otitis.** *British Medical Journal*, March 26th, 1910.

(4) **Lohmann, W.—On a remarkable motor phenomenon of the eye. (Ueber ein beachternwertes Bewegungsphänomen des Auges.)** *Klin. Monatsbl. f. Augenheilkunde*, Mai-Juni, 1910.

(5) **Bahn, C. A.—A rare anomaly of the central vein of the retina.** *Ophthalmology*, July, 1910.

(6) **Dowling, J. I.—Supra-orbital neuralgia. Two cases.** *Ophthalmology*, July, 1910.

(7) **Barck, C.—Dressings after intra-ocular operations.** *American Journal of Ophthalmology*, October, 1910.

(8) **Lawford, J. B. — Retinal disease with massive exudate and detachment.** *Trans. Ophth. Society* U.K., Vol. XXX, p. 157.

(9) **Peretz.—Considerations on the causes and frequency of blindness among Egyptian children in Cairo. (Considérations sur les causes et la fréquence de la cécité chex les enfants égyptiens, au Caire.)** *Bull. de la Société d'Ophthal. d'Egypte*, 1911, and *Ann. d'Oculistique*, avril, 1911.

(1) **Koster Gzn.** gives a full description of his modifications of the sideroscope, which include a glass concave mirror for focussing the light, a more convenient position of the magnetic rod, and such a construction as enables the instrument to be conveniently packed away. ROSA FORD.

(2) **Gabriélidès**, of Constantinople, records the occurrence of an adenoma of the Meibomian glands in a boy of 15. The case is the ninth only in forty years. BERNARD CRIDLAND.

(3) The article by **Barr and Rowan**, of Glasgow, is in continuation of their previous one in the *British Medical Journal* of November 23rd, 1907, and is cast in a similar statistical form. One of the most interesting of their results is that which shows that in cases of purulent middle ear disease in which the fundus is normal the prospects of recovery without operation are four times greater than when distinct evidences of vascular engorgement of the fundus are present. Of 32 cases showing such evidences at a first examination, 15·8 per cent. healed or improved, whereas in 33 cases showing normal fundi 60·75

per cent. healed or improved. In this second series of 60 cases optic neuritis occurred in 6, and the nerve was atrophic in 1—7 in all. In the first series of 100 cases, optic neuritis occurred in 4, so that this sign was present in 11 cases of the 160, or 6·8 per cent. The type of optic neuritis has usually been mild, but in four cases it could be classed as "choked disc." The vision, however, has remained unaffected, and there has been no true secondary atrophy. The authors emphasise the fact that the optic neuritis associated with pyogenic intracranial lesions of otitic origin need not be followed by atrophy and blindness, and that Sir Victor Horsley's *dictum* as to opening the dura might require some modification. The following are the authors' conclusions :—

(1) Optic neuritis may occur in cases of purulent middle ear disease without obvious signs of an intracranial complication.

(2) Apart from optic neuritis, vascular changes of a lesser degree are frequent (about 25 per cent.).

(3) Cases of purulent middle ear disease in which optic neuritis or vascular engorgement of the fundus is present are much less amenable to local treatment than those in which the fundus is normal.

(4) As a general rule, an improvement in the eye condition is accompanied by improvement in the aural condition, while an increase in the intensity of the changes in the fundus or their persistence is associated with less amenability to treatment and greater gravity of the ear condition.

(5) The most probable cause of vascular engorgement of the fundus, or optic neuritis, is serous meningitis (diffuse or localized).

(6) Optic neuritis caused in this way is not usually followed by atrophy, and unless there are other symptoms demanding it, opening of the dura mater is unnecessary. ERNEST THOMSON.

(4) **Lohmann** observed repeatedly the following phenomenon in patients with upward and outward deviation of a blind eye.—On covering the healthy eye with the hand, its blind fellow moves downwards and inwards, this movement being accompanied by slight rotation of the eye. In the two cases, of which a more detailed description is given in this paper, the unilateral blindness was the result of injury. Lohmann thinks the primary deviation of the eye might be the effect of the suppressed consensual pupil reaction, the stimulus passing into the inferior oblique muscle. Thus, the contraction of the latter muscle would represent a kind of vicarious movement for pupillary contraction. Shading the seeing eye would remove the reflex, and cause a relaxation of the inferior oblique muscle, instead of consensual dilatation of the pupil.

C. MARKUS.

(5) The main lower vein in the left eye of **Bahn's** patient was three times the size of the corresponding vein in the right eye, and when it reached the lower border of the disc it divided into two branches, which separately entered the disc. A. J. BALLANTYNE.

(6) **Dowling's** first patient was a young lady who suffered from persistent paroxysmal pain radiating over the area supplied by the left supra-orbital nerve. On closure of the lids, there appeared a swelling at the region of the supra-orbital foramen, and palpation revealed a small moveable tumour there. Forcible closure of the lids caused temporary increase of the pain. Through a small incision below the eyebrow, the little tumour was removed. It was roughly spherical, and about 15 mm. in circumference. It proved to be a sac formed by the walls of a dilated hair follicle, the contents having degenerated into a hard calcareous mass. There had been no recurrence of the pain nearly four years later. The second patient, a married woman of 54, complained of pain in the area of the right supra-orbital nerve. With the

exception of an error of refraction, the right eye was normal, but the left eye showed glaucomatous cupping and atrophy of the optic nerve. Glasses and eserine were prescribed, and gave slight relief. A history was obtained of an injury to the left eyebrow some weeks earlier, and this suggested the possibility of a fracture of bone in the region of the supra-orbital foramen. An incision exposing the foramen confirmed the diagnosis, the foramen was converted into a notch and the nerve resected, and the symptoms were permanently relieved. A. J. BALLANTYNE.

(7) **Barck**, of St. Louis, discusses methods of dressing under the headings: (1) bandage method (with special reference to the pressure bandage); (2) strip method (gauze or cotton held in place by adhesive plaster); (3) free method (the eye being open under a mask); (4) open method (no dressing at all). The author rules the pressure bandage method and the open method out of court, the first because it tends to cause the lips of a wound to gape rather than to remain in apposition, the second because it is dangerous and opposed to common sense. The strip method leaves the eye too much open to accidental damage. In the free method, movements of the lids, however beneficial they may be in the matter of not interfering with the normal flow of tears, may irritate the wound, especially if the latter is large, or the lips are not in perfect apposition. Finally, the author himself prefers to combine (2) and (3). The lids are covered with a thin layer of gauze and cotton, or cotton alone, which is held in place by adhesive plaster from forehead to cheek. Over this is placed the shield, which is held by a plaster strip from nose to temple.

ERNEST THOMSON.

(8) **Lawford**, of London, saw a man of twenty years of age who was suffering from dim sight of eighteen months' duration in the right eye and of six months' in the left. There was retinitis with massive exudate in the right and retinitis in the left. von Pirquet's test negative and the Wassermann reaction was also negative. The man's mother had died of "phthisis of the brain."

LESLIE BUCHANAN.

(9) **Peretz** finds that ophthalmia neonatorum, trachoma, and ocular variola are rarely the cause of blindness in children in Cairo, which in 94.21 per cent. of the cases investigated by him was due to complications of conjunctivitis due to infection with the gonococcus either alone or mixed with other organisms such as the Koch-Weeks' bacillus or staphylococci. In 100 such cases the infection occurred during the first year of life 70 times, and between the ages of 1 and 5 years 28 times. Among 5,465 children, 31 were blind (0.55 per cent.) and 128 were blind in one eye (2.34 per cent.) R. J. COULTER.

BOOK NOTICES.

Julius Hirschberg's Ausgewählte Abhandlungen (1868—1912). OSCAR FEHR AND WILHELM MUHSAM. Pp. 864. Leipzig: Veit and Co. 1913. Price: 30 marks.

This is a collection of the more interesting and important papers of the great German master, whom we have lately seen amongst us at the International Congress of Medicine. By its form it can contain nothing new, but it is none the less welcome for all that, in that it brings together a mass of valuable literature which was with difficulty studied in the originals, at least in this country. It is, in fact, a monument (and what ophthalmologist can dream of a finer?) erected by his pupils to celebrate a great man and his work.

Hirschberg's knowledge, industry, and clinical insight are held before us on every page. The scheme of the collection is to divide the papers into three main classes; the first deals with the ocular complications of general disease, and contains the well-known work on diabetic retinitis, and on the corneal conditions in hereditary syphilis. The second deals with various operations on the eye, and more especially with the magnet—operations for which the master is justly famous; the third, with special ocular diseases and their treatment.

The only blemish is one for which Hirschberg cannot be held responsible: there is no index. HAROLD GRIMSDALE.

On Traumatic Dislocation of the Lens. (Ueber traumatische Linsenluxation.) By Dr. H. DAVIDS. Reports from *der Festschrift der medizin-naturwissenschaft in Münster i./W. zur vier und achtzigste Versammlung Deutsch. Naturforscher und Aerzte.* 1912. Halle am S.: Carl Marhold.

Davids, of Münster i./W., gives an interesting account of the phenomena associated with dislocation of the lens after blows upon the eye. He discusses the various theories which have been advanced to explain exactly how and why the lens becomes dislocated, and why ruptures appear in the iris after blows upon the globe. We must, he says, take a common-sense view of the mechanics of the accident. A direct blow upon the cornea drives it inwards, fluid is displaced backwards, and exerting pressure in all directions, forces the iris backwards and distends the sclera, making tension perhaps upon the zonule. The lens feels the sudden pressure and is forced as far back as the vitreous will permit. Were the capsule of the eye rigid this action could not take place; but it is not, it can stretch slightly, otherwise it must rupture, as we know it does when the blow is sufficiently severe. The iris may be driven back until it passes completely or partially behind the lens, in the former case the lens passes into the anterior chamber, generally it falls into the vitreous, but even then it may be found in the anterior chamber, more especially if the pupils have been dilated with atropine. When the lens has fallen into the vitreous, liquefaction of the vitreous ensues in most cases, and generally iridocyclitis follows. In some few cases the dislocated lens is well tolerated. Glaucoma is a very common sequel to lens dislocation, and is more frequent after a partial than after a complete dislocation.

The author advises that an attempt be first made to try to get the lens into the anterior chamber. The pupil is dilated with atropine (homatropine would be better), and the patient lies prone. If the lens falls into the anterior chamber, the pupil must be contracted with eserine to keep it there while it is extracted. This attempt usually fails, and then a spoon or vectis must be employed. Davids makes a small incision through the cornea, not the limbus, and then passes a suture. The assistant now holds the wound closed, while the operator enlarges the wound on each side with scissors. The wound is then allowed to open, and the vectis introduced. The assistant is always ready to close the wound by crossing the suture if vitreous present. It would surely be better to adopt Kalt's method, pass the suture first and then make a section with the Graefe knife in the usual manner. A preliminary iridectomy of wide dimensions would also make the extraction safer. In any case, the author says the operation is one of the most thankless in ophthalmic surgery, and the eye is often lost. He advises a downward section in most cases. T. HARRISON BUTLER.

Elliot's Corneo-Scleral Trephining: A technical study, anatomical and experimental researches. (La Trépanation Cornéo-Sclérale d'Elliot: étude technique, recherches anatomiques et expérimentales.) By DR. ALBERT DUCAMP. Paris: Vigot frères, 23, Place de l'École-de-Médecine, 23. 1913.

In this opportune contribution Dr. Albert Ducamp, of Paris, makes no attempt to appraise the value, relative or absolute, of Elliot's operation of corneo-scleral trephining in cases of glaucoma. On the contrary, he studies the topography of the operation and the conditions under which the fistula produced by it heals, since, contrary to Lagrange's operation, it is a well-defined procedure and is always identical with itself, while its proper execution does not invariably depend upon the skilfulness of the operating surgeon. Although it is impossible as yet to affirm that as regards the clinical results Elliot's is superior to Lagrange's operation, Ducamp, so far as experiments upon animals go, feels justified in claiming that it is much the simplest and safest way of obtaining "fistulisation" of the eyeball.

Diligent readers of THE OPHTHALMOSCOPE have little to learn from the first part of the book, devoted to a technical study of Elliot's operation, since most of the procedures described by Dr. Ducamp first saw light in the pages of this periodical.

At the same time certain figures, quoted from Rochon-Duvigneaud, concerning the dimensions of the angle of the anterior chamber in man, may be glanced at with advantage. As everybody knows, the anterior chamber is larger than the transparent cornea, so that its periphery is hidden beneath the opaque border of the sclera. Owing to the fact that the chamber has an almost exactly circular contour, while the cornea forms an oval figure, the long axis of which is transverse, it follows that the amount of the angle concealed by the scleral border varies in its different parts. Rochon-Duvigneaud's figures were obtained by measuring the interval between a line marking the transparent edge of the cornea, on the one hand, and the angle of the anterior chamber, on the other. They are as follows: between the upper end of the vertical axis and the angle of the chamber, 2·25 mm.; between the lower end of the vertical axis and the angle of the chamber, 2 mm.; and between the nasal or temporal end of the horizontal axis and the angle of the chamber, 1·25 mm.

The second part of the book is devoted to an account of the anatomical and experimental researches pursued by the author.

In order to ascertain the topography of subconjunctival trephining, Ducamp followed the *technique* recommended by Rochon-Duvigneaud, which was briefly as under.—The contents of the orbit, including the eyeball, were removed *en bloc* from recent corpses, in such a way as to interfere as little as possible with the normal arrangement of the ocular conjunctiva. By careful dissection, the eyeball, with its conjunctiva, was isolated. The globe was then fixed upon a piece of cork by the aid of pins, but without penetrating the eyeball. The eyeball, secured in this way, was trephined. In the next step, the globe (still attached to the piece of cork) was immersed in a fixing fluid, such as 10 per cent. formol or Müller's fluid. The specimen was freed from the cork only after complete fixation by the fluid selected, and then after treatment by the usual means, it was embedded and cut in celloidin. Measurements of the sections were obtained by Nachet's ocular micrometer combined with Nachet's objective No. 2, the micrometric divisions having previously been carefully checked by the extremely accurate markings afforded by Hayem's hæmatimeter. Measurements were taken from the

tendon of the ciliary muscle to a fine groove made with a Graefe's knife at the point where transparent cornea runs into opaque sclera.

From experiments made upon three human bodies, Ducamp concludes that dissection of the conjunctival flap by scissors is always inadequate, since at the upper part of the limbus the adherent zone of conjunctiva extends to a height varying from 1·2 mm. to 1·4 mm. A 2 mm. trephine applied after such a dissection would assuredly impinge upon the ciliary body. It is necessary, as Elliot has insisted, to trephine far forwards. If Elliot's procedure be adopted, we must dissect with a blade far enough back to have at the base of the conjunctival flap a blackish crescent of from 0·5 mm. to 1 mm. in breadth. This appearance (first pointed out by Elliot) finds its natural explanation in the fact that the pseudo-limbus, seen at the bottom of the dissection, lies behind the true limbus, simply on account of the obliquity of the corneal bevel. The dimension of this bevel set under the sclera, as it were, was found constantly to amount to 1 mm. The aperture made by the instrument was invariably a little smaller than that of the particular trephine employed. If the modification proposed by Dupuy-Dutemps be adopted (see THE OPHTHALMOSCOPE, August, 1913, p. 485), the conjunctival covering must always be brought well below the orifice of the trephine aperture, and even then we must bear in mind the possibility of the free edge of the displaced conjunctiva rolling in upon itself.

In brief, upon these several points, Ducamp's experiments, made upon the dead, confirm in a remarkable way Elliot's experiences, obtained from the living.

Ducamp selected cats for the next series of experiments, intended to ascertain how the trephine hole healed. Cats had several advantages over rabbits for the purpose. For example, the anterior chamber was deep; the cornea was sufficiently resistant; the iris was endowed with great contractility; and, last but not least, the tonus of the cat's eye appeared to be almost constant. Upon four of these animals Elliot's operation was performed under the influence of A.C.E.; from time to time the intra-ocular tension was estimated by the Schiötz tonometer; and the eyes were enucleated, two at intervals of 26, and two at intervals of 33 days after the original intervention. The globes were fixed in 10 per cent. formol and Müller's fluid, and embedded in celloidin. They were then cut for the microscope, and sections stained with hæmatoxylin-rubine-orange.

The trephine had been applied, according to the particular cat selected, twice to the sclera, once to the limbus, and once midway between cornea and sclera. Tension had returned to normal in all the cats before the eye was enucleated. Nevertheless, in one of the experiments alone did the author succeed in obtaining "fistulisation," and even in that animal, where the operation was performed at the limbus with a 2·5mm. trephine, the condition was merely transitory. The author concludes from these facts that in cats the trephine should be of the diameter mentioned, and that in order to excise the extremity of Decemet's membrane, trepanation should be neither corneal nor scleral, but should include both the structures in question.

It was found that the trephine hole, no matter where placed, speedily became blocked by more or less vascular fibro-cellular tissue, unless, indeed, all healing was precluded by entanglement of the iris. This fibrous tissue appeared to be impermeable. It was found that the fibrous callus (so to speak) did not represent even a weak spot, inasmuch as it always manifested itself as a rectilinear element in the composition of the corneo-sclera. Descemet's membrane was an important factor in the healing of a corneo-scleral aperture. That membrane was found to be simply incised and

not excised, even in a cat where iridectomy, made *à ciel ouvert*, proved that the anterior chamber had been perforated by the trephine.

In one case of corneo-scleral trephining, combined with iridectomy, where the Dupuys-Dutemps flap had been adopted, "fistulisation" had been established for at least a few days, and in this animal a little tag of sclera, which had been spared by the trephine, appeared to have taken an important share in the processes of cicatrisation. By Elliot himself an important part is attached to such tags, which he believes prevent the entanglement of the iris or ciliary body in the surgical orifice. However that may be, Ducamp holds that their existence may favour obliteration of the trephine orifice by newly-formed tissue.

It seems likely that in man, as in cats, the trephine hole soon becomes plugged, except in cases where a heterogeneous element, such as the iris, forms a mechanical obstacle to the proper repair and cicatrisation of the loss of substance. SYDNEY STEPHENSON.

Transactions of the Ophthalmological Society of the United Kingdom. Volume XXXIII. London: J. & A. Churchill, 7, Great Marlborough Street. 1913. Price 12s. 6d.

Some of the contents of this attractive looking and well illustrated number of the *Transactions* of the Ophthalmological Society have already been abstracted in the columns of THE OPHTHALMOSCOPE. Others will be published in due course.

The anniversary address of the sixteenth annual meeting of the American Academy of Ophthalmology and Oto-laryngology will be given by Colonel R. H. Elliot, I.M.S., on October 27th next, at Chattanooga, Tenn., U.S.A.

THE OPHTHALMOSCOPE DIARY.

	1913.	
Midland Ophthalmological Society.	October 7th.	Birmingham.
Scottish Ophthalmological Club.	October 18th.	Royal Victoria Eye Infirmary, Paisley.
American Academy of Ophthalmology and Oto-Laryngology.	October 27th to October 29th.	Chattanooga, Tenn., U.S.A.
Royal Society of Medicine: Section of Ophthalmology	November 5th.	1, Wimpole Street, London.
Royal Society of Medicine: Section of Ophthalmology.	December 3rd.	1, Wimpole Street, London.
	1914.	
Oxford Ophthalmological Congress	July.	Oxford.
British Medical Association: Section of Ophthalmology.	July 15th to July 17th.	Aberdeen.
International Congress of Ophthalmology.	August 10th to August 15th.	St. Petersburg.

THE
OPHTHALMOSCOPE.
A MONTHLY REVIEW OF CURRENT OPHTHALMOLOGY.

VOL. XI.—No. 11.] *NOVEMBER 1, 1913.* [TWO SHILLINGS.

CONTENTS.

Original Communications.—

1. Sydney Stephenson.—On some of the Causes of Failure after Elliot's Sclero-Corneal Trephining 640
2. N. C. Ridley, F.R.C.S.—Some Commonplaces with regard to Plastic Operations... 650
3. Franz Deutschmann, M.D.—The Pathogenesis of Sympathetic Ophthalmitis 654
4. A. W. Stirling, M.D.—Latent Convergence or Divergence? With an Addendum by Ernest E. Maddox, M.D. 660

Clinical Memoranda.—

1. Percival J. Hay, M.D.—Synchysis scintillans 663
2. Wilbur B. Marple, M.D.—On the Electric Ophthalmoscope, with Presentation of an improved Model 663

Novelties.—

1. The "Signal" Vision Test Type.—By N. Bishop Harman ... 667
2. A Modified Glaucoma Trephine.—By Frederick A. Anderson ... 668
3. A Trephine worked by Electric Motor.—By H. H. Taylor, F.R.C.S. 669

Current Literature.—

I. Ophthalmology and General Medicine (third notice) 670
II. The Ætiology of Diseases of the Eye 673
III. Colour Vision 676
IV. Injuries to the Eye by Light 677
V. Inflammations of the Conjunctiva 678
VI. Bacteriology 682
VII. Sympathetic Ophthalmitis 684
VIII. Remedies (ninth notice) 692

Correspondence 695

Book Notices 698

Notes and Echoes 701

The Ophthalmoscope Diary... 706

ORIGINAL COMMUNICATIONS.

ON SOME OF THE CAUSES OF FAILURE AFTER ELLIOT'S SCLERO-CORNEAL TREPHINING.

BY

SYDNEY STEPHENSON,

LONDON, ENGLAND.

Introduction.

ELLIOT'S operation of sclero-corneal trephining, first described in the columns of THE OPHTHALMOSCOPE four years ago, is now on trial in every part of the habitable globe. The view of those well qualified to judge appears to be that it embodies better than any known procedure those points now generally believed to be essential for the surgical cure of glaucoma. It bids fair, then, to displace the other modern substitutes for iridectomy.

That even such a well-found operation as Elliot's cannot succeed in every case goes without saying. That would be too much to expect. With regard to this, and to many other points, Elliot[1] has himself placed at our disposal a set of valuable figures. He gives, as the result of his personal experience, 4·6 as the percentage of failures among upwards of nine hundred instances of trephining. Again, the Moorfields Hospital statistics, as quoted by G. F. C. Wallis, late senior house surgeon, yield 9·8 per cent. of case failures among 91 patients affected with chronic primary glaucoma. Any case that developed *plus* tension within a year of the operation was counted as a "failure" in the figures quoted by Wallis.[2]

It becomes a matter of importance to enquire as to the reason or reasons for the occasional failure of trephining to reduce raised intra-ocular tension. From the clinical point of view, Elliot[3] has gone deeply into the question, and, with characteristic acumen, has enumerated practically all of them. Thus, he is convinced that the trephine hole may become occluded by the proliferation of connective tissue, derived either from the episclera or from the uvea. He regards the occurrence, however, as uncommon, even in long-standing cases. He has further pointed out that the trephine hole may be blocked by iris, ciliary body, suspensory ligament, lens, or vitreous, making a movement forwards when the aqueous has been allowed to escape through the opening drilled in the corneo-sclera. At the same time he doubts whether the aperture ever becomes plugged, provided there has been no intra-ocular hæmorrhage, and furthermore, the surgeon has not dragged uveal tissue into the wound whilst performing an iridectomy (*loco citato*,[1] pp. 83 and 89).

The conditions under which the trephine wound heals have been investigated by Rochon-Duvigneaud and Ducamp[4] by a series of experiments upon cats. They found that in those animals a loss of substance in sclera or corneo-sclera, even as large as 2mm., had become closed with fibrous tissue at latest on the twenty-sixth day after operation, except in cases where entanglement of the iris had put an end to all cicatrisation. They hazarded the speculation that in man, also, a similar obliteration might occur. They laid stress upon the fact that the ocular tunics had an invincible tendency to repair any loss of substance, such as that made by the trephine, but, then, they by no means followed Elliot's *technique* in its entirety. Kümmell,[5] also, has studied upon rabbits the conditions under which the trephine wound in Elliot's operation heals. He found that the defect was at first filled with

a fibrinous exudation, including leucocytes. During the ensuing days this became replaced by young connective tissue, which, in turn, was transformed little by little into fibrous connective tissue. The fibres of the newly-formed tissue did not contrast markedly with the lamellæ of the cornea or sclera, unless it were by their irregular arrangement. Kümmell was not inclined to attach any high powers of filtration to the new tissue.

At the moment* we lack reports of the anatomical examination of human eyes in which trephining has failed to relieve the symptoms of raised intra-ocular tension, although we shall doubtless be plentifully supplied with such reports before long, as the operation becomes more and more widely practised. The anatomical examination of eyes, removed after death, where during life the operation had relieved the symptoms of glaucoma, would give us another set of facts of a different but equally valuable character.

In the meanwhile, even fragmentary contributions to the question (such as the present one), may not be unacceptable.

General Remarks.

The causes of failure may be roughly classed as:—1. Septic; 2. Hæmorrhagic; and 3. Mechanical.

1. Septic Failure.

Elliot[3] has not lost a single case of trephining by suppuration or acute irido-cyclitis among nearly nine hundred consecutive operations. This he attributes to the rigid conjunctival antisepsis he employs. But such an event must be extremely uncommon even when the ordinary aseptic precautions are taken.

It is, however, likely that sepsis may have been partly responsible for the conditions found in the last specimen (No. 4) described in the course of the present communication.

The question of so-called "late infection" has been brought into some prominence, by the recent communications of Wagenmann, Isakowitz, Axenfeld, Kuhnt, and others. In Wagenmann's case,[6] after a perfectly successful operation, there appeared a late infection of the anterior chamber through the site of the trephining. In Isakowitz's case,[7] symptoms of irido-cyclitis, with a small hypopyon, made their appearance forty-four days after an apparently successful Elliot operation. The result was in suspense when the case was reported. The condition was due to infection through the filtering cicatrix. The interval in Axenfeld's[8] patient was still longer, but then the condition followed a Lagrange and not an Elliot operation. The case reported by H. Kuhnt[9] was an instance of exogenous infection with pneumococci. The two eyes were trephined at an interval of a fortnight. Fifty-four days after the last operation, there was inflammation of the conjunctiva of both eyes, and twelve days after that, there was suppurative irido-cyclitis of one eye. The ultimate result of the case was bad. In Kuhnt's patient, as in the others, the filtering cicatrix had evidently become abraded, and allowed pneumococci, present in the inflamed conjunctival sac, to pass through the epithelium into the eye, with consequences touched upon above.

In Schur's patient[10] one eye was lost from late infection, the immediate cause of which was an injury. It was the sole instance met with by him

* Uhthoff (ref. in *Klin. Monatsbl. f. Augenheilk.*, August, 1913, S. 248), however, had an opportunity of examining after death an eye which had been trephined for inflammatory glaucoma. With the microscope, the trephine wound was found to be completely closed by pigmented cicatricial tissue.

among the trephinings in Schleich's Klinik at Tübingen. In both Harms'[11] and Storp's[12] cases the eyes were lost from late infection.

Elliot has found that, in a notable percentage of cases of trephining, a cicatrix results at some point along the line of junction between the flap and the other parts of the ocular conjunctiva. The bearing of this upon late infection need not be laboured.

2. Hæmorrhagic Failure.

Hæmorrhage from the choroidal or retinal vessels is a bogey in every operation in the course of which the eyeball is opened. Small retinal hæmorrhages are known to be common after any operation of a decompressive nature, whether it be iridectomy or otherwise. At the same time expulsive hæmorrhage, endangering the safety of the eye, is fortunately a rare accident, although an ever-present danger, especially in cases of glaucoma. Elliot (*loco citato*,[1] p. 81) after reviewing the cases in which it occurred during trephining, concludes that the risk of the accident is a small one, and this he attributes to several factors, as follows:—(a) the very slight pressure to which the eye is subjected during operation; (b) the small piece of the sclera removed; and (c) the minimal amount of interference with the contents of the eye once the trephining is accomplished.

It may, indeed, be argued that the small aperture made in the corneo-sclera is in itself a safeguard against intra-ocular hæmorrhage, and should such occur, is a factor in putting an end to the process. Blood, if poured out from the choroidal or retinal vessels in any notable amount, would push the vitreous and other structures forward, so as to block the trephine hole. Pressure would rise, with the consequence that the bleeding vessel would be, as it were, automatically compressed.

3. Mechanical Failure.

The specimens at my disposal show that failure may result from several mechanical causes, one of the most important of which is the filling up of the aperture made by the trephine with connective tissue. Associated with this obstruction, or even occurring in its absence, we find that the trephine hole may be occluded by (*a*) iris, (*b*) ciliary body, (*c*) capsule of lens, and (*d*) lens itself. The exact nature of the obstruction depends largely upon whether an iridectomy has or has not formed part of the operation. In the latter event, it is obvious that neither the lens nor its capsule could form the obstructing medium. On the contrary, when iridectomy has been done, there is no bar (other conditions being favourable) to the capsule of the lens becoming adherent to the wound in the corneo-sclera. This is usually brought about by sub-luxation of the lens itself. The possible causes of this unfortunate accident, four in number, are as follows:

(1) The inexpertness of the surgeon.

(2) Intra-ocular hæmorrhage pushing forwards the vitreous and with it the lens.

(3) Extreme laxity of the fibres of the suspensory ligament, allowing the lens to tilt and to move bodily towards the trephine hole (Elliot).

(4) Delayed formation of the anterior chamber, so that when iridectomy has formed part of the operation, the capsule of the lens becomes adherent to the lips of the wound by plastic exudation, and when the anterior chamber re-forms, the lens is pulled out of place by traction.

Attention has been directed by Paderstein[13] and Schur[14] respectively to another mechanical incident liable to occur after the performance of Elliot's

operation, namely, a temporary detachment of the choroid, such as sometimes follows iridectomy or the removal of cataract. This was encountered by Schur in three cases (3·5 per cent.) among 85 trephining operations. For purposes of comparison, it may be said that it was met with by Fuchs in 10 per cent. of the cases of glaucoma treated by iridectomy and by Meller in 22 per cent. of those treated by Lagrange's operation.

DESCRIPTION OF SPECIMENS.

Specimen No. 1.

Cause of failure.—Partial blocking of trephine hole (in which no attempts at repair are visible) by ciliary body and herniated and sub-luxated lens, an accident probably due, in part at least, to intra-ocular hæmorrhage.

Abstract of Case.—W. J., aged 80 years, first attended the Warneford, Leamington, and South Warwickshire General Hospital at Leamington on August 14th, 1912, under the care of Mr. T. Harrison Butler, whom I have to thank for permission to publish the notes of the case. According to the history, the patient's left eye became inflamed three years ago, and rapidly lost its sight. On examination, V.=no p.l., and T.+1. Ciliary redness. Cornea hazy. *Occlusio et exclusio pupillæ.* On October 19th, 1912, the eye was trephined, but owing to the long-continued inflammation, the cornea could not be "split," and so the trephine aperture was unavoidably placed wholly in the sclera. There were no complications. In particular, the trephine did not slip deeply into the eye, so as to be likely to wound the lens. Iridectomy was not performed. On December 5th, 1912, it was noted that the site of the trephine wound was ectatic, and that the hole itself was plugged with a dark substance. The eye was red and painful, and its tension was slightly raised. On January 9th, 1913, the eye was removed.

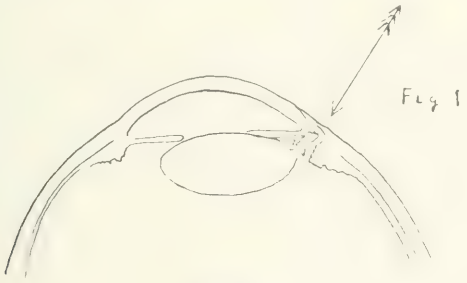

Fig. 1.

*Pathological appearances.** The lens is sub-luxated towards the trephine hole in the sclera, in which no attempt at repair is visible (fig. 1). The aperture in the sclera, remains patent, except externally, where it is ectatic and covered with epithelium and with œdematous and vascular conjunctiva (fig. 2.) It is lined with remains of the ciliary body. The aperture in the sclera is partially occupied by a hernia of a portion of the displaced lens. The capsule can be traced nearly round that part of the lens which has prolapsed into the wound. But at one point, lens substance lies between capsule and remains of ciliary body which lines the cavity, so that the capsular investment cannot be complete. The intact angle of the anterior chamber is widely open. There are deposits, including particles of pigment, on the back of the cornea. The

* The microscopical specimens were cut by Dr. T. Henderson, of Nottingham.

iris, which is atrophic, is adherent here and there to the capsule of the lens. The vessels of the iris, ciliary body, choroid, and retina are distended, and there is a considerable accumulation of blood in the vitreous chamber posterior to the fibres of the suspensory ligament. The conjunctiva and episclera in the vicinity of the trephine aperture are extremely vascular and markedly thickened.

Hyalin changes are present in the ciliary body and muscle, as well as in the iris.

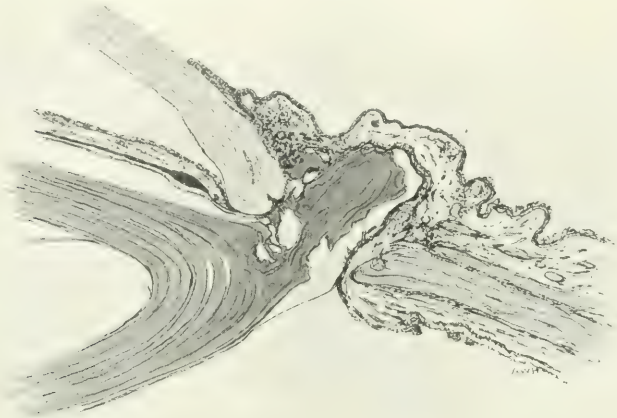

Fig. 2.

Specimen No. 2.

Cause of failure.—Blocking of the trephine aperture by connective tissue, and incarceration of the iris in the wound.

Abstract of case.—The specimen was obtained by the kindness of Colonel R. H. Elliot, I.M.S., from the left eye of a male Hindoo, Padmanabba Pillay by name, 35 years of age, who was admitted to the Government Ophthalmic Hospital at Madras on July 11th, 1911. The history of the case extended over 4½ years, during which period sight had steadily failed without pain. Before operation V.=O, and tension was 35mm. mercury. On July 13th, 1911, was trephined by Major Kirkpatrick, I.M.S., in order to prevent glaucomatous attacks. A 2mm. trephine was used, and iridectomy was performed. The disc of sclera was not cut out quite cleanly. A week after operation, V.=O, and tension was 6mm. of mercury. On February 14th, 1913, the cornea showed a K-shaped opacity, and the eye was in a state of phthisis bulbi. Tension was 35mm. of mercury. The globe, removed on March 5th, 1913, was placed in Bless's fluid, where it remained until April 16th, 1913, when it was transferred to 70 per cent. alcohol.

Pathological appearances.—The eyeball shows the usual signs of chronic glaucoma. The sclera is thicker than normal and puckered. The epithelium of the cornea is œdematous, and the substantia propria contains numerous blood-vessels. Iridectomy has formed part of the operation. Near the limbus there has been a penetrating wound, as shown by a tract of tissue in the corneo-sclera, which differs both in appearance and staining reactions from the tissue lying on either side of it (fig. 2). At the inner end of the aperture, Descemet's membrane is cut through, and the curled-up

ends of the membrane, together with the anterior surface of the iris, are adherent to the fibro-vascular connective tissue that occludes the trephine hole. A few particles of pigment, scattered through the lower third of the occluding plug, have apparently been derived from the adherent iris. Towards the centre of the cornea, Descemet's membrane is extensively detached from the substantia propria, and adhesions have been formed with the anterior surface of the iris.

The pupil is closed by a fine membrane, composed of young connective tissue, particles of pigment, and vessels. Descemet's membrane, which has proliferated in parts, is largely adherent to the anterior surface of the occluding membrane.

The posterior layer of the uvea of the iris has contracted adhesions to the anterior capsule of the lens (posterior synechia), and in this way a condition resembling *iris bombé* has been brought about.



Fig. 3.

The lens, the cortex of which is cataractous, is *in situ*. Lying for the most part immediately beneath the capsule, in the degenerated parts of the lens, are a number of small calcareous granules and masses, stained deeply with hæmatoxylin. No evidence of intra-ocular hæmorrhage. The choroid is degenerated, and, close to the optic papilla, are a couple of small calcareous plates. The retina is totally detached. The head of the optic nerve, instead of being "cupped," as one would expect, is somewhat protuberant and much cavitated. The nerve itself is atrophic.

Specimen No. 3.

Cause of failure.—Blocking of the trephine holes, of which the eye contains two. Sub-luxation of the lens, and impaction of the capsule in one of the trephine wounds. The other trephine wound is occluded by adherent iris, as well as by connective tissue.

Abstract of case.—N. Radhakrishnâ Doss, 63 years, was admitted to the Government Ophthalmic Hospital, Madras, under the care of Colonel R. H. Elliot, I.M.S., on September 21st, 1912. The left eye was blind and painful, and had been so for a couple of months; in fact, since some "drops" had been put into the eye elsewhere. The tension of the eye, as ascertained by the Schiötz tonometer, was 70mm. of mercury. The tension of the systemic arteries was 164mm. of mercury. With a view to relieve pain, the eye was trephined above on September 26th, 1912, by Captain Hingston, I.M.S. Iridectomy formed part of the operation, which was uncomplicated. On the following day, tension was 21mm. of mercury, the chamber was re-formed, the

pupil was central, but it was found that the flap had been button-holed. On December 12th, 1912, V. was O, and tension was 55mm. of mercury (Schiötz). On this date the eye was again trephined, this time by Captain Gray, I.M.S. A 2mm. trephine was employed, operation was done below, and the [illegible] disc, left hinged on the nasal side, was cut out, with a piece of iris. But the eye remained painful, the filtration was not marked, and on March 6th, 1913, the tension stood at 45mm. of mercury. The eye was accordingly enucleated upon April 16th, 1913, and was placed in Müller's fluid, which was frequently changed.

Pathological appearances.—The lens in its capsule is sub-luxated, and adherent to the inner end of a trephine wound in the corneo-sclera (fig. 4). Iridectomy has been performed. The adherent part of the capsule is thrown into folds, presumably by the traction of the newly-formed connective tissue to which it is adherent. The wound in the corneo-sclera is completely

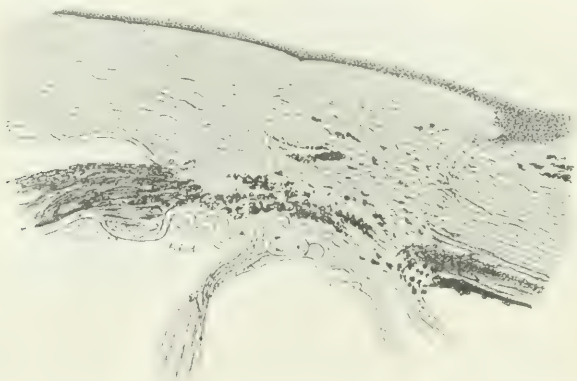

Fig. 4.

filled with vascular fibro-nuclear tissue, which contains numerous particles of pigment, evidently derived from the iris. The tissue filling the trephine wound can be distinguished from cornea, on the one hand, and from sclera, on the other, by its containing numerous particles of pigment, to say nothing of many more nuclei, as well as by the interlacing and irregularity of its component fibres. The ends of Descemet's membrane, which are separated by a gap as wide as the trephine wound, are incurled and incorporated in the new fibro-nuclear tissue.

The second trephine wound is also filled with vascular pigmented fibro-cellular tissue, to the hinder surface of which both ends of the cut iris (iridectomy has been done) are adherent.

Furthermore, there has been a penetrating wound towards the centre of the cornea, to the posterior end of which the pupillary edge of the iris has become attached. This wound has been repaired in the usual way. A clump of pigment lying towards the centre of the substitute fibrous tissue probably represents migration from the entangled iris.

Suitable sections show a fine membrane more or less bridging over the pupil. Some lymphocytic exudation is present in the anterior chamber and elsewhere. Posterior synechiæ are also present.

Traces of blood are to be seen in the anterior chamber, in the meshes of the suspensory ligament, in the vitreous, and about the optic disc, which is deeply "cupped" in a pathological sense.

The retina and the choroid are in relatively good condition. However, the former contains "Blessig's cysts" towards its periphery, and the latter, a few "Drusen" here and there.

Specimen No. 4.

Cause of failure.—Irido-cyclitis possibly connected with the scleral disc left in the anterior chamber at the time of operation. Sub-luxation of lens, and adhesion of the latter to wound in the capsule of the eye, itself occluded by new-formed fibrous tissue.

Abstract of case.—H. Y. S., aged 61 years, who had been affected with glaucoma of the right eye for many years, was trephined on March 21st, 1910. V. was then about 6/18, and the field of vision showed characteristic changes. As soon as the corneo-sclera was drilled, the iris bulged and was excised, and the resulting iridectomy was found to involve the pupillary margin of the iris. The trephined disc slipped into the anterior chamber, where it was left. The flap was secured by a single suture. On the following day (March 22nd), the anterior chamber was re-formed, and on the next day (March 23rd) the parts over the trephine hole were distended with fluid. Five days later (March 28th), the eye, however, had become deeply congested, tension was raised, and intermittent pain was complained of. On March 31st (ten days after operation) the eye was markedly reddened, and V.=fingers near face. No fundus reflex could be elicited. By focal illumination, the trephine hole could be recognised beneath the swollen and reddened ocular conjunctiva as a darker marking. Lying in the upper part of the iridectomy coloboma was a circular more or less frayed-out looking body, of a greyish-white colour, believed to be the trephined disc left in the anterior chamber at the time of the operation. On April 1st (eleven days after trephining) the suture was taken out of the flap, but after the anterior chamber had been opened with a keratome, the bit of sclera did not escape with the wash of the aqueous humour, as it was hoped it might do. No attempt was made to drag it out. It was noted that the tension of the eye was not lowered by the paracentesis, and, further, that a layer of greyish-white exudation lay along the nasal edge of the surgical coloboma. Next day (April 2nd), there had been no pain, but tension was *plus* two. On April 4th tension was normal, and the patient was practically free from pain. On April 11th the appearances were those of a severe irido-cyclitis, *viz.*, deep congestion of the eyeball, discoloured iris, and plastic exudation along the inner side of the coloboma and on the capsule of the lens. Tension was somewhat below normal. "Neuralgic" pain was complained of. The trephined disc was plainly visible in the upper part of the surgical coloboma, where it was undergoing changes. On April 23rd (33 days after trephining) there had been no pain worth mentioning, and the redness of the globe was receding. Tension was normal. Most of the iridectomy coloboma was now occupied by a soft-looking conical body, which represented the trephined disc, and which looked as if it were attached somewhere in the region of the original wound. What little remained of the pupil, which is much smaller than it was, in consequence of the irido-cyclitis, was occupied by greyish-white effusion. On May 2nd (42 days after trephining) the globe was still somewhat red, the pupil was blocked by exudation, the tension was slightly lower than normal, and the projection of light was fair. A few days later, intra-ocular tension rose, and on May 9th (49 days after trephining) it was *plus* two, the pupil was blocked by exudation, and a greyish ectasia lay over the sight of the trephining. On May 14th (54 days after trephining) tension was *plus* two, the iris was *bombé*, V.=perception of light, and a protrusion was present over the site where the corneo-sclera had been trephined.

On June 3rd (74 days after trephining), under the influence of gas and chloroform, the eye was removed.

Pathological appearances.—The lens, which shows degenerative changes, as vacuoles and Morgagnian bodies, is sub-luxated, and united by plastic material to the inner end of the trephine aperture in the corneo-sclera. The trephine wound appears to be impermeably sealed with fibro-cellular tissue, containing a certain number of pigment granules, evidently derived from the iris (fig. 5). Some of the sections show that the capsule of the

Fig. 5.

lens is ruptured in the neighbourhood of the trephine wound. An iridectomy has been performed, and part of the iris has become adherent to the anterior capsule of the lens (posterior synechiæ). The iris is atrophic, and much of it is in contact, if not actually united, with the posterior surface of the cornea. No keratitis punctata. *Iris bombé.* Extending from the edge of the iris below to contract an adhesion with the posterior aspect of the cornea above, is a membrane, composed of a fibro-cellular tissue, vessels, and pigment.

The episclera is thicker and more vascular than usual.

"Blessig's cysts" well-marked in the peripheral parts of the retina. No evidence of intra-ocular hæmorrhage. Deep glaucomatous "cupping" of the optic disc.

Remarks.

In successful cases, the continued permeability of the track in the corneo-sclera is inferred from the existence of a so-called "filtering cicatrix," *in which the aperture made with the trephine may often be recognised*, as well as from the fact that the tension of the eye remains normal or sub-normal. Indeed, there seem to be sound reasons why, under ordinary circumstances, the track should remain patent. In truth, the conditions are peculiar. To begin with, the wound is, or should be, clean-cut. Then, its posterior aperture is constantly bathed by the bland and non-irritating aqueous humour, which would probably be as inimical to union as in the case of the cut iris (Fuchs, T. Henderson). Finally, external irritants, bacterial or epithelial, would be largely prevented from entering the anterior chamber by the conjunctivo-corneal flap that seals the outer aperture of the wound. Elliot[3] believes that blocking of the trephine hole is by no

means a common occurrence, even in long-standing chronic or sub-acute congestive types of glaucoma.

In all but one of the specimens described in the present communication, the trephine track was found to be occluded by vascular fibro-nuclear tissue, disseminated through which were particles of pigment derived from the iris. In one specimen alone (No. 1) was the trephine hole found to be patent, and there its closure was rendered impossible owing to the interposition of part of the ciliary body and lens.

The trephine wound, when it heals, heals just like any other penetrating wound of the cornea, except that as the investing epithelium has never been destroyed, there is no necessity that it should be reproduced by karyokinesis from the neighbouring epithelium. It is not always an easy matter at first glance to distinguish the new fibrous tissue from the adjacent cornea or sclera, unless the tissue includes particles of pigment (which it usually does), when its recognition is rendered altogether simple. Kümmell,[3] whose experimental work has already been referred to, noted the same lack of contrast in the cornea of rabbits.

It is of some little importance to note the fact that the severed ends of Descemet's membrane were usually separated by a gap as wide as the original wound, or not far short of the latter, thereby showing that the membrane had been cut through by the trephine or other instrument employed during the operation (fig. 4). Even when the ends had become entangled in the new tissue filling the wound in the cornea, and were presumably pulled out of position by that material, the interval between them was of fair size (fig. 3).

Many of the sections showed plainly the flap resulting from "splitting" the cornea after Elliot. It was found to include some of the more superficial fibres of the substantia propria of the cornea, often a good deal changed in appearance.

Much as the trephine wound in healing follows the ordinary laws that govern the cicatrisation of penetrating injuries of the cornea, so the remaining complications of Elliot's operation are by no means peculiar to that procedure. All are known on occasion to have followed the performance of iridectomy or the removal of cataract. One of the most striking of these complications is subluxation of the lens, found in three of the four specimens described in the present communication. In Specimen No. 1 the appearances suggested that intra-ocular hæmorrhage had been the cause of the displacement. Although nearly three months had elapsed between trephining and enucleation, yet the vitreous chamber still contained a good deal of blood. In Specimen No. 4 the plastic irido-cyclitis present (both clinically and pathologically) might be responsible for displacing the lens, and a similar explanation may possibly be true of Specimen No. 3. If the unfortunate accident results, as supposed by Elliot, from laxity of the fibres of the suspensory ligament, the results in the shape of impeded filtration should be immediately visible; but if, on the contrary, it is the result of traction exerted by the products of irido-cyclitis, then it would appear much later in the history of the case.

Most of the remaining complications are due to the incarceration of this or that structure in the wound. The present series affords examples of the entanglement of (a) iris, (b) ciliary body, (c) lens, and (d) capsule of lens. It is to be noted that in every case where this took place, the trephine track had become obliterated by pigmented connective tissue.

As regards Specimen No. 4, the case was a peculiar one. The trephined disc escaped into the anterior chamber during the operation, and no immediate attempt was made to remove it. I argued, as Elliot[1] had done

before me, that no harm would accrue from leaving it in place. He mentions cases where the disc was left without any signs of inflammatory reaction following. The incident therefore caused no particular solicitude in my mind until the fifth day after the operation, when pain was experienced, tension was raised, and the eye was deeply congested. The escaped disc could be plainly seen in the eye. At a later period, the disc was undergoing disintegration, but symptoms were worse. An attempt to remove the disc, by simply opening the anterior chamber and allowing the aqueous to escape, failed. The eye did badly, and was finally enucleated, as it was thought it might threaten danger to the remaining eye. When examined with the microscope, the eye showed definite signs of severe irido-cyclitis. Moreover, the trephine track was occluded by new-formed tissue, to which the umbo of the sub-luxated lens was adherent.

Speaking of irido-cyclitis, it is noteworthy that three of the specimens, including the one just mentioned, showed with the microscope such definite signs of the disorder as posterior synechiæ, occlusion of the pupil, *iris bombé*, deposits on the cornea, and lymphocytic exudation into the anterior chamber and elsewhere.

REFERENCES.

1. **Elliot, R. H.**—"Sclero-Corneal Trephining in the Operative Treatment of Glaucoma." London, 1913, Pulman and Sons, 24-27, Thayer Street, W.
2. **Wallis, G. F. C.**—The Ophthalmoscope, October, 1913.
3. **Elliot, R. H.**—The Ophthalmoscope, October, 1913.
4. **Rochon-Duvigneaud and Ducamp.**—*Bull. de la Société d'Ophtal. de Paris*, juin, 1913.
5. **Kümmell.**—*Zeitschrift für Augenheilkunde*, Juli, 1913, S. 60.
6. **Wagenmann.**—*Zeitschrift für Augenheilkunde*, Juli, 1913, S. 61.
7. **Isakowitz.**—*Klin. Monatsbl. für Augenheilkunde*, Juni, 1913.
8. **Axenfeld.**—*Klin. Monatsbl. für Augenheilkunde*, Juni, 1913.
9. **Kuhnt.**—*Zeitschrift für Augenheilkunde*, August-September, 1913.
10. **Schur.**—*Klin. Monatsbl. für Augenheilkunde*, September, 1913, S. 377.
11. **Harms.**—*Klin. Monatsbl. für Augenheilkunde*, September, 1913, S. 380.
12. **Story.**—*Inter. Med. Congress*, London, 1913.
13. **Paderstein.**—*Berl. Ophthal. Gesellschaft*, 1913.
14. **Schur.**—*Klin. Monatsbl. für Augenheilkunde*, September, 1913, S. 372.

SOME COMMONPLACES WITH REGARD TO PLASTIC OPERATIONS.*

BY

N. C. Ridley, F.R.C.S.

LEICESTER, ENGLAND.

My object in making plastic operations the subject of this short paper was more with the idea of starting a topic for discussion afterwards among the members of the Congress, and thereby acquiring some information and knowledge myself, rather than that of imparting any special information.

These operations, necessitated by accident or by disease, are constantly cropping up in the practices of everyone of us, and the line of conduct has to be plotted and carried out according to the need of the case, very often at short notice; and one may say that it is only on the rarest occasions that any of the standard operations of the text-books will fulfil the requirements. Conditions, too, have changed since most of those standard operations were planned. The advent of local anæsthesia, and, far more important, antiseptic

* An address delivered on July 18th, 1913, before the Oxford Ophthalmological Congress.

methods, have given us a freer hand. For instance, it is not now necessary to fix the part from which a portion of tissue is to be transplanted to the neighbourhood of its new abode without completely separating that tissue, in the way John Hunter did in his experiments.

Granted that I am dealing only with plastic operations connected with ophthalmic surgery, I would define them as operations performed with the object of restoring function to damaged or destroyed parts, or with the idea of mitigating disfigurement. One may also include in the category such operations as are employed as a temporary measure with the object of curing disease, such as artificial ankyloblepharon in bad corneal ulceration, in the proptosis of Graves' disease, arterio-venous aneurism of the orbit, and so on.

In our limited branch of surgery, most of these operations are performed on the eyelids and skin in the neighbourhood, on the conjunctiva, and the orbital walls.

I have had a knife made for me by Messrs. Weiss and Son, Limited, which I have used for many years for plastic operations, and which I will pass round (*see* figure). Its chief advantages are :—

It has the convenient size of a small scalpel.

It resembles a scalpel, too, in having a good belly for dissecting and making skin deep incisions.

It has a straight back, so that one can tell the direction of the point even when it is hidden.

It has a double-edged point and a thin blade for convenience in transfixion and for such manipulations as splitting an eyelid or freeing the skin from the subcutaneous tissue, to enable it to be drawn across a gap.

It has the handle of an ophthalmic instrument, which is what we are most accustomed to use.

The general principles to be observed in all operations of this kind are, first, asepsis, which should be rigidly carried out, as our object is to get primary union, as when healing occurs by granulation, it is necessarily followed by contraction and consequent distortion of the neighbouring parts ; secondly, good apposition and immobility, enabling new vessels to grow into a graft more readily.

If the above postulates are strictly observed, sloughing seldom takes place, for the splendid vascularity of the skin of the face gives far better chances of success than are obtained in any other part of the body, and necrosis from innutrition, pure and simple, practically never occurs. It is sepsis which causes the trouble, by producing severe inflammation and consequent blocking of vessels.

While speaking of nutrition, I might mention that a theory I have formed, for there is none stated in the text-books, why temporary ankyloblepharon is useful in certain bad corneal ulcers, and more especially in the threatened necrosis in the severe proptosis of Graves' disease, is that, as we know, the nutrition of the cornea is carried out by lymph conveyed through the channels and spaces of the substantia propria from the vessels of the circumcorneal zone. This lymph must have some force to propel it along and to distribute it, and its otherwise sluggish current is, to my mind, greatly assisted by the continuous massage produced by the movements of the lids over the cornea. The band-shaped degeneration of the cornea, pointed out by Treacher Collins, as occurring in old people where the movements of the lids are less powerful,

helps to support this theory. I think, too, that the corneal sloughing in bad proptosis and lagophthalmos is due to this want of massage more than to exposure and dryness.

Repair of a torn eyelid is an operation for the performance of which no invariable rules can be laid down. When the tear is incomplete, and done with a blunt instrument, it is generally found to begin at the inner extremity of the lid and pass through the canaliculus. When union has taken place, a little epiphora generally follows for a time. This, however, is seldom troublesome, but should it prove so, it is not difficult to cut down upon and to open up the blocked canaliculus, or, at all events, to make a permanent groove running into the lacrymal sac.

These cases generally come into the hands of the house surgeon, who recognising that they require early attention, operates at once. He is mostly careful enough to suture the conjunctival surface as well as the cutaneous, but is apt to forget, when it is a case of the upper lid, that there are important structures contained in it that may need uniting, and that if not found at first, they probably never will be. I have a case illustrating this, where I was quite unable at a later date to find any sign of the levator palpebræ superioris. I did a Hess's operation, but as Müller's muscle as well as the levator was destroyed, the lid when raised by the occipito-frontalis, is pulled away from the globe and considerable disfigurement results. Simple suture of the lower lid, on the other hand, gives usually a perfect result.

If the part be completely torn off, it should be replaced. If part of the lid be missing, the ragged remains must be carefully brought together, and, if necessary, a skin graft added. The following case illustrates the point.—On one occasion, when the chief part of the lid was left on some barbed wire fifteen miles away, I had a young pig killed and immediately removed its upper lid and spliced it into the remains. This graft lived long enough for new tissue to grow into it before it shrivelled away, and quite a useful lid resulted.

A notch, as from a tear or cut in the middle of the lid, may be much improved by making a linear transfixion parallel with the lid margin and bringing the extremities together with a suture, as is sometimes done in slight cases of hare lip. Of course, this does not remedy the noticeable absence of eyelashes. If that be a matter of consequence, the overlapping operation described in Meller's book, which is very simple, can be performed.

I now come to **plastic operations on sockets**.—When the trouble is only a band or two produced by wearing a rough prothesis, a V—Y operation in one or two places, freely dividing the scar, and undermining the neighbouring conjunctiva, will usually give good results, just as one does in operating for symblepharon, but if much conjunctiva be lost, I fear very little can be done. I have tried all kinds of skin grafting, after making a large cavity, many times, but have never succeeded in getting the grafts to grow, in spite of attempts to preserve apposition by specially-made glass obturators. Neither have I ever seen a successful case by any other surgeon.

If any member of the Congress can tell me a useful method of procedure in such cases, I shall be deeply grateful, as it makes a considerable difference to some people if they can wear a decent-looking artificial eye instead of a shade.

On the other hand, in those apparently more severe cases, where the whole of the contents of the orbit have had to be removed for recurrent malignant disease, the results are far better. Frequently, in such cases the skin of the lids is free from disease, and may be dissected back from just beyond the line of the cilia. When the orbit has been thoroughly cleared, these flaps may be tucked in and kept in position by the dressing. Being very easily stretched,

as granulation proceeds beyond their margin, they gradually get drawn further and further until their margins unite and the whole cavity is lined.

If required, an artificial eye and lids can be worn in such a cavity behind spectacles. A cleared-out frontal sinus may be lined in a similar way, and if the overhanging bony edges be cut freely away, it is surprising how little disfigurement results.

The chief thing, however, I wish to bring before your notice, is the method of repairing **severe contractions of the skin of the face**, more especially of the eyelids, by means of grafts of the whole thickness of skin taken from other parts.

When I first performed this operation, now some sixteen or seventeen years ago, the method had fallen into disrepute, owing to the frequency with which the grafts sloughed, and so the patient was put to the inconvenience of a somewhat severe operation all to no purpose.

If the whole thickness of the skin can be got to grow, it is manifestly better to use it than small strips and thin layers, as it of itself supplies more fully the place of lost or destroyed tissue, and so the original shape of the part is more fully restored. It sounds more probable, too, that with fair treatment, a graft containing the whole of the active growing cells of the corium should live, rather than one where only those cells contained in the apices of the cut-off papillæ are transferred.

There are several details that should be carried out in order to have a fair chance of success. *First*, the part to be operated upon, and the part from which the graft is to be taken, must be carefully washed and made aseptic. I generally take the graft from the flexor surface of the upper arm, or the inner surface of the thigh of the patient, since the skin there is particularly soft and free from hair. *Second*, a general anæsthetic is necessary, as removing the skin is very painful, and hypodermic injection of any drug, at either site, depresses the vitality temporarily, and militates against ultimate success. *Third*, the part to be restored is freely divided, and a framework or skeleton of the new part made from what is left, simply leaving, as it were, a large gap in the surface. *Fourth*, a piece of skin, one-third larger in each direction than is required to fill the opening accurately, is dissected off the arm or thigh of the patient, care being taken not to remove any fat or superficial fascia with it. It is worthy of notice how much smaller the graft is after removal than the patch marked out. Care must be taken not to damage the graft by holding it with forceps and crushing it. The fingers should be used instead as soon as it is possible After removal, the graft is washed in warm boric lotion, and all blood carefully cleared away, both from it and from its new site. *Fifth*, the graft is attached in its new position by as few sutures as possible. It must not be stretched, but must lie without any tension on it, and, indeed, rather overfill the gap. *Sixth*, firm pressure must be applied over the graft to keep all parts of its under surface in apposition with the site, so as to avoid "pocketing." *Seventh*, the dressing must not be removed for forty-eight hours, and then most carefully, to avoid breaking-down the first lymph adhesions.

It is generally impossible to make a nice-looking job at the time of the operation; indeed, if it be neat-looking, then you may be tolerably sure that you have not put in enough tissue. It is wonderful how Nature smooths down and fits it afterwards, and does all the fine adjustment, so to speak.

When a large piece of soft fresh skin is required, one naturally thinks of the material that can be obtained in the operation of circumcision. I have used the prepuce on several occasions, having had the two operations conducted simultaneously. The results, however, have not been to be compared with those performed as I have stated above, and I think the reason is, that it

is very difficult to get the skin only of the prepuce without the underlying fascia, and in cleansing it, time spent and hard usage exercise their bad influences on the graft.

The raw place on the arm or thigh generally heals in two or three days, if the edges be drawn together by a couple of deep and a few superficial sutures.

After removing a rodent ulcer, I generally allow the part to heal by granulation if at all extensive, and then do a plastic operation later, when it is more easy to see if the part left be healthy, and what is required to restore the original shape.*

THE PATHOGENESIS OF SYMPATHETIC OPHTHALMITIS.†

BY

DR. FRANZ DEUTSCHMANN,

HAMBURG, GERMANY.

ALTHOUGH the researches on sympathetic ophthalmia during the past years have been numerous, and a vast amount of work and keen observation have been applied in this domain, I am as yet unable to give a generally recognised definition of this disease. Of most importance is the fact that the disease of one eye is dependent upon a chronic uveitis of the other. To this point we must adhere, and from it we may draw the conclusion that the diagnosis is especially a clinical one. Usually, the patient's first affected eye presents a perforation of the globe of traumatic origin, or has passed through an operation, followed by a chronic inflammation of the deeper parts of the eye. After an indefinite time—usually from four to eight weeks—although intervals as short as ten days, and as long as thirty years, have been recorded —the second, sympathising, eye suddenly becomes affected, without any signs of the existence of a general disease.

We mostly start with a disease of the uvea, which affects at first only the anterior parts of the eye as an iridocyclitis, with deposits on Descemet's membrane, and later spreads to the choroid. Less frequently, it begins in the choroid as little isolated yellowish spots. These may disappear completely if the inflammation does not make any progress and the ciliary body and iris remain unaffected.

Another form exists, known as sympathetic papillo-retinitis. The ophthalmoscopic picture of this presents a moderately severe papillitis, which is not very conspicuous, and is surrounded by slight retinal opacity. It has the peculiarity that immediately after enucleation of the first eye, the process gradually recedes without further treatment, and without leaving any permanent injury to the optic nerve. Very rarely does a partial atrophy occur: a total atrophy has never been observed.

This degeneration may appear primarily without ophthalmoscopically visible inflammatory changes, and may be considered as a sequence of a retrobulbar neuritis, which may be diagnosed in advance in some cases by increase in the size of the blind spot.

Sympathetic ophthalmia is usually a severe disease, is always of doubtful prognosis, and therapeutically no specific remedy is known to stay the progress, after the onset of the attack, the treatment being limited chiefly to inunction of grey ointment, large doses of salicylates, iodides, and warm applications.

*This communication was illustrated by the presentation of several patients.

†Read at the Oxford Ophthalmological Congress on July 18th, 1913.

Prophylaxis alone proclaims here its triumphs, since we are certain to save the second eye, if after a lapse of four weeks following the enucleation of the eye suspected to be dangerous, we still find the other one unaffected.

The microscopic findings are not nearly in all cases sufficient to base upon them alone a correct diagnosis. Weaker inflammations, exclusive of those that have recovered, are scarcely available for microscopic work, since only the seriously injured eyes are enucleated, and even then we must make allowance for a mixed infection, as well as for the lesion caused by the trauma itself. The sympathising eye alone offers an absolutely true picture, and this has been examined in fifteen cases only.

Briefly summed up, the following may be said.—The point of interest is an infiltration of the uvea, which may arise in its different parts as an isolated affection, or may involve the entire uvea, and consists chiefly of plasma cells, besides lymphocytes, mast cells, and eosinophils-leucocytes—which are chiefly found in the layer of the larger vessels. The onset is usually in discrete foci, but confluent foci may appear early. The denser the cell aggregations, the thicker the choroid becomes ; the choriocapillaris remains for a long time uninvolved, and rupture of the hyaloid membrane is very infrequent. The iris and ciliary body are involved much more quickly in this infiltration process, the cells which appear on their posterior surfaces uniting into a kind of granulation tissue, which may ultimately become indurated. The sympathizing inflammation in this stage cannot be distinguished from a chronic post-traumatic inflammation, since it presents at times pneumococci, staphylococci, and streptococci, as is shown by the researches of Gilbert.

Notwithstanding, it may already in this early stage become the cause of the disease of the second eye, which has lately been observed several times.

Following the further progress of this sympathetic infiltration, there appears the development of epithelioid and giant cells in all structures of the diseased eye. This is the most frequent finding in the sympathizing eye when sympathetic ophthalmia already exists. It has been pointed out that the picture presented reminds one decidedly of tuberculosis, but the microscopic diagnosis in this advanced stage of the sympathising inflammation may be made with considerable certainty when it is known that the eye in question has become diseased in connection with perforation of the globe. The appearance of this second stage, which Fuchs[2] declares "typical," is probably due not only to lapse of a definite period of time, but also to a certain virulence of the exciting agent. In the numerous cases of eyes enucleated on prophylactic grounds, where the other eye had not yet become involved, the "typical" findings of Fuchs have been confirmed only three times, but it is impossible to assume that only those three eyes were sympathetic, and thus justifiably enucleated. According to my views, the development from a simple fibrous, plastic inflammation of the "typical finding" occurs simultaneously with the migration of certain germs through the optic sheaths to the second eye, and is, as a rule, completed when the second eye has been reached by the microbes. At times, even after seizure of the second eye by sympathetic ophthalmia, we may find the early stage still existing, which may be accounted for by an exceedingly rapid migration. The opposite—that is, "typical finding" without sympathetic ophthalmia—forces us to the assumption that the migration here met with effectual obstacles.

The question now arises, why, in so many prophylactically enucleated eyes in which the "typical finding" was absent, an involvement of the second eye did not follow. Is it probable that all the bacteria were removed with the eyeball? Under no circumstances do I believe this. The salutary effect of the enucleation does not depend alone upon the removal of the diseased parts

of the eye, together with the microorganisms existing in it. The opening of the lymph channels of the eyeball and the orbit causes an accelerated flow away from the brain. It would indeed seem plausible, that in consequence of this vigorous lymph drainage, just as in the sudden opening of the anterior chamber, serum products and bactericidal substances would pass from the vessels into this fluid. Thus, the bacteria which had already entered the channels of the optic nerve would, because of the enucleation, not only be carried away by the lymph stream, but would also be attacked *in situ*.

With the exception of a few cases of sympathetic ophthalmia following sarcoma of the choroid, there has always been a penetration of the first eyeball. To this category belong, also, subconjunctival ruptures of the globe. We always find in the sympathising eye a chronic uveitis, which must be classed with the infective granulomata. Once the onset of the inflammation has begun in the second eye, it will continue its own course regardless of, and uninfluenced by, the severity of the process in the first eye, or by its enucleation. During the course of sympathetic ophthalmia, relapses frequently occur. All these signs force upon us the assumption that a microbic, and perhaps a specific, cause is responsible. But such has not yet been demonstrated, either by staining or by culture.

I desire now to give a brief report of my own work on this subject, which was originally published in v. Graefe's *Archiv für Ophthalmologie*, Bd. 78, 79, and 81.

I have succeeded in producing genuine sympathetic ophthalmia, both in monkeys and in rabbits, by infecting them with particles of the uveal structure taken from sympathetic human eyes. Other animals were inoculated with particles taken from the first and second eye, as well as from the optic nerves of these diseased animals, with positive results. Of nineteen animals experimented on, two became generally diseased, so that these may be excluded from consideration. Of the remaining seventeen, the inflammatory changes were in only two cases confined to the inoculated eye. In thirteen cases the optic nerve of the first eye in connection with the meninges was involved; in ten the optic nerve of the first eye, the meninges, and the nerve of the second; and in eight both nerves and the second eye, the meninges being also involved in seven of the latter. The inoculated eyes of the animals reacted with varying degrees of severity, some with a mild and others with a severe iritis; some with uveitis, while one developed into phthisis bulbi. The disease of the second eye was not always confirmed with the ophthalmoscope, but was discovered in some cases only by the anatomical examination. The intervals were 134, 78, 45, 17, and 27 days. The animals presented at no time general symptoms, and upon *post-mortem* examination, the blood in the heart was found to be sterile. (Two animals which gave a positive blood test are not included here.)

The microscopic findings were the same in the exciting and sympathising eyes. They consisted of infiltration of the uvea with plasma cells, usually arranged in circumscribed foci, at times more marked in the iris, again in the ciliary body, and at other times in the choroid. Occasionally, epithelioid cells were discovered.

In a number of animals I discovered extra-bulbar granulations of considerable size in the subconjunctival and orbital tissues. In the centre of these foci were found numerous epithelioid cells.

These inflammatory changes in the orbit were often in direct connection with those of the uvea and accompanied the ciliary vessels, either without interruption from the muscles into the eye or only in shorter ways. At the back part they continued sometimes in the optic sheaths, sometimes the foci of the choroid in the circumference of the optic head, passed directly into its sheaths.

The changes in the sheaths of the optic nerves presented no specific appearances; besides the endothelial proliferations, there existed agglutinations and adhesions of the intervaginal spaces in older cases and in earlier exudates of mononuclear cells, and in two cases giant cells were found.

In fourteen cases I was able to find a leptomeningitis. The site of the lesion varied; sometimes the base and sometimes the convexity of the brain was affected; at all times I found parts of the meninges unaffected, which proves that the invasion originated in circumscribed areas and foci. The process itself was in the different cases more or less intensely marked, and expressed itself by endothelial proliferation in the arachnoid, infiltration of round and plasma cells, which at times caused an exudate into the subarachnoidal space, new vascular formation with tendency to ecchymosis beneath the arachnoid, and in one case polynuclear leucocytes and giant cells. It would seem, then, that generally speaking, it takes the form of a chronic, circumscribed meningitis.

In each of the eight animals in which the second eye also became diseased, the inflammation passed from the first eye through the optic nerve by way of the optic chiasm into the second eye. The passing of the inflammatory process from the eye into the optic nerve, and *vice versâ*, presented two separate types: either direct from the choroid into the intervaginal space, or through the anterior ciliary vessels, out of the globe, around it, through the musculature, and behind the eye into the optic sheaths. In some instances both types of transmission were observed.

These findings agree, as far as reported hitherto, exactly with those of men. The inflammatory changes in the eyes of my experimental animals, as with the patients, took the form of chronic uveitis, which sometimes was not healed even after eight months. Extrabulbar granulations in the orbit have been described in sympathetic ophthalmia, not only by me, but also by Schirmer[3], Ruge[4], Blaschek[5], and others. Anatomical findings of the meninges of those patients unfortunately do not yet exist. But there is a series of clinical observations, which, in some cases, justified the diagnosis of meningitis. Thus, fever was observed by Pflüger[6], Blaschek[5], and de Wecker[7]; delirium or epileptiform fits by Snellen[8], Blaschek[5], Galezowski, and myself; and zur Nedden[10] must admit that a slight meningitis existed in his case, the origin of which he declared to be metastatic.

As regards the progress of the inflammatory process from the optic sheaths to the meninges, the cases speak very differently in which, during the course of the sympathetic ophthalmia, deafness has occurred without inflammatory changes of the outer or middle ear, and in which sometimes an inflammation of the auditory nerve within the capsule of the skull may be assumed. Such cases have been reported by Snellen[8], de Wecker[7], Rogmann[11], and Blaschek[5]; Only in the patients of the last-named was the difficulty of hearing, which bordered upon deafness, a transitory thing lasting but two weeks; in all the others it was permanent and bilateral, appearing in both ears, sometimes one after the other, sometimes simultaneously.

Altogether, I have microscopically examined twelve sympathetic eyeballs, with more or less typical results. In these I found five times a few Gram-positive diplococci in the inflamed uvea, and at times also in the optic sheaths. The microscopic demonstration of bacteria in the sympathetic eyes, which, however, does not exclude the possibility of mixed infection, must not be appraised too highly. It is, however, worthy of notice that in my positive cases *diplococci* were *constantly* found, which if stained according to Gram's method, did not decolourize. Their appearance was extremely rare, and mostly in those cases, in which the inflammatory processes were fresher, I have never discovered anything in the neighbourhood of epithelioid or giant cells. They are nearly

always isolated, and on that account can be easily overlooked. I have often had to look through preparations five times before I obtained a successful result, yet as I could see from the preparation of serial sections, in positive cases there must have been specimens in every section.

The shape of the isolated diplococcus, surrounded by a light halo, rendered uncommonly easy the recognition of the granules of the mast-cells. Far more disturbing were the scattered pigment grains among them. In such cases Gram-preparations, with subsequent colouring with alum-carmine, gave the best pictures. This rare appearance assured to them a certain pathogenicity, since avirulent bacteria are quickly removed by the natural protective powers of the organism.

Very much more important as proof are the results of my experiments upon animals. Nearly everywhere in inflammatory changes in the first eye one can find Gram-positive diplococci in the diseased optic sheaths and the meninges ; and, indeed, at times in the second eye also. Here it is not a case of mixed infection, because transference to the optic sheaths and the production of circumscribed chronic thickening of the meninges belong to the specific properties of the hypothetical exciter of sympathetic ophthalmia. Of the four cases of sympathetic ophthalmia which have been reported to date, in which both optic nerves were examined, I have in my possession specimens from the patients of R. Deutschmann[12] and Grunert[15]. In each case diplococci were discovered both in the optic sheaths and in the second eye.

In Volume 81 of von Graefe's *Archiv*, W. Poellot reports, from the University Eye Clinic of Heidelberg, a case of sympathetic ophthalmia with the anatomical findings of both eyes. Each time he concludes the report with the words "micro-organisms were not found in the eyeball." Upon my request, he most courteously sent me Gram-preparations made by himself. I found in both eyes, as well as in the arachnoidal growths, beautiful specimens of Gram-positive diplococci. After returning the preparations, with detailed drawings of the bacterial findings, I received the following reply from Herr Poellot :—"I also now believe that a part (in some places I was doubtful, the other part however appears to me certain) of these dark double spots are Gram-positive cocci—diplococci. In the first left sympathetic eye they are the more variable cocci—formed diplococci—in the sympathetic right eye they are the more peculiar Gram-positive diplococci in one infiltration group of the choroid, and in the arachnoidal growths of the intervaginal space. However, I am not prepared to state in view of this that the cause of sympathetic ophthalmia is a Gram-positive diplococcus."

I succeeded once in growing Gram-positive cocci from the aqueous humor taken from a sympathetic eye, which in appearance stood between virulent staphylococci and sarcinæ, and which assumed the form of diplococci when introduced into the animal body. When the vitreous body of a rabbit was inoculated with this culture, it caused an abscess in the vitreous and iridochoroiditis, which presented after two months new infiltrations of the choroid and led to inflammatory changes in the optic sheaths and meninges.

I succeeded in growing Gram-positive and Gram-negative sarcinæ from a sympathetic eye, also a cocci culture which in the third generation changed into sarcinæ.

On the other hand, I have several times been fortunate—partly through inoculation into the abdomen, partly into the vitreous body—in varying sarcinæ through several animal passages in such a way that they took the form permanently of diplococci and showed the one or the other cultural property of true staphylococci, so that one could have taken them for avirulent white staphylococci. The cultures had most similarity to the coccus described by

Sattler, which also had been cultivated by Stilling, Limbourg, and Levy in sympathetic ophthalmia. The coccus found by me is perhaps also only a modified sarcina, although this cannot be exactly proved. One can assume that in cases of perforation of the eye, sarcinæ are carried into the eye directly by the inflicting instrument, or later find their way through the wound into the eye from the conjunctival sac, and there change in such a manner as to enable them in the form of diplococci to pass from the first eye, by way of the lymph channels of the optic nerve, past the chiasma, into the second optic nerve and thence into the second eye, setting up a sympathetic ophthalmia.

The theory of Leber and R. Deutschmann, according to which transmission of the exciting agent of sympathetic ophthalmia occurs by way of the optic nerve sheaths, receives renewed support from my researches. The former difficulties of this theory, which consisted in the several facts that the attack affected the anterior portion of the eye, and the frequent absence of symptoms of meningitis, are removed by the anatomic demonstration of a chronic, circumscribed leptomeningitis in seven out of eight animals affected with sympathetic ophthalmia, as well as be the extra-ocular transmission of the inflammatory process from the optic nerve to ciliary body.

All other theories which by reason of their imperfections are not generally recognised, contain new difficulties in explaining the facts discovered by me, especially the changes in the orbit and the meninges. Of late the abacterial genesis of sympathetic ophthalmia has received support from various quarters. The hypotheses are manifold and proceed from the assumption that no bacteria are found in the sympathetic eye, and that the inflammatory changes only move about in the two eyes. My experiments show that this assumption is false. It has been proved that the only tenable facts are that in animal experiments the eye can become anaphylactically diseased, and that such uvea is in the condition to act as antigen. The use of these results for the explanation of sympathetic ophthalmia, however, has completely failed, since up to now neither autocytotoxin nor uvea antibodies have been demonstrated in this disease, any more than in any other.

Guillery by means of enzymes, ferments, and other substances that exert kindred characteristic action upon the eye of the rabbit and especially upon the uvea, succeeded in producing a round cell infiltration, corresponding, in the main, with the infiltration of sympathetic ophthalmia, But I cannot recognise this similarity, since, as formerly explained, I do not admit that there is an absolutely specific anatomic picture of sympathetic ophthalmia. Furthermore, there is in Guillery's investigations a plain lack of proof that the inflammation caused by the ferments can be continued for a long time without the renewed support of ferments or that the propagation power is of sufficient degree to carry the process to the second eye.

Conclusions.

The results of my experiments and investigations on the pathogenesis of sympathetic ophthalmia may be summed up as follows:

1. I have succeeded by inoculation with particles taken from the choroid of a human eye affected with sympathetic ophthalmia, in producing genuine sympathetic ophthalmia in monkeys and rabbits.

2. I believe that the exciting cause of sympathetic ophthalmia is a Gram-positive diplococcus; possibly a modified sarcina.

3. The second eye becomes diseased when the bacteria succeed in passing from the first eye into the lymph channels of the first optic nerve, past the optic chiasma, and through the lymph spaces of the second nerve into the orbit.

4. The course of the bacteria passing from the eye into the optic lymph spaces, and *vice versâ*, is a twofold one; either direct from the choroid into the intervaginal space, or along the anterior ciliary vessels from the eyeball, around it, within the musculature of the orbit, and eventually back of the eye along the central vessels into the spaces of the optic nerve, and *vice versâ*.

5. The chronic inflammatory changes in the meninges consist of circumscribed foci, and cause no general symptoms.

LITERATURE.

1. v. Graefe's *Arch. f. Ophthalm.*, Bd. LXXVII.
2. v. Graefe's *Arch. f. Ophthalm.*, Bd. LXI and Bd. LXX.
3. v. Graefe's *Arch. f. Ophthalm.*, Bd. XXXVIII.
4. v. Graefe's *Arch. f. Ophthalm.*, Bd. LVII.
5. Kuhnt and v. Morrell, *Zeitschrift f. Augenheilk.*, Bd. IX.
6. Quoted in *Handbuch* v. Graefe-Saemisch, II Aufl., Kap. viii.
7. *Annales d'Oculistique*, 1901.
8. Quoted in 7.
9. Quoted in *Handbuch* v. Graefe-Saemisch, II Aufl., Kap. viii.
10. v. Graefe's *Arch. f. Ophthalm.*, Bd. LXII.
11. *La Clinique Ophtalmologique*, 1900.
12. *Beiträge zur Augenheilkunde*, 1893, Heft x.
13. *Klin. Monatsbl. f. Augenheilk.*, 1900, Letzehefte.
14. Knapp's *Archiv f. Augenheilk.*, Bd. LXVIII; *Klin. Monatsbl. f. Augenheilk.*, Bd. XLIX.

LATENT CONVERGENCE OR DIVERGENCE?

BY

A. W. STIRLING, M.D., C.M.

OPHTHALMIC SURGEON TO GRADY HOSPITAL, ETC., ATLANTA, GEORGIA, U.S.A.

WITH AN ADDENDUM

BY

ERNEST E. MADDOX, M.D.,

BOURNEMOUTH, ENGLAND.

I HAVE had a number of cases resembling the three following, and should be interested to hear comments upon them by ophthalmologists who have given special attention to muscular anomalies.

I.—Miss R. H., age fifteen years, complains of seeing badly, and of pain in the brow. Her vision, as a matter of fact, is nearly 6/4, with each eye slightly improved (under homatropine and cocain) with +.5 D.sph. +.25 D.cyl axis 90°.

She appears to have, as tested with the red Maddox rods, latent convergence of 7°, right eye also looking up 5°; but on testing with the red-green lights,* she shows a latent divergence of a varying degree. Next day, January 8th, 1911, she appears to run up to 8° of latent convergence, but when a 9° prism base out is put up before the right eye, she says that the line jumps twenty-four inches to the left. On removing the prism, the line continues on the left for a minute or two, and then slowly moves to the right; with the red-green test, she has latent divergence, which, with a 2° prism base in, goes to the right, but continuing to put up the prisms base in, as far as 10°, it becomes latent divergence after a period of about thirty seconds in each case.

*The red-green lights referred to oblongs of red and green glass. In the case of those for horizontal testing the long diameter of the red glass is set above that of the green, and for vertical tests the long diameter of the two lies in the same horizontal plane, Snellen's red-green glasses being worn by the patient.

February 3rd.—L.C. 8°, then L.D., remaining D. for a minute or so, sometimes moving slowly to D, and sometimes by a jump. February 8th.—L.D. at first, and then L.C., no prism being used. May 10th.—Sometimes L.C., and sometimes L.D., but usually a little L.C.

May 24, 1913.—L.C. at first, and then jumping to L.D. She has used for sometime in the interval prism exercise, base in.

II.—Miss H. H. age sixteen years. Complains of feeling as if eyes turned out.

October 1, 1909.—Has, under homatropine and cocain, 1·25 D. latent hypermetropia=6/4. She appears to have L.C. 1°, but the red-green test shows L.D. 3°. Right eye up 2°.

4th.—Sometimes L.C., at others L.D.

5th.—L.C. 4°, and suddenly L.D.

6th.—L.C. 4° and when 5° prism base out is used, line jumps several feet to L.D.

7th.—L.C. 1° and with 2° prism base out, line jumps two feet to left.

9th.—Correcting vertical imbalance does not affect the horizontal; thus, when so corrected, L.C. 5°, will suddenly become L.D.

III.—Miss J. D., age eighteen years, complains of morning headache, although health is good

R.V. 6/6 L.V. 6/6 partly. After examination under homatropine and cocain, she was ordered R. + .5 D ax. 60°. L. + .5 D. sp. +.25 D. cyl ax. 60° =6/5. With Maddox rods she shows first L.C., and when a 2° prism base out is put up, it becomes L.D. as far as 6°. With the finger test, there is distinct L.D., and on questioning, it comes out that the left eye deviated when she was a child.

ADDENDUM

BY

ERNEST E. MADDOX.

ALTHOUGH it is difficult to express an opinion on cases not actually seen and examined, the following comments may be offered:

Cases of double projection, in which one eye has two alternative fields of projection, are nearly, if not quite, always due to the previous existence of a (possibly undetected) squint. In case III a pre-existent squint is recorded. The name "false macula" used to be given to this condition, although projection is not a retinal, but a cerebral act.

During the continuance of the squint, one monocular field becomes displaced with relation to the other, a readjustment of identical points taking place in the part common to both. On the other hand, the original and natural correspondence, which existed before the commencement of the squint, is not wholly forgotten, the more so since it is favoured by anatomical relations, which are particularly persistent in the foveæ. Temporary squint may be due to hypermetropia, which disappears as the eye elongates, or to temporary failure of health, or transitory monocular impairment of vision; or it may be due to hyperphoria, which for a time is not conquerable, but thereafter becomes so, and this may have been the explanation of Dr. Stirling's first case

The two tests used by Dr. Stirling appear to have stimulated the use of different projections. The glass rods, if closely in contact, abolish fusion completely, while Snellen's spectacles still leave bright horizontal and vertical lines in the room visible, so that only a horizontal deviation may reveal itself, or only a vertical one, according as the eye is held in fusion partially by one or other set of lines. For example, when a horizontal line is perceived by eyes having hyperphoria combined with cyclophoria, the two images, being

inclined to one another, lie closer together at one end than at the other, and are thus more easily fused with one of the projections than with the other. They favour, therefore, the selection of that particular projection, whereas the rod test evidences no such favouritism, and does not necessarily appeal to the same projection. It may quite well happen that one test may elicit one projection and the other test awaken the second, so as to give the impression that the eye has jumped from one position to another, though it may not really have moved at all. Even while using the same test the mind may swing from one projection to another.

The glass rods need a little care to use them rightly. They should be thin and tightly packed, so as to allow no chinks between them, which might awaken fusion. They are best made of red glass and mounted with green glass before the other eye, a small handle enabling them to be slightly oscillated if necessary, to attract attention to them.

Rare cases like these recorded by Dr. Stirling may be studied with interest by many tests, such as Stevens' Phorometer, the Near Vision Phorometer made for the writer by Raphael, the writer's Wing Test,* Duane's parallax test, etc., but the most interesting of all is that by ophthalmoscopic reflections from the corneæ, since these enable the eye to be actually watched and its position noted during the exercise of each individual projection.

The treatment of an eye which has an eccentric, as well as a central projection, is first to find which is the central projection and develop it, placing it (by optical or surgical means) under the most favourable conditions for its exercise.

It has been suggested by one colleague that such vagaries as those above noted by Dr. Stirling shew the tests employed to be inaccurate. On the contrary, it is to their credit that they reveal them, for the vagaries are in the eye and not in the tests. The rod test can be safely trusted to tell a true story, and will, I think, be found as true a routine test for distant vision as any. Of course, in the presence of uncorrected hypermetropia, its story may vary from moment to moment, in proportion to the amount of accommodation in exercise, but that the rods faithfully reveal these movements of the eye in sympathy with accommodation is not a fault of the test, unless truthfulness be accounted such. The real fault lies in not securing a steady output of accommodation by correcting the refraction. The tests which I like best in ordinary work are, for distant vision the rods, and for near vision either the same with a fine source of light at the centre of a tangent scale, or the new Wing Test.

It is perhaps well to mention that, with all modes of phorometry, there is one pitfall for the unwary, to which too little attention has hitherto been given. It is this, that when a cyclophoria coexists with a horizontal deviation, the reading of hyperphoria will be a false one unless the horizontal deviation be first corrected by a prism. When thus corrected, the reading becomes true. Even with naked eyes, if a recent pure esotropia or exotropia with diplopia be tested by looking at a lamp or other object without the intervention of any apparatus whatever, the cyclophoria will cause one image to appear higher than the other and simulate hyperphoria. This misleading result will at once disappear on correction of the horizontal deviation with a prism, although a very strong prism has to be set with extreme accuracy to be wholly free from the disadvantage of itself producing an artificial apparent hyperphoria.

Of all modes of phorometry the glass rods alone can afford to dispense with the prism referred to. We are able to dispose of the fallacy entirely by the

* Made by Holloway, 115, Richmond Park Road, Bournemouth.

simple expedient of rotating the rods till the red line of light appears perfectly horizontal to the patient. Not only does the degree of tilt thus found measure the cyclophoria, but the spurious diagnosis of hyperphoria is eliminated. This is an advantage of the rod test over all others, although, confessedly, the error of others is not enough to be of importance unless the horizontal and torsional deviations be considerable.

CLINICAL MEMORANDA.

SYNCHYSIS SCINTILLANS.

Method of Observation by "Dark-ground Illumination."

BY

PERCIVAL J. HAY, M.D.,

SHEFFIELD, ENGLAND.

Synchysis scintillans can be demonstrated in very striking fashion in the following manner, which I discovered the other day.

Assuming that a Morton ophthalmoscope is being used, with the usual arrangement for placing either the small or large mirrors in front of the lens aperture, place the large mirror in front of the aperture, bring a + 8 D. or + 10 D. lens into use, and reflect the light not from the large mirror, but from the small one, which has been rotated out of the way. Look through the aperture, as in the direct method, approach the eye as near as possible, when the particles of cholesterin will appear brightly illuminated against a black background.

The effect is very beautiful.

ON THE ELECTRIC OPHTHALMOSCOPE, WITH PRESENTATION OF AN IMPROVED MODEL.*

BY

WILBUR B. MARPLE, M.D.

NEW YORK CITY, U.S.A.

I WAS much pleased with the appreciation of my model of the Electric Ophthalmoscope by Colonel Elliot which appeared in a recent number of THE OPHTHALMOSCOPE. May I, in this connection, again draw your attention to one point, and that is that its use is not limited to any one form of opthalmoscope. When one has become accustomed to the employment of a certain form of ophthalmoscope from years of practice, one becomes averse from changing to a new type of instrument, and many prefer a model different from the Morton. In my original communication on the subject, I

* Presented at the Oxford Ophthalmological Congress, July 18th, 1913, and at the International Medical Congress, London, August 9th, 1913.

distinctly stated that my electric attachment could be readily fitted to any form of ophthalmoscope, and any who essayed this new form of illumination could do it with whatever form of instrument he used. I presented it first fitted to a Morton instrument, because that was the one to which I was accustomed. I will not repeat what Colonel Elliot has so well stated, as to the many advantages of this electrically lighted instrument but will say that I have never known a *confrère* who, once giving it a good trial, did not permanently discard the old form of instrument.

There is one matter to which Colonel Elliot did not refer, and that is, its immense superiority over any other instrument in the discovery and removal of foreign bodies in the cornea. I have repeatedly discovered foreign bodies so minute that I could not see them with the Berger or Koller *loupes*, or any other instrument. In fact, I would not have been able to relieve the patient without the aid of my ophthalmoscope. With a +20 or +30 D. lens back of the aperture, these minute particles stand out so clearly on the red



glow from the fundus that they cannot be overlooked. Having once located them one can keep them in view with a weaker lens (+10 or +12D) and with a spud in the other hand remove them easily and with the minimum scratching of the rest of the cornea. You can also tell at once when the foreign body is removed. I have employed this method for the removal of these particles for several years, and the various *loupes*, which I formerly employed, lie unused in a drawer.

Like all who have used the instrument, I have long felt that if we could only do without the wires (which in the dark room often knock something over, or catch in something) it would be a great advantage. Dr. Crampton, of Philadelphia, two years ago, introduced into the handle a small dry cell. But there was no way of controlling the amount of illumination, which was so bright at first that patients disliked it very much. I present here a model which aims at eliminating this disagreeable feature by means of a little rheostat in the upper part of the handle, which is under the control of the observer, who can thus regulate the brilliancy of the light at will. As you will see, there is a small roughened band at the upper part of the handle which can be turned with the finger, thus regulating the light (2 in the figure). This is the first one made for me, and the band should move more easily. As to the mechanism for controlling the light, I first tried a knob moving up and down, but did not find this very convenient, and so discarded it. I then experimented with a little projecting knob moving horizontally, like that of Dr. Fenton. This worked all right except in one respect. As stated above, I always start by turning the handle till the reflex of the lamp filament is vertical. I found that after doing this the knob was sometimes in one position, and sometimes on the opposite side of the handle, in a position quite

inaccessible to the finger, so I discarded this, and employed the roughened band. Some part of this circular band is always easily accessible to the tip of the finger, and when its movement is made a little easier, I think it is an ideal mechanism for the purpose. These batteries are cheap; are said not to deteriorate after keeping; and to run eight hours with interrupted, and four hours with continuous use. As far as I have used it, which is about six weeks, it has worked admirably. As you see, it is quite simple to remove the worn-out battery and introduce a new one. If it continues to work as well as it has already done, I think it will soon be generally adopted in place of the model with wires attached to the handle, at least in temperate climates. Colonel Elliot tells me that the climate of India is so hot and moist that he has never had much success with dry cells.

This instrument is the Loring model, but the attachment, as already stated, can be fitted to any form of ophthalmoscope.

Since I have been in England several gentlemen have shown me instruments (which they have purchased of various makers) supposed to be my model, but the working of which was not satisfactory. When examined, these instruments were invariably found to be made in a faulty manner. Therefore, I will briefly refer to certain features which the perfect instrument should possess. First, I wish to say that no one who has not had the experience of having a certain form of instrument made by instrument makers, can have any idea how difficult it is to have your ideas exactly carried out, and to have several instruments made exactly alike. For example, I have been five months getting the instrument produced that I show to-day, with the battery in the handle, and with the light under control. During these five months I have had at least six different instruments delivered to me, each one getting a little nearer to what I wanted. As I have already stated, this model has one or two things which want limbering up; when these points are attended to, I think it will prove to be a most satisfactory instrument.

When I first showed this ophthalmoscope at the American Ophthalmological Society several years ago, a number of my colleagues were so pleased with it that they ordered the instrument of the makers. Shortly afterwards, I began hearing from them to the effect that the instruments they had received were not at all as satisfactory as mine which they had tried at the meeting referred to above. After much trouble, the instrument makers began turning them out with some semblance of uniformity. However, they are all carefully inspected before they are put on the market, and one often has to return an instrument to the factory on account of some fault in the mechanism. When I first began using Prof. Schiötz' tonometer, I wrote to him to see if arrangements could not be made whereby one of our American makers could manufacture the instrument, as there was such a high customs duty on all that were imported. He replied very courteously, saying that the instrument was a very delicate one; that he always inspected them before they were put on the market; and that he would prefer that they continue to be made by his man in Christiania. My position in reference to my ophthalmoscope is much the same. It is probably unnecessary for me to say that for some reasons it is immaterial to me who makes it, for I am only anxious that it should be in the hands of as many as possible. But there are several important features about it which must be accurately made, and up to the present time I have had my hands full in getting one maker to produce them with anything like uniformity; so that, especially as I have seen so many wretchedly made instruments lately on this side, and some of them right here in the exhibition of this Congress, I feel that I must say that the only

instruments made under my supervision are manufactured by E. B. Meyrowitz, of New York City and London (1a, Old Bond Street, W.).

As to the features which the perfect instrument should possess, first of all, as Colonel Elliot has said, it must be one thing or the other, either a reflecting or an electric ophthalmoscope. I have seen models where an electric attachment was merely slipped on the ophthalmoscope after simply removing the mirrors, making it a sort of interchangeable instrument. None of these is at all satisfactory, and, as I have stated above, it must be made exclusively an electric instrument if one expects to be satisfied with it. It is not necessary, however, to buy a new instrument, for anyone can have any ophthalmoscope he possesses readily and cheaply converted into the electric model, but when so converted, it should be solely an electric model, not an interchangeable one. Second: the fault with most instruments that have proved unsatisfactory is in the mirror. As is well known, this should be U-shaped. It will not do, however, merely to have the silver removed, but the glass must be cut away over an area 1·5 mm. broad, from the top of the mirror to the point which would be the lower margin of the aperture if the mirror had a circular central aperture (about 4·5 mm.). One gentleman showed me an instrument which he had bought, the mirror of which not only had the silver removed at the back, a bad enough fault, but over an area not U-shaped but V-shaped, apex down. As the angle of the V was very acute, practically no light came through the centre at all, and I could not get any view of the fundus through it. Furthermore, the mirror should be concave. Most of those I have seen made on this side, are plain. The fact is that it is quite difficult to make one of these mirrors satisfactorily. One can easily tell whether the mirror is concave or not by turning on the light and reflecting it on to the back of the hand. If it is concave a clear image of the mirror is formed on the back of the hand, the size of which changes as the light is moved by the finger up or down the handle. Third: formerly, I broke a mirror very frequently, but with the improved case which is now sold this accident has not happened to me for a long time. A broken mirror, a long way from an instrument maker, is a serious accident, although Colonel Elliot has introduced a most ingenious device by which a new mirror can be readily inserted, the later models all have this device, and several extra mirrors go with each instrument, so that in case one is broken, a new one can be easily introduced. So much for the mirror. Fourth: Colonel Elliot, in his article in THE OPHTHALMOSCOPE, has emphasized the importance of the moveable light, and in a good instrument the observer should have this light readily under his control with any finger. If one finds that one cannot readily move up and down with the tip of the finger the roughened band moving the lamp up and down ("1" in figure), one should reject such instrument until this defect is corrected.

Before using the instrument, it is desirable to see that the reflex of the lamp filament in the mirror is vertical. If it is not, a turn of the handle will quickly bring the reflex into the proper position.

One of the commonest causes for the failure of the lamp to burn is that in knocking it around the lamp has gotten a little loose and contact is broken. Whenever I find that the light does not burn, the first thing I do is to pull the ophthalmoscope from the handle, and screw the lamp firmly home. Nine times out of ten I find this promptly starts things going again. Colonel Elliot tells me that in several instances men who have taken instruments from Madras to distant parts of India have returned them to him after some time saying they would not work. All that was the matter was that the lamp needed to be screwed a little tighter, and the difficulty was removed.

Fifth: in the new model which I present to-day, there are two points to be always looked into. First, the roughened ring ("2" in figure) which turns the rheostat, should move easily with one finger. Again, the rheostat should be delicate, and control the brightness of the lamp regularly and without any sudden gradations in brilliancy. In other words, the light should begin as a very faint one, as we often want to use a feeble illumination. Then, as we turn the rheostat, the illumination should gradually and regularly increase.

In selecting an instrument, therefore, attention must be paid to the following points:

1. It must be an electric ophthalmoscope through and through, not one of the slip on-and-off kind.
2. It must have a U-shaped mirror where the glass has been cut away, with a slit 1.5 mm. broad, and the mirror must be concave.
3. It must have Colonel Elliot's device for readily inserting a new mirror.
4. The band ("1" in figure), moving the light up and down, must move easily with the tip of the finger.
5. We must be able to turn the handle around in the ophthalmoscope.
6. In the new model the band, moving the rheostat ("2" in figure), must turn readily with the finger while examining a patient, and the rheostat must work evenly and delicately.
7. A desirable feature is a large case holding the whole instrument without taking it apart.
8. One must not forget, if the lamp does not burn, to pull the instrument apart and to tighten the lamp.

If one possesses an instrument having the above features, and gives it a fair trial, he will become more and more delighted with it the longer he uses it, and will more and more appreciate its numerous and great advantages over any other form of ophthalmoscope.

The instruments produced under my supervision are made by E. B. Meyrowitz of London and New York City.

46, West 53rd Street.
New York.

NOVELTIES.

THE "SIGNAL" VISION TEST TYPE.

by
N. Bishop Harman.
London, England.

This test type has for its signs the block E, after the fashion of Hirschberg's test types, but only one sign is given for each grade of the test. The signs are mounted on turntables, so that their positions can be varied indefinitely In one model the whole of the turntables are geared together by a simple pulley arrangement, so that the movement of a milled head at the front

bottom edge of the board, causes all the signs to turn in different directions. In the simpler model, the turntables have knobs projecting behind the board, by which they are moved as required.

This test is of particular value where it is desired to make a subjective test of vision, with a minimum of error due to the "mental factor," *e.g.*, in testing seamen, railwaymen, or other employées whose vision is a matter of importance. This test requires no knowledge of letters, only the minimum power of imitation. The test has already been in use for testing school children for some time, with excellent results.

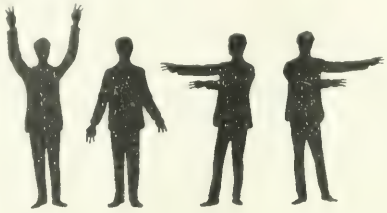

As a school vision test, the children should be taught to regard the E sign as three fingers, turned up, down, to the right, or left. The teacher should draw these signs on a class black-board in large size, and teach the whole class "signal drill," showing them how to stretch out three fingers of both hands in the position of the fingers of the E sign pointed to. After this drill, vision testing will be quick and sure. The test should be hung in full daylight (not sunshine), a monitor should stand beside the test, holding a sheet of dull coloured card, so as to cover all the signs below the one the child is looking at. The child should stand toeing a chalk line, drawn at a distance of 16 feet 6 inches from the test. The examiner, sitting slightly behind the child, will see both the sign and signal. The signs should be altered in position for each child, by the monitor turning the milled head or one or two of the discs. Except that the test will get dirty, there is no objection to letting it hang in the class-room, for it cannot be learned by heart.

On the back of each test card, there is gummed a printed sheet with the instructions as above, and a figure showing the manner of signalling with the arms and fingers.

The test is made in excellent fashion by Messrs. Curry & Paxton, Great Portland Street, London, W.

A MODIFIED GLAUCOMA TREPHINE.

BY

FREDERICK A. ANDERSON,

SHREWSBURY, ENGLAND.

The modification of Sydney Stephenson's trephine shown in the accompanying illustration is designed to give a better control over the instrument than is at present possible. It consists of a small stud with a cylindrical shaft which fits loosely into the central tube of the trephine handle. The base of the stud is concave upwards, to give a comfortable grip

for the finger and to diminish friction when the instrument is rotated. The handle of the trephine is cross-hatched, to obviate slipping of the fingers. In use the trephine is rotated between the thumb and second finger, while the ball of the index finger is placed on the stud. The advantage claimed is that the



thumb and second finger are free to act as rotators, while the index finger controls the pressure and maintains the upright position of the trephine. There is no tendency of the rotating fingers to slip down the handle.

The instrument is made by Messrs. Down Bros., London, S.E.

A TREPHINE WORKED BY ELECTRIC MOTOR.

BY

H. H. TAYLOR, F.R.C.S.,

SURGEON TO THE SUSSEX EYE HOSPITAL, BRIGHTON.

I have tried nearly all the different methods for obtaining a permanent drain in cases of glaucoma, and have come to the conclusion that Colonel Elliot's method is unquestionably the best. There is, however, at times some little difficulty in getting the trephine to bite, and also the objection—not a small one—that the pressure employed is painful to the patient.

Last year I had some trephines fitted to the hand-piece of a dental cable worked by the foot, but I found this unsteady, and the weight of the cable on the wrist awkward. I used it several times, however, and was very successful with it.

After many experiments, I have now fitted up an electric motor to work the cable, which is proving very satisfactory. The motor was supplied me by the Dental Manufacturing Co., Alston House, Newman Street, London, W. whom I have to thank for the trouble and interest they took in the matter. It is a Suspension Type Cable Engine. It is suspended from the ceiling by a wire and chain, so that the exact distance from the patient's eye can be regulated. There is also a reversible controller worked by foot. One advantage of the latter is that the motor instantly ceases when the pedal is released. The difficulty experienced at first was to get down the revolutions, but I do so now by passing the electric current from the main through a suitable lamp. It may seem at first sight that so powerful an instrument must be dangerous, at any rate in the hands of a not too skilful operator, but the very reverse is the case, as only the very slightest pressure is necessary. The ease and safety with which it works is a revelation to anyone first using it.*

* Vogt published his experiences with an electrically-driven Elliot trephine earlier this year (*Klin. Monatsbl. f. Augenheilk.*, April, 1913). – EDITOR.

CURRENT LITERATURE.

NOTE.—Communications of which the titles only are given either contain nothing new or else do not lend themselves to abstract.

I.—OPHTHALMOLOGY AND GENERAL MEDICINE.

(*Third Notice.*)

(1) **Taylor, James.—Vascular and other retinal changes associated with general disease.** *Trans. Ophthal. Society U.K.*, Vol. XXXIII, 1913, p. 1.

(2) **Werner, Louis.—On vascular and other retinal changes associated with general disease.** *Ibidem*, p. 9.

(3) **Coats, George.—Discussion on retinal vascular disease: pathological aspects.** *Ibidem*, p. 30.

A discussion upon the retinal changes associated with general disease took place at the first annual meeting of the Ophthalmological Society held in London in April last. It was opened by Drs. James Taylor and Louis Werner from the clinical aspect, and by Mr. George Coats from the pathological aspect.

(1) **Taylor**, of London, directed particular attention to cases in which failure of sight is associated with evidence of blocking of retinal vessels. Touching upon the commonly assumed embolic origin of the cases, he had been struck with the fact that in many he had found it impossible to identify any probable source from which an embolus could originate. In particular, there was no evidence of heart disease or of aneurism. Where the picture of embolism of the central artery of the retina coincides with an absence of cardiac mischief (mitral disease, dilatation, irregularity both in force and rhythm) the underlying condition is believed to be one of thrombosis. Taylor gives brief notes of four such cases, which he has met with during the last two years, in patients whose ages ranged from 10 to 27 years. When sudden impairment or loss of sight in one eye is associated with thrombosis of retinal veins and the occurrence of hæmorrhages and effusion, it becomes very important to endeavour to discover changes in the other organs, for upon them depends our power of giving a trustworthy prognosis. Taylor gives case-histories of eight patients, ranging in age from 38 to 72 years, all of whom suffered from failure of vision in one eye, associated with retinal hæmorrhages, usually associated with evidences of blocking of one or other of the retinal vessels. One alone of Taylor's patients had neither albumen in the urine nor enlarged heart. This particular patient was alive after two years. From a study of these cases Taylor draws the conclusion that such vascular ocular changes rarely occur without other visceral changes, and although the former may not possess the same ominous signification as those of albuminuric retinitis, yet they must be looked upon, as a rule, as indicative of grave visceral disease.

In Taylor's experience of cases of retinal thrombosis, cardiac hypertrophy and disease of the vessel wall are nearly always present. Albumen is sometimes found, and even when it is absent, the urine may be of low specific gravity. Sugar is rarely discovered. Where hypertrophy of the heart is not present, disease of vessels other than the retinal can almost always be verified.

Syphilis does not appear to be a common cause of vascular changes in the retina.

The vital prognosis in these cases is bad, although exceptional cases may survive for an unexpectedly long period. SYDNEY STEPHENSON.

(2) **Werner,** of Dublin, limits his remarks to the discussion of angio-sclerosis and its consequences as regards the eye. He urges the need of familiarity with the ophthalmoscopic evidences of the condition, since the retinal vessels may furnish the earliest indication of the disease and may remain the sole objective sign throughout its course. Ophthalmoscopic examination is no less important in the case of suspected arterio-sclerosis than it is of suspected intra-cranial growth. It may, indeed, be argued that it is more important in the one case than the other, seeing that arterio-sclerosis is a common condition, while tumour is a rare one, and that much may be done for the former class of patient, provided the underlying condition be discovered and remedied early.

The changes of angio-sclerosis may be present in both arteries and veins, or they may occur in either alone. They resolve themselves into alterations in the course, calibre, and walls of the vessel. According to de Schweinitz, three of the earliest signs are :—

1. A corkscrew-like appearance in the small arterial twigs, especially involving the macular branches ;

2. "Silver-wire" arteries, causing more or less displacement of the veins where they cross the last-named ; and

3. A dull-red colour of the optic disc.

As regards the second of the foregoing signs, the late R. Marcus Gunn (who was the first to describe its significance) pointed out that the pressure exerted upon the vein by the artery, might merely flatten the vein, or push it aside, or it might constrict the vein, which then appears swollen at either side of the artery (so-called "banking" of a vein), or decidedly impede the circulation on the distal side of the vein. In all cases the artery has lost its transparency, so that the vein can no longer be recognised beneath it, as under normal conditions. Werner's observations lead him to the conclusion that it is not altogether uncommon, even in children, to find a transparent artery produce slight flattening or displacement of an underlying vein.

The disease of the retinal vessels may be widely distributed, but more often it is limited in extent, and may even remain confined to one branch of a vessel, and even then may involve a very small part of its length.

Obstruction of the retinal circulation is one of the most serious consequences of angio-sclerosis. The cases fall into two groups : (1) those which show the ophthalmoscopic appearances familiar to us all as "embolism," and (2) those which we now know to be due to "thrombosis" of the central vein.

A case of bilateral obstruction, with the clinical signs of "embolism," is related.—The patient, a boy of eleven years, went suddenly blind in the left eye on March 7th, and three days afterwards he lost the sight of the other eye in a similar way. When seen by Werner the same day, the lad was unable to tell day from night with either eye, and his pupils were widely dilated and irresponsive to light. The right fundus presented a picture of "embolism," while the left fundus showed an appearance closely resembling that of choked disc. There was a history of a couple of attacks of "nose-bleed," although the patient was not a bleeder. Swollen glands in neck. Urine normal. No culture obtained from the blood. Blood-pressure, 95 mm. Wassermann reaction, tested twice, negative. Tuberculin test positive. Beyond some possible accentuation of the pulmonary second sound, the heart was normal. During the following 45 days it is satisfactory

to note that the lad regained 6/30 with his right, and 6/24 with his left, eye. Embolism is out of the question, and the condition is regarded by Werner as one of endarteritis, with or without thrombosis; but when it comes to accounting for the vascular affection in a child of this age, the author is driven to assume that tuberculosis, as evidenced by the positive tuberculin reaction, and the existence of enlarged glands in the neck, may have been the cause.

Among the "macular star," present in the foregoing case, Werner takes the opportunity of pointing out that the appearance can no longer be regarded as pathognomonic of Bright's disease, since it may be found in many other conditions, such as chlorosis, embolism, and other obstructive diseases, as well as in the neuritis associated with cerebral tumour, etc.

Werner next discusses those sudden repeated but temporary attacks of failure of sight, complete or partial, sometimes known under the name of *Amaurosis fugax*. The condition may affect one eye alone, or each eye at different times. A majority of the patients suffer from cardiac disease, angiosclerosis, or anæmia. The general symptoms noted during the obscuration of sight include headache, giddiness, and sometimes vomiting and fainting, while in a few instances a species of Raynaud's disease has been noted as a concomitant. Ophthalmoscopic appearances were rarely those of so-called "embolism," or much more often extreme constriction of the central artery or of its branches. In connection with re-establishment of the circulation, some curious phenomena have been described.—For example, by Sachs and Wagenmann a ring-like constriction was observed to travel centripetally along a retinal artery, and to disappear at a bifurcation. In a case by Benson the bloodless portion of the vessel advanced centripetally, and disappeared suddenly when it reached a bifurcation. In Harms' case, the blood-column was interrupted, and an ampulla-like enlargement of the vascular wall filled with blood moved peripherally like a wave. Weiss saw both arteries and veins converted into white streaks. When the attack resulted in permanent loss of sight, which sometimes happens, the appearances were similar to those witnessed in the late stage of embolism. Disease of the vessels is the main factor present in the causation of these recurrent obscurations of sight. The temporary character of the attacks is explained by assuming a fall in blood-pressure, so that the *vis a tergo* becomes inadequate to force the blood through the narrow lumen of the diseased artery. On the other hand, if the lowered blood-pressure lasts beyond a certain time, the obstruction becomes permanent, perhaps aided, as Werner suggests, by the formation of thrombi in the vessels. The fact that most patients examined with the ophthalmoscope during an attack manifested vessels converted into white lines is regarded by some authors as good evidence that the walls of the vessels were diseased, because the walls of healthy retinal vessels are invisible, even when they include no blood.

The older theory of causation held that the failure of sight was due to spasm of the central artery or of its branches. Pathologists seem averse to accepting this explanation, and in view of the pathological findings, there is no longer any necessity to assume the presence of spasm in explanation of the condition. The evidence of spasm in the retinal arteries is based partly upon the ophthalmoscopic appearances and partly upon analogy. It is difficult, except on the ground of spasm, to account for the appearance of a constriction, travelling like a peristalic wave towards the periphery of the fundus. Reimar thinks, however, that these descriptions of the appearances observed with the ophthalmoscope are due to a wrong interpretation of the phenomenon, known as "visible streaming," which is produced by the agglutination of the

corpuscular elements of the blood in a stagnant current. The argument from analogy is drawn from cases of migraine or from amblyopia fugax accompanied by symptoms of Raynaud's disease. But it has not been proved that spasm actually occurs in either class. Panas failed to confirm Raynaud's discovery of spasm in the retinal vessels in some of his cases. Werner concludes that further investigation will be necessary before we can finally decide what part is played by vascular spasm in the causation of these sudden obscurations of sight. SYDNEY STEPHENSON.

(3) **Coats,** of London, prefaces his study of the pathological changes that may occur in the central vessels of the retina by a sketch of their normal structure. His communication is illustrated by some excellent drawings of the vessels, normal and diseased.

Disease of the central artery of the retina is primarily confined to the intima—that is to say, to the endothelium and the elastic lamina. Changes in the muscular coat (which, although thin, is well-defined in the central artery) are probably always secondary. The essential lesion of endarteritis is to be found in the existence upon the inner aspect of the elastic lamina of new tissue, which nearly always encroaches upon the lumen of the vessel in an eccentric way, and may narrow it to an extraordinary degree. In the central artery the pathological process affects the intima alone, but in the retinal arteries, most usually the media and the adventitia. The lumen is lined with endothelial cells, which seldom manifest any great departure from the normal. By the use of specific stains, it can be shown that elastic fibres are the main constituent in the new tissue. The elastic lamina itself may often become considerably thickened, and it is not infrequently duplicated as regards part of its circumference. Each of the elements may undergo degeneration.

The primary lesion appears to be a proliferation of the endothelium, since in the healthy artery there are no other cells from which the new tissue could originate. The newly-formed elastic tissue also is presumably derived from the same source. The case is analogous, in fact, to the formation of Descemet's membrane and the lamina vitrea from the cells which line them, and to the subsequent irregular deposition of a similar substance from the pathological activity of those cells.

Evidence of primary disease of the central vein is, Coats believes, exceedingly rare. The usual change is an increase in the fibrous tissue of the wall, one result of which is to constrict the lumen concentrically.

It has been suggested that endothelial proliferation is in response to toxin circulating in the blood-stream, and on this view fibrosis is intended to resist increased pressure. There is some evidence that endothelial proliferation is responsible for irregularity of calibre with little obvious disease of the vascular wall, and that fibrosis causes the familiar "silver wire" appearance of the arteries, and, in a more advanced stage, white lines alongside the vessels.

SYDNEY STEPHENSON.

II.—THE ÆTIOLOGY OF DISEASES OF THE EYE.

(1) **Gamble, W. E.—The use of diagnostic doses of old tuberculin in determining the ætiology of optic neuritis and neuro-retinitis of obscure origin: the reaction is specific, definite reduction in sight.** *Ophthalmic Record*, February, 1911.

2) Bach, L.—**The ætiology and course of diseases of the uveal tract.** (Ætiologie und Verlauf der Erkrankungen des Uvealtractus.) *Zeitschrift für Augenheilkunde*, Januar, 1912.

3) Belenky-Raskin.—**Upon the ætiology of phlyctenular inflammation of the eye.** (Zur Ætiologie der phlyctänulären Augenentzündung.) *Zeitschrift für Augenheilkunde*, Juni, 1913.

(1) **Gamble,** of Chicago, records two most interesting cases bearing on the question of the diagnostic value of subcutaneous injections of old tuberculin in optic neuritis and neuro-retinitis. The patient was a medical man in each instance. In the first case there was right optic neuritis, but no symptoms of increased intracranial pressure, such as headache or dizziness. Wassermann reaction was negative, and the patient lost weight on mercurials. von Pirquet's reaction was positive, but to confirm this test, 4 mg. of old tuberculin was given subcutaneously. This was followed next day by considerable systemic disturbance, sickness, depression, restlessness, exhaustion, loss of appetite, and a feeling of nervousness. The eyes ached, and in the afternoon the head and teeth ached. Forty-eight hours after the injection, R. V.=20/100, as compared with 20/40 before the operation. In the left eye, which had also shown some blurring of the disc for over a month, the only change in vision discoverable was that in looking at black print the letters appeared grey. Three months later vision was 20/15 in each eye with correction, but some disturbance of colour vision persisted, and there was some secondary atrophy of the disc in the right eye. For six months this patient was given tuberculin T.R., beginning with 1/500 mg. every other day, gradually increased, but never in a larger dose than 1/30 mg., generally 1/40 mg. once a week.

Gamble lays down the following dictum :—

"*This pronounced reduction in sight, occurring about seventeen hours after the diagnostic dose was given, and lasting about four days, is the symptom of chief importance, and, to my mind, makes out definitely a case of tuberculous disease involving the optic nerve or tracts in the region of the chiasma, and must be considered in the nature of a specific reaction, and in view of this diagnosis the great value of tuberculin T.R. in small doses is shown.*"

The subjective symptoms in the case were instructive. In the early stage, on looking at the centre of an incandescent filament, the upper part of it looked bluish, while the lower part looked normal. Two or three days later, the filament looked like a series of dots or segments moving continuously. These phenomena were also observed in reading small print. Later, the patient entirely lost the ability to see red with the right eye. Six weeks later the left eye showed similar symptoms, and the optic disc became blurred. The left half of the electric filament looked blue, and people's faces had a ghastly hue. The recovery of colour vision for red was gradual, and began in the upper nasal quadrant.

The second case was one of left tuberculous neuro-retinitis in a man, forty years of age. The vision was 20/20 and 1 J. in each eye, but the left peripheral field was quite contracted. Wasserman negative. $2\frac{1}{2}$ mg. of old tuberculin was given, and this was followed in twenty-six hours by reduction of vision in the left eye and general constitutional disturbance. In forty-eight hours the vision was at its worst, *viz.*, L.V. = < 6/60. No Jaeger type. R.V. not affected. Nine days after the injection, he could read 6/18, and he was given 1/500 mg. T.R. therapeutically. The fundus at this time presented the appearances generally associated with albuminuric neuro-retinitis. The dose was gradually increased to 1/100 mg.

The danger in using tuberculin is in over-dosage, as no one clinical symptom can be relied upon to guide us. A temperature that is above normal is of little help practically, as we do not approach a dosage that will produce temperature. A more delicate temperature test, in Gamble's opinion, is subnormal temperature produced by tuberculin, and especially in the morning. The more important clinical symptoms to observe are weight, appetite, mental state, and physical energy. J. JAMESON EVANS.

(2) **Bach**, of Marburg, has analysed the records of all the cases of disease of the uveal tract which have visited his clinic during the past sixteen years, and whenever possible has sent for them for re-examination. In many cases the Wassermann reaction was carried out. The author excluded cases of tuberculous granulation tumours, and undoubted cases of syphilitic infection; it is difficult to see exactly why he did so, but he states that both conditions played a very small part in his clinic. The total number of patients was about four hundred.

It was found that of cases of iritis and cyclitis only fifteen and twenty-one per cent. respectively were bilateral; but when we come to iridocyclitis and choroiditis the figures mount to fifty-two and sixty-one; that is to say, choroiditis is four times more frequently bilateral than iritis. The distinction the author makes between iritis and cyclitis and iridocyclitis seems rather subtle, and hardly accurate pathologically. Tuberculosis and rheumatism were the commonest causes of the uveal affection. Fifteen per cent. of the cases of iritis and cyclitis were tuberculous, twenty per cent. of iridocyclitis, and eighteen per cent. of choroiditis. Rheumatism accounted for eighteen per cent. of the iritis and seven per cent. of choroiditis. *In forty-seven per cent. of the cases of iritis and fifty-nine per cent. of choroiditis, the most careful local examination and the most minute general overhaul failed to determine the cause of the inflammation.* The author considers that modern methods of diagnosis, especially the use of Röntgen rays, will reveal a general tuberculous infection in a larger percentage of cases. In other words, he believes that a certain number of the fifty odd per cent. of undetermined cases have a tuberculous ætiology.

Seven per cent. of the cases of iritis recovered; forty per cent. of those of choroiditis. Twenty-one cases treated with tuberculin are not included in the analysis: the number Bach thinks too small upon which to ground any opinion as to the value of the method, but he avers that the views stated in modern tuberculin literature fill him with astonishment, even with alarm. For this reason he feels compelled to state certain facts.—(1) Nearly all tuberculins—there are over twenty kinds—have no experimental foundation, and rest entirely upon rational (*rationellen*) considerations. (2) The nature of the action of tuberculin is entirely hidden from us. (3) The diagnostic value of tuberculin is very small, excepting in children, for the best tuberculin vaccination methods show that up to twenty years of age nearly ninety per cent. of all men are *infected* with tubercle, but are not *ill* with tubercle. The general reaction, fever, etc., does not give evidence that an ocular infection is tuberculous or not, whereas a local reaction must be avoided, because, as well known, it can mobilise tubercle bacilli. (4) The author would point out that in veterinary work tuberculin therapy had been entirely given up. (5) Tuberculin therapy, in Bach's opinion, demands individual dosage.

The author recommends those ophthalmologists who have no experience to carry out v. Hippel's methods carefully, and not to be led away by erroneous teaching. T. HARRISON BUTLER.

(3) **Belenky-Raskin**, of Bern, working under Professor Siegrist, has

investigated one hundred consecutive cases of phlyctenular disease to determine whether the patients were tuberculous or not. Axenfeld found signs of scrofula is 90 per cent. of these cases, and it is now generally held that phlyctenules denote the presence of the tubercle bacillus somewhere in the body. As is well-known, phlyctenules often appear when old tuberculin is instilled into the eye. Rosenhauch and Rubert have succeeded in producing them in animals which were tuberculous by irritating the conjunctiva with old tuberculin, or staphylococci, or their toxines. The present paper deals with the results of the von Pirquet reaction and the Moro reaction. The author obtained a positive result in 90 per cent. of the von Pirquet tests and in 85 per cent. of the Moro tests. The remaining 8 per cent. were carefully examined, and in all of them either there was a strong family history of tuberculosis or the patient showed obvious signs of clinical tuberculosis. Indicanuria was not often detected. The results of the investigation help to prove that phlyctenules denote tuberculous infection, although personally we do not attach great weight to von Pirquet's reaction. The reviewer's own statistics show that at least 70 per cent. of all cases afford evidence of tuberculous infection.

T. HARRISON BUTLER.

III.—COLOUR VISION.

(1) **Armaignac.—Some reflections on colour vision and Daltonism. A new arrangement of coloured wools for the investigation of Daltonism. (Quelques réflexions sur la vision des couleurs et la Daltonisme. Nouveau dispositif de laines colorées pour la recherche du Daltonisme.)** *Ann. d'Oculistique*, septembre, 1912.

(2) **Hilbert, R.—The true chromatopsias. (Zur Kenntnis der genuinen Chromatopien.)** *Klin. Monatsbl. f. Augenheilkunde*, April, 1913.

(3) **Horniker, E.—Remarks upon testing the colour sense. (Bemerkungen zur Farbensinnuntersuchung.)** *Zeitschrift für Augenheilkunde*, August-September, 1913.

(1) **Armaignac**, of Bordeaux, has had many years' experience in examining the colour vision of railwaymen, and is satisfied that a considerable number of failures to pass the tests employed are due to colour ignorance. His own statistics show only 3 to 4 per 1000 of Daltonism instead of 3 to 4 per cent., as found by other observers. He points out that the conditions obtaining in the lamp and wool tests resemble respectively night and day signals. He describes Holmgren's test as consisting in making the candidate not only name the colours of the skeins of wools successively presented to him, but also classify them, when mixed, by colours and tints. For several years he used the wool test and a test with polarised light simultaneously, and he found that they gave identical results, but he considers the former more suitable for people of limited intelligence. His own method of applying the wool test consists in making the candidate first name all the colours, each of which is presented to him several times and then to distinguish between several confusion or complementary colours of feeble or medium tints. If he answers correctly and without hesitation, he is regarded as having normal colour vision, but if not, he is given a skein of the purest and most saturated type of the colour about which he appears to be uncertain and told to point out all those of a similar colour. If he does this correctly, he is regarded as distinguishing

the suspected colour well, and the other colours are tested in a similar manner. In applying this test Armaignac uses a set of forty-three plaits (*brins tordus en corde*) 8 cm. long of wools of carefully selected colours. These are made into a tassel which fits into a case, so that by drawing it in or out, any desired amount of the wools from the entire 8 cm. to merely the ends can be exposed. In practice the ends of the wools are first shown, and if there is any difficulty in distinguishing their colour, increasing amounts of the wools are drawn out of the case. R. J. COULTER.

(2) This short paper by **Hilbert**, of Sensberg, will be of value to those who are interested in the subject of chromatopsia. In it he reviews the cases published during the sixteen years since the appearance of his work on the pathology of the colour sense. He adds a number of references, bringing the bibliography up to date. A. J. BALLANTYNE.

(3) **Horniker**, of Triest, begins his paper by the statement that ophthalmologists are practically unanimous in the opinion that Holmgren's wool test is incapable of detecting all cases of colour blindness, and is, therefore, to be abandoned as untrustworthy. He says later in his paper "so much is clear, from all that has been said, that the further employment of Holmgren's test must be abandoned. The difficulty and awkwardness of its application, and its inability to detect many cases of colour weakness, are quite sufficient to warrant its absolute abolition."

Here the author is in complete agreement with Oloff and Stargardt, and with almost all English ophthalmic surgeons. In fact, the test is now peculiar to our Board of Trade and some of our railway companies. Horniker goes on to say, that the only practical tests which remain are Nagel's and Stilling's, when large numbers have to be examined. He is obviously (as most Germans who write upon the subject are) ignorant of the simplest test of all, *viz.*, the Edridge-Green Lantern. He likes Stilling's test best, and notes that Nagel himself recommends its use concurrently with his own, Stilling's cards to be used first, then Nagel's. But he says, that no single test suffices for all cases. The anomaloscope is useful, but its cost is almost prohibitive, except in certain central stations. Also an intelligent malingerer who has a normal Rayleigh equation, but is still colour blind, may succeed in passing the test unless great care is exercised. Some malingerers have even learnt Stilling's and Nagel's tests, but if Stilling's cards be cut up into small pieces, this objection falls to the ground. In conclusion, the author recommends Stilling's plates, Nagel's cards, and perhaps, also Cohn's tablets. The reviewer would say, Why not add the lantern as well? The whole matter is really so simple, if a man examined with a lantern which has neutral glasses never confuses white, red, and green, and can see red combined with the deepest neutral glass, he is safe at sea and on the locomotive. If he once calls white green, or green red, or white red, reject him at once, no matter what he does with any pigment tests. Spectral tests or Rayleigh's equations are far too complicated for the average engine driver or seaman.

T. HARRISON BUTLER.

IV.—INJURIES TO THE EYE BY LIGHT.

(1) **Santer, Albert C.—Electric injuries of the eye.** *Ophthalmic Record*, May, 1911.

(2) **Jocqs, R.—Cataracts due to electric discharge. (Cataractes par décharge électrique.)** *La Clinique Ophtalmologique*, 10 avril, 1912.

(3) **Bronner, Adolph.—Note on a case of unilateral optic atrophy after exposure to an arc light.** *Lancet*, March 29th, 1913.

(1) **Santer,** of Philadelphia, cites a case of lental opacities following exposure of the eyes to very brilliant light caused by the short circuiting of some electric wires. Impairment of vision was noted only two months after the exposure. A year later, R.V. = 6/35, L.V. = 6/60, and both lenses showed opacities formed of fine dots and lines with here and there numerous fine myeline globules. The opacities were situated in the anterior cortex of the right eye and at the equator of the lens in the left eye. The eyes were otherwise perfectly healthy, but there was concentric contraction of the field for form and colours in each eye. Beyond a history of syphilis twenty years previously, there was nothing in the family or personal histories which might explain the occurrence of lental haze.

In addition to cataract and visual inflammation, keratitis, hæmorrhages into the anterior chamber, vitreous, retina, choroid, and optic nerve and blindness from lesions in the cortical visual centres have been recorded as the result of industrial electric traumatism. Occasionally electric injuries are succeeded by definite systemic nervous manifestations, with eye symptoms characteristic of those affections. J. JAMESON EVANS.

(2) In association with a case of his own, **Jocqs,** of Paris, reviews the literature of the subject of cataract by electric shock. He comes to the conclusion that cataract, due to lightning stroke, comes on early as a rule, whereas that due to ordinary industrial currents is later, coming on in from one to four months after the trauma. This is important from the standpoint of prognosis. One may estimate that these cataracts (presumably those due to industrial currents, are here referred to), take from one month to one year to become complete. At the commencement, one sees fine dots in the anterior layers, and sometimes stellate opacities. When the cataracts are fully formed, they are white, and, according to the observation of Roche, this is due to thickening of the anterior capsule. In six cases out of nine, the cataract was unilateral. ERNEST THOMSON.

(3) **Bronner,** of Bradford, relates the very interesting case of a female patient who, after an hour's work with an arc lantern of which the inspection aperture was for part of the time unprotected with tinted glass, developed undoubted optic atrophy. There can be little doubt about the facts, since Bronner saw her for the first time within a week of the incident. At that time, while the vision was poor, the optic nerve looked normal, and Bronner was able to watch the changes which took place in the nerve through the progress of time, and to note also the alterations in the visual field. There was never any pain or photophobia. The fellow eye was unaffected.

ERNEST THOMSON.

V.—INFLAMMATIONS OF THE CONJUNCTIVA.

(1) **Sava-Goiu.—On an epidemic of diplobacillary conjunctivitis. (Sur une épidémie de conjonctivite à diplobacilles.)** *Ann. d'Oculistique*, août, 1911.

(2) **Pfalz, G.—Traumatic conjunctivitis. (Ueber traumatische konjunctivitis.)** *Klin. Monatsbl. f. Augenheilk*, November, 1911.

(3) Dorff, H.—Conjunctivitis due to ascarides. (Ueber Konjunktivitis durch Askariden.) *Klin. Monatsbl. f. Augenheilk.*, Dezember, 1912.

(4) Fromaget, Camille, and Fromaget, Henri — On a rare form of staphylococcal infection of the conjunctiva. (Forme rare de Staphylococcie Conjonctivale.) *Ann. d'Oculistique*, avril, 1912.

(5) Gross, Julius. — Two cases of vernal conjunctivitis. *American Journal of Ophthalmology*, June, 1912.

(6) Ishihara, S. — Relationships between perléche and blepharo-conjunctivitis, both of diplobacillary origin. (Beziehungen zwischen Perléche und Blepharo-conjunktivitis beide hervorgerufen durch Diplobazillen.) *Klin. Monatsbl. f. Augenheilkunde*, Oktober, 1912.

(7) Ormond, A. W.—Case of pemphigus of the conjunctiva followed by essential shrinkage of that membrane. *Proceedings of the Royal Society of Medicine*, December, 1912.

(8) Cohen, Martin. — The clinical course of conjunctival affections associated with so-called trachoma bodies. *Archives of Ophthalmology*, January, 1913.

(9) Arboleda. — Chronic calcareous conjunctivitis. (Conjuntivitis Calcarea Chronica.) *Anales de Oftalmologia*, febbraio, 1913.

(10) Krusius and Clausen. —On the etiology of Parinaud's conjunctivitis. *Archives of Ophthalmology*, March, 1913.

(1) **Sava-Goiu**, of Jassy (Roumania), gives a description of an epidemic of conjunctivitis among the civil and military population of Vasluy during the months of December, 1910, and January and February, 1911, which was found to be due to infection with the Morax-Axenfeld diplobacillus, complicated in some cases by staphylococcic infection. The origin of the outbreak was supposed to be traced to two infected attendants at the public baths.

R. J. COULTER.

(2) **Pfalz**, of Düsseldorf, deals with this subject from the point of view of the experienced insurance officer. The following are his main conclusions.—Conjunctivitis due to mechanical injury is short-lived, recovering in a few days without treatment. If its duration is prolonged, we are dealing with an infective condition, either existing before the injury or due to secondary infection. In some occupations a certain amount, of conjunctival hyperæmia, and even of discharge, is quasi-physiological. The use of astringents will only increase the irritation, and the sole method of treatment is removal from the conditions which are responsible.

Chemical and thermal conjunctivitis occurs in three degrees, the first characterised by simple hyperæmia, the second by chemosis and hæmorrhages, and the third by necrosis. The first two should be treated by simple antiseptic and non-irritating lotions. Astringents should be avoided. After these injuries, hyperæmia is apt to persist for a long time. This is not to be taken as evidence of inflammation. It is due to the formation of new vessels, which are slow to atrophy. Pfalz quotes illustrative cases in which the patient was kept off work and under treatment for months, and even for years, on account of this supposed persistence of inflammation. Treatment in this condition is not only useless, but it keeps up irritation, besides inducing a neurasthenic state. Where there has been destruction of conjunctiva, early transplantation of skin or mucous membrane is advised, but only if the loss is in the palpebral conjunctiva or fornix.

In industrial districts where trachoma is prevalent, for example in Westphalia, trachoma is often attributed to an injury, and the possibility of such a relationship has been much discussed. It must be admitted to be theoretically possible that the injury could render the conjunctiva less resistant to the trachomatous infection, but there are many other possibilities, and in the majority of cases the association is merely coincidental.

A. J. BALLANTYNE.

The form of conjunctivitis referred to by **Dorff,** of Freiburg, has been known to occur in somewhat rare cases in butchers and knackers through the body fluids of the Ascaris Lumbricoides, or other variety of Ascari, gaining access to the conjunctival sac, but it has been much more common among zoologists who have had occasion to handle or to dissect those worms. Different individuals show remarkable differences in the degree of their susceptibility, some, like the author himself, being apparently immune to the poison, even in its strongest form, while others merely require to enter the room in which the creatures are being handled to experience quite a severe affection of the eyes. The affection may be described in two forms, the milder apparently produced by some effluvium which is given off by the worms, and the more severe form caused by some of the cœlom fluid coming into contact with the conjunctiva. The former, in susceptible persons, gives rise to a subacute catarrh with conjunctival swelling of short duration. It is not uncommon in laboratory workers who are exposed to the undefined emanations referred to. The result of the actual contact of the fluid contained in the body cavity of the worm with the conjunctiva of a susceptible person is the sudden development of severe burning and lacrymation, with pronounced chemosis. The pain and lacrymation soon pass off, but œdema of the lids and neighbouring skin develops to the point of complete closure of the lids. Spontaneous recovery is complete in three or four days. The cornea and the deeper parts of the eye are unaffected.

Dorff's experiments may be said to have been carried out both on animals and on the human subject Rabbits and guinea-pigs were found to be quite immune. Some cats gave a slight reaction, while most dogs gave no reaction, but 5 out of 22 gave a severe one. The author himself was quite unaffected, even by the instillation of the cœlom fluid into his conjunctival sac, while the laboratory attendant, who assisted him in the work, was affected every time he had to handle one of the animals to which conjunctival applications had been made. He was unable to influence the susceptibility of animals by administration of calcium salts or by the withdrawal of calcium from the body. Repeated application of the toxic fluid in animals produced effects of diminishing intensity, but this does not seem to agree with the experience of susceptible persons who suffer from the symptoms whenever exposed to the irritant.

With regard to the nature of the irritant, Dorff concludes that it is not to be classed with substances like turpentine, mustard, etc., which produce their local effects by a reflex action, but among those which act directly on the vessels or on the sympathetic nerve-endings in the vessels. This opinion was confirmed by the fact that if adrenalin was instilled before the application of the Ascaris poison, chemosis and redness did not occur. He considers that these two substances act at the same point, but in opposite senses. They belong to the class of Specific Vascular Toxins, one characteristic of which is that they act only in specially disposed individuals. The fluid is not rendered inactive by passage through a bacterial filter. Its active constituent is therefore more likely to be a soluble alkaloid than a toxalbumose.

A. J. BALLANTYNE.

(4) **Camille** and **Henri Fromaget**, of Bordeaux, record a case of an unusual form of conjunctival inflammation, which was found on bacteriological examination to be due to infection with staphylococcus aureus. Clinically, it was characterised by injection, most marked in the culs-de-sac and at the angles, and an indurated ill-defined swelling, 15 mm. by 5 mm., in the lower cul-de-sac, with a velvety inflamed surface, covered with small yellowish abscesses the size of a grain of millet. There was marked swelling of the preauricular gland and of the carotid chain of glands. Under symptomatic treatment (evacuation of the abscesses, bathing with boiled water, and borate of soda drops) a rapid cure was obtained. R. J. COULTER.

(5) The article by **Gross**, of St. Louis, consists in about six pages of interesting historical review of spring catarrh, and one page of description of two cases. ERNEST THOMSON.

(6) *Perléche* is an eczematous affection of the skin at the angles of the mouth characterised by the presence of moist white plaques. It occurs chiefly in uncleanly young persons, and may affect several members of one family or become epidemic in schools. It is very common in Japan. The condition is apt to show relapses. It seldom ulcerates or leaves rhagades. **Ishihara**, of Tokio, has found that in every case diplobacilli are present in the lesion, and that these diplobacilli in pure culture produce a typical blepharo-conjunctivitis when inoculated in the human conjunctiva. He believes the diplobacillus of Morax-Axenfeld to be the infective agent. A. J. BALLANTYNE.

(7) A male, aged 17, who had had the disease since eleven years old, was shown, by **Ormond**, of London, with the object of getting advice as to treatment.

In the discussion it was mentioned by J. B. Lawford and by Herbert Fisher, of London, that in a case which each of them had seen, in which vesicles were present, a vaccine had been prepared from the vesicles. Lawford said it was difficult to say anything about such treatment on the experience of one case only, but his opinion was that the treatment had retarded the progress of the disease. N. B. Harman, of London, thought that temporary alleviation of symptoms was all that could be expected with our present knowledge. Ormond, in replying, said that seven years ago there had been vesicles, and that he had removed and injected a small piece into a guinea-pig with the view of ascertaining whether there was any tuberculous basis. None had been found. ERNEST THOMSON.

(8) In further confirmation of his theory that there exists an independent conjunctival affection associated with the trachoma bodies resembling trachoma with acute manifestations, but not complicated with pannus or cicatrices and their sequelæ, **Cohen**, of New York, reports a number of other cases in which the trachoma bodies have been found, which he divides into three groups, namely, cases of trachoma, of blennorrhœa neonatorum non-gonorrhoica, and cases of blennorrhœa gonorrhoica in young girls. In only a few of all these cases was the clinical course possibly much affected by the treatment, since only mild therapeutic measures were, as a rule, employed. The conjunctival affection which Cohen thinks to be due to the trachoma bodies is characterised by swelling with slight mucoid secretion and medium-sized follicles in the upper and lower transitional folds and papules on the tarsal conjunctiva. After lasting about two months, resolution gradually occurs, and the conjunctiva returns to normal in all in about three or four months. This disease, if it be a true entity, must often be confused with trachoma, with which disease it is also apparently frequently co-existent. It co-exists also with blennorrhœa gonorrhoica, but the blennorrhœa neonatorum

(non-gonorrhoica) in which the bodies were found were, Cohen thinks, pure cases of the disease, neither true trachoma being present nor gonorrhœa.

ROSA FORD.

Arboleda calls attention to a condition which he has noticed very frequently in his practice at Bogota, and which, on the other hand, is very much rarer elsewhere. It consists in the deposition of calcareous nodules in the conjunctiva of the lids, especially in the lids of those patients who suffer from errors of refraction. These nodules can be seen in both lids, but not frequently in the culs-de-sac, of the size of the head of a pin; their colour is whitish-yellow, their consistence is hard, and they elevate the surface of the mucous membrane; they are, in fact, true foreign bodies, embedded in the conjunctiva itself. When the conjunctiva gives way over them, they abrade the cornea and produce much irritation.

Examination of the concretions shows that they contain a few epithelial cells and polynuclear leucocytes. No micro-organisms are found; the histochemical examination shows the presence of lime salts. The only treatment of use is removal; but they often recur HAROLD GRIMSDALE.

(10) **Krusius and Clausen**, of Berlin, consider that Parinaud's conjunctivitis is due to a local tuberculous infection of an individual previously infected by tuberculosis, and therefore relatively immune. The two cases which they have investigated both gave a positive von Pirquet's reaction and a positive reaction to tuberculin, although this was general and never local in the eye. In one case, a phlyctenular condition had formerly been present, which the writers think is fresh proof of a previous general tuberculous infection, a phlyctenule in their opinion being a non-tuberculous morbid process in a tuberculous body. The evidence that the infection in Parinaud's conjunctivitis is tuberculous rests upon the type of the affection, *viz.*, the stormy onset, arrest in the first glandular swelling, and spontaneous recovery.

ROSA FORD.

VI.—BACTERIOLOGY.

(1) **Mattice, Albert F.—The occurrence of pneumococci on the conjunctiva after extirpation of the lacrymal sac. (Ueber das Vorkommen von Pneumokokken auf der Konjunktiva nach der Tränensackexstirpation.)** *Klin. Monatsbl. f. Augenheilkunde*, Juli, 1912.

(2) **Metafune and Albanese.—Further researches into the occurrence of the pneumococcus on the normal conjunctiva, with special reference to the variation of the findings. (Weitere Untersuchungen über das Vorkommen der Pneumokokken auf der normalen Bindehaut, besondere über die Schwankungen des Befundes.)** *Klin. Monatsbl. f. Augenheilkunde*, Oktober, 1912.

(1) Plaut and Zelewski concluded from their researches on this subject that, after extirpation of the lacrymal sac, there was an increase in the flora of the conjunctiva, especially of the xerosis bacillus. The pneumococcus was found in only 10 per cent. of the eyes; was in small numbers; and had a low degree of virulence. Although the stagnation of fluid in the conjunctival sac tended to increase the danger of infection as compared with the normal, the danger to the eye in the presence of a dacryocystitis was infinitely greater. Calderaro also found an increase in the bacterial content of the conjunctival sac. Two

months after the operation, the organisms were chiefly saprophytes, but bandaging of the eye for six or twelve hours, led to a distinct increase in the number and virulence of the pathogenic organisms present. He therefore recommended the postponement of operation for the extraction of cataract for a considerable time after extirpation of the sac, and also that bandaging of the eye should be avoided.

Mattice, of Seattle, has repeated these researches with the more refined method of Elschnig and Ulbrich. He finds that, while pneumococci are present in the conjunctiva of 90—95 per cent. of dacryocystitis cases before extirpation of the sac, this percentage is reduced by the operation to 43 per cent., and in the positive cases the number of organisms is comparatively small. No relation could be discovered between the severity of the epiphora and the bacterial contamination of the conjunctiva. The results show that the extirpation of the lacrymal sac, in cases of dacryocystitis, is a most valuable prophylactic measure against post-operative wound infection. It must not of course, be assumed that the conjunctiva is clean because the sac has been removed. It is necessary to make repeated examinations of the conjunctiva before operation can be considered as safe. A. J. BALLANTYNE.

(2) There has been a considerable difference between the results of different researches into the frequency of occurrence of pneumococci on the normal conjunctiva. Gasparini found it in 80 per cent., but some of his successors made the figure no higher than 4 to 9 per cent. Probably the figures obtained by Elschnig, and by others working according to his method, are more reliable. They put the percentage at from 30 to 40. **Metafune and Albanese**, of Naples, set out to find answers to two questions: (1) Is the pneumococcus content of the normal conjunctiva of cataract patients, before and after operation, constant, and does the conjunctiva which has by treatment been freed from pneumococci remain free, or does it return to its former condition after cessation of the treatment? (2) How does the pneumococcus content of the conjunctiva of normal persons vary when tested daily over long periods? Are both eyes always similarly affected?

They investigated the conjunctiva of 70 cataract patients before and after operation, and also carried out a long series of daily observations on their own conjunctivæ. Smear preparations and cultures, according to Elschnig's bouillon method,* were employed. They found great variation in the results in the normal conjunctiva, independently of any recognisable cause. An individual might show pneumococci one day, but not the next. The organisms might be present or absent, over longer or shorter periods. The two eyes often showed striking differences, indeed, one eye might for weeks show the presence of the pneumococci, while, during the same period, the other eye remained persistently free from the organisms. The conclusion reached is that even the method of Elschnig does not reach all the organisms present in the conjunctival sac, but that it is probable that variations in the number and vitality of the organisms themselves do occur. On the whole, the authors tend to the belief that 40 per cent. is an understatement of the number of healthy conjunctivæ in which the pneumococcus is present, and that we must always count on the possibility, not only of the presence of a few pneumococci, but also of an increase in their virulence.

A. J. BALLANTYNE.

---

* For description, see THE OPHTHALMOSCOPE, 1912, p. 39.

VII.—SYMPATHETIC OPHTHALMITIS.

(1) Domann, Paul.—Sympathetic ophthalmia: a critical study of the cases observed in the Leipzig University Eye Clinic in recent years, with special reference to the nature of the disease and the pathological findings. (Kritischer Bericht ueber die an der Universitätsaugenklinik zu Leipzig in den letzten Jahren beobachteten Fälle von sympathischer Ophthalmie, mit besonderer Berücksichtigung der Natur und der pathologisch-anatomischen Befunde.) Deutschmann's *Beiträge zur Augenheilkunde*, Heft lxxxii, 1912.

(2) Guibert.—Intra-ocular foreign bodies and sympathetic ophthalmia. (Corps étrangers intra-oculaires et ophtalmie sympathique.) *L'Ophtalmologie Provinciale*, mars, 1912.

(3) Brav, Aaron.—Sympathetic irido-cyclitis following cataract extraction, with report of a case. *Ophthalmology*, July, 1912.

(4) Guillery.—Concerning the effects of fermentations on the eye and their relation to sympathetic ophthalmia, Part II. (Ueber Fermentwirkungen am Auge und ihre Beziehungen zur sympathischen Ophthalmie II.) *Arch. f. Augenheilkunde*, Bd. LXXII, Heft ii, S. 99, September, 1912.

(5) Peters, A.—Sympathetic ophthalmia and disturbances of hearing. (Sympathische Ophthalmie und Gehörstörungen.) *Klin. Monatsbl. f. Augenheilkunde*, Oktober, 1912.

(6) Pechdo.—Some notes on sympathetic ophthalmia. (Quelques souvenirs d'ophtalmie sympathique.) *L'Ophtalmologie Provinciale*, novembre, 1912.

(7) Franke.—The relationship of lymphocytosis to injuries of the eye and to sympathetic ophthalmia. (Die Beziehung der Lymphcytose zu Augenverletzungen und der Sympathischen Ophthalmie.) *Bericht der Ophthalmologischen Gesellschaft*, Heidelberg, 1912.

(8) Stoewer.—Sympathetic ophthalmia and tuberculosis. (Sympathische Ophthalmie und Tuberkulose.) *Arch. f. Augenheilkunde*, Bd. LXXIII, Heft ii and iii, S. 155, Februar, 1913.

(9) Elschnig, A.—Sympathetic ophthalmia. *Trans. Seventeenth Annual Meeting of the American Academy of Ophthalmology and Oto-Laryngology*, p. 5. (Received May, 1913.)

(10) McReynolds, John O.—Sympathetic ophthalmia. *Ibidem*, p. 21.

(1) The material investigated by **Domann**, of Leipzig, comprises 26 cases of sympathetic ophthalmia. Putting aside three, in which the details are insufficient for the purpose of his paper, he bases his statistical results on twenty-three cases. Twelve of these occurred among 387 perforating injuries, giving 3·1 per cent., and eleven among 3,820 operations involving opening of the globe, giving 0·21 per cent. Both series of cases occurred during the same period of six years. Among the cases of an accidental nature there was a distinctly higher percentage of sympathetic disease among children than among adults. He did not find any special frequency among women as compared with men, nor in summer as compared with winter.

His statistics do not give any support to the view that retention of a foreign body in the eye increases the risk of sympathetic disease.

The time-interval between the injury and the onset of the disease was, as a rule, from four to six weeks, but it varied considerably, and it is, so far, impossible to establish an incubation period for the infective agent.

In the eyes which were the exciters of sympathetic mischief, the first subjective symptom was usually dimness of vision; occasionally, pain was complained of. Objectively, there was increased redness of the cicatrix, then succeeded hyperæmia of the iris, ciliary injection, narrowing of the pupil, precipitates on Descemet's membrane, and posterior synechiæ. In the later course of the cases there was much variation in the symptoms. Vitreous opacities were frequently present, and the fundus was usually obscured by cyclitic membranes or after-cataract. The disease in the sympathising eye usually came on during the acute outbreak in the exciting eye, but also sometimes occurred when the latter was recovering, when it was quiet, or after it had been removed.

The seat of the disease in the sympathising eye may be in the anterior part of the uvea, in which case corneal precipitates, ciliary injection, paralysis of accommodation, etc., are first noticed; or further back, involving the optic nerve, and leading to early loss of vision. The general course of the disease is similar to that in the exciting eye.

Domann's views on prognosis are that in young healthy subjects, who come early under treatment, enucleation of the inflamed eye gives a very good chance of saving the second eye. In older patients and weakly children, the prognosis is more doubtful. It is possible that in these cases the first eye may retain better vision than the sympathising eye, and enucleation, therefore, is not so clearly indicated.

The material submitted to microscopical examination consisted of nine exciting eyes, two sympathising eyes, and one eye removed as a safeguard in a case in which sympathetic disease did not subsequently occur. Lymphocytes were the cells most abundantly found in the infiltrated tissues, often grouped around the vessels and appearing as if they had wandered through the vessel-walls. Domann has formed the opinion that the lymphocytes come out of the blood stream, and make their way, perhaps under chemotactic influence, towards the injured spot. Plasma cells were also very numerous; so much so that he counts them as part of the typical picture of sympathetic ophthalmia. In severely affected eyes, epithelioid cells were sometimes found. They resembled the cells found in the normal connective tissue of the choroid and in the adventitia of blood-vessels. He considers that they are cells of this nature, and that they appear as the result of connective tissue destruction. In the severer forms, two varieties of giant cells were seen, some with peripherally arranged and some with scattered nuclei. Polymorphonuclear cells, mast cells, and eosinophiles were seldom seen, and bacteria never. In regard to the distribution of the changes, the subconjunctival and episcleral tissues showed lymphocytic and plasma cell infiltration, especially well-marked where the anterior ciliary vessels perforate the sclera. It was sometimes also present in the peripheral zone of the cornea, and in the episcleral tissue as far back as the insertions of the muscles. The iris and ciliary body were thickened by lymphocytic and plasma cell infiltration, and in the ciliary body the lymphocytes sometimes formed nodular masses. Plasma cells were less numerous and giant cells more so in the ciliary body than in the iris. In the vitreous chamber he found all the cells already mentioned. The choroid was chiefly affected in the neighbourhood of the optic nerve entrance. Lymphocytes were heaped around the larger vessels, and the walls of the vessels were often greatly thickened by growth of the adventitia. In about one half of the cases, the optic nerve itself was altered, showing slight increase

of its nuclei or infiltration of the typical description in the intervaginal space. The retina and its pigment epithelium seldom showed any change.

Disturbances of the general health were uncommon in Domann's cases. In one patient, however, a fresh mitral regurgitation seemed to develop in the course of his attack. The blood was examined in six cases. Three in which the lymphocytes were doubled in numbers at the expense of the polymorphonuclears, gave a good result. The other three cases showed a smaller increase in the lymphocytes, and the result in these was less satisfactory.

A. J. BALLANTYNE.

(2) **Guibert**, of La Roche-sur-Yon, refers to a previous article of his on the same subject in the *Clinique Ophtalmologique*, March 25th, 1901; he now repeats the observations then made, and reports three fresh cases. He agrees with Panas that the local lesion is not sufficient to give rise to sympathetic ophthalmia; there must also be a general auto-toxæmia.

In the first case the left eye was injured eight years ago, and was now glaucomatous and very painful. At the time of the accident, it was impossible to diagnose an intra-ocular foreign body, on account of blood in the vitreous, and, later on, the eye looked so normal that operation was not suggested. Three months ago, the eye became red and the cornea dull. Guibert suspected the presence of a foreign body, and his suspicion was confirmed when the eye was enucleated.

The second case was in a young man with a corneal wound and traumatic cataract, which was removed by suction. Vision was 6/24, and the fundus seemed normal; no foreign body was discovered. Two months afterwards, vision disappeared and tension became *minus*, and a retinal detachment was seen. Two years later, the patient returned saying that he had got a foreign body into the stump. On examination, it was found to be an old encysted fragment of metal undergoing spontaneous expulsion. There was never any reaction in the uninjured eye.

In the third case the author removed a small foreign body from the left eye of a child; there was a small hernia of the iris, which was touched with the galvano-cautery. Two months later, the patient returned with a double iridocyclitis. By dilating the right pupil, papillitis could be made out, and sympathetic ophthalmia was diagnosed. The child had a high temperature for three weeks, and both discs eventually became atrophic. P. A. HARRY.

(3) The case reported by **Brav**, of Philadelphia, was that of a woman, aged 60 years, on whom a needling operation was performed four weeks after extraction of cataract. Two weeks later, a plastic iridocyclitis appeared in the "operated" eye, and sympathetic irritation in the other. In about a fortnight the exciting eye was in a shrunken condition, and the other was suffering from sympathetic inflammation. Finally, both eyes were shrivelled and blind. Enucleation of the exciting eye had been refused.

Brav thinks the lesson to be derived from his case is that it is a mistake to do a secondary operation too soon, probably not sooner than six weeks after the primary operation, and certainly not before all redness has disappeared.

A. J. BALLANTYNE.

(4) **Guillery**, of Cologne, published a short work on this subject in the *Klin. Monats. f. Augenheilkunde*, 1911, S. 41. His second article takes up the question of the relation of the bacteria known to be strong fermentation producers to the ætiology of sympathetic ophthalmia.

Guillery first draws attention to statements of F. Deutschmann, who, he says, misses in Guillery's explanation the proof that the inflammation caused by fermentation is able to sustain itself for a long time without a renewed amount of fermentation. Guillery's efforts have been directed to the question whether

it is possible to set up, without bacteriological action, an anatomical picture such as is found in sympathetic ophthalmitis. It is probable that the fermentations from tissue degeneration possess a certain specificity in the sense that a certain ferment, in general, is only able to cause a certain effect. Hence it follows that the enzyme from inflammation or necrosis will manifest only a certain effect. This is well shown in the so-called autolysis of tissues. Guillery quite understood that if he wished to increase the effect, he would have to depend upon renewed fermentation. With the *Staphylococcus quadrigens*, known as a ferment producer, he obtained a fermentation solution which he tested. To a rabbit in the course of thirty-three days six injections in each eye were given. After the third, there developed in the right eye a posterior synechia on the upper border. The eyeball became soft, and presented the picture of a chronic inflammation. The rabbit was killed on the thirty-fifth day, and the following found.—In the left eye the corneal limbus was very infiltrated. In the anterior chamber and in the posterior part of the iris there was a rich fibrinous exudation. Small-celled infiltration was noted in the posterior part of the lens and in the ciliary body. The large vessels of the choroid in all the sections showed accumulations of round cells. In some places they broke through the layer of pigment epithelium. There were also accumulations of single-nucleus cells, among which were a group of epithelial cells. The retina was retained for a short distance only, most of it being embedded in a homogeneous mass, which completely filled the vitreous. From the corneal limbus the infiltration extended far into the conjunctiva, sclera, and muscles. The findings in the right eye are described in similar detail. In all preparations the right choroid was found remarkably thickened. The capillary layer appeared as a light-coloured band between round-celled infiltration and pigment epithelium. Epithelial cells were found everywhere. Near the optic nerve the infiltration in the choroid was specially marked.

Similar experiments with the *Proteus vulgaris* produced a wealth of epithelial cells in the choroid collections. Their change from the chromaphores of the stroma could be followed through all stages.

The results with the *Subtilis ferment* were especially clear, since after a single injection, distinct changes were found. After puncture of the right eye of a rabbit, an effective subtilis ferment was injected. Five days later, the left eye was injected, and the rabbit was killed on the tenth day. There was a clinical reaction of moderate grey pupillary exudation, with diminished tension. The anatomical findings were as follows.—The right corneal limbus was infiltrated and the corneal layers, especially in the peripheral parts, showed moderate cell proliferation. Descemet's membrane, in many sections, had a covering of single-nucleus cells. The iris in its deeper layers was infiltrated, while some of the ciliary continuations were markedly so. The choroid was likewise infiltrated, especially close to the optic nerve. The latter was thickened, the vessels were infiltrated, and often there were found accumulations of round cells in rows. In its anterior part the retina was fairly well preserved. The rods and cones had disappeared, the other layers were irregular and some had large empty spaces. Staining for bacteria gave negative results. Of the choroid of the other eye, Guillery says it was thickly infiltrated. Some sections showed thick accumulations and the passing of excrescences along the course of the vessels into the sclera. In one area there was an accumulation containing epithelial cells. From the border of the choroid the infiltration extended into the papilla and sheaths of the optic nerve. In the latter there were everywhere found rows of endothelial enlargements and round cells. No bacteria were discovered.

A large black and white rabbit, with normal fundi, received, after

puncture of the anterior chamber, 0·03 ccm. of a very active subtilis ferment. One hour later, the cornea was chemotic and the entire pupillary region filled with a grey fibrous exudate. No hypopyon was present, and no fundus reflex. On the second day, the chemosis had diminished. The appearance of the eye on successive days is given. On the nineteenth day, it was very irritable. The rabbit died on the seventy-third day. The ciliary body was found to be infiltrated with cell accumulations, mostly of epithelial character. The choroid was everywhere enlarged and thickly infiltrated. In some places one could follow the change from infiltration to fibrous tissue. One small knot was found made up entirely of epithelial cells. Retinal elements were not recognized. There were no pus cells. The papilla was thickened, and its border was indistinct. No bacteria were found.

A middle-sized rabbit, after the anterior chamber had been punctured, received subtilis ferment in the vitreous. This was followed by severe chemosis, which in the course of some hours' time, extended between the lids. On the second day, the aqueous was dark, and there was an exudation on the pupillary border. The rabbit was killed on the seventh day. In the right eye, there was found much fibrin in both the anterior and posterior chambers. The retina in its lower half was devoid of rods and cones. The ciliary body showed diffuse and in some spots thick infiltration, and in the choroid, round cells were everywhere mixed with the vessels.

Guillery then proceeds to discuss the question of the relation of bacteria to the process. Experiments with vitreous from the rabbit and the horse were tried in the following way.—The eyeballs were washed in sublimate, followed by salt solution. The optic nerve was cut so near the globe that the vitreous presented, and was taken into a sterile retort. It was then inoculated with staphylococcus aureus and incubated for twenty-four hours. The contents were then put through a fine net and bacteria filter, and examined for sterility and fermentation. The latter was always present. This liquid was then injected into the vitreous and gave results similar to those just described in detail. A single injection was sufficient to call forth a remarkable effect in the uveal tract. In an animal killed on the fourth day, the following was found.—The iris in its deeper layers was richly infiltrated. In the anterior part of the vitreous there were accumulations of round cells with a single nucleus The ciliary body was filled with round cells and the choroid was thickened to three or four times its normal width, and the large vessels especially were surrounded with round cells. In some places the pigment epithelium was dissolved and replaced by thick accumulations. The left eye, which was also injected, showed similar changes. With a fermentation solution obtained from the staphylococcus aureus in the vitreous of a horse Guillery made eight injections on each side in the course of two months. After each injection, there appeared a passing reaction, with turbidity of the vitreous, and diminution of the tension. The examination of the globes gave the following.—The choroid was so thickened that it was noticeable macroscopically as a blue line. The iris and ciliary body were thickly infiltrated. The thickened choroid was infiltrated from one end to the other with round cells, and formed a tumour-like mass. The degeneration of the vessels, as described by Fuchs, was clearly seen. There were epithelial cells scattered between the round cells. Only the remains of the retina were found. The optic nerve was swollen, and on each side the infiltration of the choroid extended into the nerve sheaths. No bacteria were found.

The results from *Aureus fermentation* from the vitreous of the horse and from *Pròaigiosus fermentation* are also given.

F. Deutschmann believed he had found the origin of sympathetic ophthalmia in a Gram-positive diplococcus. However, his explanation does not satisfy one that he was describing the disease, which has a characteristic clinical and anatomical picture. He holds that every inflamed spot, no matter how small, in the second eye is sympathetic. Up to the present there has been known in mankind a well-defined form to which the name "sympathetic ophthalmia" has been given. Deutschmann's findings in his animal experiments do not correspond with this. It would be certainly interesting if this micro-organism could originate a transmission of disease from one eye to the other, but this would not help us much in clearing up the subject in the human being.

Guillery considers it proved by his experiments that (1) there are poisons which, when brought into a rabbit's eye, will cause a uveitis very similar to sympathetic ophthalmia; (2) it is possible from the blood-stream to cause an irritation state in the eye, in a purely toxic way, and not only in the sense of anaphylaxis in a diseased organ but also in a healthy one.

From all this it seems to the reviewer that a new basis has been found for experimental research in sympathetic ophthalmia. HANFORD MCKEE.

(5) The migratory theory of sympathetic ophthalmia has been contested on the ground that there is seldom either pathological or clinical evidence of meningeal or cerebral complications, such as one would expect if it were true; but cases have recently been recorded in which there was evidence of meningitis and in some of these defect or loss of hearing was also present. Including the present one, six cases of this kind have been reported.

Considering all the evidence, **Peters**, of Rostock, thinks that there are not sufficient grounds for the assumption of a cerebral origin for the deafness in these cases. Nor does he agree with the view that it may be due to a toxic affection of the auditory nerve. His theory is that it is due to a disturbance of the pigment of the labyrinth. He refers to the theory of Elschnig and Kümmel, that sympathetic ophthalmia is an anaphylactic phenomenon, in which there is "sensibilisation" of the ocular pigment, and he thinks it possible that the labyrinthine pigment may undergo the same change. As related facts, he points to the deafness of albinotic cats and dogs due to absence of pigment from the labyrinth, and to the whitened cilia which sometimes appear in sympathetic ophthalmia, either on the exciting or on the sympathising side. The theory he suggests is consistent with the bilateral character of the deafness, and with the fact that it is, like the ophthalmia, benefited by enucleation of the exciting eye. A. J. BALLANTYNE.

(6) **Pechdo,** of Villefranche-de-Ronergue, quotes Panas in support of the opinion that the exciting eye should not be enucleated if it possesses any vision. The inflammation in the second eye would not be arrested by excision of the exciting eye; on the other hand, it would be aggravated by it. He mentions two cases, however, one in which the eye was not removed, and notwithstanding medical treatment, both eyes were lost; the other in which the exciting eye was removed, with good results. Recently, he has had a patient under treatment who lost the right eye after a severe contusion; there was subconjunctival rupture of the globe, with dislocation of the lens; the eye remained painful, and seemed an eye that would give rise to sympathetic disease. Some months after the injury, the sight of the left eye rapidly became worse, and Pechdo was able to make out a neuro-retinitis. Enucleation of the exciting eye, followed by energetic mercurial treatment, succeeded in arresting the disease.

The author still has under treatment a man whose right eye was injured and the sight destroyed some years before; examination revealed several

synechiæ of the left iris, and small deposits on the lens. The right stump was removed, and atropine cautiously used to the left eye. The pupil dilated readily after the excision, although the atropine had no effect on it before. The condition of the eye continued to improve without the use of mercury.

Pechdo remembers another case where a patient lost an eye by an injury from a cow's horn, and sympathetic iritis developed. The disease was aborted by removal of the injured eye.

The prognosis of the plastic or malignant cases is grave. In this event it were better to remove the sympathising rather than the exciting eye.

P. A. HARRY.

(7) **Franke,** of Hamburg, observes that the diagnosis that an iridocyclitis is one likely to cause sympathetic ophthalmia is generally a guess, a probability only. If Gradle's view be correct, *viz.*, that this type of inflammation is associated with a lymphocytosis, then we have a valuable aid in coming to a correct conclusion. Franke states that Gradle's opinion has been confirmed by Jones and Browning, who also suggested that the lymphocytosis was present because the cause of the disease was a protozoon. Gilbert, on the other hand, has made an examination of the blood in every case before an eye was enucleated, and has often found a lymphocytosis up to 50 per cent. He has, however, discovered no difference between the blood-states in an ordinary traumatic uveitis and the dangerous form. The lymphocytosis, in his opinion, is caused by an infective process in the interior of the eye, but it is not diagnostic of the sympathetic form. Elschnig says the same. Franke has investigated the question carefully in over 50 cases. He finds that lymphocytosis may be present in early cases of severe injuries to the eye, both when they heal without inflammation and when severe iridocyclitis follows. The same blood picture is present in cases of old perforating wounds of the cornea and of severe contusions—conditions which do not lead to sympathetic ophthalmia. The same is true of old perforations of the sclera, which have been present for years without any signs of irritation—cases which are unlikely to cause sympathetic ophthalmia. The presence or absence of a lymphocytosis after severe perforating accidents to the eye has no diagnostic or prognostic value with reference to the development of a sympathetic ophthalmia.*

T. HARRISON BUTLER.

(8) To the cases of sympathetic ophthalmia treated with tuberculin and recently reported by Bernheimer and Zirm, **Stoewer,** of Witten, adds the following two:

i. A miner, of twenty-one years, was admitted on March 8th, 1911, because his sight had failed so much that he was unable to do his work. In the right eye, there was found episcleral injection, and at the limbus a scar of 3 mm. The cornea was slightly opaque, the iris above was adherent to the limbus scar and below to the anterior lens capsule. Vision = 2/60. In the left eye, there was ciliary injection, and the whole border of the iris was adherent to the lens capsule. There were opacities in the vitreous, and the vision was equal to 4/60. There was no doubt that the condition of the right eye was due to a perforating wound, and, when questioned, the patient gave a history of having had his right eye injured on 1st January, 1911. There was no doubt also that the creeping iridocyclitis of the left eye was of a sympathetic nature. The patient was treated in the usual way, with complete rest, inunctions, and scopolamine drops, but without improvement. On April 24th, 1911, the patient received a diagnostic tuberculin injection, which was followed by a

*Frank and Gradle both fail to separate a lymphocytosis into its constituent items, namely, increase of the mononuclear cells and of the small mononuclear cells. Browning has shown that the former are increased in sympathetic ophthalmitis.—T. H. B.

distinct general and some local reaction. Treatment with tuberculin was then followed out until the patient insisted upon going home on June 10th, 1911. On November 5th, 1911, he again entered the Hospital, and tuberculin, in small doses and at long intervals, was given. The treatment was followed until the next spring, and in the final result the eye remained quiet, with vision of 4/35.

Had we to deal here with a case of sympathetic ophthalmia, asks Stoewer? The perforating injury of the right eye, followed by a fibrinous uveitis, and a beginning uveitis in the other eye, about six or seven weeks after the injury, favour this conclusion. In such cases it is often impossible to decide, from the clinical symptoms, whether the case is one of sympathetic ophthalmia in a patient with tuberculosis, or one of tuberculous uveitis, caused by trauma. The failure of node-like prominences on the iris, or of local reaction of the eye by subcutaneous diagnostic injection, does not exclude tuberculous uveitis. In this case a remarkable improvement appeared only after the tuberculin was regularly used.

ii. A female patient, aged 56 years, had been operated upon for cataract two years previously. The operation went smoothly. During convalescence, however, an iridocyclitis developed, which would not yield to treatment, and after some weeks, an iridocyclitis developed in the other eye. When seen first by Stoewer, the left eye showed a small iris coloboma, a small pupil, in which there was a thick grey membrane. No good light projection. On the right side there was a ripe cataract with a tough opaque capsule. Projection good. On September 9th, 1911, the cataract was extracted with an iridectomy above. Three days later, some ciliary injection, followed by injected iris and opaque cornea. In spite of energetic scopolamin treatment and warm compresses, the pupil became smaller, and blood and fibrin appeared in the anterior chamber, and there was pain. The Wassermann reaction was negative. A puncture of the anterior chamber was made, followed by potassium iodide and inunctions of mercury. The eye quieted down, and, later, an iridectomy, followed by a discission, was performed. Soon after, ciliary injection again appeared, with numerous deposits on Descemet's membrane. A diagnostic tuberculin injection produced a general and local reaction, so that treatment with bacillary emulsion was begun, and the inunctions were stopped. The final result was a quiet eye, with vision equal to 2/60.

This case was thought to be one of sympathetic disease, but in Bonn, where the first operation was performed, the double-sided uveitis was looked upon as a tuberculous one, an opinion with which Stoewer agrees. The success of the tuberculin treatment here was remarkable. While it was feared for some months that the right eye would be ruined, as the left was, by iridocyclitis, an improvement appeared immediately with the tuberculin treatment.

Stoewer says these two cases illustrate, first, how similar sympathetic ophthalmia and tuberculous uveitis may be; and, secondly, in inflammatory diseases of the uvea, one should bear in mind the possibility of a tuberculous origin, even although the clinical picture shows nothing typical of tuberculosis.

HANFORD MCKEE.

(10) In every operation upon the eye, according to **McReynolds**, of Dallas, Texas, the possibility of sympathetic ophthalmitis must be borne in mind. He recalls the fact that the late H. Knapp, of New York (who held in America the highest record for successful cataract extraction) estimated that the disease occurred once in every 750 operations undertaken by him. In examining the various specimens of eyes that had caused the disease, preserved in the museum of the Royal London Ophthalmic Hospital, McReynolds found that one-half of the total number could be traced to some form of operation. Contrariwise, he has been impressed by the fact of the

small number of cases that have resulted from the retention of a foreign body within the globe. Most of the cases have resulted from wounds, accidental or surgical.

Briefly stated, some of the more important conclusions reached by McReynolds are as follows.—Of the five or ten cases likely to be encountered by the busy eye surgeon during his lifetime, 10 per cent. will occur from a retained foreign body, 20 per cent. from operations upon the globe, and 70 per cent. from accidental injuries to the eye. Enucleation is safer than any of its substitutes as a preventive of the disease. No operation, however, is infallible. An hopelessly injured eye should be removed forthwith. If an injured eye means to do well, it will probably give indications of this within two or three weeks. A blind eye, subject to recurring attacks of inflammation, should be enucleated. The conservatism necessary to reduce the incidence of sympathetic ophthalmitis, if followed injudiciously, would result in the sacrifice of many eyes, the sight of which could be saved. Lastly, whenever an eye has sustained a penetrating wound (accidental or designed), the patient should be fully informed of the possibilities, and, as McReynolds very shrewdly suggests, a dictaphone will be found efficient and convenient for the purpose! SYDNEY STEPHENSON.

VIII.—REMEDIES.

(Ninth Notice.)

1. Coulomb, R.—An eyebath for the anophthalmic. *L'Ophtalmologie Provinciale*, août, 1912.
2. Browning, S. H.—The importance of examining the fæces and urine in eye diseases. *Ophthalmic Review*, April, 1913.
3. Janson, E.—The influence of anti-diphtheritic serum on the course of infective diseases of the eye. (Ueber den Einfluss des Diphtherieheilserums auf den Verlauf von infectiösen Augenerkrankungen.) *Klin. Monatsbl. f. Augenheilkunde*, Mai, 1913.
4. Agricola, B.—A papilloma of the cornea and conjunctiva, which had recurred five times, cured by Mesothorium. (Fünfmal rezidiviertes Papillom der Binde- und Hornhaut, geheilt durch Mesothoriumbestrahlung). *Klin. Monatsbl. f. Augenheilkunde*, Mai, 1913.
5. Norman, Alfred C.—Electricity in ophthalmic practice. *Hospital* June 21st, 1913, p. 359.
6. Chaillous, J.—On the treatment of sympathetic ophthalmia with Salvarsan and Neosalvarsan. (Du traitement de l'ophtalmie sympathique par le Salvarsan et le Néosalvarsan.) *Ann. d'Oculistique*, juin, 1913.
7. Darier, A.—Subconjunctival injections of Neosalvarsan. (Injections sous-conjonctivales de Néosalvarsan.) *La Clinique Ophtalmologique*, 10 juin, 1913.
8. Chatterton, Edgar.—A case of double tubercular iritis. *Proceedings of the Royal Society of Medicine*, June, 1913.
9. Manolesco, D. N.—On two cases of sympathetic ophthalmia improved by Salvarsan. (Sur deux cas d'ophtalmie sympathique améliorés par le Salvarsan.) *La Clinique Ophtalmologique*, 10 juin, 1913.

(10) **Grandclément.**—Cure of an enormous epibulbar epithelioma by the use of X-rays and radium. (Guérison d'un vaste épithélioma épibulbaire de l'œil par l'emploi des rayons X et du radium.) *La Clinique Ophtalmologique*, 10 juin, 1913.

(11) **Dutoit, A.**—Therapeutic experiences with Lipojodin in certain diseases of the optic nerve and retina. (Therapeutische Erfahrungen mit Lipojodin bei einigen Erkrankungen des Sehnerven und der Netzhaut.) *Zeitschrift für Augenheilkunde*, Juli, 1913.

(12) **Dutoit.**—Experiences with Physostol. (Erfahrungen mit Physostol.) *Zeitschrift für Augenheilkunde*, August-September, 1913.

(1) The various manipulations in connection with the wearing of a glass eye often lead to infection of the socket, for the treatment of which an eyebath is usually recommended. **Coulomb,** of Paris, gives an illustration of a special eyebath that is advantageous under these circumstances. Ordinary eyebaths depend on the presence of the eyeball for their usefulness; after enucleation, the lotion is apt to escape over the patient's cheek. In order to get the support required from the orbit, the eyebath suggested by Coulomb has a larger opening than usual, about five or six centimetres in diameter, and the rim is protected by a covering of rubber. P. A. HARRY.

(2) This is a plea by **Browning,** of London, for more frequent examination of the excreta, especially in those cases where the cause is not obvious, as irido-cyclitis and some cases of keratitis. He mentions instances of eye trouble in people, found to be suffering from colitis and cystitis, where the eye and other affection have benefited by the use of an autogenous vaccine. A. H. PAYAN DAWNAY.

(3) **Janson**, of Dorpat, points out that the claims of certain authors to have cured iritis, infected wounds, pseudo-membranous conjunctivitis, suppuration of the lacrymal sac, and ulcus serpens by the so-called "paraspecific" serum therapy, are based on purely clinical grounds and are not supported by experiment. According to Janson, even the clinical material, as published, especially by Darier, does not support the claims made on behalf of paraspecific therapy. He reviews in detail the opinions of different authors as to the supposed facts and their interpretation of them, and has some pretty hard things to say about the therapeutic enthusiasts who are too apt to find what they wish to find. His own work on the subject consists, firstly, of a series of animal experiments in which he estimated the opsonins, agglutinins, and power of complement deviation for certain organisms, in the blood of animals which had been treated with non-specific serums. The results were entirely negative. He adds, in the second place, the results of treating a number of cases of ulcus serpens with anti-diphtheritic serum, avoiding, as far as possible, confusion from the use of other forms of treatment. His results are opposed to those of Darier and his followers. Neither animal experiments, nor his review of the clinical results obtained by others, nor his own clinical trials, support the current view as to the value of paraspecific serum therapy. Diphtheritic serum is a quite untrustworthy method of treating ulcus serpens. At the most, it is an aid to other treatment, and even that is not proved. It is quite unjustifiable to omit other treatment in its favour. A. J. BALLANTYNE.

(4) The papilloma in this case by **Agricola**, of Hannover, was a small nodular tumour situated at the outer border of the cornea, soft, and freely movable. It was removed by the knife and cautery, and microscopic examination showed it to be non-malignant. It recurred on five occasions. It was removed

by the knife, and on each occasion, except the last, the cautery was also used. On the last occasion removal was followed up by the application of mesothorium radiferum. Five mg., equal in activity to one mg. of radium bromide, was applied three times daily, in such a way as to give about half a minute to each part of the surface. After six days' treatment, and an interval of a week, two further series of similar treatments were given. The result was a complete cure, maintained ten months after cessation of the treatment.

A. J. BALLANTYNE.

(5) **Norman,** of Durham, in the course of a series of articles on "Electricity in Modern Medicine," devotes a section to its uses in ophthalmic work. Apart from the treatment of eye disease, electricity is employed (1) as a source of illumination; (2) to furnish X-rays; (3) to excite powerful electro-magnets: and (4) for ionic medication of corneal ulcers, rodent cancer, and lupus of the eyelids, etc. Incidentally, he waxes enthusiastic as to the advantages of the Morton-Marple electric ophthalmoscope, for "with this instrument it is as easy to make a detailed examination of the fundus oculi as it is to look into a room through the window." In fact, beginners acquire as much facility in one day as they would previously have taken three or four years to acquire with the older reflecting instrument. He has found the method of localising foreign bodies in the eye, described by Holth in THE OPHTHALMOSCOPE (Vol. IX, 1911, p. 550), at once simple and satisfactory.

SYDNEY STEPHENSON.

(6) **Chaillous**, of Paris, reports the following cases.—1. Sympathetic ophthalmia in the left eye, of three days' duration, coming on six weeks after a perforating injury of the right eye with a piece of metal. Two intravenous injections of 0·3 centigrammes of Salvarsan were given, and in three weeks, the symptoms had disappeared, and the vision, which had been reduced to 2/10, was normal. 2. Very severe sympathetic ophthalmia in the right eye, of about six days' duration, coming on one month after a perforating wound of the left sclerotic. The exciting eye was excised; a subconjunctival injection was given in the sympathising eye, and, in addition, five intravenous injections of 0·30 centigrammes of Neosalvarsan were administered in the course of six weeks, with the result that the patient, whose vision had been reduced to perception of light with good projection, was discharged at the end of 2½ months with a vision of 2/10.

Chaillous considers that these two cases, especially the last-named, are conclusive as to the value of Salvarsan and Neosalvarsan in the treatment of sympathetic ophthalmia, and quotes with approval a suggestion made to him by Thibierge, namely, that prophylactic injections of one or other of these drugs might prove useful in cases in which the onset of sympathetic trouble was feared.

R. J. COULTER.

(7) **Darier,** of Paris, has been trying the use of subconjunctival injections of Neosalvarsan in various cases of keratitis and choroidoretinitis, and in a case of detachment of the retina. The results are not very encouraging, for the author points out that of eleven cases it is only possible in four at the most to attribute a favourable action to the method. The treatment is apt to be very painful.

ERNEST THOMSON.

(8) **Chatterton**, of London, reports a case of tuberculous iritis which improved under the repeated injection of a constant dose of tuberculin, T.R. 1/5000 mg.

ERNEST THOMSON.

(9) **Manolesco**, of Bucharest, refers to the literature on the use of Salvarsan in sympathetic ophthalmitis, a literature which shows considerable divergencies of opinion, and then relates two cases of his own in which this treatment seems to have determined at least an improvement. In accordance

with the findings of different authors, and with his own experience, Manolesco cannot consider that Salvarsan is a curative agent in this disease, although it often has a favourable influence. The question, why Salvarsan sometimes does good and sometimes not, remains as yet unanswered.

ERNEST THOMSON.

(10) In the case reported by **Grandclément**, of Lyons, a large tumour seated upon the inner half of the right eye melted away in one month under the influence of *X*-rays. Soon afterwards, a small tumour appeared on the upper lid. It was treated by radium, and was got under control in eight days. In spite of the title of the article, the exact pathological nature of this neoplasm is not certain. The author assumes that it was derived from a nævus (*d'origine nævique*), and refers to the work of Clunet and Offret who have recently examined and treated eight cases of epibulbar epithelioma at the Quinze-Vingts. Of these eight cases, six were nævic epitheliomata, one was a spino-cellular (*spino-cellulaire*) epithelioma, and one a dermo-epithelioma. These authors say of the epibulbar tumours which they thus examined at the Quinze-Vingts: they appear between 40 and 55 years; they almost always have the structure of nævic epitheliomata; they develop very slowly at first but progress rapidly as soon as the tumour becomes prominent. Histologically, the tumours are malignant and recurrence after excision is frequent; they are, however, rarely followed by generalization or by metastasis. In short, the indication is to remove them as soon as possible.

Grandclément points out that Clunet and Offret have mentioned the value of *X*-rays, and considers that his own is the first case of severe epibulbar epithelioma which has been attacked and cured by radio-therapy.

ERNEST THOMSON.

(11) **Dutoit,** of Montreux, is indefatigable in writing upon the latest products of the pharmaceutic chemist. His efforts in this direction cannot fail to interest those ophthalmologists who are fond of trying new drugs, nor, we may assume, can they be altogether distasteful to the firms who manufacture them. Lipojodin is an iodine compound with neurotropic properties. Dutoit has used it in cases of optic neuritis and in senile changes at the macula, with very favourable results. T. HARRISON BUTLER.

(12) **Dutoit,** of Montreux, still writes of new drugs. This time it is Physostol, which is a 1 per cent. solution of pure physostigmine in absolutely anhydrous olive oil. It is dispensed in a bottle, which acts as an aseptic drop bottle. It has proved useful in glaucoma, before and after operation. It causes no irritation, and allows us to use eserine in a pure and stable form in accurate dosage. T. HARRISON BUTLER.

CORRESPONDENCE.

[While THE OPHTHALMOSCOPE will at all times welcome correspondence from its readers, the Editor does not hold himself responsible for any views expressed in this column.]

THE PRESENT POSITION OF OPHTHALMOLOGY.

To the Editor of THE OPHTHALMOSCOPE.

SIR,—Referring to Mr. Sydney Stephenson's paper read at the Ophthalmological Congress at Oxford *re* the "Optician" question, I would ask you to be good enough to allow me to make some comments on it.

I agree with him, Sir, that the qualified optician in this country has "come to stay."

It being admitted that opticians are necessary to the public, and that qualified opticians are better than those who merely sell spectacles, it follows that the best results must obtain (*a*) from inducing those who sell spectacles to refer them on scientific lines, and also (*b*) by instructing them how to recognise cases which are beyond their scope and which should be treated by the surgeon-oculist.

The small provincial towns and villages cannot support opticians, pure and simple, and the sale of spectacles has always been a part of the jeweller's or chemist's business; so that it is far more reasonable, and better for the public, that these should be qualified.

The danger of optical certification would lie, not in educating those who carry on the optical trade, conducted in open shops, but in raising up a new class of semi-professionals who, to the public, would not materially differ from the medical man, and who might claim equality with, or even superiority to, the general medical practitioner in matters connected with the eye.

The Spectacle Makers' Company, of which I have the honour of being a member, has always had in view the establishment of a Guild of scientific craftsmen and tradesmen, and has set its face strongly against quack professionalism.

I may add that if the optical trade is scientific, then chemists who have had a scientific training and passed fairly stiff examinations, are better adapted to carry on that trade than any other class of tradesmen that I know; more particularly as such eminent men as Professor Silvanus P. Thompson, F.R.S., D.Sc., etc., Dr. C. V. Drysdale, and oculists of the front rank, are examiners, and the Right Hon. Sir William Hart Dyke, Bart., M.A., D.L., etc., late President of the Board of Education, is the Director of Examinations.

This controversy is not a new one, and unless a law is passed by Parliament enacting that no one, other than a qualified medical man, shall prescribe glasses for defective eyesight, the controversy will continue; but I doubt that this will ever occur, and I further think that it would be contrary to the public welfare; for the sale of spectacles is a perfectly legitimate trade, and no amount of cheap sarcasm or ridicule will arrest it.

I am, Sir,
Your obedient Servant,
SEYMOUR TAYLOR, M.D.

16, SEYMOUR STREET,
PORTMAN SQUARE, W.
September 24th, 1913.

To the Editor of THE OPHTHALMOSCOPE.

SIR,

In your last issue you publish Mr. Sydney Stephenson's paper which he read at the Oxford Ophthalmological Congress, and from that paper I am pleased to learn that it is now recognised that there is a large body of opticians who, by general and technical education, and who by adopting a code of ethics somewhat similar to those observed in our profession, have come to be more or less respected by a section of the medical profession which was bitterly antagonistic to the whole body of opticians because of the ignorance and blatant assertion of the few. There is nobody more anxious than the opticians themselves to have their business methods and principles regulated by statute, and for penalties to be imposed. My experience and observation have led me to conclude that the educated optician, while in limited but legitimate competition with the ophthalmic surgeon, is satisfied that his functions are

limited, and is ever ready to refer to the surgeon those cases which are beyond the scope of his trade or practice.

Mr. Stephenson remarks that few medical men appear to be as conversant as would seem desirable with the "Optician Question." It appears, however, that he himself is not conversant with one part of that question with which he deals, for he speaks of the Spectacle Makers' Company as a concern, inert as compared with the British Optical Association, and from which "as little is to be hoped as it is to be feared," and that "it lays itself out to manufacture the chemist-optician."

Opticians who hold the diploma of the Worshipful Company of Spectacle Makers, of which I have honour to be a Liveryman, number over a thousand, and to obtain that diploma they have had to pass such an examination as would, in the section of visual optics alone, stagger ninety per cent. of your readers either at the present moment or when they were fresh from their final schools, either University or Collegiate. The senior examiner is Professor Silvanus Thompson, and this fact is sufficient evidence of the character of the examination. I have to-day been enabled to peruse a complete prospectus of the Spectacle Makers' examination scheme, and the agreement between the Company, and the candidates for the diploma, and Mr. Stephenson's reference to the "Chemist-optician" is not an intelligible one. It appears that the diplomates are, under penalty of withdrawal of the diploma, proscribed from using any drug, or from testing the vision while it is under the influence of any drug, unless it has been administered by a medical practitioner, and that they must refer to a surgeon cases in which tests do not result in accurate estimate of the refraction, or in which disease may be suspected, or in which acuteness of vision cannot be satisfactorily corrected, also all cases wherein there appears to be symptom of disease.

Such a class of opticians as is "manufactured" by the Spectacle Makers' Company has come to stay; certainly, as Mr. Stephenson says, little is to be "feared" from them, but, on the contrary, I feel convinced that mutual advantage will develop from a little co-operation.

I am, etc.,

H. G. CRITCHLEY, M.A., M.D.

55A, WELBECK STREET, W.
23rd September, 1913.

SCLERECTOMY AND SCLEROSTOMY.

To the Editor of "THE OPHTHALMOSCOPE."

DEAR SIR,

The term sclerostomy has been used lately by one or two authors to designate in a general way the operation designed to provide a subconjunctival escape for the intra-ocular fluids, when the pressure is too high. Sclerostomy, however, is an unfortunate word. It means an impossible operation and has no parallel in surgery. Gastrostomy and colostomy do not correspond to it. It is not the sclera, of course, a solid structure, which we wish to provide with a mouth or "stoma," but the eye, just as others have provided a stoma for the stomach and not for some part of its wall. Lovers of new terms will find "ophthalmos" to their hand. And what more beautiful than "ophthalmostomy!" But what is the matter with "sclerectomy" and "trephining"?

I am, Yours faithfully,

PERCIVAL J. HAY.

SHEFFIELD, *October 4th*, 1913.

BOOK NOTICES.

Bericht über die Neununddreissigste Versammlung der Ophthalmologischen Gesellschaft, Heidelberg, 1913. Wiesbaden: Verlag von J. F. Bergmann. 1913.

A cordial welcome to the thirty-ninth *Bericht* of the Heidelberg Ophthalmological Society, one of the most important and valuable of all periodical ophthalmological publications. The present volume closely resembles its predecessors as regards *format*, while as regards contents, they fully maintain the standard that we have been taught to expect from the *Bericht*. One notes with approval that the volume is provided with a *Namenregister* and with a modest *Sachregister*.

Transactions of the American Ophthalmological Society, Forty-Ninth Annual Meeting, Washington, D.C., 1913. Vol. XIII, Part ii. Philadelphia: American Ophthalmological Society, 1913.

This substantial volume of 317 pages (which has just reached us) represents the proceedings of the 49th annual meeting of the American Ophthalmological Society, which was held in May last at Washington, D.C. It is freely illustrated in black and white and in colours. Its more important contents will be abstracted in due course in the columns of THE OPHTHALMOSCOPE. In the meanwhile we may be pardoned for pointing out that its contents would be made more accessible to readers were an index appended.

Diseases of the Eye. By G. E. DE SCHWEINITZ. Seventh edition. London and Philadelphia: W. B. Saunders and Co., Henrietta Street, W.C. 1913. Price, 21s. net.

The fact that this book has reached its seventh edition is more than enough to indicate a demand on the part of medical practitioners for such a volume.

It is amply illustrated, the coloured plates being exceptionally fine. In this edition the recent discoveries and observations of the last three years have been incorporated, necessitating the inclusion of a considerable amount of new matter. Special paragraphs appear on such subjects as the Schiötz tonometer, trephining of the sclera, angiomatosis retinæ, etc. Vaccine therapy and the use of Salvarsan in ocular disorders are also dealt with.

The book is especially valuable to the practitioner of medicine rather than the undergraduate, and it must (and evidently does) command a wide circle of readers desirous of making themselves familiar with recent and authoritative work on diseases of the eye.

Altogether, the book is thoroughly good and will serve admirably the purpose for which it is intended. J. P. N.

The American Encyclopedia and Dictionary of Ophthalmology. Edited by CASEY A. WOOD, M.D., C.M., D.C.L., assisted by a large staff of collaborators. Volume I, A to Azioviolett. Chicago: Cleveland Press. 1913. Price, cloth, $6.00 per volume.

The first volume of *The American Encyclopedia and Dictionary of Ophthalmology*, edited by Casey A. Wood, is now in our hands. To appraise

or to criticise an encyclopedia of any kind without having had the whole of it in daily use for a considerable time is hardly a feasible proposition. It is possible only to give an outline of this large and important work in accordance with the Introduction and with a more or less casual turning over of the pages as yet published, namely, from A to Azioviolett. This latter word may be presumed to exhaust the letter A.

This first volume contains 727 pages royal octavo. From it we gather that the work is to be a dictionary of ophthalmic medical terms, a biographical dictionary of ophthalmologists, and an encyclopedia of eye diseases, all rolled into one. Strict alphabetical order is followed, so that here and there one finds pages that are purely dictionary pages, followed by a more or less lengthened article on some special subject. With this arrangement one can find no fault: it makes for simplicity.

The editor has not hesitated to include articles of such wide scope that each might form the groundwork of a text-book. Thus, the Gross Anatomy of the Eye, by Shasted, occupies 71 pages with over 60 illustrations, eight of the latter being full-page coloured plates. Anæsthesia in Ophthalmic Surgery, by the editor, occupies 37 well-illustrated pages.

Under the letter A is included an interesting article by Ellett (46 pages) on the After-treatment of Ophthalmic Operations. One might be inclined to query the wisdom of classifying this apart from the word *operation*, yet doubtless when we reach the letter O we shall find a cross reference to this article. Further, in the beginning of the volume there is a list of the more important articles to be found in it, so that the reader who is puzzled to know under what head to seek the information he requires, may get a hint from a perusal of this list.

The editor, in the Introduction, makes two important promises.—The one is that there shall be ample cross references, the other that omissions shall be dealt with in an Appendix. We hope these promises will be fulfilled in a generous spirit. No work of such magnitude as this can escape from the probability of omissions. Indeed, the reviewer was so unfortunate as to stumble across an omission of an important subject, cross referred to another article which, as a matter of fact, does not in any practical sense deal with it at all.

As has been said already, we do not wish to deal critically with the volume before us. When the whole set of volumes is complete, it will be time to endeavour to crystallise one's opinion. Yet from the style of this first volume, it seems likely that the complete work will be one of the most valuable literary possessions of the ophthalmologist, more particularly, perhaps, of the English-speaking ophthalmologist. We look forward to the advent of future volumes with the utmost interest. ERNEST THOMSON.

Guide to the Microscopic Examination of the Eye. By Professor R. GREEFF, with the co-operation of Professor STOCK and Professor WINTERSTEINER. Translated from the third German edition by Hugh Walker, M.A., M.B., C.M. London: The Ophthalmoscope Press, 24 Thayer Street, W. 1913. Price, 7s. 6d.

Dr. Hugh Walker's translation of Greeff's *Guide* has appeared in serial form in the columns of THE OPHTHALMOSCOPE, and is now republished as a book. It will be very welcome to those interested in the pathology of the eye. It contains, in brief and very readable form, an account of the more important ways of handling material for the microscope. A successful

attempt has been made to bring together such matter as may prove specially useful to the ophthalmologist. The translation is so well done that nobody would imagine it had ever been written in any language other than English. It is well printed. SYDNEY STEPHENSON.

Abstract-Bulletin of the Physical Laboratory of the National Electric Lamp Association, Cleveland, Ohio. Vol. I, No. i. EDWARD P. HYDE, Director.

We have received the first number of this rather interesting publication. It contains an abstract of every research carried out in the Laboratory from its inception (1908) to 1912. The abstracts, written by the authors of the original papers, are fully illustrated in the hope that to all, except those specially interested in the details of the investigation, they may be satisfactory substitutes for the original papers.

The idea strikes one as distinctly good. Within the short compass, 127 pages, one finds the substance of twenty-eight individual researches. Some of these researches are of interest to the ophthalmologist. One notes articles on "A Visual Acuity Test Object," by Ives; "The Influence of the Illumination of the Eye on Visual Acuity," by Cobb; and "The Dependence of Visual Acuity on the Wave-length of Light," by Luckiesh. The numerous illustrations help the reader to obtain from the study of an abstract a good idea of the original work. ERNEST THOMSON.

Précis d'Ophtalmologie. Par le Dr. V. MORAX, ophtalmologiste de l'Hôpital Lariboisière, Paris. Deuxième édition refondue. Paris: Masson et Cie., 120, Boulevard Saint-Germain. 1913. Prix, 14 fr.

Dr. Morax's second edition, which has recently been published, has been brought thoroughly to date. For example, it includes descriptions of sporotrichosis as it affects various parts of the eye and of its appendages. Morax lays stress upon the necessity of recognising that the ocular mucous membrane may form one channel whereby the *S. Beurmanni* may enter the system, so that the infection may be cut short by the administration of large doses of potassium iodide internally. Under those circumstances complete cure may be brought about in the course of a few weeks. The lesions, of course, must be distinguished from those of syphilis, and especially of tuberculosis. Morax points out that in cases of chancre of the conjunctiva the *Treponema pallidum* may always be found in the lacrymal secretion. His remarks upon the diagnosis of syphilitic iritis are very much to the point. He holds that the number of cases where the initial sclerosis or the cutaneous manifestations have been overlooked is infinitely more considerable than has been believed, and that such things as pains in the joints may be due to syphilis. A positive Wassermann furnishes us with an element of great probability as to the specific origin of the eye condition. On the other hand, it is an absolute rule to draw no conclusions from a negative result. The diploscope is fully explained. Instrumental tonometry is touched upon, and speaking of the Schiötz appliance, Morax tells us that it is nowadays indispensable to the clinical worker. He regards tensions of between 16 mm. and 25 mm. of mercury as normal, while those of from 25 mm. to 40 mm. are not always accompanied by symptoms of irritation. Readings of from 40 mm. to 100 mm., however, correspond to high tension, with its effects. Attention is paid to the

newer operations for glaucoma, but Morax holds that the surest plan of treating acute glaucoma is by iridectomy. The account given of Elliot's operation of trephining is not that now recommended by its distinguished author, and has probably been obtained by Morax from one of Elliot's earlier publications. By the way, the figures given to illustrate Herbert's sclerotomy are the clearest that we have so far seen.

For a book of this class, primarily meant for the general practitioner of medicine, quite an elaborate account is given of partial keratoplasty, probably because a good deal of the recent work on that operation has been carried out at the Lariboisière, to which Morax is attached. Morax turns Magitot's observation to practical use. It will be remembered that Magitot found that the cornea and media remained transparent for from ten to twelve days if the eyes were kept in rabbits' serum at a temperature between 0° and 4° C.

The book includes twenty-four coloured figures, arranged as four plates, of the fundus oculi and its disorders. They touch a good modern standard. In addition, the volume has no fewer than 427 figures in the text. From an artistic point of view, many of these leave a good deal to be desired, although they are realistic enough in all conscience. As examples, we may mention Nos. 3, 8, 12, 13, 18, 20, 21, 22, 23, 25, 31, 33, 41, 61, 93, 106, 148, 169, 414, and 415.

This admirable *Précis* is provided with an adequate index.

SYDNEY STEPHENSON.

Compendium of the Pharmacopœias and Formularies (official and unofficial) with practical aids to prescribing and dispensing. By C. J. S. THOMPSON. Fourth edition. London: John Bale, Sons, and Danielsson, Ltd. 1913. Price, 5s. net.

This handy little *omnium gatherum* reminds one as regards appearance of the earlier editions of Martindale's "Extra-Pharmocopœia." We have found it to be a most useful compilation.

E. Merck's Annual Report. 1912: Vol. XXVI. 1913.

Merck's *Annual Report* for the year 1912 (Volume XXVI) resembles its predecessors in all essential points. A limited number of copies of the present volume will be sent to medical men on application to 66, Crutched Friars, London, E.C. The book is also obtainable from booksellers at 1s. 6d. per copy.

NOTES AND ECHOES.

Deaths.

A MAN of many parts, Tempest Anderson, died recently at sea from enteric fever on his way home from the Philippines, at the age of 66 years. After taking his degree and spending a term abroad, Anderson returned to his native city of York, where he was appointed ophthalmic surgeon to the York County Hospital. He was a J.P. for the city, and in the year 1894 he held the office of sheriff. Some ten years later he retired from active practice, and devoted his attention almost wholly to the study of volcanoes and earthquakes, in

connection with which his name was already widely known. He was appointed Tyndall lecturer at the Royal Institution, London, choosing as his subject volcanoes. Anderson, despite his scientific activities, found time to take a deep interest in the housing problem and in the preservation of open spaces movement. He was a prominent member of the Alpine Club, and a photographer of no mean abilities. He was unmarried.

John Albert Nunnerley, who for a period of thirty years was ophthalmic surgeon to the Leeds General Infirmary and surgeon to the Leeds Eye and Ear Infirmary, died on August 21st last. He had written on Conical Cornea and Lacrymal Obstruction, but had retired from practice for many years before his death. It is now announced that he left estate of the gross value of £55,556, with net personality sworn at £49,605. On his wife's death he left £100 to the United Kingdom Beneficent Association, and the ultimate residue of his property, estimated to amount to about £45,000 before deduction of legacy duty, two-thirds to the Leeds General Infirmary and one-third to the Mineral Water Hospital, Bath, of which he was a governor at the time of his demise.

We regret to announce the death of Duff W. Greene, which took place suddenly at Dayton, Ohio, U.S.A., at 62 years of age. Dr. Green was head of the Eye Department of the National Military Home and St. Elizabeth's Hospital at Dayton. His name had become specially prominent during the last few years in consequence of his ardent advocacy of the intra-capsular extraction of cataract, which he spent several months in studying at first hand under Colonel H. Smith in India. He was a member of the Oxford Ophthalmological Congress, and was present at the last meeting but one of that body.

Dr. Monte Griffith, assistant professor of ophthalmology in Georgetown University, died on July 11th, at the age of 51 years, from angina pectoris.

A well-known ophthalmic surgeon, Otto Lange, of Brunswick, died on October 5th in his sixty-first year. Born at St. Petersburg, Lange studied at Leipzig and Heidelberg, and was attached to the Eye Institution of his native town from 1877 to 1886. He was then appointed ophthalmologist to the Ducal Hospital at Brunswick, where the title of professor was bestowed upon him in 1904.

The death is announced of Dr. Lürmann, president of the *Niedersächsischen Augenärztlichen Vereinigung.*

The death is announced from Berlin of Leopold Mandelstamm, once of Riga.

Johannes Heinrichs, a Magdeburg ophthalmic surgeon, died on the 29th of August last, in his thirty-seventh year.

The death is announced from Hamburg, of Wolfgang Arthur Herschel, at the age of 58 years. He had practised ophthalmology in Hamburg since 1881.

* * * *

Appointments. H. WILLOUGHBY LYLE has been appointed lecturer on practical ophthalmology at King's College Hospital Medical School, London.

J. A. Davidson has been appointed assistant surgeon to the Ulster Eye, Ear, and Throat Hospital, Belfast.

C. G. Haye Sharpe has been elected ophthalmic surgeon to the Luton Education Committee.

The following appointments have been made to the Birmingham and Midland Eye Hospital:

G. Heaton appointed consulting general surgeon. Appointed assistant surgeons: —T. Harrison Butler (editorial secretary of THE OPHTHALMOSCOPE), R. Beatson Hird, and D. Priestley Smith.

Casey A. Wood has been appointed professor of ophthalmology and head of the department of ophthalmology in the newly organised College of Medicine of the University of Illinois, the former College of Physicians and Surgeons, Chicago.

Richard Fröhlich has been nominated *primarius* of the newly-erected department for eye patients in the General Hospital of Wien-Neustadt.

J. van der Hoeve, of Gröningen, has been appointed professor of ophthalmology in Utrecht.

G. N. Brandon has been appointed ophthalmic house surgeon to St. Thomas's Hospital, London.

R. L. Kitching has been appointed ophthalmic house surgeon to St. Bartholomew's Hospital, London.

* * * *

Honours.

IN connection with the recent International Congress of Medicine, Professor Ernst Fuchs, of Vienna, was elected an honorary Fellow of the Royal College of Surgeons of England.

Dr. J. Walton Browne, surgeon to the Belfast Ophthalmic Hospital, has been appointed a Deputy Lieutenant for the County of that City. Congratulations!

* * * *

Workmen's Compensation Act, 1906.

AN important order (No. 814) has been issued by the Secretary of State, extending the provisions of the Workmen's Compensation Act (6 Edw., 7, c. 58) to writer's cramp, and consolidating certain orders. Section No. 2 enacts that "a glass worker suffering from cataract shall be entitled to compensation . . . for not more than six months in all, and for not more than four months, unless he has undergone an operation for cataract." Provision is also made for compensation to apply to "the disease known as miner's nystagmus, whether occurring in miners or others, and whether the symptom of oscillation of the eyeballs be present or not." Thus worded, the paragraph quoted is likely to give rise to difficulties of interpretation.

* * * *

Doctor of Ophthalmology, Colo.

THE examination for the degree of Doctor of Ophthalmology, held at the University of Colorado, August, 1913, included an oral examination and report upon three microscopic slides, clinical examination of cases, with a written report on each, and the following questions in written examination:

1. Describe a meridional section of the anterior segment of the eyeball, giving, by diagrams and figures, exact relations and dimensions of the parts.

2. Describe the course of the rays of an incident pencil in regular astigmatism; and give the five possible relations of the retina to them.

3. Describe a case of squint for which you would operate; give reasons for operating, what operation you would choose, and reasons for choice.

4. In a case of redness and pain of the eye and photophobia, name five different conditions to which it might be due, and give the reasons deciding in favour of or against one of them, the appropriate treatment and prognosis.

5. In a case of supposed sudden blindness of one eye give three possible causes; with further symptoms which would decide which was the cause, and indicate what would be the appropriate treatment for each.

6. Describe three different forms or kinds of toxic amblyopias, and give the prognosis for each.

7. In a case of intraocular tumour composed chiefly of small round cells, what different kinds of tumour might it be; and by what appearances or facts of the history would you determine which it was?

8. Give three causes of exophthalmos, the differential diagnosis between them and the treatment for each.

9. If a patient came with the history of having been struck in the eye by a flying object, how would you ascertain the nature of the injury sustained? Give the first treatment for three different kinds of injury.

10. Describe briefly ocular manifestations of tuberculosis.

* * * *

The Conservation of Vision.

At the May meeting of the *Heidelberger Ophthalmologische Gesellschaft* a communication was presented through one of the corresponding members of the Twelfth International Ophthalmological Congress, to be held in St. Petersburg in August, 1914, urging that a request be made that a part of the session of the Congress be devoted to the consideration of the "Conservation of Vision and the Prevention of Blindness." This met with a most hearty endorsement, and Professor Dr. Wagenmann was appointed on behalf of the ophthalmologists of Germany to communicate with the general secretary of the Congress to this end. It is expected that one morning will be devoted to this subject and from this may result more definitely organized efforts in preventive ophthalmology throughout the world.

British members of the Congress might well unite with their American *confrères* in urging that some time be given at St. Petersburg for consideration of so important a subject.

* * * *

The Swanzy Memorial Fund.

The preliminary list of subscribers to the Swanzy Memorial Fund has now been issued, from which we observe that the sum of £991 3s. 7d. has so far been contributed in commemoration of the memory of our late colleague.

Congress of Surgeons of North America.

THE Clinical Congress of Surgeons of North America will hold its fourth annual meeting at Chicago from November 10th to 15th next. Communications by Drs. Edward Jackson and Harold Gifford are announced. A series of operative clinics have been arranged in the amphitheatres of the hundred or more hospitals and dispensaries of Chicago, and special measures have been taken to ensure that spectators shall see what is going on. Among other foreign operators we note the name of Lieut.-Colonel R. H. Elliot, I.M.S., who will demonstrate his method of using the corneal trephine for the relief of glaucoma. The attendance of those interested in the surgery of the eye is invited.

* * * *

International Trachoma Prize.

A PRIZE of 1,000 kronen is offered by the Hungarian Minister of the Interior for the best work upon the ætiology of trachoma. An indispensable condition of the award is that the essay must show a tangible progress. Communications that have been published for the first time during 1913 or 1914 will be accepted. They may be written in English, German, French, or Hungarian. They must be received not later than June 30th, 1914, and are to be sent to Budapest, I., Vár, Belügyministerium. The jury will be nominated by the Minister of the Interior, and the decision reached will be announced at the Twelfth International Ophthalmological Congress at St. Petersburg, August, 1914.

* * * *

The Heidelburg Congress.

OWING to the meeting of the International Ophthalmological Congress in August next, it has been decided to hold no session of the Heidelburg Ophthalmological Society during 1914. The next meeting of the last-named society will take place at the beginning of August, 1915.

* * * *

Professor Hirschberg's 70th Birthday.

THE friends and pupils of Professor Hirschberg (and they are numerous) celebrated the seventieth anniversary of his birthday on September 18th last. In order to commemorate the occasion, the well-known periodical founded by Hirschberg thirty-seven years ago, the *Centralblatt für praktische Augenheilkunde*, published a *Festnummer* containing fourteen articles written by the friends of our distinguished Berlin colleague. Germany was represented by Krückmann, Peters, Fehr, Schleich, Wessely, and Stern; Austria-Hungary by Fuchs, Purtscher, Dimmer, Meller and Elschnig; France by de Lapersonne and Frenkel; and Italy by Albertotti. Great Britain unfortunately went unrepresented among the list of contributors, but Professor Hirschberg may rest assured that good wishes from that country were none the less cordial and widely-spread.

THE OPHTHALMOSCOPE DIARY.

	1913.	
Royal Society of Medicine: Section of Ophthalmology	November 5th.	1, Wimpole Street, London.
Congress of Surgeons of North America	November 10th to November 15th.	Chicago.
Royal Society of Medicine: Section of Ophthalmology.	December 3rd.	1, Wimpole Street, London.
	1914.	
Oxford Ophthalmological Congress	July 8th to July 10th.	Oxford.
British Medical Association: Section of Ophthalmology.	July 15th to July 17th.	Aberdeen.
International Congress of Ophthalmology.	August 10th to August 15th.	St. Petersburg.

THE

OPHTHALMOSCOPE.

A MONTHLY REVIEW OF CURRENT OPHTHALMOLOGY.

VOL. XI.—No. 12.] *DECEMBER 1, 1913.* [TWO SHILLINGS.

CONTENTS.

Original Communications.— PAGE

1. George Coats, F.R.C.S.—Infarction of the Posterior Ciliary Arteries 708
2. George H. Oliver, D.O.—Hyaline Bodies at the Optic Disc in a case of Retinitis Pigmentosa 716
3. J. Igersheimer, M.D.—Recent Investigations dealing with Inherited Syphilis of the Eye 718
4. Bernard Cridland, D.O.—The Visual Fields in Coal Miners' Nystagmus 727
5. J. Burdon-Cooper, D.O.—Direct Ophthalmoscopic Examination with Indirect Vision and Illumination 729

Novelties. –

Tarsal Cyst Forceps.—By Arthur Greene, M.D. 733

Current Literature.—

I. Light and the Eye 734
II. The Sensory Pupil Reflex in Tobacco Amblyopia 736
III. Lamellar Cataract and Tetany 737
IV. The History of Spectacles 737
V. "Secondary" Tuberculosis 740
VI. Ophthalmology and General Medicine (fourth notice) 741
VII. Pathology (fifth notice) 742
VIII. Hemeralopia and Xerosis Conjunctivæ 746
IX. Cataract Operations 747
X. Syphilitic Affections of the Eye 753
XI. Myopia 756
XII. Remedies (tenth notice) 758

Book Notices 764

The late Mr. Edward Nettleship 767

The Ophthalmoscope Diary... 770

ORIGINAL COMMUNICATIONS.

INFARCTION OF THE POSTERIOR CILIARY ARTERIES.*

BY

GEORGE COATS, F.R.C.S.,

LONDON, ENGLAND.

SOME years since I published the pathological details of a condition which seemed to be due to acute obstruction of a posterior ciliary artery (*Trans. Ophth. Soc.*, Vol. XXVII, p. 135, 1907). As no similar observation seems to have been recorded before or since, and as I have again had the opportunity of examining a case of exactly the same kind, it seems worth while to resume the subject.

Briefly summarised, my former case was as follows: —

CASE I.

Man, aged 38 years. Complaint of dimness of vision in the left eye for twelve months. Said to have been no congestion, pain, or exophthalmos.

FIG. 1. General view of the posterior upper quadrant of the globe in case I. A. to A'. Necrotic area in the sclera. B. to B'. Larger necrotic area in the choroid. C. to C'. Necrotic area in the retina. E. Equatorial staphyloma. Papilla atrophic and cupped. Nerve atrophic. (From *Trans. Ophth. Soc.*, Vol. XXVII, 1907.)

Lens became opaque about six months after onset of symptoms. When seen, chronic iridocyclitis present. Old corneal precipitates; iris discoloured and covered with large new-formed vessels. Lens cataractous. Scleral staphyloma forming. Right eye normal.

Pathologically: Patch of choroidoretinal atrophy above disc. Commences 4-5 mm. from the nerve entrance, with which, however, it is connected by an

*Communication read at the meeting of the Seventeenth International Congress of Medicine, London, 1913.

atrophic streak, and measures 10 mm. in diameter. Has the form of a brown island surrounded by a yellow moat. Microscopically the area consists of :—

(1) A necrotic patch in the inner layers of the sclera, occupying about 1/3 of its thickness. No infiltration of the patch itself, but the surrounding tissues show a good deal of inflammatory reaction (Figs. 1 and 2). Not much thickening of the sclera, and no inflammation of it anywhere else. No occluded vessel found. No endarteritis of the ciliary vessels outside the globe.

(2) The choroid is also completely necrotic in an area corresponding roughly with the dead portion of sclerotic, but of wider extent (Figs. 2 and 3). Some blood corpuscles present in its stroma. Pigment irregularly scattered. Inflammatory infiltration, absent within the necrotic patch, commences at its edge.



FIG. 2. Case I. Higher power view of the necrotic sclera and choroid. C. Choroid. Nuclear staining absent. Pigment epithelium lost. Stroma pigment collected in irregular masses. A few blood vessels are scattered in the stroma, but the normal structure is lost NS. Necrotic portion of sclera. The lamellar structure is preserved, but nuclear staining is absent. S. Living sclera. At the line of junction with the dead portion there is a moderate amount of inflammatory infiltration. (From *Trans. Ophth. Soc.*, Vol. XXVII, 1907.)

(3) Complete necrosis of the retina in a somewhat more extensive area (Fig. 3). The two limiting membranes distinguishable, but all other elements broken down to a structureless granular *débris*. Pigment epithelium lost, but a considerable amount of pigment, diffusely scattered and in clumps, in the retina. No adhesion between the retina and the choroid over the necrotic area, but some fusion at the edge of the patch. No normal retina or choroid between the patch and the nerve entrance. Recovery of both structures much more rapid on the peripheral than on the central side of the atrophic patch.

Some atrophy, but no other disease of the retina and choroid beyond the patch. Elsewhere precipitates of cells on the inner surface of the retina ; inner layers atrophic, outer well preserved. Some areas of old choroido-retinitis in periphery. Cupping, partly glaucomatous, partly atrophic, of papilla.

Iris condensed and infiltrated ; fibrous membrane in pupil ; posterior synechiæ. Corneo-iridic angle occluded. Precipitates on the cornea. Infiltration about the spaces of Fontana and canal of Schlemm. Lens fibres breaking down ; thick deposits of anterior capsular cataract. Atrophy, some infiltration, and commencing membrane formation in the ciliary body.

CASE II.

Summary.—*Attack of iridocyclitis with increased tension, in a man aged 40. Quiescence for two years, after which eye lost from an infected ulcer of the cornea. Other eye normal throughout.*

Pathologically: A large roughly quadrangular white area on the nasal side of the nerve entrance, consisting, microscopically, of a wedge of necrosis in the outer layers of the sclera, with surrounding inflammatory lesions, and of profound degenerative changes, with little inflammation, in the choroid and retina. The affected area in the choroid and retina larger than in the sclera. Some atrophy of the outer layers of the retina beyond the patch. Elsewhere retinal changes slight, and choroidal practically absent. Some cupping and atrophy of the nerve. Lesions in the anterior part of the eye, partly those of a recent infected ulcer, partly those of an old plastic iridocyclitis.

A man, aged 40 years, was admitted to the Royal London Ophthalmic Hospital, under the care of Mr. J. B. Lawford, on December 8th, 1904. The right eye had suddenly become inflamed eight weeks previously. There was no history of any illness. Iridocyclitis was present, with many corneal precipitates; the tension was raised; vision = counting of fingers at two feet. He was under occasional observation for a period of about five months, and was treated for a time with subconjunctival injections of cyanide of mercury and acoin. The tension of the right remained higher than that of the left. He was then lost sight of for a period of two years, when he returned saying that the eye had given him no inconvenience till the previous day, when it had suddenly become painful. There was much injection, the cornea was œdematous, a deeply infiltrated ulcer was present in its centre, and the anterior chamber contained pus and blood. The iris was abnormally vascular, and some yellowish-grey lymph was present in the pupil, which was of medium width. Vision = perception of light. Projection very defective. Tension raised. Left eye normal. Vision 6/6. The right eye was excised on May 8th, 1907.



FIG. 3. The necrotic retina in Case I. The limiting membranes are distinguishable. Between the two the retina is converted into a mass of detritus with some pigment clumps and a few isolated nuclei. There is no trace of the rods and cones. No adhesion with the choroid or inflammatory infiltration is present. C. Choroid. S. Sclera. R. Retina. (From *Trans. Ophth. Soc.*, Vol. XXVII, 1907.)

Pathological Examination.

The eye is fixed in formalin and divided sagittally. The vitreous is clear, the lens, retina, and choroid are *in situ*. In the horizontal meridian, on the nasal side of the disc, there is an area of retino-choroidal atrophy measuring at its broadest about 8 mm. both horizontally and vertically. Its general outline is roughly square, but with the lower-outer angle truncated. It is separated from the papilla by an interval, but in the horizontal meridian a small tongue stretches towards, but does not reach, the disc; peripherally it extends to about the equator. The area is almost pure white, but with a few small islands of brown pigment here and there. There are no patches of choroiditis elsewhere.

Serial sections in the horizontal plane were made through the atrophic area.

Microscopical Examination.

The lesions in the atrophic area on the nasal side of the disc are of chief interest. They consist in (1) a necrotic patch, with surrounding changes, in the sclera; and a very profound disorganisation of (2) the choroid and (3) the retina.

1. The necrotic patch takes the form of a wedge with a short base directed towards the nerve entrance, and a long sharp apex directed towards the equator (Figs. 4A and 5A). It is situated in the deepest layers of the sclera, its inner boundary corresponding with the sclero-choroidal junction. It occupies about a fourth of the total breadth of the atrophic region. Within this area the coarser characteristics of the scleral structure are more or less preserved, but the regular, elongated scleral nuclei are absent, their place being taken by a few darkly stained, mostly round or only slightly elongated elements. The scleral fibres have a granulated appearance, and stain more darkly than normal with eosin. On the inner aspect of the area numerous pigment granules, partly intracellular, partly diffusely scattered, probably represent the pigmented cells of the lamina fusca. No vessels are present within the patch.

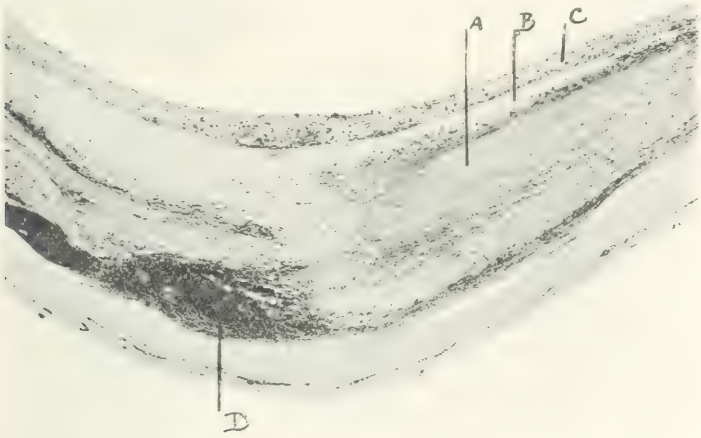

FIG. 4. × 34. General view of Case II. A. Wedge-shaped necrotic patch in the sclera. B. Choroid. C. Retina. D. Lymphocytal infiltration in the outer layers of the sclera. The sclera is thickened and the area is slightly ectatic.

The tissues in the vicinity lack the regularity of the normal sclera; they are loosened and finely fibrillated, and where they encroach on the necrotic patch, especially on the inner side, they have a frayed irregular edge. Immediately around the patch inflammatory infiltration is comparatively slight (Fig. 5), but in the more superficial layers, and especially round the ciliary arteries and nerves, there are considerable collections of lymphocytes, which can be followed also for some distance backwards along the ciliary vessels (Fig 4, D). Tracks of lymphocytes are also found elsewhere among the layers of the sclera. Some cells like plasma cells are also present, but polymorphonuclear leucocytes are practically absent. These changes cause a moderate thickening of the sclera, and the whole area is slightly ectatic. There is no evidence of inflammation in the sclera elsewhere.

Some of the posterior ciliary arteries by the side of the nerve show slight endarteritis, but in none of them is there any approach to obliteration of the lumen, and many of them are free. No obliterated vessel could be found with certainty within the area itself.

2. Over a large part of the area the normal structure of the choroid is wholly lost (Figs. 4B and 5B). The vessels have disappeared and the line of separation between the sclera and choroid is ill-defined. The stroma is replaced by a condensed tissue with a faint longitudinal fibrillation, and with only a few scattered round or elongated nuclei. Most of the pigment is lost, but a few unbranched or scarcely branched chromatophores remain. The membrane of Bruch is distinct and intact almost throughout. Some traces of the pigment epithelium are visible in the form of irregular groups of proliferated cells, usually with well-stained nuclei; pigment is mostly absent, but present in places. The line of demarcation between the retina and choroid is fairly well defined; there is no intimate fusion, such as is found in patches of retino-choroiditis.

These changes are most marked in an area about half as large again as the patch of scleral necrosis. The transition from normal to degenerate choroid is rather abrupt towards the periphery, a few lymphocytes and plasma cells, but no profound alteration of structure, being present at the edge. Towards the nerve entrance signs of inflammation, both in the retina and choroid, are more marked, the

fusion of these two tracks is more intimate, and the membrane of Bruch is more interrupted. Full recovery of the normal pigmentation of the choroid takes place only in the immediate vicinity of the nerve entrance; infiltration ceases within a very short distance of its restoration.

In the retina also practically all traces of normal structure are lost (Figs. 4 and 5.) The limitans interna is usually fairly well defined, the externa traceable only in places. Between the two the tissue consists of a homogeneous or slightly granular substance, and of fibrils longitudinally disposed, and most prominent in the inner layers. Small scattered nuclei, mostly round and deeply stained, are present in variable abundance, and form small collections in places, especially near the necrotic patch in the sclera. Pigment, mostly intracellular, but partly in the form of scattered granules, is fairly plentiful. Not only have the nerve elements entirely disappeared, but the neuroglial proliferation which often takes their place seems to have remained entirely in abeyance. Towards the papilla, as has been said, the signs of inflammation and of adhesion between the choroid and retina become more pronounced, traces of the internal nuclear layer are distinguishable, and, finally, where the choroid is fully restored, the rod and cone and outer nuclear layers again make their appearance. The changes in the retina reach an equally high degree over practically the whole of the necrotic area.

Beyond the atrophic area on the nasal side the choroidal stroma seems to be normal, except for a few patches of lymphocytes in the extreme periphery. There is, however, considerable patchy degeneration of the rod and cone and outer nuclear layers of the retina, together with some irregularity of the pigment epithelium. On the temporal side of the nerve entrance a cellular membrane is present on the surface of the retina, but the retina itself shows only a moderate degree of atrophy of the nerve fibre and ganglion cell layers, all the outer layers being normal. The choroid also shows nothing pathological in this situation. There is slight glaucomatous excavation of the papilla, and the nerve is atrophic.

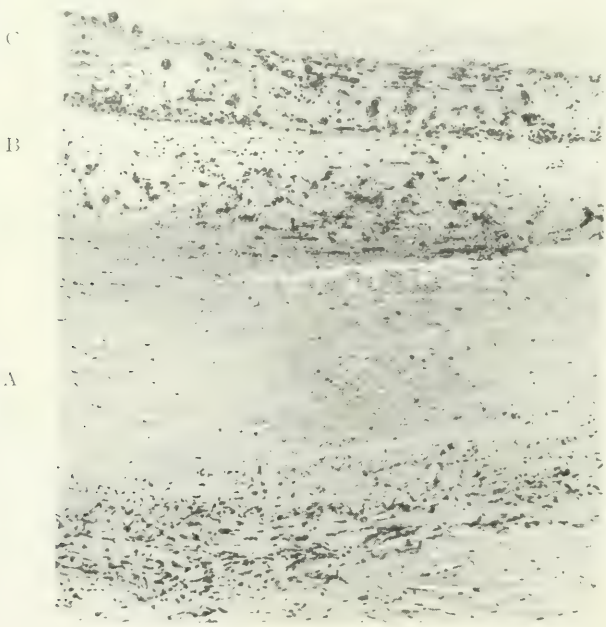

Fig. 5. × 90. Higher power view. A. The sclera, necrotic in its inner, slightly infiltrated and loosened in structure in its outer layers. B. The choroid, showing the loss of all normal structure and the clumping of the pigment into irregular granular masses. The line of separation between the sclera and choroid is not very well defined; the membrane of Bruch is visible on the inner aspect. C. The retina, almost structureless, and containing a few small nuclei, clumps of pigment, and granular debris.

The changes in the anterior part of the eye are partly recent, partly old. The recent consist of a central ulcer with much infiltration, loosening and destruction of the corneal lamellæ; no perforation is present, however. In the same situation the deepest layers of the cornea are also intensely infiltrated, the intermediate being relatively free; the membrane of Descemet is interrupted and some of the deepest lamellæ are eroded; a large hypopyon, mixed with hæmorrhage, adheres to, and is continuous with, the deep infiltrate in the cornea. This condition of posterior erosion without complete perforation is known as "early perforation" ("*Frühperforation*") of the membrane of

Descemet. A moderate degree of infiltration is also present elsewhere in the cornea. The iris is thickened, intensely infiltrated with lymphocytes, larger mononuclear cells, and polymorphonuclear leucocytes. It is much congested and hæmorrhages are present in its root. The ligamentum pectinatum is stuffed with leucocytes. Considerable patches of infiltration are found in the anterior part of the ciliary body. Posteriorly the evidence of inflammation is much slighter. A few leucocytes are present in the anterior part of the vitreous.

The changes of old standing are (1) a deposit of densely organised fibrous tissue on the back of the cornea. It contains no vessels, and in these horizontal sections does not reach the corneo-iridic angle. The angle itself is narrowed, and in places occluded to a small extent, by a peripheral adhesion. (2) In the ciliary body the unpigmented epithelium shows irregular proliferation and there is slight membrane formation in the region of the pars plana. (3) The lens shows breaking down of its fibres and a fairly extensive anterior capsular cataract.

Remarks.

It is evident that these two cases closely resemble one another, and differ in important particulars from ordinary instances of choroido-retinal inflammation or degeneration. In both the clinical appearances were those of a seemingly idiopathic iridocyclitis with raised tension; in both, on dividing the eye, a large more or less quadrangular patch of choroidal atrophy was found, commencing a little distance from the nerve entrance, but joined to it by a streak of atrophy, and measuring from 8 mm. to 10 mm. in diameter; in both a wedge of the innermost layers of the sclera had undergone necrosis, while a larger area of the choroid, and a still larger area of the retina showed, in the first case necrosis, in the second extremely profound degenerative changes probably indicating the former presence of necrosis; in both this area of degeneration and necrosis was surrounded by inflammatory reaction of moderate degree, associated in the first case with very little, in the second with some, thickening of the sclera; in both the transition to normal retina and choroid was more rapid in the periphery of the patch than on the aspect towards the nerve entrance; in both there was evidence of a deposit of inflammatory cells on the inner aspect of the retina; and in both the signs in the anterior part of the eye were those of a non-specific plastic iridocyclitis. The differences between the two cases were probably due simply to the longer duration of the second.

The chief point of distinction from a patch of choroido-retinitis lies in the preponderance of necrosis over inflammation. Except at their edges the necrotic tissues are not at all infiltrated. Moreover, the adhesion and fusion of the choroid and retina, which are so characteristic of choroido-retinitis, are absent over the greater part of the area.

The only possible explanation of these phenomena seems to be that the necrosis is due to a cutting off of the blood supply.

An inflammation severe enough to cause this degree of necrosis would certainly be associated with more profound reaction, deeper cellular infiltration, and more matting together of the retina and choroid. It follows, therefore, that the necrosis must have been primary and the inflammation secondary; and the only probable cause of this species of necrosis *en masse* is arterial obstruction. The localisation of the area also corresponds well with the distribution of a posterior ciliary artery.

The lesion, therefore, is of the nature of an infarction, and it has the wedge shape of infarctions elsewhere in the body. In the retina and sclera, its characters are those of the pale infarct; in the more vascular choroid, in Case I, blood corpuscles were present in the stroma, and the hæmorrhagic infarct was to some extent imitated. From such necrotic portions of tissue toxines seem to diffuse into the surrounding living structures, giving rise to an inflammatory reaction which leads finally to encapsulation of the dead tissue, or to its penetration with organising material. So also in the present

instance, inflammatory reaction was provoked in the living sclera, choroid, and retina, and it seems probable that the inflammatory changes in the anterior part of the eye were also due to the diffusion of toxines from the necrotic tissues through the vitreous to the aqueous ; the presence of inflammatory cells on the surface of the retina in both cases seems to support this view.

It may, perhaps, be thought surprising that complete necrosis should occur in so vascular a tissue as the choroid, but it should be remembered that the vitality of a tissue after obstruction of its arterial supply depends not simply on its vascularity, but also on the freedom with which the blood from collateral sources can be poured into it. Thus, the kidney and spleen are highly vascular organs, but owing to pecularities in the distribution of their vessels, they are subject to infarction. Similarly in the choroid, according to Leber, the larger ciliary arteries have few branches of communication with one another, and these mostly in the anterior part of their distribution and round the nerve entrance. Hence, when they are blocked, the circulation is not restored quickly enough to preserve the vitality of the tissues which they supply.

It is more difficult to account for the necrosis of the retina, which has a blood supply of its own. Probably the element of suddenness in the obstruction has something to do with the matter, and possibly the toxines derived from the necrotic tissue may not be wholly without influence. On dividing the posterior ciliary arteries in the rabbit, Wagenmann found a condition of the retina closely similar to that which has been described above, but in view of the more restricted retinal blood supply in that animal, a certain amount of caution should be observed in transferring his results to human pathology. According to his description, " the retina consists only of a thin membrane in which, in places, an indistinctly reticular supporting tissue is recognisable among finely granular material. A few cells of variable form and size, with oval nuclei, are present, apparently the remains of the inner nuclear layer. Here and there are little heaps of chromatin and shrunken nuclei, the last remnants of the outer nuclear layer. Large fatty cells are also found. Pigment occurs in the degenerated retina, partly as free granules, partly enclosed in cells. . . ."

Although the reasons given above seem fully sufficient to justify the assumption of an arterial occlusion, yet it should be remembered that for the present this is a deduction and not an actual observation. In spite of serial sections in the second case, the obstructed vessel could not be found, perhaps because the blocked portion was outside the sclera and was therefore left behind in excising the eye, perhaps because the vessel, cut in some oblique or longitudinal plane and having probably undergone much alteration in the course of $2\frac{1}{2}$ years, escaped recognition among the lymphocytal infiltration, which was present in the perivascular sheaths of all the perforating arteries.

The presence of an infarction is in itself proof that the occlusion was sudden, for gradual blockage of ciliary vessels produces a different and sufficiently well-known set of phenomena. It is unlikely therefore that the block was due to endarteritis alone ; it must have been either a thrombus, probably superimposed upon disease of the arterial wall, or an embolus. Unfortunately no details as to the cardiac condition of either patient are available. In Case II there was a moderate amount of endarteritis in the posterior ciliary arteries ; in Case I there was none.

No published case seems to be quite similar to these two. An observation by Knapp (*Arch. of Ophth.*, Vol. XIV, Part i, p. 245, 1868) may perhaps refer to something analogous.

A woman aged 20, suffered from mitral regurgitation, the result of acute rheumatism, and frequently had headaches and flickering scotomata before the eyes. Ten days before she was seen, she felt ill and giddy, and at the same time vision failed suddenly in both eyes. Sight was speedily recovered in the left, but a scotoma upwards and inwards remained in the right field. A diffuse, greyish, slightly prominent opacity was present in the right retina round the macula and below the nerve; it disappeared gradually in four or five days. She subsequently had some cerebral symptoms—indistinct stammering speech—and some time afterwards, the vision of the left eye failed, again in association with a cardiac attack. Above the macula, an opacity was present, which cleared in three days.

Knapp believed that these cerebral and visual phenomena were to be explained by the lodgement of emboli in the cerebral and posterior ciliary arteries. Fuchs doubts the probability of emboli finding their way into the ciliary arteries on both sides, but in view of the association of cardiac symptoms with both attacks, the possibility of thrombosis from deficient circulation is to be kept in mind. It may also be objected that the description leaves it uncertain whether the retinal opacity may not have been due to obstruction of retinal rather than choroidal vessels.

It is of interest to consider whether any connection exists between these cases and the condition described by Fuchs (*Ber. d. Ophth. Gesellsch.*, Heidelberg, Bd. XXX, S. 71,1902) under the name "Posterior Scleritis." In Fuchs' case, a lad, æt. 16 years, who had suffered from diphtheria six weeks before, complained of pain about the outer canthus of the left eye and in the side of the head. Some days later sight became dim in the same eye. The conjunctiva was swollen and vascular on the temporal side, and there was photophobia, but otherwise the external appearances were normal. There was some pain on pressing the globe back into the orbit. The disc was red and blurred, and the retina around it opaque; the macular region bulged forward 3D to 4D. Vision with a + 5D. lens was 6/12 partly; there was concentric narrowing of the field of vision. The right eye was normal; vision with + 0.75 D. sph.=6/6. Nothing abnormal was detected elsewhere in the body, and there was no albumen in the urine. In a few days the pain abated and in a little over a fortnight the hypermetropia and opacity of the retina had disappeared, leaving a visual acuity of 6/8 partly. Two months later the right eye was attacked in a similar manner and again the symptoms disappeared within a short time. A similar case has been reported by Inouye (*Klin. Monatsbl. f. Augenh.*, Bd. XLIV. i, S.123., 1911).

In this instance, as Fuchs points out, a primary affection of the retina or choroid seems to be excluded by the presence of pain—nerves of sensation being present in the sclera alone—by the slight degree of diminution of vision, and by the disappearance of the retinal opacity and hypermetropia without leaving pigmentation or other traces. A purely orbital affection, on the other hand, seems to be excluded by the ophthalmoscopic appearances and by the absence of œdema of the lids, proptosis, etc. The presence of scleritis is apparently proved by the redness of the conjunctiva and sensitiveness to touch on the temporal side, where the sclera can be examined furthest back.

This reasoning is no doubt correct, but the present cases differed in several important respects from the observation of Fuchs. Pain, congestion, and swelling of the conjunctiva were absent. In Fuchs's case the symptoms cleared up within a short time, and the anterior parts of the globe were normal; in the present cases a quiet form of iridocyclitis led to loss of the eye. It seems probable, therefore, that the two conditions are really different, the lesion in Fuchs's case being essentially an inflammation of the sclera, and

in mine an occlusion of a ciliary artery. The same remarks apply with even greater force to the cases of posterior scleritis described by Wagenmann (*Ber. d. Ophth. Gesellsch.*, Heidelberg, Bd. XXXI, S. 140, 1903), in which the signs of inflammation were still more prominent.

In 1895, Siegrist* (*Ophthalmoskopische Studien. Mitteil. aus Kliniken u. med. Instituten d. Schweiz.*, III Reihe, Heft ix.) ascribed to rupture of a posterior ciliary artery, a condition in which, following a blunt injury, one or more map-like areas of yellow discolouration are found in the vicinity of the disc; subsequently a diffuse pigmentation takes place and the area becomes lighter in colour and more sharply defined. Birkhäuser and Hirsch have each reported two similar cases, and, indeed, the type of disease will be familiar to most ophthalmic surgeons. Hirsch (*Untersuchungen über die Pigmentierung d. Netzhaut*, 1905, p. 26) made a pathological examination of a case in which, a month after an injury with a cow's horn, a similar patch was observed on dividing the globe; the fundus had not been seen with the ophthalmoscope. He found the retina on the temporal side atrophic and adherent to the choroid. The pigment epithelium was irregular—present in places, imperfectly pigmented or absent in others; elsewhere proliferated and invading the retina. The choroid was atrophic, the smaller and smallest vessels having suffered most; some small patches of inflammation were present. In the vicinity of the nerve entrance remains of old hæmorrhage were found in the layers of the sclera.

The attribution of these changes to interference with the ciliary circulation is probable enough, but it must be remarked that the lesions, both clinically and pathologically, fell very far short in severity and extent of those which were present in my case. The vessel actually ruptured was not found by Hirsch. It seems likely therefore that if traumatic pigmentation is due to a vascular lesion it is the smaller vessels rather than the main trunks which are damaged.

HYALINE BODIES AT THE OPTIC DISC IN A CASE OF RETINITIS PIGMENTOSA.

BY

GEORGE H. OLIVER. D.O. Oxon.

ASSISTANT SURGEON, ROYAL EYE AND EAR HOSPITAL, BRADFORD, ENGLAND.

By the courtesy of the editor of THE OPHTHALMOSCOPE I am able to submit coloured drawings of the condition mentioned at the head of this short paper.

Case.

The patient is a young man who was brought to me by his mother a short time ago, because his vision was so bad that he could not find his way about except in the precincts of his own home. He was taken to see a doctor when eight years of age on account of his inability to see "as well as other people" at night. His mother was told that the boy's vision would probably get worse, which it evidently did, as the doctor saw him again five years later, when vision was R. 6/60, L. 6/36. The surgeon's note made at the time says "typical retinitis pigmentosa is present, with some thinning of vessels and slight pallor of both discs." He was not able to trace the former visit of the patient.

*The original of this paper has not been available to me, but through the kindness of Professor Axenfeld, I have been able to consult Birkhäuser's memoir, in which the views of Siegrist are summarised.

Right Eye.



The patient is now 25 years old, the fifth child of a family of six; four sons and two daughters. His parents are first cousins. Three years ago he had a severe attack of influenza, and since then has been subject to epileptic fits at long intervals. He is well-nourished, but distinctly below the average in mental capacity, and somewhat deaf; he stammers badly, which failing is well-marked in his father and in a younger brother. There is no trace of inherited syphilis about him, as far as I can make out, nor in any other member of the family; he has no other congenital defect, his brothers and sisters are in normal health, and none has up to date complained of night blindness. The patient's vision is now reduced to shadows, the pupils reacting very sluggishly to light. Ophthalmoscopic examination, as is well shown in the drawings, reveals typical and well-marked retinitis pigmentosa extending almost up to the disc, the pigmentation being very dense at the equator, much more so than in the average case of this disease. Thinning of the vessels and pallor of the discs. It is the extension of the degenerative process posteriorly that accounts for the great diminution of visual acuity, unusual in one so young. The refracting media are perfectly clear. In the right eye two yellowish-white, glistening, semi-translucent masses are seen, one on the inner, the other on the outer side of the disc, the edges of which they overlap, and in length each is approximately one-fourth of the circumference of the disc and separated above and below by an equal length of disc margin. Where the bodies come into relation with the blood vessels, the latter course beneath the former; two other small brilliant bodies are seen immediately above the larger mass, which is on the nasal side of the disc. It is not uncommon to see such formations more peripherally placed.* In the left eye there are six masses of similar appearance but of a different shape, being more inclined to rotundity; these are at the edge of the disc, which is overlapped by each body, four on the temporal and two on the nasal side. In this eye, as in the right, blood vessels run beneath one of the masses.

It is not easy to estimate the degree of prominence of these bodies, as they are semi-translucent and the surface of each is so brilliantly reflecting at different points. They all have the same characteristic appearance, and they seem to project forward into the vitreous to a distance varying from 6 D. to 10 D., the larger ones being the more prominent. The surface of each is irregular, as the outline of each body shows, and might be compared with that of a minute closely-knit cauliflower.

Remarks.

It is well known that these bodies, mistakenly named "*Drusen*," are met with in retinitis pigmentosa, although rarely. Of forty-two cases reported up to 1903, seven occurred in this disease.[1] Up to July, 1913, hardly fifty cases in all had been reported.[2] No case has been seen during the last fifty years at the Hospital with which I am connected, an evidence of the extreme rarity of this condition.

Regarding the nomenclature, Wetzel,[3] one of the most recent writers on this subject, says, that it is better to speak of "excrescences" than of "*Drusen*" "*weil wir unter Drusenbildung in der Krystallographie, einen mit Krystallen angefüllten Hohlraum im Gestein verstehen*," so that the term "*Drusen*" cannot be correctly applied to the excrescences so well shown in the drawings.

Pathologists are not agreed as to the nature of these bodies, the chief reason being that so few cases have been examined with the microscope. For those

Parsons, *Trans. Ophth. Soc. U.K.*, 1903, p. 144.

who are interested in this side of the subject, an excellent account will be found in Parsons' "Pathology of the Eye," Vol. II, p. 661.

This case seems to me to be extremely like that reported by Ernest Thomson in the January, 1913, number of THE OPHTHALMOSCOPE, with the difference in his case that there was posterior cortical cataract in both eyes, while in the case under consideration the refracting media are perfectly clear.

REFERENCES.

1. **Parsons.**—*Trans. Ophth. Soc.*, 1903.
2. **Giri.**—THE OPHTHALMOSCOPE, July, 1913.
3. **Wetzel.**—Inaugural dissertation, *Ueber Drusenbildung im Sehnervenkopfe und in der Retina.* Rostock, 1911.

RECENT INVESTIGATIONS DEALING WITH INHERITED SYPHILIS OF THE EYE.*

BY

JOS. IGERSHEIMER, M.D.,
HALLE, GERMANY.

THIS address, which deals with damage caused to the eyes by inherited syphilis, principally in childhood, will give no general view of the present state of this question, but will discuss only the results of my personal experiences. My examinations began with the ocular syphilis of nurslings, a territory to which, until now, very little attention has been paid by ophthalmologists, with the exception of Hirschberg, at least in Germany.

A syphilitic eye affection during intra-uterine life sometimes occurs, but seems to be very rare ; equally rare are syphilitic manifestations in the newly-born. I have myself examined ten newly-born babies, whose mothers had shown certain signs of syphilis, in their first days of life, and could discover neither disease of the eyes nor of the body. Unfortunately, I had only one opportunity of making a *post-mortem* examination of the eyes ; this turned out also negative. With ocular syphilis, as with other syphilitic manifestations, it seems that in the majority of cases the disease comes to light only some weeks after birth. This is to be explained by the fact that children only become infected in the last months of intra-uterine life, and that those fœtuses which were infected earlier, either succumb to the infection before birth, or soon afterwards (Trinchese).

Twenty-seven of the nurslings of my series displayed general symptoms of syphilis ; their age was usually between two and eighteen months. Of these, six had normal eyes ; in the case of twenty-one (a very high percentage), the state of the eyes was pathological.

The first two observations concern cases of **Conjunctivitis** which was in no way of a special nature, but in spite of this, had apparently something to do with syphilis. I conclude this from the immediate success of specific therapy, while every sort of local treatment was avoided ; also from the fact that in the case of my experimental injections of cultures of spirochætes into the carotid, it was not at all rare to find that conjunctivitis, more or less severe, made its appearance as the only, or first, reaction.

*An address delivered at the Oxford Ophthalmological Congress, July, 1913.

Among my observations of congenital syphilitic patients with diseases of the cornea, I may mention some cases of **Keratomalacia**, without, however, believing that syphilis is the direct cause of this affection. The interesting discoveries of spirochætes in the cornea by Sydney Stephenson (which were corroborated by E. v. Hippel) again prove, according to my opinion, that spirochætes in the cornea are often to be found in the case of congenital syphilis, without the spirochætes themselves causing damage to the cornea. Among 31 cases in our clinic, five had congenital syphilis. I agree with the opinion of Kapuczinski, namely, that keratomalacia depends on a severe derangement of nutrition, which is often caused, or may be influenced, by syphilis.

My next observation referred to an affection of the cornea which is to be regarded as **Keratitis parenchymatosa**, although it was somewhat doubtful whether the disease of the parenchyma originated in fœtal or post-natal life. It is probable that these cases are analogous to those of E. v. Hippel, Clausen, and of Reis, and are instances of pure spirochætal affection. The retrogression of the infiltrate, and especially the speedy disappearance of the grey masses from the anterior chamber after the injection of Salvarsan, are in favour of this view. The effect of the medicament is, however, not absolutely indubitable, as two days previously, an operation for relieving the pressure had been undertaken, which no doubt had a good influence in clearing up the diffused cloudiness of the cornea (not the infiltrate).

The cause of **Iritis** in babyhood is generally congenital syphilis. It may occur without any considerable external irritation, for which reason it is probably sometimes overlooked. I will here show you, from an illustration derived from an enucleated eye, the pathological anatomy of such an iritis. You will note the infiltration of the iris with lymphocytes and plasma cells and the nodule formation ; you will observe that, in contradiction of Michel's opinion, an affection of the vessels need in no way be the precursor of syphilitic iritis, as endo- and peri-vasculitic processes are wanting in the iris and ciliary body.

A severe specific disease of the anterior uveal tract may lead to the clinical picture which we term **Pseudo-glioma**, a condition which, in spite of its apparent great rarity, I have twice had the opportunity of seeing. Risley also seems to have observed similar cases. The external view shows, as may be seen from the illustration, the pupil filled with a yellowish-red mass ; on closer examination, we see that vessels of the iris are hyperæmic as also the vessels which go over from the iris to the mass in the pupil. The pupil is more or less closed by inflammatory tissue. There may be an increase of tension. The accompanying picture gives a view of the nature of the the massive inflammatory products. For the differential diagnosis as against glioma, and for proof of the specific character of the affection, regard must be paid to the inflammatory nature of the disease, especially to the hyperæmia of the iris, and to any other signs of syphilis. The examination of the second eye is especially important.

By far the most frequent syphilitic affection of the eye in babyhood is **Choroiditis** or **Choroido-retinitis**, which takes the form of more or less numerous yellowish spots, usually situated in the periphery of the fundus. The condition was made known by Hirschberg. Most of us recognise them in the later pigmental period as being one of the most important stigmata of congenital syphilis. It appears to me to be quite possible, indeed probable, that this peripheral choroido-retinitis, when it is found in eyes in which in later childhood a keratitis parenchymatosa develops, has generally commenced in babyhood or childhood, and so belongs to the " condylomatous " phenomena

of congenital syphilis, which, according to Hochsinger, terminate with the fifth and sixth year.

To get light on this point is important when considering the question of the pathogeny of interstitial keratitis. The fact that after the expiration of the keratitis the spots of choroido-retinitis have nearly all an old appearance and are markedly pigmented, perhaps points to the fact that the choroido-retinitis had existed long before the beginning of the inflammation of the cornea. In these cases in which I found quite yellow spots, and in which, therefore, the affection might have been recent, I observed long after the termination of the inflammation of the cornea that the spots were not pigmented (the patients were usually blonde): in these cases, therefore, the choroido-retinitis had existed long before the breaking-out of the keratitis. Sidler-Huguenin has very clearly demonstated how, during many years' observation the choroido-retinitic deposits remain unchanged.

It speaks still more in the above sense that I observed in seventeen cases in the second eye, which up to that time was not affected with interstitial keratitis, old peripheral choroido-retinitis. Hirschberg, also, and especially Sidler-Huguenin, have reported that before the breaking out of the inflammation of the cornea, they could detect alterations of the fundus. It is also interesting to add here that in seven observations, in which the second eye was quite normal, I found, after the termination of the corneal affection of the first eye, the fundus without alterations.

The supposition that the choroido-retinitis is an early symptom of congenital syphilis will make the fact comprehensible that, in the case of such children the Wassermann reaction may later be negative, in spite of the existing typical alterations of the fundus.

It cannot be denied, however, that some cases of specific choroido-retinitis may progress or recur. I must not omit to mention that Sidler-Huguenin, in four cases of keratitis parenchymatosa, in which there was a typical "pepper and salt" fundus, observed after the termination of the inflammation of the cornea, new spots of pigmentation.

I can positively state that I have never, at least up to now, seen a keratitis parenchymatosa where previously the fundus was normal, and afterwards was found to be pathological. I have also never heard of such in the literature.

The anatomical characters of such a spot of peripheral choroido-retinitis is shown in the following illustration. You will observe the atrophy of the choroid and retina, especially the alterations of the pigment epithelium and immigration of the pigment to the retina.

The next picture illustrates the fact that the retina may become diseased independently of the choroid. Here the internal layers are especially affected, being infiltrated with lymphocytes and plasma cells; the ganglion cells have for the most part been destroyed; the walls of the vessels share in the infiltration; the external layers, however, are nearly normal.

We now come to **Affections of the Optic Nerve**, which, according to Hirschberg, may be observed occasionally in babies. Among my cases there was really only one in which the somewhat hazy condition of the edges of the optic disc pointed to the possibility of an inflammatory affection of the optic nerve. Besides this, in the eye, which was enucleated on account of pseudo-glioma, an atrophy of the optic nerve was found, which was due to the severe involvement of the internal retinal layers. On the other hand, another condition is very frequent in syphilitic babies, *viz.*, a strikingly pale, sometimes almost a silver-grey, tone of the optic disc, on account of which the surrounding retina is often strikingly white. One has the impression, clinically, that it is not a matter of an atrophic process, but of a high-grade anæmia.

In one case, where I had the opportunity of examining the optic nerve anatomically, the latter showed neither inflammatory nor degenerative alterations (Marchi method). The other parts of the eye were also anatomically intact.

I must lay stress upon this statement, because, in recent years, some authors have stated that affections of the optic nerve in syphilitic nurslings are a very frequent occurrence (Japha, Heine). Indeed, Heine goes so far as to say that he ascertained in the case of 105 babies at the breast, that 81 per cent had neuritis optica; and Japha, again, knows of a large number of nurslings where atrophy of the optic nerve has been present.

Although I cannot dispute the occasional occurrence of an optic neuritis, I must, nevertheless, in view of my personal experience, reject the possibility of its frequent occurrence. As regards atrophy of the optic nerve, I must refer you to the possibility just mentioned of confusion with anæmic conditions of the optic disc. Should the interpretation of the authors quoted be correct, then we should see decidedly more atrophy of the optic nerve in childhood than is actually the case. It is certainly not to be denied that, where an atrophy of the optic nerve has been established, syphilis may have played an important part as an ætiological factor. In my researches in the Halle Blind Institute (where youths under eighteen years alone come into consideration), I found among twenty-seven cases of atrophy of the optic nerve that about 25 per cent. of the patients showed signs of syphilis. In one case alone did the affection apparently date from birth or babyhood.

It is desirable that in the case of babies who have syphilis, the eye should receive very much more attention than up to now has been customary.

I now come to a very curious disease which leads me away from babies and into the pathology of childhood. It is **Nystagmus without Ophthalmoscopical Abnormalities.** The first case of this kind which I observed was in a one-and-a-half year old child with pronounced signs of congenital syphilis. The nystagmus was irregular in both eyes; left, gross and horizontal; right, slight and more rotatory. The nystagmus, as well as the other signs of the syphilis, improved after specific therapy, and disappeared altogether after a second anti-syphilitic cure.

Stimulated by this observation, I sought for a syphilitic ætiology in all the cases I could find of pure nystagmus in youths without ophthalmoscopic alterations, and the interesting fact came out that of twelve such patients, hereditary syphilis could be found in eight when sought with the help of the Wassermann reaction, etc. The positive cases varied between the ages of one and seventeen years. In six patients the fundus seemed quite normal; twice a slight specific choroiditis was encountered in the periphery, which, without doubt, had nothing directly to do with the nystagmus. Often the nystagmus was observed from birth; sometimes, however, very much later. The nature of the nystagmus was in no way uniform, but was constant even in the position of rest. With the youngest patient of one year old, the nystagmus was observed only when he stared at objects. Pendular nystagmus and nystagmoid movements, horizontal and rotatory nystagmus have so far been seen. Very often, in the cases of young children especially, when looking at objects, an oblique pose of the head, or a nodding of the head, made its appearance along with the nystagmus. Bad derangements of sight were never present; in the case of older children the vision varied between 5/5 and 5/20. The light-sense seemed—as far as could be ascertained—uninjured.

If the high percentage of identified congenital syphilis points to a connection between syphilis and this kind of nystagmus, then this supposition

would be seconded by the success of anti-syphilitic therapy in the above mentioned case, and in yet another case in a one year old child. Whether specific treatment also would be of any use in later years, I cannot so far say from my own personal experience.

For the present I will be satisfied with recording the fact, and shall avoid all theoretical discussion as to the origin of the nystagmus. But concerning the time of origin I would like to express the conjecture that it occurs in the earliest childhood. For this there are two reasons. First, the statement, often received, that the nystagmus has existed from birth; and, secondly, the fact that with older patients, of from sixteen and seventeen years, the Wassermann reaction was very weakly positive or indeed negative.

I should now like to draw attention to the **Diseases of the Lacrymal Drainage Apparatus**.

While syphilis plays quite a subordinate ætiological part in the case of dacryostenosis, blennorrhœa of the lacrymal sac, and dacryocystitis in adults, it forms for these diseases in childhood a very important cause, to which up to now too little attention has been paid. Blennorrhœa of the lacrymal sac originating in nurslings through the closing of Hasner's valve, which is very easily cured, is of course not under discussion here.

I include observations from about the second to the fourteenth year of age. In this period syphilis seems to come into consideration as the cause in at least one-half of the cases; amongst my material there are sixteen cases with signs of syphilis, against only seven without syphilitic symptoms. Occasionally, the ætiological question could not be determined with certainty.

In two cases of dacryostenosis in congenital syphilis nothing was found in the nose. In eight cases uni- or bilateral blennorrhœa was present; three times fistula of the lacrymal sac; once dacryocystitis and twice phlegmon of the lacrymal sac. I now endeavoured to find out how this disease of the lacrymal sac came about. I should not like to decide this question off-hand, as it seems probable to me that the cause is not a uniform one, but we must admit that there are two great causes: (1) an affection of the nose; and (2) an affection of the bony wall of the lacrymal duct.

A syphilitic affection of the lacrymal sac itself hardly seems to come into consideration; at least, in three cases no specific alterations could be discovered anatomically in the extirpated sac, but only lymphocytic infiltration, and I could find no spirochætes in the tissue. In nine cases nasal abnormalities were observed, but in only five of these did they look like syphilitic affections (among these, four times "saddle-nose" and alterations in the bony framework); four times the condition of the nose was normal, apart from adenoid vegetations. Once there certainly was a dacryocystitis, and once an abscess underneath the surroundings of the lacrymal sac, probably connected with the periosteum. This dacryocystitis got well very quickly with anti-syphilitic treatment. With blennorrhœa of the lacrymal sac in which there is no external inflammation, I have had up to now no success with specific therapy; perhaps the phlegmonous inflammation will offer a somewhat better prospect. We shall probably not be able to dispense with surgical measures. In spite of this, it seems to me that the knowledge that the affections of the lacrymal drainage apparatus, so frequent in childhood, are connected with syphilis, is of diagnostic and therapeutic importance.

Little is said in the literature about the fact mentioned above. Thus, Chaillous, Terson, Antonelli, and Stieren emphasize the fact that they have sometimes seen cases of dacryocystitis in congenitally syphilitic persons; and Sidler-Huguenin observed among his 125 patients with congenital syphilitic

choroido-retinitis, four times dacryostenosis, once fistula of the lacrymal sac, and once dacryocystitis.

Other eye-affections in childhood pointing to syphilis are so well known in their ætiology that it will suffice if I touch upon them briefly in passing. I allude especially to paralysis of the eye-muscles, and among these, above all, paralysis of the internal eye-muscles. Improved methods of diagnosis have more deeply established the doctrine that, when these affections are not hereditary, and especially when they make their appearance on one side, they are almost without exception of syphilitic origin.

Before finishing this address, I should like to make a few remarks about some investigations on **Keratitis parenchymatosa**, with which I have occupied myself a good deal lately; above all, about two questions:—(1) The origin of this common and obscure disease; (2) The after-fate of patients who have suffered from it.

In order to obtain an idea of the method of origin of keratitis parenchymatosa, it is, above all, necessary to set out with no prejudiced ideas, but to keep in sight all the facts which have been found up to the present. In the following table I have set forth these facts, and the points which are related to one another, I have written side by side.

ANIMAL.	MAN.	
	INHERITED SYPHILIS.	ACQUIRED SYPHILIS.
By injecting *Spirochæta pallida* into the blood, keratitis parenchymatosa is produced. The micro-organisms penetrate the cornea. *Spirochætes* abound in the *blood* (on injecting, sometimes later also). *Anatomically.*—Enormous immigration of lymphocytes and leucocytes into the cornea. Unimportant alterations of the corneal-cells. *Effect of anti-syphilitic remedies* very good and prompt. General and local *anaphylaxis* is produced against this antigen on injecting a foreign species of serum into the cornea, by which means a keratitis parenchymatosa may be produced. The first injection may be well supported, whereas a second intravenous injection starts a keratitis parenchymatosa in the previously inoculated eye.	(*a*) In the case of *Fœtus and Newborn.* *Spirochæta pallida* was often found in the clear cornea, and in the one with keratitis parenchymatosa. *Spirochætes* certainly abundant in blood at a certain time. *Anatomically.*—Abundance of leucocytes. Unimportant alteration of the fixed corneal cell. (*b*) *In small children from 6—8 years.* Course of the keratitis parenchymatosa faster, and clearing-up of the corneal cloudiness often better than later.	(*c*) *In older children and adults.* *Spirochæta pallida* once found in keratitis parenchymatosa: generally cannot be demonstrated. *Spirochæta* very rare and when present at all, very scarce *in the blood.* *Anatomically.*—Disintegration of the fixed corneal cells, necrosis of the lamellæ, little or no lymphocytic infiltration. *Effect of the anti-syphilitic remedy* usually unimportant, doubtful, or non-existent.	*Origin.*— 1. *Local infection* by syphilitic affection of the conjunctiva or of the lids. 2. After an antecedent congenital syphilis with reinfection. 3. *Acquired syphilis alone.*

Experiments with animals have shown, so far, that keratitis parenchymatosa which has been experimentally produced endogenously, is chiefly a

pure spirochætal infection caused by the treponema, which abounds in the blood and penetrates the cornea. The anatomical signs of an acute inflammation, and the prompt effect of anti-syphilitic remedies, agree with this. While the keratitis parenchymatosa generally observed in man, as shown in Column 3, differs in all points from the condition in animals, it seems to me to be of great interest to note that in the case of the fœtus and nurslings (Column 2), a striking agreement exists with the condition in the case of animals. I think it probable, therefore, that the keratitis parenchymatosa of the fœtus and nurslings is also a purely spirochætal infection. The spirochætes, however, which sometimes get into the cornea of the congenital syphilitic during fœtal life, cause an inflammation of the corneal tissues only in rare cases; but they subsist for a longer or shorter space of time in the cornea. It may be taken for granted that many of them die off slowly. However, with this death of the spirochæta and the liberation of endo-toxic products, a specific tissue change (*Umstimmung*) makes its appearance; or, to express it differently, there is an anaphylaxis of the cornea. The older the individual, the more probable is it that anaphylaxis will be prominent, and that the living spirochætes will become fewer or disappear. From this point of view the clinical fact is worthy of note that, in small children, under six or eight years of age, the course of the keratitis is quicker, and the clearing up of the corneal cloudiness is often better, than in later life.

Leaving out of account interstitial inflammation of the cornea in the fœtus or newly-born, it seems to me necessary to hypothecate two things for the causation of keratitis parenchymatosa:—

(1) The spirochætes themselves.

(2) The specific tissue change (*Umstimmung*) of the corneal tissue.

The two conditions are often existent for years without corneal inflammation developing. The question is therefore:—"How is the inflammatory process really started?" From our former considerations it is not to be supposed that the initial cause is represented by the spirochætes in the circulating blood, but it seems much more plausible that somewhere in the tertiary stage of hereditary syphilis, specific toxic products from some of the syphilitic foci which are to be found in the body have got into the circulation. If these come into the specifically unchanged cornea, they may cause in it an anaphylactic reaction in the form of a keratitis parenchymatosa; a reaction which is very similar to the anaphylactic keratitis produced in animals by introducing a foreign species of serum. Possibly the specific toxic substances which get into the cornea exert an influence also on the spirochætes which may happen to be living, so as to excite an inflammation.

The facts so far determined may be correlated well with this explanation, which supposes two processes acting alongside of one another. For example, without going further, it is quite comprehensible that it should be generally impossible to find the spirochæta in trephined pieces of cornea affected with interstitial keratitis in older children and adults, as in them the organisms are too few in number. That they exist is nevertheless proved, to a certain degree, by the one example of organism which I have found.

With this explanation, the conditions which obtain in the keratitis parenchymatosa of acquired syphilis will, moreover, be much clearer. It is not to be wondered at, that in acquired syphilis only insignificant numbers of spirochætes are present in the circulation, and that they can be found only for a short time. The syphilitic micro-organisms very rarely penetrate the cornea. One of the hypothetical conditions of the origin of a keratitis parenchymatosa is, therefore, wanting; hence its rareness in acquired syphilis.

It is very interesting to note that the appearance of parenchymatous keratitis has several times been observed in people who besides having acquired syphilis, have also inherited the disease. I assume that in these cases the two predicates—immigration of spirochætes to the cornea and the specific change (*Umstimmung*) of the corneal tissue—have been fulfilled by the congenital infection; and it only needed the third factor, immigration of toxic products to the blood during the course of the acquired syphilis, to cause the inflammation of the cornea.

It would be very much to the purpose, if during the further observations of keratitis parenchymatosa in acquired syphilis, an attempt were made by means of exact investigations of family histories (inclusive of the Wassermann reaction), to find out whether there were not hereditary syphilitic individuals who have re-infected themselves.

The keratitis parenchymatosa which originates in conjunction with syphilitic processes of the conjunctiva and the eyelids, should be regarded as a pure spirochætal infection arising *per continuitatem.*

I should like briefly to demonstrate a few tables concerning the after-fate of the patient who has suffered from keratitis parenchymatosa. The first table

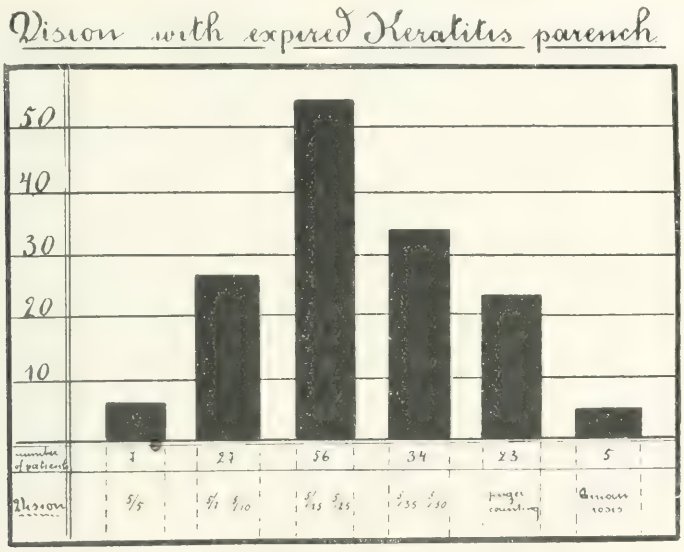

Fig. 1.

shows how the vision behaves in cases of keratitis which have been obsolete for many years. It will be seen that 40·80 per cent. of patients with bad eyesight are opposed to 59·2 per cent. with fairly good visual acuteness up to 5/25 inclusive. The prognosis is, therefore, *quoad* vision, much worse than one would generally suppose.

The second is based on an enquiry and on an objective determination of facts. It demonstrates how keratitis parenchymatosa encroaches upon the power of earning one's living. Of seventy-seven patients, forty-three are to be regarded as permanently injured in their livelihood or power of gaining a living; among the twenty-eight who were not injured, many were to be found who had already gone through keratitis parenchymatosa as school children, and so could select a profession to suit their eyes.

The next table (Fig. 3) gives a general view of how far the tension of the eye is altered in keratitis parenchymatosa, and how the disease, even after its cure, may still have an injurious effect. As seen, the reduction of the

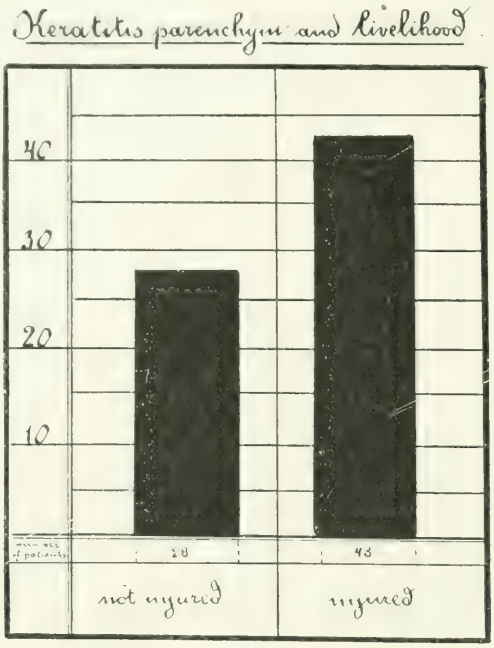

Fig. 2.

tension generally completely recovers after the expiration of the disease, while after some years increase was observed with the Schiötz tonometer in more than ten per cent of the cases. There may be a typical contraction of the field of vision, as is usual in glaucoma, or even amaurosis.

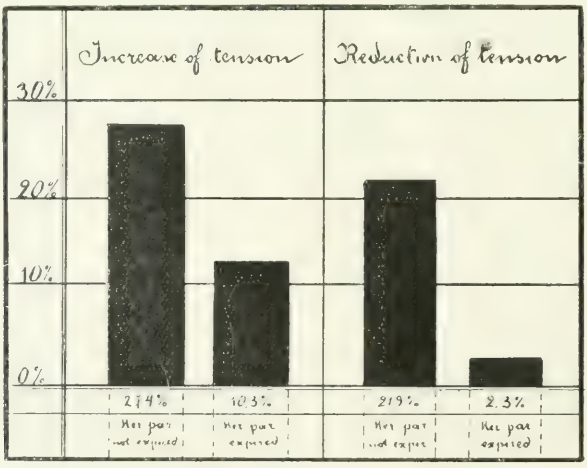

Fig. 3.

So far I have spoken of the influence of diseases of the eye itself on the lot of the affected individual, but I must now mention that other bodily infirmities,

which may be traced to syphilis, may also considerably injure the lot of the person affected with keratitis parenchymatosa. Especially well known are the diseases of the ear. On the other hand, it may not be so well known that, as I proved by an exact investigation of the nervous system in 101 cases, nearly one-half of all congenitally syphilitic persons who have, or have had, keratitis parenchymatosa, show some signs of disease of the nervous system.

Another table (not reproduced) illustrates a very important and vital question, *viz.*, how the Wassermann reaction acts years after the expiration of the affection of the cornea. You will perceive from the table that it becomes quite gradually negative. In some patients, however, after several decades, it will be found positive. Specific treatment increases the negative reaction; but, nevertheless, a negative reaction may veer round later in cases so treated to a positive.

The effect of syphilis is also to be found after the second generation. The mother who has inherited syphilis is not uncommonly barren, or nearly barren. The descendents often show, as E. Treacher Collins, among English ophthalmologists, has especially emphasized, dystrophic symptoms, and in some cases it even comes to a transmission of syphilis to the third generation. I have myself observed such a case.

These few considerations as to the fate of the patient who has suffered from interstitial keratitis serve to show that we have to deal with a very sad chapter of ophthalmology.

It must be our constant endeavour to cure, or better still to prevent, this disease. Both are difficult, but it seems to me that prophylaxis is indeed really easier than cure, because we know that this affection of the cornea often defies every remedy. Prophylaxis must begin with the child, soon after birth, and when this is not possible, then in later childhood. Every doctor must endeavour to treat the wives and children of syphilitic persons, even when these relations as sole manifestation show a positive Wassermann reaction. The foundation of homes for hereditary syphilitic children, such as already exist in Copenhagen and Berlin, also possibly blood testing of school-children, especially if combined with treatment, would bring us considerably forward in our fight with congenital syphilis. I hold this war against hereditary syphilis to be a necessity, in the first place out of sympathy for the innocent victims of the disease, and, again, out of interest for the country in general, for the State loses, totally or in part, through keratitis parenchymatosa alone, the services of a large number of persons who should be capable of gaining their livelihood.

THE VISUAL FIELDS IN COAL MINERS' NYSTAGMUS.

BY

BERNARD CRIDLAND, D.O.Oxon., F.R.C.S.E.

WOLVERHAMPTON, ENGLAND.

BUT little attention seems to have been paid to the condition of the fields of vision in coal miners' nystagmus. Beyond the statement in an article by Dransart and Famechon entitled "Nystagmus from a medico-legal standpoint" (THE OPHTHALMOSCOPE, Vol. VI, p. 631), to the effect that "the visual field shows no change," no reference to the sign is to be found in the

literature for the past six or seven years, a time during which the disease has been receiving greater attention.

A statement such as the above must be a little astonishing to those who have taken the trouble to investigate cases systematically with the perimeter, and the explanation that no other reference has appeared can only lie in the supposition that it has not been thought worth while to make the investigation on account of the oscillatory movements of the eyes which might lead to misleading results.

In the severe cases where nystagmic movements are almost constant or very easily induced, it is of course impossible to take the fields, but in those which are recovering or in which nystagmic movements have never been a marked feature (in a word "suitable cases"), it is quite easy to use the perimeter, and, moreover, to rely upon the results obtained.

In the investigation of some sixty or seventy cases, I have been able to take the fields of vision in about twenty-five, all of which have shown alterations, some of a very striking nature.

Nearly all these cases were of the "grave" type; that is to say, occurred in men who had been forced to give up their work on account of the disturbances to their vision and central nervous systems. Cases in which the possibility of contractions from other causes might be present have been disregarded.

The fields were taken with a McHardy-Lang perimeter, using the 20 mm. square for white, blue, and red, and all save in one case in good daylight. The normal limits taken for comparison were in the case of white those shown in the charts issued by Messrs. Weiss for the perimeter used, and for blue and red those given by Baas.

The charts of some nineteen of the cases were shewn by me at the Oxford Ophthalmological Congress in July, 1913, but it is hardly possible, on account of space, to reproduce them here.

An examination of the charts, nearly 70 in number, has revealed the following points:—

(1) In practically all the cases contraction exists for white, blue, and red.

(2) The contraction is of the concentric type and symmetrical in shape, although not always in depth.

(3) In the majority the colours are in their correct order, but occasionally interlacing of the red and blue may occur, recovering their correct order as the case improves.

(4) The contractions for red and blue are generally greater than those for white, and rather greater for red than blue.

(5) By grouping the cases into mild, moderate, and severe types according to the intensity of the attack, the fields broadly show corresponding contractions. In one very severe case the field for white was contracted to the 20° limit temporally and to 10° elsewhere in each eye, that for blue to 4°, whilst red was only recognised at the fixation points. In two cases which must be classed as of the "light" form, for nystagmic movements existed without, I believe, the patients being aware of them, very slight contractions were present for white and definite contractions for blue and red, the latter being the more marked.

(6) Generally speaking, as the disease improves, the fields of vision improve, but contractions persist as long as any subjective symptoms are present, and although nystagmic movements cannot be elicited by any test.

(7) Slight contractions for white may, perhaps, be permanent, and to a greater degree for red and blue, especially for red. One case showed that this may be so. A man of 52 had suffered from an attack lasting nearly three years, but at the time of examination had neither signs nor symptoms

yet the fields, taken just after recovery, showed contractions as above stated. I have had no opportunity of examining this case since, or of examining any case long after an attack has completely cleared up, and am, therefore, unable to say at present whether it is usual for some contraction to persist.

(8) Most of the cases showed more or less marked signs of "neurosis" such as blepharospasm, neck-twitching, etc., but there seems to be no direct relationship between the presence and degree of these signs, and the degree of contraction of the visual fields, except that both may be well-marked in a severe case.

Comments.

The similarity which these fields present to those found in traumatic neurasthenia naturally suggests that the nystagmic field is of the same nature, and to say that this is so is to explain it easily and, perhaps, truly. On the other hand, it is impossible to look upon the sturdy specimens of humanity who frequently present themselves suffering from the disease and who shew these alterations in their visual fields as neurasthenics. The most marked example of all, whose case has been specially referred to above, appeared to be anything but a neurasthenic in the general sense and acceptation of the term.

It may naturally be asked what is the value of this sign, one which takes some trouble and occupies some time to elicit.

I suggest that it is of value in determining the existence or persistence of nystagmus in a case in which subjective symptoms alone are complained of and these on occasions only, and in which no nystagmic movements can be elicited by any test.

The fact that a contraction may remain permanently even when signs and symptoms have disappeared, does not, I think, necessarily diminish this value.

It is impossible until a greater number of results have been brought forward by observers other than myself, to draw any definite conclusions on the nature and value of the above findings. But there are a few points which stand out as the result of the consideration of even these few cases, namely: the frequency with which contractions of the field exist in coal miners' nystagmus, occasionally to a very marked extent; the greater contraction of the colours red and blue, as compared with white, and particularly of red; and, finally, the manner in which the contractions tend to disappear as the case improves.

DIRECT OPHTHALMOSCOPIC EXAMINATION WITH INDIRECT VISION AND ILLUMINATION.

BY

JOHN BURDON-COOPER, D.O. (Oxon.),

BATH, ENGLAND.

THE letter of Dr. H. Gifford in the March, 1913, number of THE OPHTHALMOSCOPE with reference to indirect lighting in examination of the fundus by the direct method, coupled with its importance and utility, has urged me to contribute this short note on its consideration, and also to describe my own method, using not only indirect illumination, but also indirect observation.

It is probable a great many observers, as Professor Haab points out in his article (*Beitrage z. Augenheilk.*, Heft 75), have used this method of Nagel's of

indirect lighting for the examination of fine detail in the fundus, and probably many more have done so without being at all conscious that the accuracy of the impression they had gained of any particular lesion was to a large extent dependent on the more widely divergent rays of the beam of light, or, in other words, the peripheral portion of the light area, and also of the ease with which it is possible to vary the illumination within very wide limits. Such is, nevertheless, the case, for if we consider the light produced by converging a beam of light by means of the small mirror of the ophthalmoscope on the fundus oculi, we notice that its brightness is not uniform, but that it diminishes from the centre to the periphery.

This diminution is not uniform, for over a very considerable area, at any rate to the normal eye, there is very little perceptible difference, but near the periphery the brightness diminishes rapidly, and this diminution occurs centrifugally within a comparatively narrow interval, beyond which all the fundus lies in complete shadow. This interval is produced by the more scattered peripheral rays of the beam of light. It is easy to understand how, by displacing the centre of the light area, the position or object in the fundus under examination is viewed under gradually decreasing illumination until the latter is so reduced that the ratio between the brightness of the object and the general fundus level falls below the lower limit of the fraction of Fechner, when the object will be invisible. The visibility of any fundus object is dependent on its colour, size, and form, and also on the illumination under which it is viewed.

We might digress here a little in order to consider the influence which decreasing the illumination has upon the visibility of the different colours. At the outset two things must be rigorously distinguished: (1) the general illumination under which the observer's eye is placed, and under which the colours are viewed, and (2) the alteration in the intensity of the colours themselves caused by varying the general illumination.

The lighting of the eye has a distinct influence on the perception of the different colours, an influence which is just the reverse of that produced by a variation of the brightness of the colours themselves. Suppose for the sake of clearness we take four 5 cm. squares of paper, red, yellow, green, and blue, which we think to have the same brightness by daylight illumination. By dimishing the illumination the blue paper will appear to be brighter than the red; with very feeble illumination the red paper will appear black, and the blue pale grey. If however the general illumination remains constant, and the squares be gradually cut down, it will be found that the red can be recognised much more readily than the blue, and that even when the area is smaller. It is necessary for this experiment to succeed that the paper be seen under an angle which is not too small, for it is only slightly marked for the macula.

Charpentier has shown that the apparent brightness of the more refrangible colours diminishes less in decreasing illumination than that of the less refrangible, so that red observed under gradually diminishing illumination will present the greatest change; with very diminished illumination a retinal hæmorrhage, for instance, will be so dark as to be almost indistinguishable, from, say, a patch of choroidal pigment. The next greatest change ought to be observed with the yellow, as this is less refrangible than green or blue, but that is not the case, as another factor comes in to modify the final result, *viz.*, the brightness of the colour itself. In the spectrum it is the yellow and green which have the greatest brightness. The brightness diminishes toward the extremities, but more toward the blue than toward the red, so that of the four colours yellow is seen the best, although the colour is greatly altered,

becoming a dirty yellowish-white reflecting little light. If the illumination is increased it is the yellow square which will show its colour first. The green square with diminished illumination appears almost black, but if the illumination is not too feeble, there is a sensation of dark olive-green. The blue square will appear pale grey. It may be difficult to distinguish between the luminosity of the yellow and blue squares. If no difficulty exists the yellow will appear the lighter. It is necessary in this experiment that the squares should be of the same size, as the light reflected is directly proportional to the area.

The influence which diminution of the size of the coloured object or its retinal image respectively has upon the apparent intensity of the colour is quite a measureable quantity. Red, yellow, green, and blue may be seen equally bright when their retinal image is of a certain size, but this equally disappears when the size of the retinal image decreases, the diminution in brightness being most marked in the more refrangible colours, while the decrease in brightness, due to diminution of their illumination, affects the less refrangible colours most.

On lessening the luminous intensity of the colours, the yellow and blue disappear first. On still further diminishing the brightness, the blue becomes blue-grey; and the green, green-grey; red, brownish; and finally all the colours disappear. Red does not seem to change into grey before disappearing. The appearance of the four squares is the net result of the diminution of the illumination, combined with the diminution in the brightness which results from it. So much, then, for the influence of diminished illumination on the four primary colours. In the fundus we are only concerned with red and yellow and their different shades.

Not only does this method admit of us viewing details of the fundus under different illuminations, and so arriving at conceptions of their size, form, and colour, but it also admits of us viewing them under the feeblest illumination possible. This is an important point, as, generally speaking, fine detail of the fundus should be examined under the feeblest light compatible with good vision, since not only is the observer less troubled with useless scattered light, but his retinal sensibility is relatively increased and he is in the position of being more readily able to appreciate very fine changes, which it would be impossible for him to do if the light was extremely bright.

Such, then, are the theoretical considerations of the method of eccentric illumination. Its practical application is simple.—Light is thrown into the eye by the small mirror of the ophthalmoscope as in direct ophthalmoscopy, and the light area on the fundus is displaced by turning the mirror so that the object is lighted by the more peripheral rays, and a position is found under which the object is seen to the best advantage.

In order to avoid ambiguity in connection with the terms "direct" and "indirect" being applied not only to ophthalmoscopy, but also to this special application of it, it would be well to make a distinction and use the term "eccentric illumination" in connection with this method, and to define the latter as that form of illumination in which the part of the fundus observed is made to occupy a portion near the periphery of the light area, and not in the centre, as is usually the case. As I have stated above, the visibility of any object depends on its colour, size, and form, and also on the illumination under which it is viewed. This is true so far as it goes, but it also depends on the manner of observation. We may view an object directly, in which case its image falls on the fovea, but it may also be viewed indirectly by the para-fovea. The value of this para-foveal acuity was brought to my notice many years ago by a very simple observation:

When walking by the side of a green field I happened to notice a small blue flower which, when viewed directly, could not be discerned as to colour, but viewing it indirectly or eccentrically, that is, looking at a short distance to either side, the colour became at once apparent. I append a little diagram which I have drawn to illustrate this point. The crossed drawing has hidden within it the figure VI in Roman numerals. If the diagram be viewed in moderate light, the eye fixing the centre spot for one minute, the form of the VI will be seen with the greatest difficulty, if at all, whereas if the gaze be directed to the asterisk on the centre of the bottom line, it at once becomes apparent. With the diagram it can also be ascertained that the upper part of the para-fovea is more sensitive than the lower, and the outer more than the inner.



The fovea, as we know, possesses the maximum sensibility for the sense of form, so that to gain an impression of any object we "fix" with it. Form perception is a complex faculty. To judge the form of objects we grope for them, so to speak, with the look. Indirect vision furnishes some idea of the form of objects, but it would appear to be the displacement of the look that has taught us the meaning of the impression obtained in indirect vision.

It is stated that images cast on the marginal portion disappear before those cast on the central part of the fovea, indicating that the fovea possesses not only maximum sensibility, but is less liable to fatigue. The acuity of the para-fovea exceeds that of the fovea itself as regards light perception. This is proved by the observation I have given above, and also by the following: that in the dark an object slightly darker than the background and indistinguishable from it when it is fixed is easily distinguishable when the gaze is directed to one or other side. The same applies in distinguishing faintly visible stars or in following a feebly marked mountain path It is also true within wide limits of total illumination and for monochromatic as well as for white light, as I have described elsewhere. It has been pointed out, presumably dependent upon this observation of my own on indirect observation, that miners' nystagmus may be the result of an endeavour on the part of the eye (by assuming an eccentric position) to secure under the extremely feeble illumination of the mine the clearer vision that the para-fovea gives. Whether this be so or not, the fact remains that the para-fovea is considerably more sensitive to light and colour than the fovea itself, and the form sense is to some limited extent dependent, too, on the para-foveal region.

My own method, then, consists in the combination of both eccentric illumination with eccentric vision for the examination of fine detail of the fundus. We have seen the influence of diminished illumination and we have also

shown that the para-fovea is more sensitive to both light and color. By combining the two we have the best possible means of arriving at an accurate conception of any difficult point that may present itself in an examination of fundus detail.

Before concluding I will briefly describe the method of examining, say, a small doubtful spot at the macular region.—We proceed as for direct ophthalmoscopy, and when we have got the light area on the fundus we decentre this, so that the periphery of the luminous area lights the spot. By slightly tilting the mirror we find such a position as gives the best possible view. Now if instead of looking directly at the spot we cast the gaze a trifle above or to the left side of it, and then bring it back again directly to the spot and repeat this two or three times, we get a much better conception of the form, color, and size and position than if we looked steadfastly at the spot all the time. The method of indirect vision is also of the greatest service in microscopy, as any who care to try it will find, and especially is this the case in the examination of bacteria and other minute objects.

I have used the method mainly for the examination of the small spots of superficial choroiditis frequently met with at the macula and also for observation of the changes in the vessels in intra-ocular angiosclerosis, beading of the vessel walls, irregularity of calibre, small hæmorrhages, changes in the disc margins, doubtful spots, pigment or hæmorrhage, pulsation of vessels, and generally any small detail the nature of which is not certain or the characters brought out by direct ophthalmoscopy.

In conclusion, I need only say how feebly I have approached in these remarks a subject which involves so much if we care to study it, but if I have succeeded in drawing attention to and popularising a method of fundus examination, the field of usefulness of which will extend the more we familiarise ourselves with it, then my efforts will not have been wholly in vain.

NOVELTIES.

TARSAL CYST FORCEPS.

BY

ARTHUR GREENE, M.A., M.D., F.R.C.S.I.,

HON. ASSISTANT SURGEON, NORFOLK AND NORWICH INFIRMARY, ENGLAND.

THE frequent use of tarsal cyst forceps has led me to design one with a view to, if possible, amplifying the advantages of such an instrument.

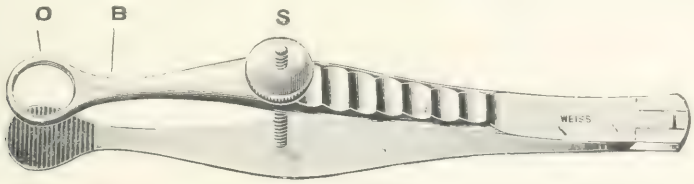

The particular points about the instrument illustrated are:—(*a*) The size of opening "O" is sufficiently large to allow dealing with a cyst of large size. (*β*) Both the upper and lower aspects of the blades are serrated to prevent slipping. (*γ*) The blades are especially shaped at "B" to allow for the thicker lid edges. (*δ*) Pressure is exerted by means of a thumb screw "S,"

thus permitting not only more accurate adjustment, but also more convenient and gentle manipulation during application and removal than is possible with any form of rachet arrangement.

The forceps is made and sold for half-a-guinea by Messrs. Weiss & Son, London, but has in error been described in their current Ophthalmic Catalogue as an "Expression" forceps.

CURRENT LITERATURE.

NOTE.—Communications of which the titles only are given either contain nothing new or else do not lend themselves to abstract.

I.—LIGHT AND THE EYE.

(1) Hertel, E.—Questions on the biological action of light. (Ueber lichtbiologische Fragen.) *Zeitschrift für Augenheilkunde*, November, 1911.

(2) Hertel, E.—A further communication upon the excitability of the retina by rays of light. (Weitere Mitteilung ueber die Erregbarkeit der Netzhaut durch Lichtstrahlen.) *Bericht der Ophthalmologischen Gesellschaft*, Heidelberg, 1911.

(3) Vogt, A.—Experimental investigations on the permeability of the transparent media of the eye for the ultra-red portion in artificial sources of light. (Experimentelle Untersuchungen über die Durchlässigkeit der durchsichtigen Medien des Auges für das ultrarot künstlicher Lichtquellen.) von Graefe's *Archiv f. Ophthalmologie*, Bd. LXXXI, Heft i, 13 Februar, 1912.

(4) Behr, Carl.—Contribution to the inquiry into the changes and injuries produced in the eye by light. (Beitrag der Fräge nach den Veränderungen und Schädigungen des Auges durch Licht.) von Graefe's *Archiv f. Ophthalmologie*, Bd. LXXXIII, Heft iii, 13 August, 1912.

(5) Stähli, Jean.—On investigation of the eye with the Nernst light. (Zur Augenuntersuchung mit Nernstlicht.) Deutschmann's *Beiträge zur Augenheilkunde*, Heft lxxxii, 1912.

(6) Wydler, V.—Experimental researches upon after-images due to dazzling and their relationship to dazzling erythropsia. (Experimentelle Untersuchungen über Blendungsnachbilder und deren Verhältniss zur Blendungserythropsie.) *Zeitschrift für Augenheilkunde*, Mai and Juni, 1912.

(1) According to **Hertel**, of Strassburg i. E., the irritation caused by light can act upon the living cell if the cell can absorb the rays. The absorptive power of plasma for the short wave length ultra-violet rays is very great, and in consequence their power, even in low intensities, soon becomes obvious. If the conditions be favourable for the absorption of rays with a long wave length, in tissues supplied with pigment or with chlorophyll, then the difference in action between long and short wave lengths disappears. Hertel has succeeded in obtaining signs of irritation with long wave lengths of the same intensity as short wave lengths by a process of biological sensitization (Dryer). Experiments have proved that light possessing wave lengths between the

extremes of 200 μ to 2,000 μ are able to cause symptoms of irritation. The effects are more easily elicited towards the ends of the spectrum, but all waves can be made to produce an equal effect, although different methods must be employed. T. HARRISON BUTLER.

(2) Little is known about the exact changes which take place in the retina when it is excited by a ray of light, and what little we imagined we knew has been contradicted by the discoveries made by Angelucci, Englemann, and others, that contraction of the rods and pigment-wandering can be induced by electrical, by mechanical, and by thermal stimuli, as well as by light. **Hertel**, of Strassburg i. E., has endeavoured to gain further knowledge by trying to discover the feeblest light intensity (measured in wave lengths) which sufficed to elicit an objective and subjective response. Were there any marked difference between the intensities necessary to cause an objective change and a subjective sensation, then the two phenomena would be causally disassociated ; if, however, the reverse were the case, then it would be logical to conclude that the objective changes were intimately connected with the sensation of light.

There were great difficulties to contend with at the short end of the spectrum, on account of the phenomena of fluorescence. Ultimately, however, it was ascertained that the contractions of the rods could be elicited up to the Cadmium line ($\lambda = 226\ \mu$) when the light was allowed to act upon a piece of excised retina of a frog. At the other end of the spectrum, contractions could be determined with wave lengths of 800 μ. Waves of 850 μ were without action. These values correspond with those determined by Helmholtz for the visibility of the spectrum, and so the research lends colour to the theory that the objective retinal changes are associated with the visual act.

T. HARRISON BUTLER.

(3) While the physiological action and their possible danger has been extensively studied for both the visible and the ultra-violet portion of the spectrum, the ultra-red or heat-rays have been comparatively neglected. This was no doubt due to the generally accepted theory of Drücke and Helmholtz, that they are completely absorbed by the liquid media of the eye.

Vogt, of Aarau, shows that these experiments were faulty, and that it requires very much deeper layers of water, which is colourless for ultra-red rays, to absorb them; as a rule, and especially for electric light, they far outnumber the visible rays as they penetrate into the retina, and it is a very interesting proof of the specific action of the neuron that no reaction takes place. But it must be borne in mind that it requires white heat to send these rays out, as in every other case the heat rays are as good as completely absorbed within the media. In the case of white heat, however, injuries both to the media, especially the lens, and to the retina can be produced, and it is very likely that heat rays play a more important part in the production of glass-blowers' cataract than the ultra-violet rays. Electric light contains a much greater proportion of heat-rays than daylight, and this may account for the common asthenopic complaints of painful "glare" under its use. R. GRUBER.

(4) Artificial light, which is very rich in short-waved rays, produces considerable reduction of the adaptability of the retina in the dark. **Behr**, of Kiel, finds that patients thus affected complain of scintillation and decrease of vision, especially in lookihg from the dark into the light. There may be slight conjunctival injection, but no other pathological symptom, and the trouble subsides if rational illumination is resorted to. The complaint may be termed "ophthalmia electrica chronica." A similar condition exists in aphakia, as the lens acts as a natural filter in retaining the short-waved rays (up to about 330 μ.); persistent use of correcting lenses sometimes

counteracts this difficulty ; in any case most patients seem hardly to notice it, and no permanent injury to the visual membranes is caused thereby.

R. GRUBER.

5) **Stähli**, of Zürich, recounts several observations which he has been able to make with the help of the Nernst lamp, used as a source of oblique illumination, and the Hartnack and Berger *loupes*. The first observation is an appearance somewhat resembling droplets of dew on the posterior surface of the cornea. This appears to be in some way associated with iritis, sometimes when other symptoms of iritis are present, or when an iritis is apparently cured, at other times in the absence of any other evidence of iritis but disappearing under the use of atropine.

His second observation is, that if the Nernst light is focussed through the pupil by means of a convex lens, we may observe minute defects in the iris which are not otherwise visible. They are rendered visible by the return rays shining through the defective portions of the iris. Sometimes when the iris has been wounded by a chip of metal, the anterior layers of the iris heal, but a defect of the posterior layers persists. It is in cases like these that this method of illumination is of value.

Two other conditions which have been more frequently observed since the Nernst lamp has come into use are, the minute punctate epithelial defects scattered over the corneal surface in certain cases of conjunctival catarrh, and rudimentary remains of the pupillary membrane, which are much more common than is generally supposed. A. J. BALLANTYNE.

(6) This paper, by **Wydler**, of Aarau, first enters in great detail into the history and literature of erythropsia, and then describes a large number of experiments. The communication does not lend itself to useful abstract.

T. HARRISON BUTLER.

II.—THE SENSORY PUPIL REFLEX IN TOBACCO AMBLYOPIA.

Dorrell, E. Arthur.—The sensory pupil reflex in tobacco amblyopia. *Trans. Oph. Soc. U.K.*, Vol. XXXIII, 1913, p. 148.

Dorrell, of London, has investigated the sensory reflexes of the pupil in 100 patients (197 eyes). The total included :—1. Healthy persons ; 2. Cases of tobacco amblyopia ; and, 3. The subjects of nervous affections. The room was darkened, and the patient was directed to look at an electric light suspended at a distance of about nineteen inches above his head. An electric stimulus was next applied to the neck on the same side as the eye under examination, and the movement of the pupil was noted. The negative electrode was applied to the neck the positive being meanwhile held in the patient's hand. The number of cells of the constant current required to produce dilatation of the pupil was noted. The general result, as summed up by the author, appears to show that the sensory pupil reflex is either difficult to obtain, or absent, in a very large percentage of the cases of tobacco amblyopia. The sign is not confined to tobacco cases, but may also be found in degenerative diseases of the spinal cord. In cases where there is a doubt, Dorrell considers that it may render valuable aid. SYDNEY STEPHENSON.

III.—LAMELLAR CATARACT AND TETANY.

Hesse, R., and Phelps, E.—Lamellar cataract and tetany. Schichtstar und Tetanie.) *Zeitschrift für Augenheilkunde*, März und April, 1913.

Hesse and **Phelps**, the former working at Gratz in Professor Salzmann's clinic, the latter attached to Professor Hartmann's neurological clinic, seek to show the close association which exists between lamellar cataract and tetany.

Forty-three patients were carefully examined in the neurological clinic for signs of tetany, and 35 of them, that is 81 per cent., gave absolute evidence of tetany. The tests used were, examination for Chovstek's sign, Erb's electric reaction, and Trousseau's sign, and, finally, the condition of the teeth. These teeth have usually been called rachitic teeth, but they are really, the authors state, associated with tetany. Only two cases were definitely rachitic and in these patients the disease was only slightly developed. Slight evidence of rickets was found in four other cases, six in all, or 17 per cent. Male and female were almost equally affected with tetany. The authors reject the theory that the cataract is caused by tetanic spasm of the ciliary muscles; they regard the tetany and the alterations in epiblastic structures, lens, teeth, nails, etc., as effects of the same ætiological factor. Tetany must be looked upon as an associate of other forms of juvenile cataract, as well as of lamellar cataract.

T. HARRISON BUTLER.

IV.—THE HISTORY OF SPECTACLES.

(1) **Greeff, R.—The oldest preserved eye glasses. (Die ältesten uns erhalteren Brillen.)** *Archiv f. Augenheilkunde*, August, 1912

(2) **Greeff, R.—Fragmentary contributions to the history of spectacles. (Bruchstücke zur Geschichte der Brille.)** *Klin. Monatsbl. f. Augenheilkunde*, Januar, 1913.

(3) **Greeff, R.—Fragmentary contributions to the history of spectacles. (Bruchstücke zur Geschichte der Brille.)** *Klin. Monatsbl. f. Augenheilkunde*, Februar, 1913.

(4) **Greeff, R.—Fragmentary contributions to the history of spectacles. (Bruchstücke zur Geschichte der Brille.)** *Klin. Monatsbl. f. Augenheilkunde*, April, 1913.

(5) **Oliver, George H.—An address on the history of the invention and discovery of spectacles.** *British Medical Journal*, October 25th, 1913.

(1) **Greeff**, of Berlin, has looked through many museums, where almost everything that one needed was exhibited, without finding such interesting things as old eyeglasses. In fact, the places where old eyeglasses are to be found are very rare.

In one of the German towns, Wartburg, Greeff found a number of eyeglasses which are the oldest we have. It was ascertained who had used them, and where they were made. The eyeglasses were brought to Wartburg by accident, and were never used there. They belonged to Wilibald Pirkheimer, the

humanist, of Nürnberg, who was a close friend of Luther and Dürer. He was born in 1470 in Eichstatt, and studied in Padua and Pavia. In 1497 he was elected to the council of Nürnberg and in 1499 he was appointed leader of the Nürnberg troops in the war against Switzerland. He died in Nürnberg in 1552.

The little room of Pirkheimer was preserved in Nürnberg till 1867, when it was purchased by the Countess Sophie of Weimar and taken to Wartburg. It was put in the right front wing of the castle, and was not open to the public. The walls were covered entirely with carved and inlaid wood, with a cornice. When in 1867, the wood was being taken from the walls, some old glasses were found, in an envelope, behind the wood not far from Pinkheimer's desk. Greeff was permitted to study them, and found eight pairs, of which the rims were fairly well preserved, but the glass was cracked or in pieces. In form they belonged to the so-called "stirrup glasses": two large round glasses joined to each other by a bridge or stirrup. Two straight stems met each other at an angle and were fixed.

Such spectacles are portrayed in old pictures of the thirteenth or fourteenth century. The real stirrup eyeglass is, however, from a later date. It was constructed so that round bordered glasses were connected with each other by a clumsily turned stirrup. Side sticks or anything for attachment and for a seat on the nose, did not exist at first. They were held by the hand from above by the stirrup, to keep them fixed to the nose while reading. Eyeglasses with bridge and stirrup, but of elastic material, came into use much later. The Pirkheimer eyeglasses were bordered with leather or with bone, were of different sizes, and were mostly large and round. The glass looked white and opaque, but in the transparent parts had a green tint. Dirt and bubbles were mixed with the glass, giving it the appearance of the material which is now used for light wine bottles. The glasses were plain on one side, and convex on the other to the degree of three dioptres. From this fact Greeff concludes that Pirkheimer used his glasses between his fiftieth and sixtieth year, so that they were probably manufactured about 1520, and also states that there is no doubt that they belonged to Pirkheimer and were made where they were worn.

Nürnberg was for centuries the centre for manufacturing eyeglasses. In 1483 the first eyeglass maker became a citizen, and manufacturing was made a free art there until 1507, when the council of Nürnberg regulated the association by an order. Greeff was told by an old optician from Nürnberg, who could trace his ancestors (also eyeglass cutters) to 1633, that the glasses were only ground in Nürnberg, while the rims were made in the near town of Furth. The handicraftsmen of this kind were called "Further Eyeglass Girdlers." The name girdler, perhaps, came from this old time when the rims were made from leather.

In 1772 Frederick the Great brought an eyeglass maker, called Hieronymus Meyer, from Nürnberg to Frankfort, where he worked at his trade with kingly privileges.

Greeff draws a picture of Pirkheimer as he was getting presbyopic: reading and writing, his loved studies, becoming ever harder for him. Imagine his joy when he heard of the first eyeglasses made in his beloved Nürnberg. How happy he was to be able to provide himself with this valuable instrument. As it was tiring to hold the glasses for a long time above, or to fix the glasses before the eyes with the fingers, so the tendency was to finish early, or to stop work when a friend came in for a chat. The eyeglasses were then put in their place on the wooden border near his desk, within easy reach. Then suddenly one day the eyeglasses could not be found. One hears him

chiding the maids who had cleaned and dusted the room, his supposition being that his beloved spectacles had been thrown out. Instead of that, they had been pushed under a little cleft in the wooden panels.

HANFORD MCKEE.

(2) **Greeff**, of Berlin, dates the beginnings of our interest in the history of glasses to about ten years ago, when an optician of Nürnberg, whose firm was established about the year 1630, found a chest containing glasses made by his family for centuries back. These examples found their way into the German Museum of Nürnberg, and to them were added at a later date a collection of spectacles made during the seventeenth century by applicants for admission to the trade guild. The author also refers to other large and valuable collections in Paris, Dresden, Berlin, Munich, and elsewhere, which must form the groundwork of any complete history of spectacles, and are of the greatest interest both to oculists and to opticians. So far little effort has been made to classify or to name the different types, but examination of the available material reveals an unexpectedly large variety of form and pattern. The introduction of glasses took place during the thirteenth century, and we find them portrayed in the works, especially of North European artists, from that time onwards. In their earliest form they appear to have been binocular, the first pattern being the so called "*Toppelpriller*" of the Nürnberg makers, corresponding to the "*Besicles clouants*" of France. Each lens is enclosed in a metal ring. From one side projects a straight stem an inch or two in length, and the ends of these stems are hinged together by a pin or nail. Although they have a resemblance to pince-nez they probably would not support themselves on the nose, and the first paintings in which they appear show that they were held by the hand, hinge upwards. This type of frame persisted for a long period. The second type appeared during the sixteenth century, and is chiefly seen in the works of the Dutch Masters. In it the rims are joined by a rigid metal bridge in the form of a hoop. At a later stage a third type, the direct forerunner of our pince-nez, evolved by the substitution of a spring for the rigid hoop. Thus was overcome the necessity for holding the glasses in the hand. Metal, horn, leather, and other materials were employed in the construction of the frames, and some of these, especially the horn, lent themselves to delicate ornamentation. Some of the most beautiful examples of pierced and fretted work in horn belong to the products of the candidates for admission to the guilds of the sixteenth and seventeenth centuries. A. J. BALLANTYNE.

(3) In the second instalment of his essay **Greeff**, of Berlin, traces the development of some forms more or less closely related to the spectacles of our own day. Among these were the glasses with leather tapes passing from each side and tied behind the head ; a somewhat similar pattern in which two threads passed backwards from each side and were tied behind the ears ; another in which the threads passed over the ears and were kept in position by weights attached to their ends ; and two other forms in which the frame was either attached to the headdress in front or had a stem passing up over the forehead and under the cap which kept it in position. Some of these types of spectacle frame are still in use in the East, especially in China and in Persia, while others are strangely reminiscent of our modern motoring goggles. They all belong to the sixteenth century. The lenses are large and round, all either plano-convex or convex menisci, and none has a greater strength than three dioptres. A. J. BALLANTYNE.

(4) **Greeff's** third article describes and illustrates several forms of binocular eyeglasses which came into use during the eighteenth century, more particularly the elegant and costly forms which were produced in France

during the later years of the century, and came to form an essential part of the equipment of every man or woman of fashion at that period. For the first time the utility of the eyeglass gave place to its importance as an article of adornment, and quotations are given to show how the ophthalmologists of the period protested in their publications against the injury that must ensue from the unnecessary employment of the "binocles."

A. J. BALLANTYNE.

5) **Oliver**, of Bradford, has brought together a great amount of information concerning the history of spectacles in this address, delivered before the members of the local division of the British Medical Association. The address was illustrated by a series of pictures in illustration of Oliver's remarks.

V.—"SECONDARY" TUBERCULOSIS.

Wirtz, **Robert.—The relationship of rheumatic eye affections to "secondary" tuberculosis. (Ueber Beziehungen der rheumatischen Augenerkrankungen zur "sekundären" Tuberkulose.)** *Klin. Monatsbl. f. Augenheilkunde*, Mai, 1913.

This paper by **Wirtz**, of Düren, is an interesting and painstaking contribution to a most important subject.

The author points out that until recently "rheumatic" was much more common than "tuberculous" as a diagnosis in affections of the eye, the reason probably being that for tuberculosis an objective sign, similar to that seen in tuberculosis of other organs, was demanded, while subjective symptoms sufficed to justify a diagnosis of rheumatism, and this was confirmed if the so-called "anti-rheumatic" remedies relieved the symptoms. With the discovery of the tubercle bacillus, the determination of the characteristic histological changes, and the introduction of the tuberculin reactions, the field of tuberculosis has been greatly widened, so much so that it actually covers much that was formerly attributed to rheumatism, even in the case of the joints. Poncet was the first to declare that a great many cases of acute and chronic articular rheumatism were in reality tuberculous, and Fleischer and the author published a number of such cases which manifested frankly tuberculous affections of the eyes. At a later date, Wirtz found in some cases of rheumatism suffering from affections of the eye that a positive tuberculin reaction could be obtained. His interest in the subject has been renewed by the work of Liebermeister and others, who have introduced the idea that tuberculosis exists, like syphilis, in primary, secondary, and tertiary forms. To the tertiary form belong the gross manifestations of tuberculosis with which we are familiar in the glands, bones, etc. The secondary stage lies between this and the period of infection, and to it belong cases which show no clinical evidences of tuberculosis, but give a positive response to the tuberculin reactions. Of still greater interest is the fact that Liebermeister has been able to find tubercle bacilli in the blood of many such patients, and to prove their presence also by the results of animal inoculation. It is worthy of note that in five out of seventy cases belonging to this group, not only was there no clinical evidence of tuberculosis, but the individuals made no complaint of ill-health. Wirtz investigated on these lines 21 cases of "rheumatic" eye

affections, *e.g.*, episcleritis, uveitis, sclero-keratitis, some with, others without, tertiary tuberculosis. He gives in detail the results of the examination in twelve cases in which there was no evidence of active tuberculosis. All were suffering, or had suffered, from articular "rheumatism." In every one of these cases the author, following the elaborate *technique* of Liebermeister, found tubercle bacilli in the blood. Some of these patients both looked and felt well, but the majority were pale and anæmic. At Liebermeister's suggestion, he adopted, instead of tuberculin treatment, anti-rheumatic treatment in the form of hot air baths of ten or twenty minutes' duration daily, for some weeks. The results were excellent, both as regards the eye condition and the general health.

Liebermeister's method of examining the blood for tubercle bacilli is very tedious, but the author believes that secondary tuberculosis can be recognised without it, since the patients have often an unhealthy appearance, and frequently give a history of scrofulosis in earlier life or a family history of scrofulosis or tuberculosis, and since a positive reaction to tuberculin is obtained.

A. J. BALLANTYNE.

VI.—OPHTHALMOLOGY AND GENERAL MEDICINE.

(*Fourth Notice.*)

(1) **Dufour, R.—On the cerebral localisation of some visual phenomena.** (Ueber die Gehirnlocalisation einiger Gesichtersheinungen.) *Bericht der Ophthalmologischen Gesellschaft*, Heidelberg, 1911.

(2) **Taylor, James and Holmes, Gordon.—Nervous symptoms associated with optic atrophy of the familial type.** *Trans. Oph. Society U.K.*, Vol. XXXIII, 1913, p. 116.

(1) **Dufour**, of Nancy, offered some suggestions regarding the cerebral localisation of some of the visual phenomena. Wilbrand states that for a visual hallucination to be projected into space the central perceptive organs must be intact but not necessarily the conducting tracts. In order that a visual sensation shall be perceived, some external or internal stimulus or alterations must have taken place in some part of the optical nervous mechanism. The spot where the stimulus has acted Dufour calls the point of origin of the visual phenomenon. He attempts to localise the *point d'origine* of some visual impressions. The *point d'origine* of a visual sensation which affects the eyes independently lies in front of the chiasma, whereas if both eyes participate in the phenomenon, it lies behind the chiasma.

Dark adaptation is generally localised in the retina, but Dufour finds that if he closes one eye for a time and then looks at a bright light with both, the darkened eye is more sensitive than the other : that is to say, dark adaptation in one eye is independent of the other.

Troxler's phenomenon can be elicited from each eye independently. The fusion faculty for colours rotated on a disc (von Kries) is localised in front of the chiasma, but the illusion caused by Plateau's spiral line demands the participation of the two eyes, and must be localised behind the chiasma.

Fechner's paradox must probably be localised behind the chiasma closed ring of muscle.

T. HARRISON BUTLER.

(2) **Taylor** and **Holmes**, of London, discuss the signs of organic nervous disease which may be associated with Leber's familial optic atrophy (or inflammation).

Leber pointed out that hereditary optic atrophy was often found in families with a neuropathic taint; in those in which headaches, vertigo, tremors, numbness of limbs, and other symptoms of the kind occur. The ocular affection has been known to be associated with epilepsy (Hancock), migraine or hysteria, or insanity (Story). In certain families (Sedgewick and Habershon) other members have died from spinal disease, the exact nature of which is unknown. In the reviews published by Hormuth (1902) and by Nettleship (1909) respectively, no mention is made of the co-existence of a single organic affection of the nervous system with familial optic atrophy.

In searching through the *Transactions* of the Ophthalmological Society which include reports of many cases of Leber's disease), Taylor and Holmes find a few cases in which symptoms suggestive of organic nervous disease occur, as those by S. Johnson Taylor, Rayner D. Batten, and R. W. Doyne. References are also made by the authors to cases of the kind reported by Leber and Gallemaerts.

It might be concluded, then, that the association of organic nervous disease with hereditary optic atrophy was exceedingly rare, but since the eye cases seldom consult a neurologist, slight signs of organic disease might readily be overlooked.

The authors have brought together seven personal cases in which symptoms of organic nervous disease coincided with familial optic atrophy or with something closely resembling the last-named. For details readers must be referred to the original communication. In this place it will suffice to say that at an early stage in the illness there was, in a few of the patients, a history of transitory mental disturbance, as shown by depression, restlessness, irritability, confusion, and loss of memory. The nervous symptoms found upon examination included absence or diminution of the deep reflexes (ankle- and knee-jerk), numbness or tingling in the limbs (most commonly in the hands and feet), pains of a dull, aching character, and some anæsthesia, analgesia, or loss of the sense of position. Several of the patients complained of slight sphincter disturbances.

The cases reported by the authors belong, it is thought, to the Leber type, from which they differ only by the co-existence of nervous trouble. In an alternative view, they may be taken as representing another type of familial degeneration related to Leber's atrophy only by the fact that the visual apparatus is similarly affected. The matter obviously cannot be regarded as finally settled.

SYDNEY STEPHENSON.

VII.—PATHOLOGY.

(*Fifth Notice.*)

(1) **Green, John, Jr.—Sarcoma of the choroid: unusual clinical features.** *American Journal of Ophthalmology*, June, 1912.

(2) **Alt, Adolf.—Microscopical examination of the eye in the case of choroidal tumour reported by Dr. John Green, Jr.** *Ibidem.*

(3) **Hegner, C. A.**—The pathological anatomy of embolic metastases in the eye. (Beitrag zur pathologischen Anatomie der embolischen Metastasen im Auge.) *Klin. Monatsbl. f. Augenheilkunde*, Juni, 1913.

(4) **Krailsheimer, R.**—Dermoid of the eye. (Ein Beitrag zum Dermoid des Auges.) *Klin. Monatsbl. f. Augenheilkunde*, Juni, 1913.

(5) **Ichikawa, K.**—The pathology of rodent ulcer of the cornea. (Ein Beitrag zur Pathologie des Ulcus rodens corneæ. *Klin. Monatsbl. f. Augenheilkunde*, Juli, 1913.

(6) **Ishihara, S.**—The development of amyloid degeneration of the conjunctiva. (Ein Beitrag zur Entwickelung der Amyloiddegeneration der Konjunktiva.) *Klin. Monatsbl. f. Augenheilkunde*, Juli, 1913.

(7) **de Schweinitz, G. E. and Shumway, E. A.**—Epibulbar carcinoma; histological examination of the specimen. *Archives of Ophthalmology*, July, 1913.

(8) **Collins, E. Treacher.**—Fibrous tissue formation in connection with the fœtal vascular system and visible vessels on the surface of the iris. *Transactions Ophthalmological Society U.K.*, Vol. XXXIII, 1913.

(1) The case reported by **Green,** of St. Louis, is one in which there were difficulties in the diagnosis caused by (1) extreme slowness of the growth; (2) complication by an attack of pertussis which led to the first symptoms being then noticed by the patient, although it is concluded now that the growth existed prior to this; (3) a large subretinal hæmorrhage; (4) the fact that the tension (controlled by the tonometer) was diminished. Eventually, when the mass, which was situated at the posterior pole, was observed to have increased slightly in size, the eye was excised.

(2) The microscopic examination was made by **Alt,** of St. Louis, who found the tumour to be mainly spindle-celled. It was absolutely confined to the neighbourhood of the macula. The difficulties of diagnosis were largely explained by the evidence of hæmorrhage having occurred about the tumour at different dates. ERNEST THOMSON.

(3) **Hegner,** of Jena, reports a case of infective endocarditis, in which, three weeks before death, blindness suddenly occurred, with the ophthalmoscopic picture of obstruction of the central artery of the retina.

Microscopic examination of the parts removed after death showed the presence of an aneurysmal dilatation of the central artery, behind the lamina cribrosa, filled with a homogeneous mass. There was intense leucocytic infiltration of the wall of the vessel and of the surrounding connective tissue of the nerve. Elsewhere throughout the nerve, there were small clumps of round cells, small hæmorrhages, and thrombosis of the smaller vessels. In the orbital tissues in the neighbourhood there were also clumps of leucocytes and thromboses of vessels. The retina was degenerated, and lymphocytic infiltration was found in the choroid and ciliary body.

The author concludes that an embolus from the heart obstructed the central artery and set up an inflammatory process in its wall and in the neighbouring tissues. The aneurysmal dilatation resulted from the embolism, this being a condition not hitherto observed in this artery. The obstruction

to the other smaller vessels would be the result of emboli derived from the original mass, while the hæmorrhages and cellular infiltrations in the retina and choroid would be the products of toxins derived from the embolus.

A. J. BALLANTYNE.

(4) **Krailsheimer**, of Breslau, describes and illustrates a congenital dermoid tumour, in the form of a pterygium-like vascular growth, occupying the temporal aspect of the globe and the outer half of the cornea. The patient was a child of eight months. The structures composing it were a connective tissue stroma, tubulo-acinous glands, a plate of hyaline cartilage, lymphoid cells, smooth and striped muscle, adipose tissue, blood- and lymph- vessels, and nerve-endings. The author describes the condition as an ectopia of the subconjunctival tissues of the fornix, including the epithelial involutions which go to form the lacrymal gland and Krause's glands, and believes that it is ultimately caused by amniotic bands or adhesions.

A. J. BALLANTYNE.

(5) **Ichikawa,** of Osaka, reports a case of rodent ulcer of the cornea, which recurred repeatedly in spite of the cautery, excision, and other methods of treatment. Ultimately, the anterior part of the globe was excised.

Microscopic examination of the lower part of the cornea, in which the ulcer originated, but which had been covered with a conjunctival flap at an earlier period, showed between the epithelium and the remains of the corneal stroma, a layer of granulation tissue containing large numbers of eosinophile polymorphs. The central part of the cornea showed active ulceration, while the upper part was the apparantly healthy cornea. The floor of the ulcer was in part covered with granulation tissue rich in eosinophiles, while elsewhere it presented the exposed lamellæ of the corneal stroma in a necrotic condition. The granulation tissue referred to was found undermining the advancing edge of the ulcer, and penetrating into the healthy corneal substance. The apparently healthy upper zone of the cornea presented fairly normal characters, but showed some epithelial degeneration, and along its upper border there lay, both before and behind Bowman's membrane, a vascular layer containing lymphocytes, epithelioid cells, plasma cells, and some eosinophiles. Discussing the question as to whether the necrosis of the corneal lamellæ, or the growth of the foreign granulation tissue is the earlier change, the author inclines to the belief that the necrosis is secondary and due to exposure of the corneal substance. The occurrence of eosinophiles has not been hitherto described in this condition, and points, he thinks, to the presence of a parasite. He believes, indeed, that rodent ulcer is the result of a specific infection which leads in the first place to the formation of a circumscribed episcleritis. From this primary focus, granulation tissue makes its way across the limbus into the cornea and also subconjunctivally round the limbus, advancing into the cornea at different points. If Ichikawa's theory is correct, it follows that, however thorough our treatment of the corneal condition may be, it may fail to stay the process until, as he suggests, the circumcorneal conjunctiva is widely removed and the episclera cauterised.

A. J. BALLANTYNE.

(6) There are, at present, several views as to the mode of origin of amyloid degeneration of the conjunctiva. Different authorities believe it to originate in the tissue cells, in the vessel walls, in the degenerative protoplasm of red corpuscles or plasma cells, and in connective tissue fibres. Deutschmann holds that, clinically, there is no distinction between the conditions known as Plasmoma, hyaline degeneration, and amyloid degeneration, and that the name Plasmoma should be applied to all of them.

Ishihara, of Tokio, has had the opportunity of examining the tissues from two cases. In the one he found that the amyloid material was developing

out of plasma cells, by their swelling, fusing together, and degenerating. The connective tissue fibres were destroyed, but not converted into amyloid. In the other case the amyloid was found to be developing out of the connective tissue fibres and not out of cells. He believes, therefore, that there are two recognisable modes of origin. The first of those described is peculiar to the localised amyloid tumours, while the second may form either local masses or a general "Amyloidosis." A. J. BALLANTYNE.

(7) **de Schweinitz and Shumway,** of Philadelphia, report a case of epibulbar carcinoma in a man of 34, who first noticed it at nineteen years of age. At that time there was a small growth at the limbus on the inner side, which remained stationary for three or four years. It was treated with the actual cautery, after which it grew rapidly for a time, and then became again stationary. On examination, the cornea was found to be replaced by connective tissue, although Descemet's membrane was intact; the growth was present on both inner and outer sides and protruded between the lids. The lens was pushed forwards and to the temporal side and the retina was completely detached. The interior of the eye was, however, free from the growth, although there was commencing involvement of the perivascular sheaths of the perforating ciliary vessels. After removal, recurrence took place in three months, a nodule being present of 9 mm. diameter in the orbital tissues. Exenteration of the orbit was then performed, and eight months later, there was no recurrence. The authors think that the growth may originally have been a papilloma which was stirred to rapid growth by the cauterisation. As a rule, similar cases are observed after 40 years of age, but in this case the first sign appeared at 19. The authors consider that if the growth is at the limbus, deep excision is indicated if the case can be watched, since here there is greater danger of perforation than away from the limbus, where excision will probably be successful. ROSA FORD.

(8) The article by **Collins,** of London, is of much interest, although most of it is unsuitable for abstract. Exception must, however, be made in favour of what he has to say on the subject of the appearance of vessels on the surface of the iris as a pathological condition. Such vessels are usually met with in eyes with increased tension, most frequently in glaucoma secondary to thrombosis of the central retinal vein. They are situated on the surface of the iris and not in the stroma. They do not run radially from the ciliary to the pupillary margin, like the vessels in the stroma, but often at right angles to them or take the form of an irregular network. In explanation of the formation of these vessels on the surface of the iris, Collins suggests that in certain cases of intraocular venous congestion some persistent tracks of the vessels of the iridic portion of the fœtal lamina irido-pupillaris may become opened up and again capable of carrying blood. These new vessels are situated in the position in which in fœtal life a plexus of vessels does exist, and are certainly not part of the normal structure of the adult iris. The author suggests that the opening up of the old tracks of vessels would be analogous to recurrence of vascularity in the cornea, either after the subsidence of interstitial keratatis, or pannus, as the result of some fresh trivial lesion, such as an abrasion. ERNEST THOMSON.

VIII.—HEMERALOPIA AND XEROSIS CONJUNCTIVÆ.

(1) **von Hippel, E.—Short report of the results of a collective investigation of the excessive occurrence of hemeralopia with xerosis in the Spring of 1912.** (**Kurzer Bericht über das Ergebniss einer Umfrage betr. das gehäufte Vorkommen von Hemeralopie mit Xerose im Frühjahr, 1912.**) *Klin. Monatsbl. f. Augenheilkunde*, Mai, 1913.

(2) **Ishihara, S.—The ætiology of idiopathic hemeralopia and xerosis conjunctivæ.** (**Zur Aetiologie der idiopathischen Hemeralopie bzw. Xerosis conjunctivæ.**) *Klin. Monatsbl. f. Augenheilkunde*, Mai, 1913.

(1) The attention of **von Hippel**, of Halle, a. S., was aroused by an unusually large number of cases of xerosis and hemeralopia in Halle in the spring of last year (twelve acute cases in two months), and enquiries made amongst a number of colleagues elicited the fact that there had been something like an epidemic of acute hemeralopia in Saxony, Anhalt, and Thuringia. Thirteen observers had treated 93 cases, and several of these patients reported that in the villages to which they belonged there were many other sufferers. The large majority of the patients were males. More than half of the number were 20 years old or younger. A large proportion were ill-nourished. Some of the observers believed it to be the result of malnutrition due to the high prices of meat, the prevalence of foot and mouth disease, and the failure of the rape seed harvest. Recovery, as a rule, was rapid. The treatment adopted was good feeding, cod liver oil, quinine, and protective glasses. Many cases were not seen, and must have recovered without special treatment. In discussing the ætiology of the condition, von Hippel thinks that neither of the factors invoked to explain it, malnutrition and the effects of glare, is sufficient in itself. Even if they act in combination, he finds the explanation unsatisfactory. A. J. BALLANTYNE.

(2) **Ishihara**, of Tokio, calls attention to the magical effect of cod liver oil in the treatment of xerosis conjunctivæ and hemeralopia, and even in keratomalacia, if the disease is not too far advanced. The use of the liver substance itself, and of mixtures of extracts of liver with honey can be traced in the early medical records of China, Japan, Russia, Turkey, etc., in the treatment of similar diseases of the eye. Eel-flesh was also used by ancient Chinese and Japanese oculists.

The author has had a large experience of these related diseases, which appear to be very prevalent in Japan. In his experience, the presence of xerosis may be independent of the general state of nutrition and of the amount of subcutaneous fat. He has seen it in well-nourished patients in whom a single dose of cod liver oil (10-15 grammes), sufficed for a cure. He instituted a series of investigations in which he employed cod liver oil, oil of eel-flesh, oil of the dried river lamprey (a popular remedy for hemeralopia in Japan), sardine oil, and olive oil. His investigations included examination of the fat content of the blood, and periodical estimations of the light-sense. His results showed that cod liver oil acts brilliantly in xerosis with hemeralopia; that oil of eels is equally efficacious; and that olive oil is not nearly so good. While the disease comes on where there is general nutritional disturbance, deficiency of body fat, liver disease or diarrhœa, it is essentially due to deficiency in the fat content of the blood. A. J. BALLANTYNE.

IX.—CATARACT OPERATIONS.

(1) Moreau.—On extraction of the lens in its capsule. (De l'extraction du cristallin dans la capsule.) *La Clinique Ophtalmologique*, 10 septembre, 1911.

(2) Sattler, R.—Intracapsular extraction of the cataractous lens. *Archives of Ophthalmology*, November, 1911.

(3) Smith, Homer E.—The advantages of a preliminary capsulotomy, especially in immature cataracts. *Archives of Ophthalmology*, January, 1912.

(3A) Maddox, E. E.—A safety device for dangerous cataract extractions. *Ophth. Review*, January, 1912.

(4) Bey, Sameh.—The extraction of cataract with its capsule. (L'extraction de la cataracte avec sa capsule.) *La Clinique Ophtalmologique*, 10 juin, 1912.

(5) Connor, F. Powell.—The intracapsular operation for cataract (Smith's method), from the point of view of the civil surgeon. *Indian Medical Gazette*, Vol. XLVII, p. 214, June, 1912.

(6) Elschnig.—Simple flap extraction of senile cataract, with peripheric incision of the iris. *Archives of Ophthalmology*, July, 1912.

(7) Calendoli, S.—Apropos the methods of avoiding prolapse of the vitreous in operating for cataract. (A proposito dei mezzi per evitare il prolasso del vitreo operando la cataratta.) *Archivio di Ottalmologia*, Luglio, 1912.

(8) Smith, Henry.—Details of vision of 132 cases of intracapsular extraction of cataract. *Archives of Ophthalmology*, November, 1912.

(9) Jackson, Edward.—Management of capsule in cataract extraction and afterward. *Trans. Amer. Ophth. Society*, Vol. XIII, Part i, 1912, p. 39.

(10) Sumner, F. W.—Control of the eye in cataract operations. *Indian Medical Gazette*, Vol. XLVIII, p. 142, April, 1913.

(11) Smith, F. F. Strother.—Extraction of the lens in its capsule. *Indian Medical Gazette*, Vol. XLVIII, p. 144, April, 1913.

(12) Meding, C. B.—Another view of the extraction in the capsule cataract operation. *Archives of Ophthalmology*, May, 1913.

(13) Ferentinos, Sp.—A method of avoiding the issue of vitreous during the cataract operation. (Pour éviter l'issue du corps vitré pendant l'opération de la cataracte.) *La Clinique Ophtalmologique*, juin, 1913.

(1) **Moreau,** of St. Etienne, gives the visual statistics (and also the

operative *technique* which we do not attempt to reproduce) of 33 cases of intracapsular extraction which he has performed out of a total of 220 cataract operations during eighteen months.

The figures are as follow :—

In 2 cases	... ...	V. = 1.
,, 5 ,,	... ...	V. = 1/2.
,, 8 ,,	... ...	V. = 1/3.
,, 9 ,,	... ...	V. = 1/4.
,, 3 ,,	... ...	V. = 1/6.
,, 2 ,,	... ...	V. = 1/8.
,, 3 ,,	... ...	V. = 1/10.
,, 1 ,,	... ...	V. = less than 1/20.
Total 33		

The author is, on the whole, pleased with his results, although he is not at all enthusiastic about the operation. It is difficult, and the apprenticeship is "expensive" and prolonged. In assimilating Smith's procedure one must not forget the great point that we live in Europe. The method is unquestionably modified by social considerations in our part of the world. The operation cannot, in Europe, be employed unconditionally. We must choose our cases.

Moreau's article is interesting from the points of view of *technique*, and of operative difficulties and accidents, but the number of cases seems too small to be of much value as the statistical foundation for an individual operation. ERNEST THOMSON.

(2) Personal experience of the Smith method of intracapsular extraction has led **Sattler,** of Cincinnati, to the conclusion that it cannot be made a ready or safe part, or substitute, of the older method, as commonly practised. If with the old method it is impossible to extract after capsule opening and expression, the vectis or skeleton spoon is the best and safest expedient to effect its removal. All other means, including Smith's, are inferior and uncertain. On the other hand, if the indications are plain for removal in the capsule, and it is selected as the most rational, the safest technical way to effect it is by the method proposed and practised so extensively by Colonel Henry Smith. ROSA FORD.

(3) **Smith,** of Norwich, N.Y., finds that a preliminary capsulotomy the day before extraction makes the latter operation much simpler.* He claims with this method to have almost constant success, with very seldom the necessity for a secondary operation. Immature cataracts can be operated on at once, and in a series of thirty of these he has found the results satisfactory, the interval between the two operations apparently allowing the aqueous to insinuate itself between the capsule and the cortex, producing thereby a separation between the two, so that no cortical matter is left behind, and a clear pupil is obtained. In mature and hypermature cataracts, his method guides one as to the length of corneal incision necessary. If the cut into the capsule is practically invisible, then a large nucleus is present, and the usual two-fifths of the cornea will be necessary ; if semi-gelatinous matter exudes, softening has taken place, and but one-third will be required ; if a milky fluid escapes, then only a small nucleus remains, and the section may be made with the angular keratome. Smith uses a special knife, designed by himself, of which the cutting edge is only 2 mm., while it has a slender shank which

*A notice concerning the Homer E. Smith operation appeared in THE OPHTHALMOSCOPE, 1912, p. 663.

just fills the corneal puncture, and thus prevents aqueous from escaping. This ensures that the lens is supported by both vitreous behind and aqueous in front, and there is therefore but very slight danger of rupture of the suspensory ligament. This knife can be made superlatively sharp and efficiently cuts the capsule in both directions. The pupil is dilated with homatropine, and this permits the point of the knife to be seen throughout the operation. The iris cannot be wounded or entangled in the instrument. and there can be no bleeding to obscure the view of the operative field, Smith uses this operation only when the iris is normal, and he does not advise it in the very aged, in whom a preliminary iridectomy is advisable; but even in these cases he thinks capsulotomy should be made in advance of the extraction proper. ROSA FORD.

(3A) **Maddox**, of Bournemouth, has found the following device useful in "squeezers," in order to avoid loss of vitreous during extraction.—He passes a soft but strong suture through a vertical tunnel of conjunctiva below the inferior limbus, then through a short tunnel, parallel with and close to the margin of the limbus above, and again through a vertical tunnel parallel with and about one-eighth of an inch from the first. The double thread across the cornea can be held aside during the section of the cornea, and can be drawn tight as the knife is withdrawn; the cystitome can now be used and on loosening the thread, the lens can be expressed. The suture can be tied and the wound can thus be kept closed; the presence of the thread across the cornea does not seem to cause any damage.

A. H. PAYAN DAWNAY.

(4) **Sameh Bey**, of Cairo, after giving a *résumé* of the literature of intracapsular extraction, or rather after an outline of its history, since the references are not given in full, describes his own operations and their results since 1906. To do justice to this latter part of the article would involve its practical transcription, so that it may suffice to say that he has operated in this way upon 310 cases; that he has had a greater or less escape of vitreous in 82 cases, or 26.48 per cent.; and that he is nevertheless satisfied that the operative and visual results obtained in his cases by the Indian method are superior to those obtained by the classical procedure with discission of the capsule, namely, for the Indian method :—V.A. 1/2 to 2/3, 27.14 per cent.; 1/6 to 1/3, 62.9 per cent.; below 1/8, 7.09 per cent.; counting fingers at one or two metres, 1.61 per cent.; no vision, 0.96 per cent.

ERNEST THOMSON.

(5) **Captain Connor** is one of Smith's pupils, having had the benefit of personal instruction. He has nothing new to say about the operation. He regards it as ideal in practice as well as in theory, and has performed it about 1,400 times. He gives tabulated results of sixty-four extractions in fifty patients, taken at random. H. HERBERT.

(6) **Elschnig**, of Prague, has replaced Hess' peripheric excision of the iris, to prevent prolapse, by a simple incision of the root of the iris. In 100 cases he had no prolapse. He claims that this operation is much easier to perform than excision, that it causes less contusion, and the opening is not large enough to allow the edge of the lens to be caught in it. In making the incision, the scissors must be placed close to the scleral margin, and that the section made as near to the margin of the cornea as possible. Elschnig makes the incision after opening the anterior capsule of the lens; but in cases where the pupil, after the opening of the capsule, remains fully dilated, the section is made after extraction, to avoid the possibility of placing it too near or actually through the sphincter. Elschnig often uses eserine, even before beginning the operation, because he finds that the pupil after extraction often remains of

medium size or dilated. Elschnig thinks that the combined method is better in cases of diabetes, and in other states in which there is special liability to trauma of the iris; as also, in cases where a drop of homatropine, instilled a day before the operation, does not produce a mydriasis of at least 5 mm.

ROSA FORD.

(7) **Calendoli**, of Turin, writes with the object of showing that Maddox's device for preventing prolapse of the vitreous during, or after completion of, extraction of a cataractous lens, is no better than the various other means previously suggested. Maddox's method (see abstract above) entails a somewhat complex suture mechanism. The writer of this article claims that of the various methods, the old-established one suggested by Desmarres, and later modified, especially by Bajardi, is the simplest and most satisfactory. This is a variety of the conjunctival bridge, and has given excellent results. The difficulties and dangers of a corneal suture are avoided.

LESLIE BUCHANAN.

(8) The only complications among these 132 cases of intracapsular extraction of cataract by **Smith**, of Amritsar, were: one prolapse of iris, one iris caught in one angle of the wound, and in three instances a slightly hazy cornea. A bead of vitreous escaped in three cases. There was capsule left behind once (this patient had 6/12 vision). There were no drawn-up pupils; no iritis or iridocyclitis. The vision obtained, tested from ten to twenty-one days after operation, in the 119 cases where observation was possible, was: 6/12 in 2; 6/9 in 3; 6/6 in 26; 6/5 in 22; 6/4½ in 61; 6/4 in 16. Near vision: Jaeger 1 in 10; thread needle with great ease, 14; thread needle with difficulty, 9. Two patients were too stupid to be tested. Needle threading was used as a test with those who could not read Roman or Urdu; it is more difficult than reading Jaeger 1. The lenses used were from +9D. to +11D. for distance, and for near work mostly +13D.; a few required +14D.

Smith attributes his excellent results to the entire absence of capsule. One hundred and nineteen of Smith's cases were normal except for the cataract; he does not state whether the other thirteen were normal. Smith considers that his results compare very favourably with those obtained by the extracapsular method by E. Treacher Collins, who states that of his uncomplicated senile cataracts, 25 per cent. had vision of 6/6 without needling. He notes that Collins does not state the time after the operation at which the vision was tested, and considers the omission important because with cases in which capsule is left behind, vision lessens as time goes on with the growing obstruction of light by the capsule. With the intracapsular operation, on the contrary, the reverse occurs, the vision improving as the patient becomes more accustomed to the glare of the sunlight and the cornea resumes its normal transparency. This is proved by a comparison of sixty-one of Smith's cases examined from one to five years after operation. Fifty-six of the sixty-one ranged from 6/3 to 6/6 with one operation. Smith protests against the use of the eyes after his operation for any exacting work for three months. After the operation, the first dressing should not be removed for ten days, in the same way as a general surgical wound is left undisturbed. Both eyes should be bandaged, in order to reduce the movements of the eyeball. The patient should rest on his back for 24 hours, and should have a light diet. After four days, he may be allowed to sit up on a chair. After the first change of dressing, Smith prefers to keep the operated eye bandaged from five to eight days longer without further inspection.

ROSA FORD.

(9) **Jackson**, of Denver, shows that Colonel Henry Smith is very wide of the truth when he claims that even after a successful cataract extraction, if

the patient is to have vision for fine work, an after-cataract operation is invariably necessary. This important point he proves by means of a tabulated list of fifty cataract extractions. According to those figures, 16 per cent. of the patients obtained normal or super-normal vision after the primary operation, while in 22 per cent. vision of 4/8 or better was obtained. This is the more striking, since Jackson adopts a method of opening the capsule which might reasonably be expected to be followed with special frequency by a more or less obstructed pupil. After completion of the corneal section and the iridectomy, he cuts the anterior capsule through at the upper margin of the pupil, and removes no part of the capsule nor causes it to roll back out of the pupillary space. Jackson estimates, that upon the

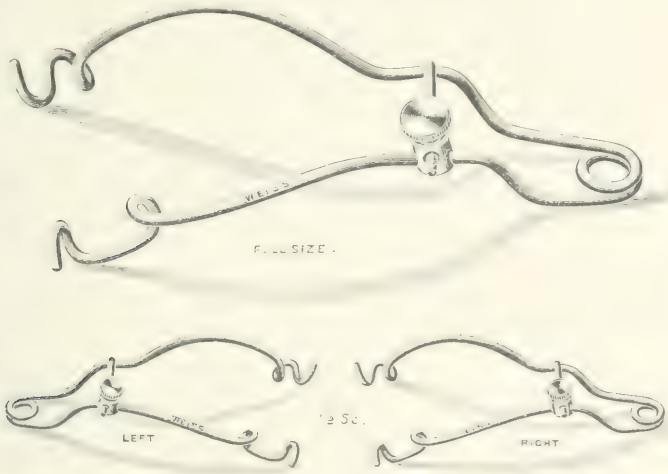

whole, about 50 per cent. of patients subjected to his method of cataract extraction will at some subsequent time be the better for a secondary operation.

Jackson ventures the opinion that the operation for secondary capsular cataract is often not well understood or efficiently performed. He lays down the following axioms:—(1) to enter the knife through the limbus and not through the clear cornea; (2) to cut and not to tear the membrane; and (3) to make a V-shaped incision, as advocated by Ziegler. Jackson reminds us that if the shank of the instrument fills, as it should do, the puncture in the cornea, there is no reason why two punctures should not be made into the anterior chamber without loss of aqueous or subsequent bad effects. The operation is of little moment, and "is attended with less danger than removal of foreign bodies from the cornea." The fact of such an operation being required in one-half of the cases of cataract extraction seems to Jackson an insufficient reason for adopting the more serious and difficult operation of intracapsular extraction of the lens.

SYDNEY STEPHENSON.

(10) **Sumner,** of Fatehgarh, India, has devised a lid speculum to enable the surgeon to dispense with trained assistance in the performance of Smith's intracapsular extraction. If the instrument proves to be as effective as he claims, it may be of service at times for other operations also. The speculum (*see* figs.) is curved to allow the assistant's index finger to lie between it and the patient's temple. The pressure of the thumb on the end of

the instrument, "acting through the index finger as a fulcrum tilts up the eyelids to whatever extent is necessary. The assistant's other hand is spread out over the patient's head, and, the eyebrow having been well drawn back, his thumb presses against the upper edge of the orbit."

The portion of the upper blade which passes under the eyelid is narrower and projects under the lid much further than in the orthodox speculum. This entails the disadvantage that right and left speculums are required, one for each eye; and smaller instruments have to be used for very small or children's eyes. Also during the making of the corneal section, the outer portion of the upper lid has to be drawn up with a blunt hook, to avoid the possibility of the knife touching the lid margin. H. HERBERT.

(11) This is a wholly unfavourable critical review by **F. F. Strother Smith**, of Allahabad, a Jullundur pupil, of Captain Nesfield's work on intracapsular extraction with division of the suspensory ligament [*see* THE OPHTHALMOSCOPE, Vol. VII (1909) p. 703, and Vol. X (1912) p. 665]. It is scarcely correct to describe the method as a modification of the Jullundur operation, for the use of the zonulotome by Gradenigo and his followers, dates from a period (1895) before the Smith operation had been developed.

With regard to the buttonhole iridectomy made by Nesfield before expressing the lens, Strother Smith pertinently remarks that no information is given as to "how often the bridge of iris gets astride the outcoming lens, giving trouble."

As an answer to other criticisms made, Smith's own sentiment might justly be turned against himself. "It is surely more consistent to deal with facts than with theories based on the absence of skill and knowledge." He has apparently had no personal experience of Nesfield's work, and although he bases his claim to criticise upon the performance of between two and three thousand intracapsular operations at Jullundur and Amritsar, and upon his presence at the performance of many others, some of his remarks show too clearly the imprint of Jullundur teaching to be generally acceptable. He shows a fear of the sensitiveness of the iris which reflects Colonel Smith's insufficient use of cocaine; and he commits himself to the statement that prolapse of the iris is best left alone for ten or twelve days until the wound has united. H. HERBERT.

(12) **Meding**, of New York, studied the statistics in the *Archives* of twenty-eight years, and found that the claims of the intracapsular operation (as there shown) in uninterrupted recovery, visual and cosmetic result were tremendous. He went to India to study the method at first hand under Colonel Smith, and came back a disciple and hero-worshipper.

A competent assistant is absolutely necessary for the operation. Every eye at Smith's clinic, as it comes along, whether it be glaucomatous, trachomatous, or with a hazy or "pannused" cornea, if it has a chance, is operated on. The conjunctival sac is prepared by douching with 1:2000 sublimate; the section is in the cornea and is made with one sweep of the knife, and particular methods of pressure, as regards force and direction in expression, are necessary. After the operation, a good smear of yellow ointment is placed on the lids, both eyes are bandaged and the patient is sent to bed. After ten days, if all has gone well, the bandages are removed, and if the eyes are healed and quiet, only a green shade is ordered and the patient is discharged. Iritis is almost unknown, and pain only occurs if there has been prolapse of the iris or hæmorrhage. The results are that only one operation is necessary, a clear pupil is obtained, to say nothing of working vision. Immature cataracts are the easiest, and hypermature the more difficult. Smith does thirty cataracts in an hour. ROSA FORD.

(13) In cases where there is no pathological rise of tension, **Ferentinos**, of Patras, Greece, applies a pressure bandage the night previous to operation in order to lessen the tension. He removes the bandage only at the time of operation. ERNEST THOMSON.

X.—SYPHILITIC AFFECTIONS OF THE EYE.

(1) **Trantas.**—Pericorneal syphilitic swelling. (Bourrelet périkératique syphilitique.) *Archives d'Ophtalmologie*, mai, 1911.

(2) **Galezowski, J.**—Ocular manifestations of tertiary syphilis in tabetics. (Manifestations oculaires de la syphilis tertiare en évolution chez des tabetiques.) *Recueil d'Ophtalmologie*, juin, 1911.

(3) **Brückner, A.**—A contribution to our knowledge of congenital syphilitic diseases of the eye. (Ein Beitrag zur Kenntnis hereditär-syphilitischen Erkrankungen des Auges.) *Zeitschrift für Augenheilkunde*, Dezember, 1911.

(4) **Fromaget, Camille, and Fromaget, Henry.**—Three cases of conjunctival chancre. (Trois observations de chancre syphilitique de la conjonctive.) *L'Ophtalmologie Provinciale*, janvier, 1912.

(5) **Luedde, W. H.**—Gummatous inflammation of the inner canthus, simulating dacryocystitis. *American Journal of Ophthalmology*, January, 1912.

(6) **Wicherkiewicz, B.**—Keratitis parenchymatosa of traumatic origin and its medico-legal aspect. (Ueber die durch Trauma entstandene Keratitis parenchymatosa und die Rechtsfrage.) *Klin. Monatsbl. f. Augenheilk.*, Januar, 1912.

(7) **Clapp, C. A.**—A case of gumma of the eyelid. *Ophthalmic Record*, June, 1912.

(8) **Dodd, Oscar.**—Syphilis of the orbit. Report of an unusual case. *Archives of Ophthalmology*, September, 1912.

(9) **Lacompte, Franz.**—A case of heredo-syphilitic parenchymatous keratitis after linear extraction of a cataract. (Un cas de kératite parenchymateuse hérédo-syphilitique après extraction linéaire de la cataracte.) *Ann. d'Oculistique*, septembre, 1912.

(10) **Mylius, W.**—Gumma of the optic disc. (Ein Fall von Gumma der Opticuspapille.) *Klin. Monatsbl. f. Augenheilkunde*, Mai, 1913.

(1) **Trantas**, of Constantinople, describes a pericorneal swelling in a young man of 19 years, suffering from secondary syphilis of which the site of the primary lesion could not be determined. The swelling surrounded the cornea, except at its supero-internal part, for a distance of 1 centimetre; it was 2 to 3 mm. broad, 2 mm. thick or prominent, and in form, breadth, and thickness resembled the condition found in spring catarrh, but differed in other respects, being white to whitish-yellow in colour, gelatinous, and with a smooth surface. It was decidedly hard, and not painful. Under mercurial inunction

for one week, the swelling appeared to increase ; but with intramuscular injections of biniodide of mercury for another week, it had nearly disappeared. The cornea showed with fluorescein some very fine superficial dots and fine vertical lines, which lasted a short time only. The lids, especially the lower, were in a condition of marked madarosis. Histological examination of the pericorneal swelling showed a marked infiltration of the pericorneal conjunctiva, the deeper epithelial layers of which were œdematous, with detritus between the infiltrating cells, the whole being very little vascular. The author has been unable to find a similar case described.

BERNARD CRIDLAND.

(2) **Galezowski,** of Paris, details six cases, male and female, ranging in ages from 34 to 60 years of age, who presented classical symptoms of tabes, and the following ophthalmoscopic changes:—papillary atrophy with bone-corpuscle pigmentary degeneration of the retina at the equator; pigmentary retinal degeneration with hemeralopia without atrophy of the discs; atrophy of the optic nerves with iridochoroiditis; optic atrophy with choroiditis; double interstitial keratitis. These symptoms, apart from, and in addition to, general nervous symptoms, sensory and motor disturbances of the eye, and optic atrophy, prove conclusively that deep inflammations of the ocular tunics may appear as manifestations of tertiary syphilis in tabetics.

J. JAMESON EVANS.

(3) In this case, by **Brückner,** of Königsberg, the right eye had become necrotic and transformed into scar tissue. There was extensive cicatricial change in the eyelids and surrounding skin. The condition is shown by a photograph. Eventually, the boy died of Bright's disease. A coloured plate shows a section of the optic nerve.

T. HARRISON BUTLER.

(4) The authors state that conjunctival chancres are not rare; they are among the most frequent of extra-genital chancres. The cases recorded are (1) chancre of the bulbar conjunctiva and cornea, (2) chancre of the palpebral conjunctiva, (3) chancre of the bulbar conjunctiva. The ulceration in the first case commenced as three small ulcers, which fused later on. The authors believe that the invasion of the cornea that occurred in this case is exceptional. No spirochætes were found, and the Wassermann reaction was only discovered to be positive five weeks after the ulcers appeared. In the second case the Wassermann reaction was positive, yet there were no enlarged glands; in the third the glandular enlargement was very marked.

(5) What was supposed by **Luedde,** of St. Louis, to be an ordinary lacrimal abscess, but with the main body of the swelling rather higher than usual, did not recede under appropriate local treatment and the administration of small doses of potassium iodide. A suspicion of the possibility of syphilis then arose, and was confirmed by closer investigation of the history. The iodide was rapidly increased, while no change was made in the local treatment. The case promptly cleared up. "The fact that the patient continued to get worse under small doses of potassium iodide and then recovered rapidly under large doses without any other modification in the treatment, is a lesson in the therapeutics of this drug which needs no further comment."

ERNEST THOMSON.

(6) **Wicherkiewicz,** of Cracow, says that two questions arise in this connection, *viz.*, (1) Can an injury, in presence of a syphilitic dyscrasia, produce a syphilitic keratitis parenchymatosa? (2) If the second eye become affected later, is this to be attributed to the injury? He considers that the first question has now been definitely decided in the affirmative. Regarding the second, he holds that inflammation in one eye sets up sympathetic irritation of

the other, and that this, like the injury itself, acts as the starting point of a specific keratitis. A. J. BALLANTYNE.

(7) The case described by **Clapp**, of Baltimore, was that of a widow, aged 54 years, who developed a hard, indurated, circumscribed mass, near the inner angle of the right upper lid, which was associated with thickening of the palpebral conjunctiva over the thickened area. Later, ulceration of the conjunctiva near the limbus, and also of the cornea, took place. The Wassermann reaction was found to be positive, and antisyphilitic treatment was followed by rapid subsidence of all symptoms.

The case was regarded as a gumma rather than a chancre, because of the position of the lesion and the absence of enlargement of the preauricular and submaxillary lymphatic glands. J. JAMESON EVANS.

(8) This case by **Dodd**, of Chicago, was in a woman of 31 years. Four years previously the glands in the neck became enlarged, and her throat was sore for some time. Two years later the glands were removed as tuberculous. The eye trouble started about eighteen months after this operation. A hard swelling appeared at the temporal margin of the orbit. An orbital abscess was diagnosed at first, and three incisions were made into the swelling, but pus was obtained only after the last of these. Resolution did not, however, occur, and later the eye became proptosed. Six months after the commencement of the eye affection, she was seen by Dodd. He operated and removed some necrosed bone, finding in the course of the operation that the disease commenced about an inch from the median line, and was not connected, as he had expected, with the frontal sinus. A Wassermann test proving positive, the patient was given an injection of Salvarsan and vigorous anti-syphilitic treatment, with the result that convalescence was rapid and complete, with less disfiguration than had been anticipated. Obviously, the previous glandular enlargement in the neck had been syphilitic, not tuberculous. From a study of the other reported cases, Dodd concludes that: "Syphilitic periostitis may be present at any age, as it occurs from the hereditary as well as from the acquired forms; in the acquired form it may appear at any time after the late secondary or early tertiary changes take place—that is, one and half years or more after the primary infection; the symptoms may be very similar to those of an orbital tumour, but pain of a neuralgic character is frequently present, an unusual occurrence with orbital tumour. The danger of a mistake in diagnosis is greater in children, in whom rapidly growing malignant tumours are more common." ROSA FORD.

(9) **Lacompte**, of Ghent, records the case of a girl, aged 15 years, who developed parenchymatous keratitis on the third day after the extraction of a cataract through an 8 mm. keratome incision in the lower limbus, performed in the clinic of Professor Fuchs in Vienna. The Wassermann reaction was positive. The author claims that his case is one of the few which fulfil the conditions requisite to prove a parenchymatous keratitis to be of traumatic origin, *viz.*, the eye was known to have been previously free from inflammation, the traumatism was undeniable, and the inflammation developed rapidly under the observation of the surgeon within a few days of the injury.

R. J. COULTER.

(10) **Mylius**, of Goerlitz, reports a case of a female patient, 25 years of age, who gave a history of dimness of vision for eight days. On ophthalmoscopic examination, he found floating vitreous opacities, the papilla invisible, being concealed by a large, dense, connective tissue-like mass, of bluish-white colour, and with dilated vessels coursing through it. Vision was fingers at half a metre. A history of specific infection was obtained. There was rapid disappearance of the mass and the new-formed vessels under specific treatment. In

a few weeks' vision was 5/5, and everything was normal. The unusually good result is taken to prove that the disease was confined to the papilla, and did not involve the nerve. It seemed to be a pure perivasculitis with formation of massive granulation tissue round the disc vessels, which became completely absorbed. A. J. BALLANTYNE.

XI.—MYOPIA.

(1) **Menacho.—A contribution to the study of the ætiology of myopia. (Contribucion á la etiologia de la miopia.)** *Archiv. de Oftal.*, Mayo, 1911.

(2) **Stargardt.—The central green patch in myopia. (Der zentrale grüne Fleck bei Myopie.)** *Zeitschrift für Augenheilkunde*, April, 1912.

(3) **Jaspers, I.—On the myopia question. (Zur Myopiafrage.)** *Zeitschrift für Augenheilkunde*, Juni, 1912.

(4) **Pichler, Alexius.—Rupture of the choroid as the probable cause of high myopia. (Aderhautruptur als wahrscheinliche Ursache einer hochgradigen Kurzsichtigkeit.)** *Klin. Monatsbl. f. Augenheilkunde*, September, 1912.

(5) **Bietti, A.—A contribution to our knowledge of the central green spot in myopia. (Beitrag zur Kenntnis des zentralen grünen Fleckes bei Myopie.)** *Klin. Monatsbl. f. Augenheilkunde*, November, 1912.

(6) **Handmann, M.—On temporary myopia in orbital new growths. (Ueber temporäre Myopie bei orbitalen Neubildungen.)** *Zeitschrift für Augenheilkunde*, Dezember, 1912.

(7) **Wilson, J. A.—Myopia: A review of five hundred cases with special reference to ætiology.** *Glasgow Medical Journal*, April, 1913.

(1) **Menacho** has noted that in many cases of myopia there are stigmata on the cornea, which are invisible to ordinary methods of examination, but which are easily detected by the changes seen when the cornea is observed by keratoscopy. He considers that this indicates a preceding keratitis, and holds that this is the true cause of the myopia and astigmatism observed by him in these cases. HAROLD GRIMSDALE.

(2) **Stargardt,** of Kiel, describes and figures a case of high myopia (17 D.) in a woman of 28 years, in whom a green patch appeared at the macula. There was no depression and no hæmorrhage. Stargardt compares this case with one described by the reviewer in the *Zeitschrift für Augenheilkunde* (Bd. XXVI, Heft 2),* and criticises Butler's theory, namely, that the production of the hole was due to over-stretching, and that the green colour was caused by altered blood pigment. Stargardt states that there could be no question of a macular hole at all; the green colour is caused by an alteration in retinal pigment; and the condition is comparable with Fuchs' black spot in myopia. Stargardt may be quite correct in this latter view, but he is wrong in saying that there were no holes; as a matter of fact, as shown by the drawings, there was a very deep macular hole in each eye. The green colour probably

*See also THE OPHTHALMOSCOPE, 1909, page 2.

had a common cause in each case, but here the resemblance between them ceases. His case showed a green *patch*, the reviewer's a green *hole* in each eye, associated with hæmorrhages and cicatrices of the retina. Deutschmann has discussed Butler's case, and compares it with others of his own in which macular *holes* were associated with myopia (*Zeits. für Augenheilkunde*, Juni, 1912). T. HARRISON BUTLER.

(3) **Jaspers**, of Marburg, has dealt with the Marburg myopia material in the same way that Siebenlist has done with the Greifswald cases (*Zeitschrift für Augenheilkunde*, Mai, 1911). Siebenlist examined 26,419 patients and found 13 per cent. of myopes among them. Jaspers, among 37,484 patients, found only 7·99 per cent. In both cases myopia under 1D. was not included. The two papers, and also a similar one by Hertel, are arranged upon the same general plan, in order that as large a number of cases as possible may be statistically correlated. Jaspers' figures agree exactly with those of Siebenlist, so that as the latter's results have already been abstracted in this journal,* it is unnecessary to repeat them in this place. The most remarkable fact brought out is that high-grade myopia is more common among peasants than among those engaged in close eye-work. The reverse is, of course, true regarding low-grade myopia. T. HARRISON BUTLER.

(4) A man of forty gave the story that at the age of six, he received a blow on the right eye, which had always been healthy. The injury caused a reduction of the vision in that eye; it remained red for some time; and a squint developed. At thirteen years of age, his face was injured by a fall from a height. There was said to be no myopia in the family. When examined by **Pichler**, of Klagenfurt, the patient presented a concomitant divergent strabismus of thirty-five degrees in the right eye. The radii of curvature were similar in the two corneæ. The lens of the right eye was not tremulous. There was a slight corneal nebula. R.E. showed a disc horizontally oval in form, the width being twice as great as the height. It was surrounded by a sharply-defined yellowish zone, rounded at the nasal side, but pointed at the temporal side. Its edge was defined by an irregular pigment line, and towards the temporal side was partly concealed by heaping of pigment. The refraction was myopic, fourteen or fifteen dioptres, vision being equal to counting fingers at three-quarters of a metre and not improved by glasses. The condition, of which a picture is given, is believed by the author to represent a rupture of the choroid, possibly beginning as two ruptures, one above and the other below the disc, which afterwards united to form one embracing the papilla. He assumes that this rupture allowed of stretching of the posterior pole of the eyeball, and was thus the cause of the high myopia. Neither the history nor the condition (as illustrated) lends much support to the view, nor are Pichler's arguments convincing. A. J. BALLANTYNE.

(5) **Bietti**, of Siena, records a case in which a highly myopic eye presented a more or less round patch at the macula, larger than the disc, of a greenish colour, but having a black spot near its centre. No difference of level could be made out between the patch and the retina. There was a central scotoma, absolute for colours, and relative for white. The first case of the kind was reported by T. Harrison Butler in the *Zeitschrift f. Augenheilkunde*, 1911. It was described as a "hole" at the macula. Stargardt, who followed with a second case, formed the opinion that neither the retina nor the choroid was involved, and that there was a proliferation of the cells of the retinal pigment layer. This view was supported by the microscopic examination in a case reported by Lehmus, and it is further upheld by the characters of Bietti's case. The green patch is supposed to be due to proliferation of

*See THE OPHTHALMOSCOPE, 1912, p. 411.

the retinal epithelium in an unpigmented condition, and the black spot to proliferation of pigmented cells. The tissue formed is analogous to the tapetum of the carnivora. A. J. BALLANTYNE.

(6) **Handmann**, of Dresden, cites cases which demonstrate the fact that certain orbital growths may compress the eye laterally, and cause temporary myopia. T. HARRISON BUTLER.

(7) The review of five hundred cases of myopia by **J. A. Wilson**, of Glasgow, is essentially statistical. It shows up once more the extreme difficulty of coming to any sound conclusion as yet regarding the ætiology of myopia. The author does not seem to attempt to draw any very definite conclusions, but we may quote some of the statements he makes at the end of his article :—" Of all the etiological factors heredity is probably the most important. If hereditary myopia is an adaptation for near work acquired by habits and environment operating through many generations, then in many cases it is an adaptation that oversteps its purpose and ends in disaster. . . . The near work of school years is an industry that is contemporaneous with the manifestations of heredity, and it is just possible that the respective responsibilities may be confused. Myopia is essentially an enfeeblement, notwithstanding the fact that there are many cases of low myopia that are resistant and stationary. It is more a woman's than a man's defect, for housewives and domestic servants predominate ; a class that does little of the so-called pernicious near work. The sedentary, or domesticated, individual, when reading, writing, or working within a confined space, may be invoking other influences as injurious as the convergence and depression of the visual lines with the associated muscle compression. Dogmatism on this subject at present is useful if it provokes discussion or stimulates investigation, but otherwise it is of little value. We shall only get at the truth through observations which have been verified and accepted as actual facts."

ERNEST THOMSON.

XII.—REMEDIES.

(Tenth Notice.)

(1) **Clausen, W.—The use of noviform ointment in external ocular therapeutics. (Die Anwendung der Noviformsalbe in der äussern Augenheilkunde.)** *Zeitschrift f. Augenheilkunde*, März und April, 1913.

(2) **Dwyer, James Garfield.—The use of vaccines in eye infections.** *Archives of Ophthalmology*, May, 1913.

(3) **Ginsberg, S., and Kaufmann, M.—The treatment of pneumococcal infections of the cornea in the rabbit by alkaloids of the quinine group. (Beeinflussung der kornealen Pneumokokkeninfektion beim Kaninchen durch Chinaalkaloide.)** *Klin. Monatsbl. f. Augenheilkunde*, Juni, 1913.

(4) **Hamburger, C.—The use of Wassermann's Histopin Ointment in Ophthalmology. (Ueber den Gebrauch Wassermannscher Histopinsalbe in der Augenheilkunde.)** *Klin Monatsbl. f. Augenheilkunde*, Juni, 1912.

(5) **Stephenson, Sydney.—Some remarks upon the diagnosis and treatment of lacrymal affections.** *Clinical Journal*, July 23rd, 1913.

(6) **Duverger.—On the action of sulphate of zinc upon the diplobacillus of subacute conjunctivitis. (Action du sulfate de zinc sur le diplobacille de la conjonctivite subaiguë.)** *Ann. d'Oculistique*, septembre, 1913.

(7) **Verry-Westphal, Arnold.—Researches upon the action of the salts of zinc in diplobacillary conjunctivitis. (Recherches sur l'action des sels de zinc dans la conjonctivite diplobacillaire.** *Ann. d'Oculistique*, septembre, 1913.

(8) **Moxon, Frank.—The use of atropin tablets for the determination of refraction in children.** *Lancet*, October 11th, 1913.

(1) **Clausen,** of Königsberg, recommends the use of noviform ointment. Noviform is a tetra-brom-benz-katechin salt of bismuth having the formula Bi (C_6, Br_4, O_2) OH. It is a useful dusting powder, which has no smell and which may be used advantageously instead of iodoform. It is insoluble in water, and can be sterilized because it tolerates a temperature of 110° Celsius without decomposition. It is non-toxic. The author finds that a 5-10-20 per cent. ointment is very efficient in blepharitis, especially in cases which do not tolerate yellow oxide ointment well. Experiments have shown that it has active bactericidal powers. T. HARRISON BUTLER.

(2) **Dwyer,** of New York, finds the results of vaccine treatment of eye infections very satisfactory. In twenty-seven cases of hordeolum thus treated, twenty were cured, one showed no improvement, and two were still under treatment. In all these cases, the staphylococcus was found, and an autogenous vaccine was used. All had lasted for years, and some had been treated and "refracted" by some of the best men in New York without improvement. In more than two-thirds of the cases there was a history of furuncles elsewhere, a fact which supports the writer's contention that it is useless in these cases to confine attention to local treatment. Unsolicited testimony from some of the patients of the improvement in their general health, again, strengthens the view that the hordeolum is only a part of a general furunculosis. The dose used was from 100 to 1,000 millions and seven or eight injections were given, and care was taken that two doses were adminstered after apparent cure. Twelve cases of infection with the tubercle bacillus were cured; these comprised five cases of phlyctenulæ, one of iritis, one of choroiditis, three of keratitis, and two of episcleritis. In six cases of gonorrhœal infection, two of iritis, and four of conjunctivitis, cure resulted. Two cases of serpiginous ulcer, with the pneumococcus as agent, were cured in five and seven days respectively, and the writer attributes the unusually rapid cure to the vaccine treatment; one case of pneumococcal kerato-hypopyon was cured in four days. Recovery ensued in four cases of streptococcal dacryocystitis, and in three cases of staphylococcal dacryocystitis, one of which had lasted for years, and in three cases of staphylococcal conjunctivitis. One patient infected with the bacillus mucosus capsulatus, one with Friedländer's bacillus, and two with the Morax-Axenfeld bacillus were also cured. Dwyer thinks it of unquestionable importance to use an autogenous vaccine, and it is better to make these freshly every few weeks. The stock vaccine was employed only as an initial measure while the autogenous one was being prepared. ROSA FORD.

(3) The experiments conducted by **Ginsberg** and **Kaufmann,** of Berlin, chiefly concerned the quinine derivative known as Aethylhydrocuprein hydrochloride. The method employed was to infect the cornea of the rabbit with pneumococci, to treat the resulting condition by instillation or subconjunctival injection of the alkaloidal solution, then to remove the cornea, grind

it in a mortar, and inject it into the abdomen of the mouse, in order to determine whether any pneumococci survived. Infected, but untreated, controls were employed. The authors were convinced of the efficacy of the treatment, so far as the experiments went. They did not experiment upon human subject, but they think that the conditions would be favourable for the use of the treatment in man. A. J. BALLANTYNE.

(4) Histopin is a watery extract of living staphylococci. It has been found to possess curative and prophylactic poperties in the form of a local application to the skin in acne vulgaris, furunculosis, chronic eczema, and impetigo contagiosa. It is obtainable in a fluid gelatine or in ointment. **Hamburger**, of Berlin, has employed the ointment for blepharitis, keratoconjunctivitis eczematosa, and other eye conditions, and finds its action superior to that of yellow oxide ointment. A. J. BALLANTYNE.

(5) **Stephenson,** of London, indicates the change, well known to every ophthalmologist, which has come over the treatment of lacrymal affections of recent years, and counsels the general practitioner to remember that these troubles are very frequently really dependent upon nasal conditions. Probing should not be employed unless there are good grounds for that line of procedure. Should it be thought proper to use probes, particular care should be taken to render the operation as little painful as possible by applying cocain, not only to the conjunctival sac, but also to the lacrymal sac itself and to the interior of the nose. The value of extirpation of the sac is insisted upon, more especially as regards the working classes, and Toti's operation is mentioned as an alternative. ERNEST THOMSON.

(6) **Duverger**, of Limoges, working in Morax's Laboratory, at the Institut Pasteur, in Paris, has carried out a series of experiments with regard to the action of sulphate of zinc on the Morax-Axenfeld diplobacillus. He first investigated the action of a solution of sulphate of zinc placed in contact with the diplobacilli for a limited time. To obtain such a contact he used elongated test tubes, occluded at their open end with cotton wool and thoroughly sterilised, containing pledgets of glass thread. In making the experiments the pointed end of the tube was broken, and some drops of culture were aspirated into it and allowed to become fixed to the glass thread. The solution of zinc was then drawn into the tube until it covered the glass thread, and left in contact with it for the desired time, after which it was blown out of the tube and its remains were washed out with several relays of sterile physiological saline solution. Some sterile bouillon was then brought into contact with the microbes on the glass thread and inoculated on coagulated serum. The following results were obtained.—1. No sulphate of zinc was used, but the diplobacilli were washed for from 5 to 20 minutes with sterile physiological saline solution. There were growths in all the tubes inoculated 2. Diplobacilli were left in contact with 1 in 50 sulphate of zinc solution for 10 seconds, 10 minutes, and 30 minutes. Only the first tube gave a culture, the other two remaining sterile. 3. Diplobacilli of three different strains were left in contact with a 1 in 50 solution of sulphate of zinc for 25, 30, and 50 seconds respectively. All three gave positive cultures. 4. Diplobacilli of two different strains were left in contact with 1 in 50 solution of sulphate of zinc for 1, 1½, and 2 minutes. All the tubes gave cultures. 5 and 6. Twenty-five tubes were inoculated with diplobacilli which had been in contact with a 1 in 50 solution of sulphate of zinc for periods ranging from 1 to 10 minutes. All the results were positive, with the exception of 2 tubes in which the contact was only for 5 minutes. To sum up, in 45 tubes inoculated with diplobacilli exposed to contact with solution of sulphate of zinc for periods varying from 10 seconds to 10 minutes

only four failed to give growths, showing that *in vitro* sulphate of zinc in ordinary strength does not kill the diplobacilli.

The second set of experiments dealt with the effect of adding sulphate of zinc to the culture medium, and showed that.—1. Exposure of the organism to a 1 in 40 solution for one minute without subsequent *lavage* did not inhibit its growth. 2. Addition of from 1 to 40 drops of 1 in 40 solution to the culture medium (coagulated serum) before coagulation inhibited the growth. 3. Covering the surface of the coagulated medium with 10 drops of solution of varying strengths for a few seconds (*pendant quelques instants*) followed by *lavage* and inoculation gave the following results:—with solutions from 1 in 40 to 1 in 100, growth inhibited; with 1 in 500 solution, one or two small colonies; with 1 in 1,000 solution, abundant growth.

The third set of experiments showed that the addition of rabbit or horse serum to solutions of sulphate of zinc did not make any alteration in their action on the organisms.

Duverger considers that the therapeutic action of sulphate of zinc needs further investigation, and that his experiments, while confirming the results of previous investigations, that it is not bactericidal, suggest that it inhibits the growth of the organism by impregnating the epithelial cells and the intercellular fluid. R. J. COULTER.

(7) **Arnold Verrey-Westphal**, of Lausanne, working in Morax's laboratories at the Hôpital Lariboisière and the Institut Pasteur de Paris, has investigated by means of cultures and cytological examinations the changes which take place in the contents of the conjunctival sac after the instillation of solutions of salts of zinc in cases of angular conjunctivitis, with a view to explaining how it is that the sulphate of zinc cures the disease, although it does not kill the Morax-Axenfeld diplobacillus.

The following facts were noted with regard to cultures of the micro-organism.—Direct culture on ascitic-agar succeeded only once, even when cultures on coagulated serum gave flourishing colonies, but sub-cultures from the latter medium on the former always gave positive results. Cultures on potatoes and carrots with their bases soaked in ascitic fluid gave no growths, even if the potato or carrot had been dipped for a moment into the fluid, but if the inoculation was made on the part of the vegetable moistened by capillarity, a growth took place which extended over the whole piece. Inoculation in milk was negative, but in milk diluted with one-quarter or one-third of ascitic fluid it was positive, the milk being partly digested and the development of diplobacilli much greater when the larger quantity of ascitic fluid was added. In pure ascitic fluid the growth of diplobacilli was very scanty and only involution forms occurred, but in sub-cultures from it on ascitic-agar typical colonies developed. On ascitic-agar-maltose and ascitic-agar-dextrose there was no alteration in the colour of tournesol.

The author repeated for the soluble salts of zinc (sulphate, citrate, permanganate, and lactate) the experiments made by Morax and Reiss on the resistance *in vitro* of the diplobacilli to the sulphate. The chloride was not tried, since it was regarded as too caustic, while the citrate did not prove sufficiently soluble, and the bromide was rejected as it always gave an insoluble flocculent precipitate. It is probable that the difficulty with these two salts was due to the formation of an insoluble oxide from exposure to the air.

In the course of his experiments the author found that he could not rely upon the results obtained when more than one sub-culture of the micro-organism had been made.

The method of procedure was as follows.—The surface of a culture of diplobacilli on ascitic agar, not more than two or three days' old, was washed

with bouillon, forming a solution with bacilli in suspension, which was aspirated into pipettes containing pledgets of sterile glass thread and shaken so as to spread over the thread. This was found to prevent the diplobacilli from being washed away in the subsequent manipulations. The solution of zinc was then aspirated into the pipette and left in contact with the suspension of bacilli from five to ten minutes, the end of the pipette being sealed by heat. The end of the pipette was then broken, the zinc solution forced out, and the glass thread washed by passing 180 c.c. of sterilised water in and out of the tube, the last 10 c.c. being left for ten minutes in contact with the glass thread containing the diplobacilli. After expelling the water, the glass thread was covered with sterile ascitic bouillon and the tube was placed in the incubator at 37° C. Control tubes were treated in an exactly similar manner, except that the zinc salt was omitted. The results showed that the only salts of zinc which prevented the diplobacilli from developing *in vitro* were the acetate and permanganate of zinc in 5 per cent. and 2½ per cent. solutions in contact for ten minutes and the permanganate of zinc in 5 per cent. solution in contact for five minutes.

The following experiments were made *in vivo*.—In patients in whose conjunctivæ the presence of diplobacilli had been demonstrated a 1 mm. loop of platinum was laid on the lower palpebral conjunctiva, avoiding masses of secretion, and afterwards shaken in 5 c.cm. of sterile ascitic bouillon. This was poured into a Petri dish containing coagulated serum, which was placed in the incubator, at 37° C. for half-an-hour, and then turned over. This was done before, and at intervals of 5, 10, 15, 30, and 60 minutes, several hours, 24 hours, etc., after the instillation of zinc solution. The results of nine cases treated with sulphate of zinc showed a uniform diminution in the number of colonies five minutes after the instillation, sometimes very marked (*e.g.*, from 230 colonies to 1). In twenty-four hours the number of colonies was usually larger than during the hour after the instillation but almost always much less than before the instillation. In all the cases which could be followed for sufficiently long, repeated instillations made the cultures free from diplobacilli. In two cases only, there were more organisms after two instillations than after one. One of these was complicated by a corneal ulcer, while the other, unfortunately, did not return for further treatment. Experiments with the other salts of zinc showed that they do not inhibit the growth of diplobacilli in the conjunctival sac. In fact, there were more colonies after two instillations of 2½ per cent. permanganate in three cases, and quite as many after two instillations of 2½ per cent. acetate in two cases as before treatment, but the symptoms were relieved.

Cytological examinations were made at the same intervals as the cultures. The method employed was as follows.—A drop of secretion was taken up in a capillary pipette, spread on a slide, dried, fixed with absolute alcohol, and stained in heat with diluted Giemsa (one or two drops in 1 c.cm). The results, available in six cases, showed preponderance of polynuclear leucocytes and epithelial cells with very few mononuclear leucocytes (one to 4 per cent. except in one case, in which there were 13 per cent. after 24 hours). Mast-cells, eosinophiles, etc., were rare. After instillation of zinc solution the number of diplobacilli present was markedly increased in five minutes but subsequently diminished rapidly, and those organisms present showed signs of degeneration, while the percentage of polynuclear leucocytes diminished and that of the epithelial cells increased, the curves of these two forms of cells being complementary, showing that the number of epithelial cells was increased but not necessarily that the polynuclears were fewer. The author gives details of two cases complicated by corneal ulceration. In the first there were

crescentic ulcers, two in the left eye with hypopyon and one in the right without hypopyon. Numerous diplobacilli were found in smears from the conjunctival sac and the ulcer in the right eye, and in the cultures on coagulated serum, but cultures on ascitic-agar gave a large number of colonies of staphylococci and xerosis bacilli but no diplobacilli. Under instillation of 2½ per cent. zinc sulphate, the corneal infiltration was much improved in 48 hours. The ulcer was cauterised with 5 per cent. sulphate of zinc on the third day of treatment, when a culture was taken which showed that, during the previous 24 hours, the number of colonies had increased from 39 to 60. Five days after the commencement of treatment, there was no stain with fluorescein. The other patient had a lozenge-shaped ulcer, without hypopyon, in the left eye. Instillation of 2½ per cent. sulphate of zinc relieved the symptoms, but the condition of the ulcer did not commence to improve until it had been cauterised with 20 per cent. zinc sulphate. Six days after the commencement of treatment, the culture contained nine colonies of staphylococci but no diplobacilli. The ulcer still stained on the seventh day. The clinical improvement in this case was much slower than in the previous one, which the author attributes to the presence of staphylococci which were much more numerous than the diplobacilli, and persisted after the latter had disappeared, a theory which was supported by the shape of the ulcer, which differed from that typical of one due to diplobacillary infection.

The author discusses the explanation of the striking difference in the results obtained from cultures and cytological examinations after the first instillation of zinc. He suggests that enough zinc may adhere to the 1 mm. loop or to the diplobacilli to inhibit their growth in the cultures or that the presence of degenerated forms in the cytological specimens may be evidence that they suffer at least a partial destruction. He suggests that the course of events in the conjunctival sac after instillation of zinc is somewhat as follows.—The diplobacilli have been shown to be lodged in the superficial layers of the conjunctival epithelium. In slight cases, these superficial layers are almost destroyed, and the action of the sulphate of zinc in contracting the conjunctiva, is sufficient to cause masses of epithelial cells, accompanied by diplobacilli, to fall into the *cul-de-sac*. The lacrymation which follows the instillation washes these away. In more severe cases, in which the diplobacilli have penetrated more largely into the epithelium, a much more complete shedding of the epithelium and washing is necessary to get rid of the germs. If this explanation is correct, it is probable that the absence of diplobacilli from the cultures was due to inhibition of growth by traces of zinc as suggested above. In support of this, he quotes a case of diplobacillary conjunctivitis with corneal ulcer, in which a culture before treatment gave 506 liquefying colonies, while after a careful *lavage* with saline solution, a culture from the caruncle gave five colonies, and one from the external canthus gave sixteen colonies, showing that the diplobacilli were washed in the direction of the stream of fluid. On the following day, after two instillations of sozoiodolate of zinc (which in other cases produced no effect), there were 13 colonies before *lavage* and none after. In another case with both eyes equally affected, one eye was irrigated with saline and the other untreated, and cultures showed 5 colonies of diplobacilli in the former and 20 in the latter, while there were large numbers of colonies of staphylococci in both eyes, showing that *lavage* has a much greater action on diplobacilli than on other micro-organisms.

The author considers that, so far as his experiences go, the washing away of the germs, as suggested above, has the greatest influence in the cure of diplobacillary conjunctivitis, but he feels convinced that there are other factors in causing it. He finds that the pain caused by the acetate of

zinc lasts at least an hour, so that it cannot be checked by the addition of cocain. But the other salts are less painful than the sulphate.

R. J. COULTER.

S. **Moxon**, of London, after a large experience of children's refraction work at Moorfields Hospital, has found that in only one case out of 800, has the application of one tablet of atropine been insufficient to cause paralysis of accommodation. The author describes his particular method of introducing the tablets simultaneously into both lower fornices by means of the fingers. He finds that 1/200 grain of atropine is sufficient, and that the saving of time over the old home method of applying ointment or drops is very great. The cost of material, also, is apparently rather less, since each patient costs one half-penny for tablets, as against one half-penny for atropine ointment, *plus* the cost of a glass rod, *plus* the cost of the dispenser's time.

ERNEST THOMSON.

BOOK NOTICES.

A Monograph on Albinism in Man. By KARL PEARSON, F.R.S., E. NETTLESHIP, F.R.C.S., and C. H. USHER, M.B., B.C. Camb. (Drapers' Company Research Memoirs, Biometric Series IX.). Text Part IV and Atlas Part IV. London: Dulau and Co. 1913. Price 21s. net.

These two volumes contain respectively descriptions of pedigree figures and bibliography, and pedigree plates and pedigrees. The work is one which is beyond the criticism of any but the expert in biometric study. It is a colossal monument to the industry of its authors. ERNEST THOMSON.

Trachoma and its Complications in Egypt. By A. F. MACCALLAN, Director of Ophthalmic Hospitals, Egypt. Cambridge: The University Press. London: Fetter Lane, E.C. 1913. Price 7s. 6d. net.

No one has a greater right to speak with authority upon questions connected with trachoma in Egypt than the Director of the Government Ophthalmic Hospitals, the author of the latest book upon the subject. Such being the case, we regret that he has not been more ambitious, for it is manifestly impossible to include a complete treatise upon the subject within the compass of 70 pages, printed in large, clear, well-spaced-out type. Under the circumstances, we cannot take the work very seriously. It is not so much a contribution to ophthalmic literature as a text-book for the Egyptian assistants in the ophthalmic hospitals and for the medical students in Cairo. Since the book is issued in Arabic as well as English, this was probably the intention of the author.

MacCallan divides trachoma into four stages, a classification which is useful for statistical work, as well as for teaching purposes, but which is at best somewhat artificial, because the change from the florid disease to complete cicatrisation is a gradual one, not characterised by sharply-marked stages.

In Egypt the disease is distributed over ten degrees of latitude, and it attacks without distinction the various races which inhabit the valley of the Nile. It is interesting to find that negroes are not exempt, because it has been often stated that the negroid race has a natural immunity from trachoma.

The author believes that flies play but a small part in transmitting the disease, pointing out that Mayerhof and Morax failed to obtain specific evidence of such a means of infection.

The reviewer's experience in Palestine agrees with the author's in Egypt with reference to the occurrence of acute trachoma: in most instances the acute cases are infected with well-known micro-organisms; sterile acute cases are rare. The general tendency is for the affection to be chronic from first to last. The nature of the acute complications of trachoma caused by an infection with the gonococcus, the diplobacillus, and the Koch-Weeks bacillus is fully described.

We cannot agree with MacCallan, when he says that protargol is inferior to silver nitrate in the treatment of the early stages of trachoma and of its acute complications. Our investigations upon this subject have led us to the opposite conclusion. Generally speaking, we found that protargol in 33 per cent. solution was superior to silver nitrate in one to two per cent. solution, but in some examples of gonococcal infection we found the inorganic salt to be the more potent. In the East, moreover, where evaporation is rapid, and treatment is often carried out by unskilled hands, the organic preparation is far safer. We disagree with the author, who states that, in his experience, protargol and argyrol do not cause argyrosis. They do so very readily; in fact, we believe that argyrol, by reason of its high silver content, is more dangerous in this respect than silver nitrate. Only recently we have seen severe staining of the conjunctiva caused by argyrol. There was occasion to excise the lacrymal sac, and the operation was rendered easier by the fact that the sac was completely black!

MacCallan gives a full account of the operations he employs for the relief of trachoma and of trichiasis. The absence of illustrations detracts somewhat from the value of these otherwise excellent descriptions. One notes that the Spencer Watson method, which the reviewer found very useful in Palestine in cases where the trichiasis was confined to the outer aspect of the upper lid, is not mentioned.

The different varieties of pannus are insufficiently treated. The reviewer has seen pannus commence from below and cover the cornea, and he has seen it develop from above and below and meet in the middle. There is also a form in which the whole cornea is covered by a plum-jelly-like coat. This variety rapidly yields to the yellow oxide of mercury ointment with atropine. Yellow oxide ointment, which is certainly valuable in trachoma, is not mentioned in the work.

The chapter upon pathology is scarcely full enough to be of any great value, but for the class of man for whom we imagine the book is written, it may be all that is necessary. The author is not as definite as one might wish upon the subject of cell inclusions. The evidence against the view that these bodies are the exciting cause of trachoma is now so weighty that even Greeff himself has recanted his former views. They have been detected in conditions in which there could be no question whatever of trachomatous infection, and, for that matter, even in normal eyes. T. HARRISON BUTLER.

The Origin of Spherical Refractions of the Human Eye. (Die Entstehung der sphärischen Refraktionen des menschlichen Auges.) von Dr. med ADOLPH STEIGER, Augenarzt in Zürich. Berlin: Verlag von S. Karger, Karlstrasse 15. Price 18 marks unbound, 20 marks bound. 1913.

This is a ponderous volume of 567 pages, which includes a bibliography of 441 references, of which only about twelve are derived from British journals.

The book is a compilation, with very little original work by the author himself. Whole chapters are devoted to the relation of the views of ophthalmic surgeons, some of the highest reputation, others comparatively unknown. The statements and statistics are criticised and utilised as they best fit in with the author's views; in some cases, the same author even seems to do duty as an advocate of two entirely opposite points of view. The first chapter is devoted to answering the question, "What is normal refraction?" Steiger says that there is no such thing, any more than there is a normal height for a man. Small degrees of hypermetropia are just as normal as emmetropia or slight myopia. Judging by the false standard of statistics, slight hypermetropia would appear to be the normal refraction of the human race. All this seems to be begging the question. A tall man and a short man may be equally efficient, and obviously there can be no normal height, but the emmetropic eye is essentially different from the hypermetropic organ in that it is in focus for distant objects when its musculature is in equilibrium, a condition which obtains neither in the hypermetropic nor in the myopic eye. The emmetropic eye is obviously from an optical standpoint the perfect one—the normal eye. It may not be the average eye; in fact it is not.

The author goes on to insist, and the reviewer considers rightly, that it is incorrect to consider any refractive error apart from the others. The causes which conduce to myopia are intimately associated with those which determine emmetropia or hypermetropia. The ultimate refraction of an eye depends upon the proportion which obtains between the refracting value of the cornea and the axial length of the globe. The corneal refractive power varies from forty to fifty dioptres, and if the axial length be correctly proportioned, emmetropia may be present with corneæ which vary between these wide limits. As a matter of fact, upon the whole, in myopic eyes the cornea tends to be more convex than in hypermetropic eyes, but the difference does not average more than half a dioptre. Both these factors vary sufficiently to allow natural selection and heredity to modify the refraction of different races. Thus, myopia would be a great disadvantage to a savage, and, in consequence, natural selection has almost eliminated myopia from an aboriginal community, although as the author admits, high myopia with choroidal changes is by no means absent from Arabs and other uncivilised men. On the other hand, with increasing civilization myopia tends to be less and less a fatal disadvantage, and consequently by purely natural laws the incidence of myopia rises in these communities until it reaches its maximum in the Jewish and Teuton stock.

The author does not state that the Germans actually are the most cultured race, but this is the logical sequence of his argument, a correct argument we believe. Heredity and natural selection are the factors which determine the average refraction of the individual. Myopia is, Steiger thinks, one disease; it cannot be separated into varieties, such as "school myopia" and "pernicious progressive myopia." All kinds are essentially the same. There is no such thing as "school myopia."

The accepted doctrine was initiated by Cohn, whose statistics, majestic in their wealth of figures, lie open to criticism, because the methods employed to compile them were faulty. The author complains that although the numbers of children whose refraction has been recorded now reaches a colossal total, we yet cannot deduce any rational hypothesis from them because the various compilations are not comparable among themselves. Some authors have employed a mydriatic, others have not; some have estimated the refraction with the refracting ophthalmoscope, others by skiascopy.

Another group of figures depends upon simple sight-testing, and, lastly, there are certain ophthalmologists who have simply depended upon the statement that certain children had parents who saw badly, and have from such meagre information advanced views regarding the inheritance of myopia. The author admits freely that myopia increases both in degree and incidence as we pass from the lower to the higher forms. He denies, however, that this progressive increase is the effect of close application at school; it is merely due to the fact that the age of the pupils is greater in the upper classes of the school. Other forms of close work have no influence upon myopia. Watchmakers tend to be hypermetropic rather than myopic, and the same is true of engravers and others. The hard-worked seamstress does not become myopic; she develops asthenopia. The author might have pointed out that hard-working English children do not develop myopia to the same degree as German children, because they have not the racial peculiarity which affects the German stock to such a degree that 50 per cent. of German professional men are short-sighted.

Dr. Steiger has succeeded in wrapping up his own views in such a volume of words that it is exceedingly difficult to discover exactly what he really thinks. When theory after theory is demolished, we expect to find the true explanation towards the end of the book. We believe that the author considers that heredity is the dominant factor, but we put down the work with no certainty upon this point. T. HARRISON BUTLER.

THE LATE MR. EDWARD NETTLESHIP.

Science, no less than ophthalmology, has sustained a grievous loss in the death of Edward Nettleship, F.R.S., which took place at his residence, Longdown Hollow, Hindhead, on October 30th last. The news that he was suffering from a mortal complaint had only recently become at all widely known, and his demise came as a shock to most of his colleagues.

Nettleship was of talented stock. He was one of the six sons of a Kettering solicitor, Henry John Nettleship. Of these distinguished brothers, none became more distinguished than the subject of this notice. The eldest of the brothers, Henry Nettleship, who died in 1893, held for fifteen years the Corpus Professorship of Latin at Oxford. Another of the brothers, John Trivett Nettleship, was a noted animal painter. Yet a third brother, Richard Lewis Nettleship, was a Fellow and Tutor of Balliol College, Oxford, and how much more can perhaps be fully appreciated only by those who came under his personal influence. His tragic death from exposure on the Alps is not yet forgotten, although it took place as long ago as August, 1892.

Edward Nettleship himself, who was born in March, 1845, at first qualified as a veterinary surgeon, but his thoughts soon turned to human medicine, and after pursuing his professional studies at King's College and the London Hospital, he obtained the diplomas of L.S.A. and M.R.C.S. in 1867 and 1868, and that of F.R.C.S. in 1870. From 1871 to 1873 he was Curator of the Museum and Librarian of the Moorfields Hospital. During 1873-74 he was Resident Medical Superintendent in charge of the Bow Branch Ophthalmic School, receiving diseased children from the West Surrey District School at Anerley. He became attached as ophthalmic surgeon to

the South London Ophthalmic Hospital (now the Royal Eye Hospital), the Hospital for Sick Children, Great Ormond Street, and eventually to the Royal London Ophthalmic Hospital (Moorfields) (1882-1898) and to St. Thomas's Hospital (1878-1895). At the time of his death he was consulting surgeon to the two institutions last-named.

For many years Nettleship enjoyed a large private practice, and in this



Mr. Edward Nettleship.

connection it will be recalled that he operated for cataract upon the late William Ewart Gladstone. At the very zenith of his popularity (1902), however, he retired from active practice, although that by no means implied cessation from work. On the contrary, he continued to take the greatest interest in learned societies, especially in the Ophthalmological Society of the United Kingdom, but, above and beyond all else, he devoted himself to the

scientific study of heredity as a factor in the causation of disease. Communication after communication on this subject, all implying painful labour, came from his fertile pen, to say nothing of more than one monograph, the latest of which is noticed in this issue of THE OPHTHALMOSCOPE. The value of his work on heredity was recognized by his election last year to the Fellowship of the Royal Society, the blue ribbon for scientific achievement in this country.

Nettleship's work in ophthalmology (as in all other subjects) was marked by an almost meticulous accuracy and attention to the smallest detail. The communications he made to the Ophthalmological Society alone cannot fall far short of one hundred, to say nothing of those published in the *Royal London Ophthalmic Hospital Reports* and in other directions. His "Diseases of the Eye," first published in 1879, ran through six editions. Many of us are indebted for our knowledge of ophthalmology to its pages, which were literally crammed with information, expressed in the tersest possible way. It was for many years the most widely read text-book of ophthalmology in England, and even now is doubtless often consulted, especially by the older generation of ophthalmic surgeons, although sixteen years have passed since the last edition was issued.

Not the least important of Mr. Nettleship's publications was a Government Report dealing with Ophthalmia in the Metropolitan Pauper Schools (1874), written after he had taken over the charge of some 400 diseased children belonging to the Anerley Schools, in the then new and unoccupied Whitechapel Workhouse in the Mile End Road. The Report led to the adoption of many needed reforms in the condition of the Poor-law child.

Nettleship rendered valuable public service by his work when a member of the departmental committees on the Maintenance and Education of Poor-law Children (1894) and on Sight Tests (1910) respectively. Only the other day he published a little book dealing with "Accidents from Defective Sight," reviewed in these columns in September, 1913.

He was one of the founders of the Ophthalmological Society in 1880, and acted as its first surgical secretary. He was a Vice-President from 1886 to 1889, and from 1895 to 1897 occupied the presidential chair. In 1909 he delivered the Bowman Lecture of the Society, taking as his subject "Some Hereditary Diseases of the Eye." Nettleship's life work was commemorated by a fund raised by his friends and admirers on his retirement from practice, which was conveyed to the Ophthalmological Society, in order that a Prize might be periodically bestowed upon the author of the best work published since the last award.

Mr. Nettleship in 1869 married Elizabeth Endacott, of Compton, Devonshire, who survives him. There is no issue.

We would associate ourselves with the vote of condolence to Mrs. Nettleship moved in touching terms by Sir Anderson Critchett from the chair at the last meeting (November 5th) of the Section of Ophthalmology of the Royal Society of Medicine.

In taking leave of this indefatigable worker and ardent student, we may be allowed to express deep sympathy with that band of earnest men, who trained by Nettleship and stimulated by his example, have, to the great benefit of humanity, carried his love of conscientious observation all over the world. R.I.P.

SYDNEY STEPHENSON.

THE OPHTHALMOSCOPE DIARY.

	1913.	
Royal Society of Medicine: Section of Ophthalmology.	December 3rd.	1, Wimpole Street, London.
Midland Ophthalmological Society	December 16th	Leicester Infirmary.
	1914.	
Oxford Ophthalmological Congress	July 8th to July 10th.	Oxford.
British Medical Association: Section of Ophthalmology.	July 15th to July 17th.	Aberdeen.
International Congress of Ophthalmology.	August 10th to August 15th.	St. Petersburg.

BINDING SECT. OCT 25 1937

RE
1
078
v.11
no.7-12

The Ophthalmoscope

Biological
& Medical
Serials

PLEASE DO NOT REMOVE
CARDS OR SLIPS FROM THIS POCKET

UNIVERSITY OF TORONTO LIBRARY